

A TEXT-BOOK OF HISTOLOGY

BY

FREDERICK R. BAILEY, A. M., M. D.

UNIV. OF CALIFORNIA

SIXTH REVISED EDITION

PROFUSELY ILLUSTRATED

NEW YORK
WILLIAM WOOD AND COMPANY
MDCCCCXX

UCSD LIBRARY

COPYRIGHT, 1920
By WILLIAM WOOD AND COMPANY

THE MAPLE PRESS YORK PA

PREFACE TO THE SIXTH EDITION

As stated in the preface to the fifth edition, the very gratifying approval which the previous editions of the Text-book have received has made it seem unwise to attempt any change in the general plan and scope of the work as outlined in the preface to the first edition. The text has been thoroughly revised, some parts of it rewritten. Some new figures have been added for which the writer wishes to acknowledge his obligations. While the chapter on the nervous system as it appeared in the first edition was the work of the author, the rewriting of this chapter for the fourth edition and again for the present edition has been so complete that the chapter is now properly credited to Dr. Oliver S. Strong, Associate Professor of Neurology, Columbia University. This chapter has been revised, extensively rewritten and considerably enlarged, not only by the addition of more detail but by allusions to the comparative anatomical, clinical, physiological and sometimes even the psychological significance of certain nervous structures. These are not intended to do more than suggest to the student the meaning of these structures and for this reason sometimes matter of quite a speculative character has been introduced. For the use of certain terms, suprasegmental, etc., and the conceptions underlying them, the author is indebted to Dr. Adolf Meyer.

471200

PREFACE TO THE FIRST EDITION

THE primary aim of the writer in the preparation of these pages has been to give to the student of medicine a text-book of histology for use in connection with practical laboratory instruction, and especially to furnish to the instructor of histology a satisfactory manual for classroom teaching. With these objects in view, the text has been made as concise as possible consistent with clearness, and the writer has attempted to make the more essential elements stand out somewhat from the necessarily accompanying details,

It has been impossible to accomplish this without some sacrifice of uniformity of treatment and of logical sequence. This is especially noticeable in the chapter on the nervous system, which has been made much fuller and more "practical" than is usual. The author's reason for the method of treatment there adopted and for the considerable amount of anatomy which this chapter contains is the apparent success the method has met with in the teaching of this always difficult subject to students.

The chapter on general technic is intended to furnish the student with only the more essential laboratory methods. For special and more elaborate methods the student is referred to the special works on technic mentioned at the close of the chapter. The special technic given in connection with the different tissues and organs is in most cases such as can be conveniently used for the preparation of class sections.

The original illustrations are from drawings by Mr. A. M. Miller, to whom the writer is greatly indebted for his careful and accurate work. The uselessness of redrawing perfectly satisfactory illustrations has led the writer to borrow freely from various sources, each cut being duly accredited to the work from which it has been taken. For all of these the author wishes to express his appreciation and obligation. He is also deeply indebted to Dr. O. S. Strong for his careful review and criticism of the chapter on the nervous system and for his supervision of the drawing of Figs. 263 and 264; to Dr. G. C. Freeborn, his predecessor as Instructor of Histology at the College of Physicians and Surgeons, for many valuable suggestions; and to Dr. T. Mitchell Prudden for his careful and critical review of the author's copy.

CONTENTS

PART I.—HISTOLOGICAL TECHNIC

CHAPTER I

PAGE

GENERAL TECHNIC.

General Considerations 3
Examination of Fresh Tissues 3
Dissociation of Tissue Elements 4
Teasing 4
Maceration 4
Preparation of Sections 5
Fixation 5
Decalcifying 10
Injection 13
Hardening 14
Preserving 14
Embedding 14
Celloidin Embedding 14
Paraffin Embedding 16
Section Cutting 17
Celloidin Sections 17
Paraffin Sections 18
Frozen Sections 18
Staining 20
Nuclear Dyes 20
Plasma Dyes 22
Staining Sections 23
Staining in Bulk 24
Mounting 25
Staining and Mounting Paraffin Sections 27

CHAPTER II

SPECIAL STAINING METHODS.

Silver Nitrate Method of Staining the Intercellular Substance 28
Chlorid of Gold for Demonstrating Connective-tissue Cells 28
Weigert's Elastic Tissue Stain 28
Verhoeff's Differential Elastic Tissue Stain 28
Golgi's Chrome-silver for staining Secretory Tubules 29
Mallory's Phosphomolybdic Acid Hæmatoxylin Stain for Connective Tissue . 29
Mallory's Phosphotungstic Acid Hæmatoxylin Stain for Connective Tissue . . 30
Mallory's Aniline Blue Stain for Connective Tissue 30
Maresh's Modification of Bielschowsky's Stain for the Finer Connective-tissue Fibrils 31

PAGE
Osmic Acid Stain for Fat 31
Sudan III and Charlack R for Fat 31
Jenner's Blood Stain 32
Benda's Method for Mitochondria 32

CHAPTER III

SPECIAL NEUROLOGICAL STAINING METHODS.
Weigert's Method of Staining Medullated Nerve Fibres. 33
Weigert-Pal Method 34
Marchi's Method for Staining Degenerating Nerves 35
Golgi's Chrome-silver Impregnation Methods 36
Slow Method 36
Rapid Method. 36
Mixed Method. 36
Formalin Bichromate Method 37
Bichloride Method 37
Golgi-Cox Method 37
Cajal's Method 38
Nissl's Method 39
General References on Technic. 41
Bielschorrsky's Silver Impregnation Method for Nerve Tissue 40
Weigert's Neuroglia Method. 40

PART II.—THE CELL

CHAPTER IV

THE CELL 43
General Structure 43
Structure of a Typical Cell 44
The Cell Body. 44
Theories of Structure of Protoplasm 45
Mitochondria 47
The Cell Membrane 47*b*
The Nucleus. 48
The Centrosome 50
Vital Properties of Cells. 51
Metabolism 51
Function 52
Irritability 53
Motion 53
Amœboid 53
Protoplasmic 54
Ciliary 54*a*
Reproduction 54*a*
Direct Cell-division, amitosis 54*a*
Indirect Cell-division, Mitosis 54*b*
Fertilization of the Ovum 59
Technic. 63
References for further study. 65

PART III.—THE TISSUES

CHAPTER V

PAGE
HISTOGENESIS—CLASSIFICATION 69
Tissues Derived from Ectoderm 69
Tissues Derived from Entoderm 69
Tissues Derived from Mesoderm 70

CHAPTER VI

EPITHELIUM (INCLUDING MESOTHELIUM AND ENDOTHELIUM) 72
Histogenesis 72
General Characteristics 72
Classification 73
Simple Epithelium 74
Simple Squamous 74
Simple Columnar 75
Pseudostratified 75
Stratified Epithelium 75
Stratified Squamous 75
Stratified Columnar 77
Transitional 77
Modified Forms of Epithelium 78
Ciliated Epithelium 78
Pigmented Epithelium 80
Glandular Epithelium 80
Neuro-epithelium 80
Mesothelium and Endothelium 80
Technic 82

CHAPTER VII

THE CONNECTIVE TISSUES 84
General Characteristics 84
Development 85
Classification 86
Connective Tissue Proper 86
Embryonal Connective Tissue 86
Fibrillar Connective Tissue 86
Connective-tissue Cells 87
Intercellular Substance 90
Areolar or Loose Connective Tissue 91
Fat Tissue 92
Formed or Dense Fibrous Connective Tissue 94
Tendons and Ligaments 94
Aponeuroses 95
Elastic Tissue 96
Reticular Tissue 97
Technic 98
Cartilage 101
Hyaline 101

PAGE
Elastic 103
Fibrous 103
Technic 104
Bone 104
Technic 106

CHAPTER VIII

THE BLOOD 107
Red Blood Cells 107
White Blood Cells 109
Blood Platelets 112
Blood Dust 112
Development 113
Technic 114

CHAPTER IX

MUSCLE TISSUE 115
Involuntary Smooth Muscle 115
Voluntary Striated Muscle 118
Involuntary Striated Msucle (Heart Muscle) 123
Development of Muscle Tissue 126
Technic 129

CHAPTER X

NERVE TISSUE 130
THE NEURONE 130
General Structure 130
The Cell Body 130
The Nucleus 131
The Cytoplasm 132
Neurofibrils 133
Perifibrillar Substance 133
Chromophilic Bodies 133
The Protoplasmic Processes or Dendrites 135
The Axone 135
Non-medullated Nerve Fibres (Non-myelinated Nerve Fibres) 137
Medullated Nerve Fibres (Myelinated Nerve Fibres) 138
Theories as to Physiology of the Neurone 140
Significance of Degenerative Changes in the Neurone 142
Neuroglia 147
Technic 149
General References 149

PART IV.—THE ORGANS

CHAPTER XI

THE CIRCULATORY SYSTEM 155
The Blood-vessel System 155
General Structure 155

PAGE
Capillaries . . . 155
Arteries . . . 157
Veins . . . 162
Technic . . . 164
The Heart . . . 165
Technic . . . 167
Development of the Circulatory System . . . 167
The Lymph-vessel System . . . 169
Lymph Capillaries . . . 169
Lymph Spaces . . . 169
Development of Lymph-vessel System . . . 170
Technic . . . 170
General References . . . 170

CHAPTER XII

LYMPHATIC ORGANS . . . 171
Lymphatic Tissues . . . 171
The Lymph Nodes . . . 171
Lymph . . . 175
Chyle . . . 175
Development . . . 176
Technic . . . 176
Hæmolymph Nodes . . . 177
Technic . . . 179
The Thymus . . . 179
Development . . . 181
Technic . . . 182
The Tonsils . . . 182
The Palatine Tonsils . . . 182
The Lingual Tonsils . . . 184
The Pharyngeal Tonsils . . . 184
Development . . . 184
Technic . . . 185
The Spleen . . . 185
Technic . . . 191
General References . . . 192

CHAPTER XIII

THE SKELETAL SYSTEM . . . 193
The Bones . . . 193
Periosteum . . . 196
Bone Marrow . . . 197
Red Marrow . . . 199
Yellow Marrow . . . 201
Technic . . . 202
Development of Bone . . . 202
Intramembranous Development . . . 203
Intracartilaginous Development . . . 205
Subperiosteal . . . 207
Growth of Bone . . . 208
Technic . . . 208

PAGE
The Cartilages . . . 209
Articulations . . . 209
Technic . . . 211
General References . . . 211

CHAPTER XIV

THE MUSCULAR SYSTEM.
A Voluntary Muscle . . . 212
Tendon Sheaths and Bursæ . . . 213
Growth of Muscle . . . 214
Technic . . . 216

CHAPTER XV

GLANDS AND THE GENERAL STRUCTURE OF MUCOUS MEMBRANES . . . 217
Glands—General Structure and Classification . . . 217
Duct Glands . . . 221
Tubular Glands . . . 221
Alveolar Glands . . . 222
Ductless Glands . . . 222
General Structure of Mucous Membranes . . . 223

CHAPTER XVI

THE DIGESTIVE SYSTEM . . . 224
Anatomical Divisions . . . 224
The Headgut . . . 225
The Mouth . . . 225
The Mucous Membrane of the Mouth . . . 225
Glands of the Oral Mucosa . . . 225
Technic . . . 228
The Tongue . . . 228
Technic . . . 232
The Teeth . . . 232
Development of the Teeth . . . 243
Technic . . . 247
The Pharynx . . . 247
Technic . . . 248
The Foregut . . . 248
The Œsophagus . . . 248
Technic . . . 250
General Structure of the Walls of the Gastro-intestinal Canal . . . 250
The Stomach . . . 252
Technic . . . 259
The Midgut . . . 260
The Small Intestine . . . 260
Peyer's Patches . . . 265*b*
The Endgut . . . 268
The Large Intestine . . . 268
The Vermiform Appendix . . . 270
The Rectum . . . 271

PAGE
The Peritoneum, Mesentery, and Omentum 272
Blood-vessels of the Stomach and Intestine 273
Lymphatics of the Stomach and Intestine 275
Nerves of the Stomach and Intestine 276
Secretion and the Absorption 277
Technic 280
The Larger Glands of the Digestive System 281
The Salivary Glands 281
The Parotid 282
The Sublingual 283
The Submaxillary 284
Technic 286
The Pancreas 286
Technic 292
The Liver 292
Excretory Ducts of the Liver 294
The Gall-bladder 301
Technic 301
Development of the Digestive System 302
General References 304

CHAPTER XVII

THE RESPIRATORY SYSTEM 305
The Nares 305
The Larynx 307
The Trachea 307
Technic 310
The Bronchi 310
The Lungs 314
Development of the Respiratory System 321
Technic 323
General References 323

CHAPTER XVIII

THE URINARY SYSTEM 324
The Kidney 324
The Kidney-Pelvis and Ureter 335
The Urinary Bladder 336
Technic 338
General References 338

CHAPTER XIX

THE REPRODUCTIVE SYSTEM 339
Male Organs 339
The Testis 339
The Seminal Ducts 345
The Epididymis 346
The Vas Deferens 346
The Seminal Vesicles and Ejaculatory Ducts 348

PAGE
Rudimentary Structures Connected with the Development of the Genital System . . . 348
The Spermatozoa . . . 349
Development of the Spermatozoa . . . 350
Technic . . . 352
The Prostate Gland . . . 353
Cowper's Glands . . . 355
Technic . . . 355
The Penis . . . 355
The Urethra . . . 357
Technic . . . 358
Female Organs . . . 358
The Ovary . . . 358
The Graafian Follicle . . . 360
Oogenesis . . . 363
The Corpus Luteum . . . 364a
Rudimentary organs connected with the Ovary . . . 369
The Oviduct . . . 370
Technic . . . 371
The Uterus . . . 372
The Mucosa of the Resting Uterus . . . 373
The Mucosa of the Menstruating Uterus . . . 375
The Mucosa of the Pregnant Uterus . . . 376a
The Placenta . . . 377
The Vagina . . . 381
Development of the Urinary and Reproductive Systems . . . 382
Technic . . . 385
General References . . . 385

CHAPTER XX

THE SKIN AND ITS APPENDAGES . . . 386
The Skin . . . 386
Technic . . . 390
The Nails . . . 391
Technic . . . 393
The Hair . . . 393
Technic . . . 399
Blood-vessels of Skin . . . 399
Technic . . . 400
Development of Skin, Nails, and Hair . . . 401
The Mammary Gland . . . 402
Technic . . . 407
General References . . . 407

CHAPTER XXI

THE THYREOID AND PARATHYREOID, THE HYPOPHYSIS CEREBRI, THE EPIPHYSIS CEREBRI, THE PARAGANGLIA AND THE ADRENAL.
The Thyreoid . . . 408
Development . . . 409

PAGE
The Parathyreoids 410
Technic 412
The Hypophysis Cerebri (Pituitary Body) 413
Epiphysis Cerebri (Pineal Body) 415c
Paraganglia 415d
Carotid Glands 416
Coccygeal Gland 417
Adrenal Gland 418
General References 421

CHAPTER XXII

THE NERVOUS SYSTEM.
General Structure and Histological Development 422
Membranes of the Brain and Cord 432
The Peripheral Nervous System 435
General Structure of the Peripheral Nerves 435
The Afferent Peripheral Neurones and Receptors 437
The Cerebro-spinal Ganglia 437
The Receptors 441
The Sympathetic Nervous System 448
The Efferent Peripheral Cerebrospinal Somatic Neurones 456
The Central Nervous System 457
The Spinal Cord 457
Origin of the Fibres which Make Up the White Matter of the Cord . 458
(1) The Spinal Ganglion Cells and the Origin of the Dorsal White Columns 458
(2) Cells Situated in Other Parts of the Central Nervous System which Contribute Axones to the White Matter of the Cord . . 459
(3) Root Cells 459
(4) Column Cells of the Cord 460
(5) Golgi's II Type Cells 461
Technic 461
Practical Study 462
Transverse Section of Six-day Chick Embryo 462
Longitudinal Section of Six-day Chick Embryo 463
General Topography of Cord, General Structures of Gray and White Matter, Cell Groups and Arrangement of Fibres 463
Practical Study of Sections through Lumbar Enlargement 463
General Topography 463
General Structure of Gray and White Matter 466
Cell Groups 470
Arrangement of Fibres 474
Blood Vessels 477
Variations in Structure at Different Levels 478
Practical Study 479
Section through the Twelfth Thoracic Segment 479
Section through the Mid-thoracic Region 479
Section through the Cervical Enlargement 479
Fibre Tracts of the Cord 479
Long Ascending Tracts 485
I. Long Ascending Arms of Dorsal Root Fibres 485

PAGE

II. The Lateral Spino-thalamic Tract 488
III. The Dorsal Spino-cerebellar Tract 490
IV. The Ventral Spino-cerebellar Tract 491
Long Descending Tracts 492
I. The Pyramidal Tracts 492
II. The Collicula Spinal Tracts 494
III. The Tracts from the Interstitial Nucleus 494
IV. The Rubro-spinal Tract 494
V. The Vestibulo-spinal Tracts 495
VI. The Fasciculus of Thomas 496
VII. Helweg's Tract 496
VIII. The Septo-marginal Tract 496
IX. The "Comma Tract" of Schultze 496
Short Ascending and Descending Tracts 497
(Shorter Intersegmental or Spino-spinal Tracts, Fundamental Columns or Ground Bundles) 497
Examples of Neural Arcs Involving the Spinal Cord 498
Technic 501
The Brain 503
General Structure 503
Segmental Brain and Nerves 504
Afferent Peripheral (Segmental) Neurones 504
General Somatic Group 504
Splanchnic Group 505
Vestibulo-semicircular Canal Group 505
Acoustic Group 505
Visual Group 505
Olfactory Group 505
Efferent Peripheral (Segmental) Neurones 506
Somatic 506
Splanchnic 506
Intrasegmental and Intersegmental Neurones 506
Afferent and Efferent Suprasegmental Paths 506
Afferent Suprasegmental Paths 507
Afferent Pallial Paths 507
Afferent Mesencephalia Paths 511
Afferent Cerebellar Paths 511
Efferent Suprasegmental Paths 512
Efferent Pallial Paths 512
Efferent Mesencephalic Paths 516
Efferent Cerebellar Paths 516
Suprasegmental Structures 519
Résumé 521
Hindbrain or Rhombencephalon 522
General Character 522
Technic 526
Practical Study.
1. Transverse Section of the Medulla through the Decussation of the Pyramidal Tracts 527
2. Transverse Section of the Medulla through the Decussation of the Fillet 531

PAGE

3. Transverse Section of the Medulla through the Lower Middle Part of the Inferior Olivary Nucleus 533
4. Transverse Section of the Medulla through the Middle of the Olivary Nucleus 542
5. Transverse Section of the Medulla through the Entrance of the Cochlear Root of Nerve VIII 542
6. Transverse Section of the Hindbrain at the Level of the Junction of Pons and Cerebellum and Entrance of (Vestibular) Neck 552
7. Transverse Section of the Hindbrain through Roots of Nerves VI and VII 559
8. Transverse Section of the Hindbrain through the Roots of Nerve V 562

Cerebellum 566
Isthmus 574
Practical Study 574
9. Transverse Section of the Isthmus at the Exit of Nerve IV 574
Midbrain or Mesencephalon 577
Practical Study 577
10. Transverse Section of Midbrain at Level of Inferior Colliculi 577
11. Transverse Section of Midbrain at Level of Superior Colliculi and Exit of Nerve III 581
Forebrain or Prosencephalon 586
The Interbrain or Diencephalon 586
Practical Study 592
12. Transverse Section of Midbrain and Thalamus at Their Junction 592
13. Transverse Section of Interbrain at the Level of the Optic Chiasma 594
The Endbrain or Telencephalon 600
The Rhinencephalon 601
The Corpus Striatum 601
Practical Study 603
14. Transverse Section of Thalamus and Corpora Striata through the Anterior Commissura 603
The Pallium 605
Practical Study 609
15. Transverse Section through the Central Hemispheres, Corpora Striata and Thalamus 609
The Cerebral Cortex 609
General Methods Used in the Investigation of the Architecture of the Nervous System 621
Special Technic 623
Table of Cranial and Spinal Nerves 624
General References for Further Study 626

CHAPTER XXIII

THE ORGANS OF SPECIAL SENSE 627
The Organ of Vision 627

PAGE

The Eyeball . . . 627
The Sclera . . . 627
The Cornea . . . 627
The Chorioid . . . 629
The Ciliary Body . . . 631
The Iris . . . 633
The Retina . . . 634
The Optic Nerve . . . 638
The Relations of Optic Nerve to Retina and Brain . . . 639
The Lens . . . 643
The Lacrymal Apparatus . . . 646
The Eyelid . . . 646
Development of the Eye . . . 648
Technic . . . 649
The Organ of Hearing . . . 651
The External Ear . . . 651
The Middle Ear . . . 652
The Internal Ear . . . 653
The Vestibule and Semicircular Canals . . . 654
The Saccule and Utricle . . . 654
The Semicircular Canals . . . 655
The Cochlea . . . 655
Development of the Ear . . . 662
Technic . . . 663
The Organ of Smell . . . 663
Technic . . . 665
The Organ of Taste . . . 666
Technic . . . 666
General References . . . 667

INDEX . . . 669

PART I

HISTOLOGICAL TECHNIC

CHAPTER I

GENERAL TECHNIC

CERTAIN body fluids, such as blood and urine, may be examined by simply placing them on a slide under a cover-glass. A few tissues, for example, thin membranes, such as the omentum and the mesentery, may be examined in the fresh or living condition by immersing them in some such inert medium as blood serum or normal salt solution (a 0.75-per-cent. solution of sodium chlorid in distilled water). For such examination the tissue is immersed in the salt solution on a slide and covered with a cover-glass. Most tissues and organs, however, require much more elaborate preparation to render them suitable for microscopic examination. Tissues too dense and thick to be readily seen through with the microscope must be so treated as to make them transparent. This is accomplished either by pulling the tissue apart into fine shreds, *teasing*, or by cutting it into thin slices, *section cutting*. Some tissues admit of teasing in a fresh condition; others can be satisfactorily teased only after they have been subjected to the action of a chemical which breaks down the substance holding the tissue elements together, *maceration*. Fresh tissue can rarely be cut into sections sufficiently thin for microscopic examination. It must first be treated in such a manner as to preserve as nearly as possible the living tissue relations, *fixation*. If too soft for section cutting it must next be put through a process known as *hardening*. If, however, as in the case of bone, the tissue is too hard, it must be softened by dissolving out the mineral salts, *decalcification*. If very thin sections are to be cut, it is further necessary to impregnate the tissue with some fluid substance which will harden in the tissue and give to the mass a firm, even consistency. This is known as *embedding*.

Furthermore, most tissue elements have so nearly the same color, and possess refractive indices so similar, that their differentiation under the microscope is often extremely difficult. To overcome this difficulty, recourse is had to staining the tissue with dyes which have an affinity for certain only of the tissue elements, or which stain

different elements with different degrees of intensity. This is known as *differential* or *selective staining*.

The final step in the process is the *mounting* of the specimen, after which it is ready for microscopic study.

In this chapter only the more common procedures used in the preparation of tissues for microscopic study are described. At the end of each section are given the technical methods most satisfactory for the demonstration of the tissues described in that section. For other methods the student is referred to special works upon microscopic technic.

Dissociation of Tissue Elements

Certain of the structural features of such tissues as nerves, muscle, and epithelium, which have but little intercellular substance, or of the looser forms of connective tissue, may be well demonstrated by dissociation.

This is accomplished by (1) teasing, or (2) maceration, or both.

(1) TEASING.—This consists in pulling apart fresh or preserved tissues by means of teasing needles. Instructive specimens of such tissues as muscle and nerve may be obtained in this way. In fact it is feasible to study many tissues in the same manner if tiny pieces are picked into fine shreds on the slide. This method possesses the advantage of exhibiting the tissues in their natural or living condition, whereas most of the methods subsequently described, although having distinct advantages of their own, exhibit the tissues after they are killed and artificially colored. During the past few years extensive and important observations have been made on cells and tissues while living and actually growing.

(2) MACERATION.—This is the subjecting of a tissue to the action of some chemical which breaks down the substance uniting the tissue elements, thus allowing them either to fall apart or to be more easily dissociated by teasing. The most commonly used macerating fluids are:

(*a*) *Ranvier's Alcohol* (33-per-cent., made by adding 35 c.c. of 96-per-cent. alcohol to 65 c.c. of water).—Bits of fresh tissue are placed in this fluid for from twenty-four to forty-eight hours. The cells may then be easily separated by shaking or by teasing. Ranvier's alcohol is an especially satisfactory macerating fluid for epithelia.

(*b*) *Formaldehyde*, in very dilute solutions (0.2- to 0.4-per-cent. commercial formalin[1]).—Tissues should remain in the formaldehyde solution from twenty-four to forty-eight hours. This is also especially useful for dissociating epithelial cells.

(*c*) *Sodium or Potassium Hydrate* (30- to 35-per-cent. aqueous solution).—From twenty minutes to an hour is usually sufficient to cause the tissue elements to fall apart or to be readily pulled apart with teasing needles. If it is at any time desirable to stop the action of the caustic alkali, this may be accomplished by neutralizing with glacial acetic acid or by replacing the alkali with a 60-per-cent. aqueous solution of potassium acetate. The specimens may then be preserved in the potassium-acetate solution, in glycerin, or in 50-per-cent. alcohol. This dissociating fluid is largely used for muscle cells and fibres.

(*d*) *Nitric acid* (10- to 20-per-cent. aqueous solution).—This is especially useful for dissociating involuntary and voluntary muscle.

After any of the above procedures, the macerating fluid containing the tissue elements should be placed in a long tube, allowed to stand for a time and the fluid decanted. Water is then poured into the tube, the tissues allowed to settle and the water poured off, this being repeated until all trace of macerating fluid is removed. This washing is facilitated by using the centrifuge. The tissue elements may then be preserved or mounted in glycerin or in glycerin jelly. It is frequently advisable to stain the tissues. For this purpose alum-carmin (p. 22), and picro-carmine (p. 24), are especially satisfactory. (For details see technic 1, p. 129 and technic 2, p. 129.) After staining and washing, the tissues may be preserved or mounted in glycerin, eosin-glycerin, or glycerin jelly. It frequently happens that on examining dissociated tissue elements after mounting, the bits of tissue are still too large. This may be remedied by gently tapping on the cover-glass with a lead pencil.

PREPARATION OF SECTIONS

I. Fixation

Even tissues, the structure of which admits of their being examined in the fresh condition, as described on p. 3, soon undergo post-mortem changes if placed in an inert medium such as normal

[1] Commercial formalin is a 40-per-cent. solution of formaldehyde gas in water.

salt solution or blood serum. As a result they soon lose their characteristic appearance and disintegrate. A proper killing or *fixation* is therefore the first step in the preparation of most tissues for microscopic study, the object being to so preserve the tissues that they retain as nearly as possible, and more or less permanently, the same structure and relation which they had during life. Fresh tissues are therefore essential for satisfactory results, as soon after death changes set in which destroy the structure and relations of the tissue elements. Tissues should also be handled as little as possible. Fixed tissue may be placed in water, salt solution, alcohol, etc., in fact may be subjected to many and varied manipulations which would destroy fresh tissues, without disturbing the relation of the tissue elements. Fixation of such a thin film of tissue as a blood smear may be accomplished by heating. A blood smear or even small pieces of tissue may be fixed by exposure to certain chemical vapors as, *e.g.*, the vapor of formalin or of osmic acid. Fixation is, however, usually accomplished by means of chemicals in solution, the solution being known as a fixing agent or *fixative*. The tissue is immersed in the fixative and allowed to remain there until fixation is complete. The pieces of tissue should be small enough to permit rapid and thorough penetration, and large quantities of the fixative should be used; at least ten times the bulk of the tissue to be fixed. It may be necessary to change the fluid a number of times, in order to keep it up to the proper strength. The length of time required depends upon the character of the tissue and upon the fixative used. In general it should be only long enough to bring about the desired result, as prolonged immersion in the fixative may make the tissue brittle or may interfere with the subsequent treatment of the tissue, especially staining.

Organs and even bodies may be fixed *in toto* by injecting the fixative through an artery and allowing it to escape through the veins. After the injection, the whole specimen should be placed in a large quantity of the same fixative. This method fills the entire vascular system including the capillaries with the fixative, thus bringing the latter into very prompt and close contact with the tissue elements. The result is a very rapid and accurate fixation, which is especially valuable where it is necessary to preserve the topographic relations of various parts of an organ or of an entire body.

The following are the fixatives in most common use:

(1) *Absolute Alcohol.*—This is a rapid fixative and should be used on small pieces of tissue. The time required is from six to

twenty-four hours, though tissues may remain longer without injury. The alcohol should be changed after two or three hours. This fixative should not be used where fine histological detail is desired, since it causes some shrinkage. One advantage in its use is the fact that tissues are hardened and ready for embedding at the end of fixation.

(2) *Dilute Alcohol* (30-per-cent. to 80-per-cent.).—This, as a rule, gives unsatisfactory results, causing much shrinkage of the tissue elements.

(3) *Formalin* (2-per-cent. to 10-per-cent. aqueous solution).—Formalin is rapid in its action and probably has better penetrating qualities than any other fixative. For general purposes a 10-per-cent. solution (1 part commercial formalin to 9 parts water) should be used. This fixes in from six to twenty-four hours. The results after formalin are not always good, owing to the fact that it has little hardening power, and the subsequent action of alcohol is likely to cause some distortion of the tissues. It acts better when combined with other fixatives than when used alone. (See Orth's fluid.)

(4) *Formalin-alcohol* (Schaffer).

Formalin,	30 c.c.
Alcohol, 96-per-cent.,	60 c.c.

Tissues remain in this fixative about forty-eight hours and are then placed in 96-per-cent. alcohol for a like period.

(5) *Müller's Fluid.*

Potassium bichromate,	2.5 gm.
Sodium sulphate,	1.0 gm.
Water,	100.0 c.c.

This fluid gives very good results, but is extremely slow in its action, requiring from a week to several months. Fairly large pieces of tissue may be fixed, but in all cases large quantities of the fixative should be used and frequently renewed.

(6) *Orth's Fluid.*

Müller's fluid (double strength), Formalin, 8-per-cent.,	Equal parts.

This is one of the best general fixatives. Its action is similar to that of Müller's fluid but much more rapid, fixation being accomplished in from twenty-four to forty-eight hours, though specimens may remain in the fluid several days without disadvantage. Fairly large pieces of tissue may be fixed with good results. The fixative

should be changed after a few hours. Fixation with Orth's fluid gives an excellent basis for a hæmatoxylin-eosin stain (see (1), p. 23). The fixative should always be freshly prepared. It is convenient to keep the 8-per-cent. formalin solution and the double-strength Müller's fluid in stock. Orth's fluid is then prepared by simply taking equal parts of each.

(7) *Osmic Acid.*—This, in a 1-per-cent. aqueous solution, is a quick and excellent fixative of poor penetrating power. Very small pieces of tissue must therefore be used. They should remain in the fluid from twelve to twenty-four hours. Osmic acid stains fat and myelin black and is consequently useful in demonstrating their presence in tissues. Fixation should take place in the dark.

(8) *Flemming's Fluid.*

Chromic acid, 1-per-cent. aqueous solution,	25 c.c.
Osmic acid, 1-per-cent. aqueous solution,	10 c.c.
Glacial acetic acid, 1-per-cent. aqueous solution,	10 c.c.
Water,	55 c.c.

Flemming's fluid is one of the best fixatives for nuclear structures, and is of especial value in demonstrating mitotic figures. Very small pieces of tissue should be placed in the fixative, where they remain for from twenty-four hours to three days. The solution should be freshly made as required, or a stock solution without the osmic acid may be kept, and the latter added at the time of using.

(9) *Mercuric Chlorid.*—This may be used either in saturated aqueous solution or in saturated solution in 0.75-per-cent. salt solution. Fixation is complete in from twelve to twenty-four hours, and is usually very satisfactory.

A saturated solution of mercuric chlorid in 5-per-cent. aqueous solution of glacial acetic acid also gives good results.

(10) *Zenker's Fluid.*

Potassium bichromate,	2.5 gm.
Sodium sulphate,	1.0 gm.
Mercuric chlorid,	5.0 gm.
Glacial acetic acid,	5.0 c.c.
Water,	100.0 c.c.

This fluid should be freshly made, or the salts may be kept in solution and the acetic acid added at time of using.

Zenker's fluid is a good general fixative, but usually causes some shrinkage of the tissue elements. Fixation requires from six to twenty-four hours. The most serious drawback to Zenker's fluid

is the fact that the mercuric chlorid sometimes produces dark, irregular precipitates in the tissues. This may be remedied by the use of iodine and iodid of potassium in the hardening process (see under Hardening, p. 13).

(11) *Picric acid* is an excellent fixative for cytoplasm and embryonic tissues. It is also a weak decalcifying agent and may be used as such for embryonic or partially calcified bone. It may be used in: (*a*) Saturated aqueous solution; (*b*) saturated solution of picric acid in 1-per-cent. aqueous solution of acetic acid; (*c*) saturated solution of picric acid in 2-per-cent. aqueous solution of sulphuric acid. Further treatment should be with alcohol without previous washing in water.

(12) Van Gehuchten's Fluid.

Absolute alcohol	60 c.c.
Chloroform	30 c.c.
Glacial acetic acid	10 c.c.

This is an excellent fixative for lung tissue. The pieces should be small and should remain in the fluid 3 to 12 hours. The addition of 20 grams mercuric chlorid gives especially good results in cytological work. An hour's fixation is sufficient.

II. Decalcifying

Tissues containing lime salts, like bones and teeth, must have the lime salts dissolved out before sections can be cut. This process is known as *decalcification.*

Tissues to be decalcified must be first fixed and hardened. Fixation in Orth's fluid and hardening in graded alcohols give good results. After hardening, the tissue is washed in water and placed in one of the following decalcifying fluids. The quantity of fluid should always be large and the fluid frequently changed. The completion of decalcification can be determined by passing a needle through the specimen or by cutting it with a scalpel. The time required varies with the size and hardness of the specimen and the decalcifying fluid used. When decalcification is complete, the specimen is washed in sufficient changes of water to remove all trace of acid. This may be quickly accomplished by the addition of a little ammonium hydrate to the water. The specimen is then carried through graded alcohols.

(1) *Hydrochloric Acid.*—This may be used in aqueous solutions of from 0.5-per-cent. to 5-per-cent. A very satisfactory decalcifying mixture is that known as Ebner's hydrochloric-salt solution. It consists of:

Sodium chlorid, saturated aqueous solution,	1 part.
Water,	2 parts.
Hydrochloric acid, sufficient to make a from 2-per-cent. to 5-per-cent. solution.	

The addition of the salt prevents swelling of the tissue. This fluid is slow in acting and should be changed every day.

(2) *Nitric Acid.*—This is less used than the preceding. The strength should be from 1-per-cent to 10-per-cent. aqueous solution. Weak solutions (1-per-cent. to 2-per-cent.) will decalcify small fœtal bones in from three to twelve days. For larger bones stronger solutions and longer time are required. Transferring from the nitric solution to a 5-per-cent. alum solution for twenty-four hours before washing will prevent swelling of the tissue. Phloroglucin is sometimes added to the nitric acid solution for the purpose of protecting delicate tissues or of allowing stronger solutions of the acid to be used. One gram of phloroglucin is dissolved in 10 c.c. of nitric acid. To this are added 100 c.c. of 10-per-cent. aqueous solution of nitric acid. Small pieces of tissue decalcify in a few hours. If less rapid action is desired, reduce the amount of nitric acid without changing the percentage of phloroglucin.

(3) Small bones may be satisfactorily decalcified in *Zenker's fluid* (see Fixatives, page 8), or in the following:

Picric acid,	1 part.
Chromic acid,	1 part.
Glacial acetic acid,	5 parts.

III. Injection

For the study of the distribution of the blood-vessels in tissues and organs, it is often necessary to make use of sections in which the blood-vessels have been injected with some transparent coloring matter. The injecting fluid most commonly used is a solution colored gelatin.

The gelatin solution is prepared by soaking 1 part gelatin in from 5 to 10 parts water—the proportion depending upon the consistence desired—and when soft, melting on a water-bath.

Various dyes are used for coloring the gelatin, the most common being Prussian blue and carmine.

PRUSSIAN BLUE GELATIN is prepared by adding saturated aqueous solution Prussian blue to the gelatin solution, the proportions depending upon the depth of color desired. Both solutions should be at a temperature of 60° C. After thoroughly mixing, the blue gelatin is filtered through cloth.

CARMINE GELATIN is prepared by first dissolving 1 gm. carmine in 30 c.c. distilled water. To this is added ammonia until the mixture becomes a dark cherry red. A 10-per-cent. aqueous solution of acetic acid is next added, drop by drop, with constant stirring until the mixture becomes neutral. The carmine and gelatin solutions both being at about 60° C., are now mixed in the desired proportions. If the carmine injection mass is alkaline, it diffuses through the walls of the vessels; if acid, there is a precipitation of the carmine which may interfere with its free passage through the capillaries. If, however, the alkaline carmine and gelatin be first mixed, and the 10-per-cent. acetic acid solution be then added as directed above, the precipitated granules are so fine, even with an acid reaction, that they readily pass through the capillaries. The precipitation of the carmine in the shape of coarser granules is of advantage when it is desired to have an injection mass which will fill the arteries or veins only, without passing over into the capillaries.

The *injecting apparatus* consists of a vessel which contains the injection mass, and some means of keeping the latter under a constant but easily varied pressure. With the vessel is connected a tube ending in a cannula, through which the injection is made.

A very simple apparatus consists of a shelf which can be raised and lowered, and upon which the vessel stands. The tube connecting with the cannula may be attached to a faucet in the vessel or to a bent glass tube which passes into the top of the vessel and acts on the principle of a siphon.

In a somewhat more elaborate apparatus the injection mass is placed in a closed vessel, and this is connected with a second vessel containing air compressed by means of an air pump.

Accurate regulation of the pressure may be obtained by connecting the injection vessel with a manometer.

If the injection is to occupy considerable time, a hot-water bath in which the gelatin may be kept at an even temperature is also necessary.

Whole animals or *separate organs* may be injected. For injecting a whole animal, the animal, which is usually a small one such as a guinea-pig, rat, mouse, or frog, is chloroformed, the tip of the heart is cut away and a cannula is inserted through the heart into the aorta. This is first connected with a tube leading to a bottle containing warm normal saline solution. Pressure is obtained in the same manner as above described for the injection mass. By this means the entire arterial and venous systems are thoroughly washed out until the return flow from the vena cava is perfectly clear. The cannula is next connected with the tube from the vessel containing the injection mass, the pressure being only sufficient to keep the liquid flowing. When the injection mass flows easily and freely from the vena cava, the vessel is tied and the pressure is increased slightly and continued until the color of the injection mass shows clearly in the superficial capillaries. The aorta is now tied and the animal immersed in cold water to solidify the gelatin. After the gelatin becomes hard, the desired organs are removed and fixed and hardened in the usual way. Sections of injected material are usually cut rather thick, that the vessels may be traced the greater distance.

Better results are frequently obtained by injecting separate organs. This is accomplished by injecting through the main artery of the organ (*e.g.*, the lungs through the pulmonary, the kidney through the renal). The injection is best done with the organ *in situ*, although it may be accomplished after the organ has been removed. The method is the same as given above for injecting an animal *in toto*.

The so-called *double injection* by means of which an attempt is made to fill the arteries with an injection mass of one color (red), while the veins are filled with an injection mass of another color (blue), often gives pretty, but usually inaccurate pictures, it being, as a rule, impossible to confine each injection mass to one system. Double injection is accomplished by first washing out the vessels with normal saline and then connecting the artery with the red gelatin, the vein with the blue gelatin, and injecting both at the same time, the pressure driving the saline out of the vessels into the tissues. The difficulty is that either the arterial injection carries over into the veins, or the venous injection carries over into the arteries. A somewhat more accurate method is first to inject the veins with an injection mass in which the coloring matter is in the form of granules too large to pass through the capillaries, and then to inject the arteries and capillaries in the usual manner. This method is especially

useful in demonstrating the vessels of the kidney, liver, and gastro-intestinal canal.

IV. Hardening

Most fixatives are also hardening agents if their action is prolonged. This is, however, often detrimental. It is, therefore, customary, after fixation is complete, to carry the specimens, with or without washing, through successively stronger grades of alcohol for the purpose of hardening the tissues. For general histological purposes the specimens may be transferred directly to 70-per-cent. or 80-per-cent. alcohol, which should be changed once or twice. In the case of delicate tissues the first grade of alcohol should be 40-per-cent. or 50-per-cent., the second 70-per-cent., and the third 80-per-cent. The specimens should remain in each grade from twelve to twenty-four hours.

Washing the tissues after fixation is not a matter of indifference. In some cases water should be used, while in other cases water is liable to undo the action of the fixative, in which cases alcohol must be used for washing.

After fixation in alcohol no washing, of course, is necessary. Specimens fixed in strong alcohol are embedded immediately (see Embedding, page 14), or preserved (see Preserving, page 14). After fixation in dilute alcohol the specimens are passed through the graded alcohols up to 80-per-cent.

After fixation in formalin, specimens are placed directly in 96-per-cent. alcohol without washing in water. Specimens fixed in any solution containing picric acid should not be washed in water, but passed directly through the alcohols; and it is usually necessary to change each grade in order to wash out the picric acid.

Specimens fixed in osmic acid or any solution containing osmic acid should be washed in running water before being passed through the graded alcohols. After solutions containing potassium bichromate the specimens should be washed in water sufficiently to remove the excess of bichromate, though too prolonged washing seems to be detrimental. A precipitate forms in the alcohols, but this apparently does no harm.

After mercuric chlorid or Zenker fixation the washing may be done either in water or in alcohol. To avoid precipitates in the tissues add a small quantity of an iodin solution (equal parts tincture iodin and 10-per-cent. aqueous solution potassium iodid) to any of

the grades of alcohol. As the alcohol becomes clear more of the solution is added until the alcohol remains slightly tinged.

V. Preserving

Hardened tissues are usually preserved in 80-per-cent. alcohol. Formalin in aqueous solutions of 1-per-cent. to 10-per-cent. is also used as a preservative. In either case, when it is necessary to preserve the specimens for a considerable length of time (several months or longer), the tissues are likely to lose their staining qualities to a certain extent. Preserving the specimens in equal parts of strong alcohol, glycerin, and distilled water is successful as a partial remedy for this.

VI. Embedding

Most hardened tissues are still not firm enough to be cut into the thin sections suitable for microscopic study. In order to support the tissue elements and render them more firm for section cutting, recourse is had to embedding. This consists in impregnating the tissues with some substance which is liquid when the tissues are placed in it, but which can be made to solidify throughout the tissues. In this way the tissue elements are held firmly in place. The embedding substances most used are celloidin and paraffin.

Celloidin Embedding

(1) Alcohol-ether Celloidin.—Two solutions should be made.

Solution No. 2. Thick celloidin—a 5-per-cent. solution of celloidin in equal parts 96-per-cent. alcohol and ether.

Solution No. 1. Thin celloidin—made by diluting solution No. 2 with an equal volume of equal parts of alcohol and ether.

The hardened tissues are placed successively in:

Strong alcohol (96-per-cent.) twelve to twenty-four hours, to dehydrate.

Equal parts alcohol and ether, twelve to twenty-four hours.

Thin celloidin, twenty-four hours to several days.

Thick celloidin, twenty-four hours or longer.

The exact time tissues should remain in the different grades of celloidin depends upon the character of the tissue, the size of the specimen, and the thinness of section desired. Many tissues may be advantageously left for weeks in thin celloidin.

The specimen must now be "blocked" and the celloidin hardened. By blocking is meant fastening the specimen impregnated with celloidin to a block of wood or other suitable material which may be clamped in the microtome (see Section Cutting, page 17). The specimen may be taken from the thick celloidin (considerable of the latter adhering to the specimen), quickly pressed upon a block of wood or vulcanized fibre, allowed to harden five to ten minutes in air, and then immersed in 80-per-cent. alcohol. The alcohol gives an even hardening of the celloidin, attaching the specimen firmly to the block. Another method, and one by which very even-shaped blocks may be obtained, is to place the specimen from the thick celloidin into a little paper box (made by folding paper over a wooden block), slightly larger than the specimen, and covering with thick celloidin. The celloidin should dry slowly under a bell-jar for from two to twelve hours, according to the amount of celloidin, after which it should be immersed in 80-per-cent. alcohol and the paper pulled off. Such a block may be cut into any desired shape. It is attached to the wooden or vulcanized block by dipping for a moment in thick celloidin, and then pressing firmly down upon the block. After five to ten minutes' drying in air it is transferred to 80-per-cent. alcohol.

Old, hard, celloidin-embedded specimens are sometimes difficult to attach to blocks. This usually may be accomplished by first thoroughly drying the specimen and then dipping it in equal parts alcohol and ether for a few minutes. This softens the surface of the celloidin, after which the specimen is dipped in thick celloidin and blocked. Embedded or blocked specimens can be kept in 80-per-cent. alcohol. After several months, however, the celloidin is likely to become too soft for good section cutting. In that case the specimens can be readily re-embedded by dissolving out the old celloidin with alcohol and ether and putting them again through the regular embedding process. If blocked specimens are kept in equal parts alcohol and glycerin, the celloidin will retain its toughness for months or even years.

(2) Clove-oil Celloidin.—A more rapid impregnation of the tissue may be obtained by means of what is known as clove-oil celloidin.

Celloidin,	30 gm.
Clove oil,	100 c.c.
Ether,	400 c.c.
Alcohol, absolute,	20 c.c.

The celloidin is first placed in a jar and the clove oil and ether added. From two to four days are required for solution of the celloidin. During this time the jar should be shaken several times. After the celloidin is dissolved the absolute alcohol is added and the solution is ready for use.

The specimen must be thoroughly dehydrated, placed in alcohol and ether or pure ether for a few hours, and then transferred to the clove-oil celloidin. From six to twelve hours is sufficient to impregnate small pieces of tissue. The tissue is now taken from the celloidin, placed directly upon a wooden or vulcanized block, and immersed in chloroform. The celloidin hardens in about an hour, and is then ready for sectioning. The specimen is very firm, and very thin sections can be cut.

A disadvantage in clove-oil celloidin is that neither the blocks nor the sections can be kept permanently in alcohol, as can those embedded in alcohol-ether celloidin. They may, however, be kept for several weeks in pure chloroform.

Paraffin Embedding

For paraffin embedding a thermostat or paraffin oven is necessary in order that a constant temperature may be maintained. The temperature should be about 56° C. Pure paraffin, the melting-point of which is from 50° to 55° C., is used. In very warm weather it may be necessary to add to this a little paraffin, the melting-point of which is 62° C.

The hardened tissue is first put in 96-per-cent. alcohol for from twelve to twenty-four hours, and then completely dehydrated by putting in absolute alcohol for the same length of time, or less for small specimens. It is then transferred to some solvent of paraffin. Some of the solvents used are xylol, oil of cedarwood, chloroform, and toluol. Of these the best are perhaps xylol and oil of cedarwood. The tissue should remain in either of these for several hours, or until the tissue becomes more or less transparent. It is then placed in melted paraffin, in the paraffin oven, for from one to three hours, according to the size and density of the specimen. This allows the tissues to become impregnated with the melted paraffin. The paraffin should be changed twice.

In case of very delicate tissues it is well to transfer them from the absolute alcohol to a mixture of equal parts absolute alcohol and xylol for a short time before putting them into the pure xylol. In the

same way a mixture of equal parts xylol and paraffin may be used before putting the tissues into pure paraffin.

For hardening the paraffin in and around the tissue a very convenient apparatus consists of a plate of glass and several L-shaped pieces of iron or lead. Two of these are placed on the glass plate in such a manner as to enclose a space of the desired size. Into this are placed the specimen and sufficient melted paraffin to cover it. Both glass and irons should be smeared with glycerin to prevent the paraffin from adhering, and should be as cold as possible, so that the paraffin may harden quickly. The same paper boxes described under celloidin embedding may also be used for paraffin. Another good method for small pieces of tissue is to place the specimen in paraffin in an ordinary watch-glass which has been coated with glycerin. Both paper-box and watch-glass specimens are immersed in cold water as soon as the surface of the paraffin has become hard. After the paraffin has hardened any excess may be cut away with a knife.

Paraffin-embedded specimens may be kept indefinitely in air. For section cutting, the block of paraffin is attached to a block of wood or of vulcanite or to the metallic block-holder of the microtome. This is done by heating the block-holder, pressing the paraffin block firmly upon it, and then dipping the whole into cold water.

VII. Section Cutting

The older method of making free-hand sections with a razor has been almost completely superseded by the use of a cutting instrument known as the *microtome*. This consists essentially of a clamp for holding the specimen and a microtome knife or razor. The two are so arranged that when knife and specimen meet, a section of any desired thickness may be cut.

The technic of section cutting differs according to whether the specimen is embedded in celloidin or in paraffin.

In cutting celloidin sections the knife is so adjusted that it passes obliquely through the specimen, as much as possible of the cutting edge being used. The knife is kept flooded with 80-per-cent. alcohol and the specimens are removed by means of a camel's-hair brush to a dish of 80-per-cent. alcohol, where they may be kept for some time if desired. When celloidin sections tear or when very thin sections

are desired it is often of advantage to paint the surface of the block, after cutting each section, with a coat of very thin celloidin.

Celloidin sections are usually not thinner than 10μ, although under favorable conditions sections 5μ[1] or even 3μ in thickness may be obtained.

In cutting paraffin sections the knife is kept dry and is passed not obliquely but straight through the specimen, only a small part of the cutting edge being used. An exception is made in the case of very large paraffin sections, where an oblique knife is used. Sections are removed from the knife by a dry or slightly moistened brush. If not desired for immediate use the sections may be conveniently kept for a short time on a piece of smooth paper. If sections curl they may be flattened by floating on warm 30-per-cent. alcohol or on warm water.

Paraffin sections may be so cut that the edges of the sections adhere. Long series or "ribbons" of sections may thus be secured. This is of decided advantage when serial sections are desired. Failure of the sections to cut evenly or to adhere in ribbons is usually due to the paraffin being too hard and brittle, which of course is due to its low temperature. If much section cutting is to be done, the operator will find himself amply repaid by having the room-temperature fairly high. In case paraffin of a melting-point of 50° to 55° C. is used, a room temperature of 73° to 75° F. will greatly facilitate the work. Where it is not possible to have a high room temperature, recourse may be had to coating the surface of the block with a paraffin of lower melting-point than that used for the embedding. A similar effect may be obtained by holding a heated metal plate or bar near the block until the paraffin is slightly softened. This process may be repeated as often as necessary.

In addition to the fact that ribbon series can be cut in paraffin, this embedding substance also has the advantage over celloidin that thinner sections can be obtained. On the other hand, celloidin embedding produces less shrinkage of the tissues than paraffin embedding with the accompanying heat.

FROZEN SECTIONS.—This method, while more used in pathology where rapid diagnosis is more often important, is still sometimes extremely useful to the histologist, especially as an easy and quick method of testing material. Perfectly fresh tissues may be used or

[1] μ = micromillimeter or micron = $\frac{1}{1000}$ of a millimeter = microscopic unit of measure = about $\frac{1}{25000}$ of an inch.

tissues which have been previously fixed. Fixed tissues must have the fixative thoroughly removed before freezing. Of fixatives 10-per-cent. formalin is probably the best and the tissue should remain in the fixative from one to two hours. If time is important the tissue may be boiled for two or three minutes in the formalin solution.

Ether, rhigolene and carbon dioxid are the most common freezing agents. A special freezing microtome and knife may be used, or a freezing attachment may be used with the ordinary microtome. In ether freezing the ether is vaporized by means of compressed air and the vapor carried to the under side of a metallic plate upon which the block of tissue is placed. In carbon dioxid freezing, which has now largely superseded ether freezing on account of convenience and economy, the commercial cylinder of gas such as is used for charging soda fountains is used. As the liquid carbon dioxid and not the gas is required for freezing, the cylinder should be hung valve end down, with the valve about the level of the microtome. The carbon dioxid is carried to the metallic disc of the microtome by means of a stout rubber tube and it is advisable to screw a cap with a small hole in it over the valve and to attach a longer handle to the valve lever in order to more perfectly control the flow. The piece of tissue to be frozen should not be over 5 mm. thick and the freezing should be done slowly. A proper hardness of the tissue is important and is of course determined by the amount of carbon dioxid admitted.

As the frozen section is not supported by an embedding mass, special handling is required, the section being attached to a slide or cover-glass before staining. For this purpose either egg albumen or celloidin may be used.

Egg albumen,	50 c.c.
Distilled water,	150 c.c.
Saturated solution sodium salicylate (made slightly alkaline with lithium carbonate)	50 c.c.
(or sufficient to completely dissolve the albumen).	

Sections from material previously fixed are transferred directly from the microtome to the albumen solution. Sections from fresh material are placed for three to five minutes in 5- to 10-per-cent. formalin solution before being transferred to the albumen solution.

From the albumen solution sections are floated on a slide or cover-glass, the excess of solution drained off and the section firmly

blotted with several thicknesses of washed cheese-cloth. The slide or cover-glass is next immersed in alcohol or in equal parts alcohol and ether to coagulate the albumen, thus fixing the section to the glass. The section may now be stained and mounted in the usual way.

In the celloidin method the section is transferred from the microtome to water, floated upon a slide, blotted with filter paper, flooded with absolute alcohol and drained. Before the alcohol dries the slide is flooded with a very thin celloidin solution which is immediately drained off. The celloidin is then allowed to harden a moment and the slide immersed in water. The section is now fixed to the slide and may be stained and mounted as usual.

VIII. Staining

This is for the purpose of more readily distinguishing the different tissue elements from one another by their reactions to certain dyes.

Based upon their action upon the different tissue elements, stains may be classified as (1) nuclear dyes, which stain nuclear structures; and (2) plasma dyes, which stain the cell body or cytoplasm. Plasma dyes, also, as a rule, stain the intercellular tissue elements, and are therefore known as diffuse stains.

The dyes most frequently used for staining tissues are:

I. Nuclear dyes: (*a*) Hæmatoxylin and its active principle, hæmatein; (*b*) carmine and its active principle, carminic acid; (*c*) basic aniline dyes.

II. Plasma dyes: (*a*) Eosin; (*b*) neutral carmine; (*c*) picric acid; (*d*) acid aniline dyes.

I. Nuclear Dyes—(*a*) HÆMATOXYLIN.

1. *Gage's Hæmatoxylin.*

Ammonia or potash alum,	7.5 gm.
Distilled water,	200.0 c.c.

Boil for 10 minutes to sterilize; cool and add the following solution:

Hæmatoxylin crystals,	0.1 gm.
Alcohol 95-per-cent.,	10.0 c.c.

Four grams chloral hydrate are then added to the mixture to prevent growth of germs.

This dye may be used in full strength or diluted with alum water. It stains in from two to five minutes.

2. *Delafield's Hæmatoxylin.*

Hæmatoxylin crystals,	1 gm.
Alcohol,	6 c.c.
Ammonia alum, saturated aqueous solution,	100 c.c.

The hæmatoxylin should be first dissolved in the alcohol and then added to the alum solution. The mixture should next be allowed to stand in the light for from seven to ten days to ripen. It is then filtered, and to the filtrate are added:

Glycerin,	25 c.c.
Wood naphtha,	25 c.c.

The mixture is again allowed to stand for from two to four days and filtered. It may be used full strength or diluted with equal parts of water. It stains in from two to five minutes.

3. *Heidenhain's Hæmatoxylin.*

Hæmatoxylin crystals,	1 gm.
Water,	100 c.c.

Sections are first placed for from four to eight hours in a 2.5-per-cent. aqueous solution of ammonium sulphate of iron. They are then washed in water and transferred to the hæmatoxylin solution until they are intensely blue or black (usually several hours). The sections are now washed in water and differentiated by again placing in the iron solution till they have a light grayish color. After this they are thoroughly washed in water.

4. *Mayer's Hæmalum.*

Hæmatein,	1 gm.
Alcohol,	50 c.c.
Ammonia alum, 5-per-cent. aqueous solution,	1,000 c.c.

The hæmatein is first dissolved in the alcohol, after which the alum is added. This dye does not require any ripening, and is thus available for immediate use. It is a rapid nuclear dye usually requiring not more than from three to five minutes.

5. *A combination* of Gage's and Mayer's formulæ makes a very satisfactory nuclear dye.

Hæmatein,	5 gm.
Alcohol,	50 c.c.
Chloral hydrate,	20 gm.
Ammonia alum, 5-per-cent. aqueous solution (sterilized),	1,000 c.c.

The hæmatein is first dissolved in the alcohol and then added with the chloral hydrate to the alum solution. This solution is used in full strength and stains in from three to five minutes.

6. *Weigert's Hæmatoxylin.*

Two stock solutions should be made up as follows:

A. 1-per-cent. hæmatoxylin, in 96-per-cent. alcohol.	
B. Hydrochloric acid (sp. gr. 1.126),	10 c.c.
Ferric chloride, 30-per-cent.,	40 c.c.
Distilled water,	950 c.c.

For use, mix equal parts of A and B. The mixture will keep two or three days. This is a rapid stain usually requiring not more than a minute. A more brilliant nuclear stain may be obtained by overstaining and then decolorizing. After the stain wash the sections in water and then decolorize to the proper degree in weakly acidulated water. To stop the action of the acid the sections should be dipped in water made slightly alkaline with ammonia. This is an excellent stain and gives brilliant results. It is especially good in cases where the material has become old and lost its affinity for ordinary hæmatoxylin stains.

(*b*) ALUM-CARMINE.

Carmine,	2 gm.
Alum,	5 gm.
Carbolic acid,	2 gm.
Water,	100 c.c.

The alum is first dissolved in the 100 c.c. of warm distilled water, after which the carmine is added. This mixture is then boiled for twenty minutes, allowed to cool, and filtered. The carbolic acid is then added. This is a slow-acting pure nuclear dye.

(*c*) BASIC ANILINE DYES—gentian violet, methyl violet, methyl green, methyl blue, toluidin blue, fuchsin, thionin, safranin, etc.

These are best kept in stock in saturated alcoholic solutions. When desired to use, a few drops of the alcoholic solution are added to distilled water. No rule as to exact proportions can be given, as these depend upon the material, the fixation, and the intensity of stain desired.

II. Plasma Dyes.—(*a*) EOSIN.

This is prepared as follows: Water-soluble eosin is dissolved in water to saturation. It is then precipitated by hydrochloric acid and the precipitate washed with water upon a filter until the filtrate

is tinged with eosin. After drying, the precipitate is dissolved in strong alcohol, 1 gm. of eosin to 1,500 c.c. of alcohol, or water-soluble eosin may be kept in saturated aqueous solution containing a trace of thymol as a preservative. This may be diluted to any desired strength at time of using. Eosin is a rapid plasma stain.

(*b*) NEUTRAL CARMINE.

Carmine,	1 gm.
Liquor ammonii caustici,	5 c.c.
Distilled water,	50 c.c.

The last two ingredients are first mixed, and the carmine then added. This solution is allowed to remain in an open vessel for about three days, or until the odor of ammonia has disappeared, after which it is filtered.

(*c*) PICRIC ACID—used mainly as the plasma-staining element of such a staining mixture as picro-acid-fuchsin.

(*d*) ACID ANILINE DYES.—Of these, acid fuchsin, erythrosin, and orange G are most used. They may be prepared and kept in stock in the same manner as the basic aniline dyes (see above). Erythrosin is of especial value for sections which take the eosin stain poorly.

STAINING SECTIONS

It is usually advantageous to stain the different tissue elements different colors. This may be accomplished either by staining successively with several dyes, or by a single staining with a mixture of dyes. The following are the methods in most common use:

(1) STAINING DOUBLE WITH HÆMATOXYLIN AND EOSIN.—Sections are first washed in water. They are then stained with hæmatoxylin (solutions 1, 2, 4, 5, or 6, pp. 20–22) from one to five minutes. After being thoroughly washed in water, they are dehydrated in strong alcohol and transferred to the alcoholic eosin solution (page 22). Most sections stain in from two to five minutes. By this method nuclei are stained blue or purple, cell bodies and intercellular substances red.

Very often a more brilliant staining may be accomplished as follows: Overstain in hæmatoxylin and wash thoroughly in water; decolorize in water slightly acidulated (8 or 10 drops of hydrochloric acid to 100 c.c. of water) until only the nuclei retain the stain; wash in water which has been made slightly alkaline with ammonium hydrate; then stain with eosin as usual.

(2) STAINING WITH PICRIC-ACID-FUCHSIN (Van Gieson).

Acid-fuchsin, 1-per-cent. aqueous solution,	5 c.c.
Picric acid, saturated aqueous solution,	100 c.c.

This solution usually stains in from one to three minutes. Occasionally a longer staining is required. Cell bodies including muscle cells and fibres are stained yellow by the picric acid, connective-tissue fibres red by the fuchsin. After staining, the sections are washed in distilled water.

(3) TRIPLE STAINING WITH HÆMATOXYLIN AND PICRO-ACID-FUCHSIN.—This is the same as the preceding except that before staining with picro-acid-fuchsin, the sections are overstained in hæmatoxylin (solutions 1, 2, 4, 5, or 6, pp. 20–22). The usual purple of hæmatoxylin-stained nuclei is changed to brown by the action of the picric acid. Care should be taken that the sections do not remain too long in the picro-acid-fuchsin, or the hæmatoxylin may be completely removed. After staining, sections are washed in distilled water and transferred to 96-per-cent. alcohol.

If sections overstain with fuchsin, the staining solution may be diluted with water; if sections are understained with fuchsin, more fuchsin may be added. If the picric-acid stain is not sufficiently intense, the 96-per-cent. alcohol should be tinged with picric acid.

(4) STAINING WITH PICRO-CARMINE.

Ammonium carminate,	1 gm.
Distilled water,	35 c.c.
Picric acid, saturated aqueous solution,	15 c.c.

The ammonium carminate is first dissolved in the water, after which the saturated aqueous solution of picric acid is added with constant stirring. The mixture is then allowed to stand in an open vessel for two days, when it is filtered. This fluid stains nuclei and connective tissue red, cell protoplasm yellow.

STAINING IN BULK

By this is meant the staining of blocks of tissue before cutting into sections. The method is much less used than formerly. It is slower than section staining and more difficult to control. Blocks of the hardened tissue are transferred to the stain from water or alcohol according to the solvent of the stain. Alum-carmine and borax-carmine are the most used general bulk stains.

(1) ALUM-CARMINE.

Carmine,	0.5 to 1 gm.
Ammonia alum, 4-per-cent. aqueous solution,	100 c.c.

After mixing the ingredients, the solution should be boiled fifteen minutes, and after cooling, enough sterile water added to replace that lost by evaporation. The time required for staining depends upon the size of the specimen. There is, however, little danger of overstaining. After washing out the excess of stain with water the specimen is dehydrated and embedded in the usual way.

(2) BORAX-CARMINE, ALCOHOLIC SOLUTION.

Carmine,	3 gm.
Borax,	4 gm.
Water,	93 c.c.

After mixing the above, add 100 c.c. 70-per-cent alcohol, allow the mixture to settle, then filter.

About twenty-four hours is required to stain blocks 0.5 cm. in diameter. Larger blocks require longer staining.

IX. Mounting

It is usually desirable to make permanent preparations or "mounts" of the stained specimens.

The most satisfactory media for mounting specimens are glycerin and Canada balsam.

(1) GLYCERIN.—Sections may be transferred to glycerin from either water or alcohol. In the case of double-stained specimens—hæmatoxylin-eosin—the glycerin should be tinged with eosin, as the pure glycerin abstracts the eosin from the tissues. In many cases satisfactory eosin staining may be obtained by simply placing the hæmatoxylin-stained specimens in glycerin strongly tinged with eosin (eosin-glycerin). The specimen in a drop of glycerin is transferred to the glass mounting slide, the excess of glycerin removed with filter paper or with a pipette, and a cover-glass put on.

Glycerin mounts, as a general rule, are unsatisfactory. Furthermore, they must be cemented to exclude the air. This can be done by painting a ring of gold-size, or a thick solution of gum shellac in alcohol to which a little castor oil has been added, around and over the edge of the cover-glass. Both cover-glass and slide must be cleaned free from glycerin before the cement is applied. A camel's-hair brush moistened with alcohol is the best means of removing the excess of glycerin.

Glycerin jelly is a more satisfactory mounting medium than pure glycerin. It can be purchased from firms dealing in microscopical supplies and needs merely the application of heat to make it fluid. Specimens can then be mounted in it in the usual manner, and after being allowed to cool, do not require cementing.

(2) BALSAM.—This is the most satisfactory general mounting medium. It has an advantage over glycerin in drying down perfectly hard and thus needing no cement, and in preserving colors more permanently. Its disadvantage is that its refractive index is so high that it sometimes obscures the finer details of structure, especially of unstained or slightly stained specimens.

Specially prepared Canada balsam is dissolved either in xylol or in oil of cedar, the solution being made of any desired consistence. Xylol-balsam dries much more quickly than does the oil-of-cedar balsam.

Preparatory to mounting in balsam, stained sections must be thoroughly dehydrated and then passed through some medium which is miscible with both alcohol and balsam. This medium, which at the same time renders the section transparent, is known as a *clearing medium*. For *celloidin specimens* the most satisfactory are:

(1) Oil of origanum Cretici.

(2) Carbol-xylol (xylol, 100 c.c., carbolic-acid crystals, 22 gm.) followed by pure xylol.

(3) Xylol and cajeput oil, equal parts, followed by pure xylol.

After clearing, the section is transferred by means of a section-lifter to a glass mounting slide. In case oil of origanum is used, it is then blotted firmly with filter paper to remove the excess of oil. Care must be taken to have the filter paper several layers thick in order that the oil may be completely removed. The specimen should also be blotted firmly, giving the oil time to soak into the paper. These two precautions are necessary to prevent the section adhering to the paper instead of to the slide. After blotting, a drop of balsam is placed upon the centre of the specimen and a cover-glass put on.

When xylol is used, blotting is not necessary. Drain off the excess of oil, put a drop of balsam on the specimen and put on a cover-glass.

Paraffin Sections.—The technic of staining and mounting paraffin sections differs from that of celloidin sections. This is due mainly to the fact that while celloidin is transparent and may remain perma-

nently in the specimen, paraffin is opaque and must be dissolved out before the section is fit for microscopic study.

Bulk staining with carmine (page 25) is frequently used for specimens which are to be embedded in paraffin. Sections may be counterstained if desired.

The following are the steps to be followed in staining and mounting paraffin sections:

1. *To attach sections to slide:*

Place a drop of egg albumen (equal parts white of egg and glycerin to which a little carbolic acid may be added as a preservative) on a slide, and spread it out thin with the finger.

Place a few drops of distilled water on the slide.

Float sections on the water.

Warm gently to allow sections to flatten—must not melt paraffin.

Pour off excess of water, holding the ends of the ribbons to prevent them floating off.

Stand slides on end a few hours to allow water to evaporate.

2. *To remove paraffin:*

Place slide in xylol three to five minutes.

3. *To stain sections*:

Place slide in fresh xylol three minutes.
Transfer to absolute alcohol.
Transfer to 90-per-cent. alcohol.
Transfer to 80-per-cent. alcohol.
Transfer to 50-per-cent. alcohol. (May be omitted.)
Transfer to water.
Stain with an aqueous stain.
Wash in water.
Transfer to 50-per-cent. alcohol. (May be omitted.)
Transfer to 80-per-cent. alcohol.
Transfer to 90-per-cent. alcohol.
Transfer to absolute alcohol.
Transfer to xylol.
Transfer to fresh xylol.
Mount in xylol-balsam.

If an alcohol stain is used instead of an aqueous one, the carrying down and up through the graded alcohols is omitted.

If it is desired to stain double with eosin-hæmatoxylin (page 23) use the above technic in staining with hæmatoxylin; then the alcoholic eosin stain before final transfer to absolute alcohol.

CHAPTER II

SPECIAL STAINING METHODS

Of these only the more common will be described.

(1) Silver-nitrate Method of Staining Intercellular Substance.—After first washing, the tissue, *e.g.*, omentum or cornea, is placed in a from 0.2- to 1-per-cent. solution of silver nitrate, or better, protargol, where it is kept in the dark for a half-hour or more according to the thickness and density of the tissue. The specimen is then washed in water, transferred to 40-per-cent. alcohol and placed in the direct sunlight until it assumes a light brown color. It is then placed in fresh 80-per-cent. alcohol for preservation.

(2) Chlorid of gold in 1-per-cent. aqueous solution is used in the same manner for demonstrating connective-tissue cells and their finer processes.

(3) Weigert's Elastic-tissue Stain.—This is prepared as follows:

Fuchsin,	2 gm.
Resorcin,	4 gm.
Water,	200 c.c.

These are boiled for five minutes, during which 25 c.c. of liquor ferri sesquichlorati are stirred in. The result is a precipitate which should be filtered out after the liquid has become cool. After drying, 200 c.c. of 95-per-cent. alcohol are added to the filtrate and boiled until the latter dissolves. Lastly, 4 c.c. of hydric chlorid are added to the solution. Sections should remain in the stain thirty minutes, after which they are washed in alcohol until the stain ceases to be given off.

(4) Verhoeff's Differential Elastic Tissue Stain.—

Hæmatoxylin crystals (Grübler),	0.15 gm.
Absolute alcohol,	25.00 c.c.

Dissolve by heating, then add 5-per-cent. aqueous solution ammonium hydrate, 1 drop. Allow to stand 5 minutes or longer, then add Lugol's solution (iodin 2 parts, potassium iodid 4 parts), 22.00 c.c.

Filter, let stand in corked bottle 24 hours.

In using this stain add to each cubic centimeter required of the above solution 1 drop of a 7-per-cent. solution of ferric chlorid in absolute alcohol.

Sections are carried from alcohol into the staining fluid where they remain one to three hours. The stain should be kept covered to prevent evaporation. Sections are next washed in water one or two minutes and examined under the microscope. If further differentiation is desirable, place a few seconds in 1-per-cent. aqueous solution ferric chlorid. Wash in water. Counterstain in 0.2-per-cent. eosin, dehydrate in alcohol, clear and mount in balsam.

Elastic tissue is stained black, nuclei take hæmatoxylin, while other connective tissues, myelin and neuroglia stain with eosin. Fixation by Zenker's fluid gives perhaps the best results although the stain may be used after other fixations. Water in the staining fluid causes precipitates. It is therefore important to see that all dishes used are perfectly dry or washed with alcohol before using. Too much ferric chlorid gives precipitates and overstaining, too little results in failure of the elastic fibres to stain.

(5) GOLGI'S CHROME-SILVER METHOD FOR DEMONSTRATING SECRETORY TUBULES.—Small pieces of perfectly fresh tissue, *e.g.*, liver, are placed in the following:

Potassium bichromate, 4-per-cent. aqueous solution,	4 vols.
Osmic acid, 1-per-cent. aqueous solution,	1 vol.

After three days they are transferred without washing to a 0.75-per-cent. aqueous solution of silver nitrate, which should be changed as soon as a precipitate forms. The specimens remain in the second silver solution from two to three days, after which they are rapidly dehydrated, embedded in celloidin, and cut into rather thick sections.

(6) MALLORY'S PHOSPHOMOLYBDIC ACID HÆMATOXYLIN STAIN FOR CONNECTIVE TISSUE.—Thin sections are placed for from two to ten minutes in a 10-per-cent. aqueous solution of phosphomolybdic acid. They are then washed in distilled water and transferred to:

Phosphomolybdic acid, 10-per-cent. aqueous solution,	100.0 c.c.
Distilled water,	200.0 c.c.
Hæmatoxylin crystals,	1.75 gm.
Carbolic-acid crystals,	5.00 gm.

The phosphomolybdic acid and water are first mixed, after which the hæmatoxylin and carbolic acid are added.

After staining from ten to twenty minutes the sections are washed

in distilled water, placed for five minutes in 50-per-cent. alcohol, then in strong alcohol, cleared in xylol and mounted in xylol-balsam. This stain works best after Zenker's fluid fixation.

(7) MALLORY'S PHOSPHOTUNGSTIC ACID HÆMATOXYLIN STAIN FOR CONNECTIVE TISSUE.

Hæmatoxylin (or hæmatein ammonium),	0.1 gm.
Water,	80. c.c.
Phosphotungstic acid (Merck), 10-per-cent. aqueous solution,	20. c.c.

The hæmatoxylin should be dissolved in a little water with the aid of heat and, when cool, added to the rest of the solution. Allow to ripen for several weeks or months. Or, if it is desired for immediate use, the solution can be ripened by the addition of 10 c.c. of a 1/4-per-cent. solution of potassium permanganate.

Tissues should be fixed in Zenker's fluid (p. 8).

1. Treat sections with iodin solution to remove mercury precipitate, 5 to 10 minutes (p. 13.)
2. Several changes 95-per-cent. alcohol.
3. Water.
4. One-fourth-per-cent. aqueous solution potassium permanganate, 5 to 10 minutes.
5. Wash in water.
6. Five-per-cent. aqueous solution oxalic acid, 5 to 10 minutes.
7. Wash thoroughly in water.
8. Phosphotungstic acid hæmatoxylin solution, twelve to twenty-four hours.
9. Dip for a few seconds in 95-per-cent. alcohol.
10. Clear in carbol-xylol and xylol and mount in xylol-damar.

(8) MALLORY'S ANILINE BLUE STAIN FOR CONNECTIVE TISSUE.—Tissues should be fixed in Zenker's fluid (p. 8).

1. Stain thin sections in a 0.2-per-cent. aqueous solution of acid fuchsin for five to ten minutes. (This step may be omitted.)
2. Stain in the following solution for twenty minutes:

Aniline blue (soluble in water),	0.5 gm.
Orange G.,	2.0 gm.
Phosphomolybdic acid, 1-per-cent. aqueous solution,	100.0 c.c.

3. Decolorize in several changes of 95-per-cent. alcohol.

4. Clear in carbol-xylol and xylol and mount in xylol-damar.

(9) MARESH'S MODIFICATION OF BIELSCHOWSKY'S STAIN FOR THE FINER CONNECTIVE TISSUE FIBRILS.

1. Very thin paraffin sections are fixed to the slide and placed for twelve to twenty-four hours in a 2-per-cent. silver nitrate solution.

2. For fifteen to thirty minutes in freshly prepared alkaline silver solution (20 c.c. of 2-per-cent. silver nitrate solution, to which have been added 3 drops of 40-per-cent. caustic soda, and the precipitate redissolved by adding ammonia drop by drop while stirring).

3. Rinsed quickly in distilled water and placed in 20-per-cent. formalin for three minutes or until black.

4. Washed in distilled water and transferred for ten minutes to acid gold bath (10 c.c. distilled water to which have been added 2 or 3 drops of 1-per-cent. gold chlorid and 2 or 3 drops acid).

5. Placed one-half to one minute in 5-per-cent. hyposulphite of soda to remove all unreduced silver.

6. Washed in distilled water, dehydrated, cleared in xylol and mounted in balsam.

(10) OSMIC-ACID STAIN FOR FAT.—For this purpose osmic acid is used in a 1-per-cent. aqueous solution. The method is especially useful for demonstrating developing fat, fatty secretions (mammary gland), and fat absorption (small intestine). Very small bits of the tissue are placed in the osmic-acid solution for from twelve to twenty-four hours. They are then hardened in graded alcohols, embedded in celloidin, and the sections mounted in glycerin.

(11) SUDAN III AND SCHARLACK R FOR FAT.—Either of these dyes may be used in concentrated solution in 70-per-cent. alcohol. Frozen sections of fresh or formalin-fixed tissue are used. They are first placed in 50-per-cent. alcohol for several minutes, then transferred to this staining fluid for from fifteen to thirty minutes, washed in water or in 50-per-cent. alcohol and mounted in glycerin or in glycerin jelly. Both dyes stain fat intensely red. A nuclear stain such as hæmalum, or a plasma stain such as picric acid, or both may be used in conjunction with either Sudan III or Scharlack R. Sections are first stained in hæmalum, washed in water, transferred to 50-per-cent. alcohol, then stained with either the Sudan III or Scharlack R, washed in water, transferred to an aqueous solution of picric acid, washed again in water and mounted in glycerin or glycerin jelly.

(12) JENNER'S BLOOD STAIN.

Water-soluble eosin (Grübler), 1-per-cent. aqueous solution, 100 c.c.
Methylene blue—pure (Grübler), 1-per-cent. aqueous solution, 100 c.c.
Mix, and after standing 24 hours, filter. The filtrate is dried at 65° C., washed, again dried and powdered.

To make the staining solution, 0.5 gm. of the powder is dissolved in 100 c.c. pure methyl alcohol. Blood smears stain in from two to five minutes. They are then washed in water, dried, and mounted in balsam.

This solution acts as a fixative as well as a stain.

(13) BENDA'S METHOD FOR MITOCHONDRIA.

(1) Very small pieces of tissue are fixed in a modified Flemming's fluid (chromic acid 1% 15 vols., Osmic acid 2%, 4 vols., Acetic acid glacial 6 drops) 4 or 8 days. Wash in water for one hour.

(2) Then place for 24 hours in a mixture of equal parts 1% acetic acid and 1% chromic acid.

(3) Transfer tissue to 2% solution potassium bichromate for 24 hours.

(4) Wash thoroughly in running water or in frequently changed water several hours, dehydrate in progressive alcohols, embed in paraffin, section, fix to slides, remove paraffin, and

(5) Place in 4% iron-alum solution 24 hours. Wash in running water 24 hours.

(6) Transfer to a solution of sodium sulphalizarinate (Kahlbaum), made by adding 1 c.c. of a saturated alcoholic solution to 100 c.c. of water.

(7) After rinsing, the slides are flooded with the following solution and warmed until vapor is given off.

Saturated alcoholic (70-per-cent.) solution crystal violet 1 part.
1-per-cent. alcoholic (70-per-cent.) solution of hydrochloric acid, 1 part.
Anilin water, 2 parts.

(8) Rinse, blot, differentiate by placing one or two minutes in 30% acetic acid solution, wash thoroughly in running water, blot again, dehydrate with absolute alcohol, clear by passing through bergamot oil and xylol and mount in balsam.

CHAPTER III

SPECIAL NEUROLOGICAL STAINING METHODS

Weigert's Method of Staining Medullated Nerve Fibres

In preparing material for the Weigert method, two points are to be kept in mind: 1st, proper fixation and preservation of the myelin sheaths; 2d, treatment (mordanting) with a reagent which enters into combination with the myelin, the result being that the myelin sheaths stain specifically with hæmatoxylin. Formalin fulfils the first requirement, the bichromates the first and second. Consequently the material may be fixed and hardened in bichromate, and, if not to be used immediately, is best kept in formalin to avoid overhardening. Or the material may be fixed and kept in formalin and impregnated with the bichromate before using, the latter being done before dehydrating in alcohol. Further mordanting, which is usually done, especially when the material has been kept for some time in formalin or alcohol, is for the purpose of intensifying the stain.

Material is fixed in one of the following fluids:

(*a*) Müller's fluid (page 7).

(*b*) Potassium bichromate, 5-per-cent. aqueous solution.

(*c*) Formalin, 10-per-cent. aqueous solution.

(*d*) Formalin, 1 volume; potassium bichromate, 5-per-cent. aqueous solution, 9 volumes.

In Müller's fluid or in plain potassium-bichromate solution a hardening of two days to four weeks is required; in formalin or formalin-bichromate from a week to ten days is sufficient. All material is better kept until used in 5-per-cent. to 10-per-cent. formalin solution than in alcohol. The specimens are then hardened in graded alcohols, embedded in celloidin, and sections cut in the usual way. Material fixed in formalin should be placed for several days in the following:

Chrome alum,	1 gm.
Potassium bichromate,	3 gm.
Water,	100 c.c.

before hardening in alcohol.

Sections from material fixed in any of the chrome-salt solutions are placed for from twelve to twenty-four hours in a saturated aqueous solution of neutral cupric acetate diluted with an equal volume of water. The cupric acetate forms some combination with the tissues which intensifies their staining qualities, thus acting like the chrome salts as a mordant.

After mordanting, the sections are washed in water and transferred to the following staining fluid:

Hæmatoxylin crystals,	1 gm.
Alcohol, 95-per-cent.,	10 c.c.
Lithium carbonate—saturated aqueous solution,	1 c.c.
Water,	90 c.c.

This solution must either be freshly made before using, the hæmatoxylin being dissolved first in the alcohol, or the hæmatoxylin may be kept in 10-per-cent. alcoholic solution, the lithium carbonate in saturated aqueous solution, and the staining fluid made from these as needed.

Sections remain in the hæmatoxylin solution from two to twenty-four hours, the longer time being required for staining the finer fibres of the cerebral and cerebellar cortices. They are then washed in water and decolorized in the following:

Potassium ferricyanid,	2.5 gm.
Sodium biborate,	2.0 gm.
Water,	300.0 c.c.

While in the decolorizer, sections should be gently shaken or moved about with a glass rod to insure equal decolorization. In the decolorizer the sections lose the uniform black which they had on removal from the hæmatoxylin. They remain in the decolorizing fluid until the gray matter becomes a light gray or yellow color, in sharp contrast with the white matter which remains dark. Sections are then washed in several waters to remove all traces of decolorizer, and dehydrated in alcohol.

Weigert-Pal Method.—In this modification of the Weigert method, material hardened in formalin should be further hardened in potassium bichromate 5-per-cent. for two weeks, or in copper bichromate 3-per-cent. for about a week, after which it may be cut and stained without further mordanting. Sections from material hardened in the other above-mentioned ways are mordanted in a 3- to 5-per-cent. aqueous solution of potassium bichromate instead of in the

copper-acetate solution. After rinsing in water the sections are stained in hæmatoxylin as in the ordinary Weigert method. The lithium carbonate may, however, be omitted. They are then washed and transferred to a 0.25-per-cent. solution of potassium permanganate, where they remain from one-half to two minutes, after which they are again washed and placed in the following:

Oxalic acid,	1 gm.
Potassium sulphite,	1 gm.
Water,	200 c.c.

In this solution differentiation takes place, the medullary sheaths remaining dark, while the color is entirely removed from the rest of the tissue. If the section is still too dark, it may again be carried through the permanganate and oxalic-acid solutions, rinsing in water between changes, until sufficiently decolorized.

All formalin-fixed material is best stained by the Weigert-Pal method. An intensification of the stain, especially of the very fine fibres, may sometimes be obtained by placing the sections for a minute in a 0.5-per-cent. aqueous solution of osmic acid before decolorizing.

Marchi's Method for Staining Degenerating Nerves

Small pieces of tissue are fixed and hardened for from seven to ten days in Müller's fluid. Thin slices of the tissue are then transferred to a solution of one part 1-per-cent. osmic acid and two parts Müller's fluid, in which they remain from two to seven days. After embedding and sectioning in the usual manner, sections are mounted, usually without further staining, in xylol-balsam. The treatment with Müller's fluid so affects the normal medullary sheaths that they will not take the osmic-acid stain, but appear yellowish-brown, while the degenerating sheaths (probably fatty) stain black. The result is a positive picture of stained degenerating fibres in contrast with the stained normal and unstained degenerated fibres as seen after Weigert staining. Another advantage of the Marchi method is that, as the picture is a positive one, an early or slight degeneration may be recognized which would escape notice in material stained by Weigert's method; on the other hand, in a long-standing degeneration when the medullary sheaths have completely disappeared and their places have been taken by connective tissue, there being no degenerated myelin remaining, the Marchi method is inapplicable.

Busch's modification of the Marchi method gives sharp pictures and has the advantage of allowing formaldehyd fixation and hardening. Tissues thus treated are placed for from five to seven days in a solution of one part osmic acid, three parts iodate of sodium, and 300 parts water. They are then embedded, cut, and mounted as usual.

Golgi Methods of Staining Nerve Tissue

The Golgi methods in most common use at present are the following:

(1) Golgi Silver Methods.—(*a*) *Slow Method.*—Blocks of tissue are placed for several months in a 3-per-cent. aqueous solution of potassium bichromate. Small pieces of the tissue are then transferred immediately to a 0.75-per-cent. aqueous solution of silver nitrate. This is changed several times or until no more precipitate is formed. In the last silver solution they remain for from one to three days. The only method of determining whether the tissue has been sufficiently long in the bichromate is to try at intervals small bits of the tissue in the silver solution until a satisfactory result is secured. Sections should usually be from 50 to 80 μ thick and are mounted in balsam without a cover-glass.

(*b*) *Rapid Method.*—Small pieces of tissue, 2 to 4 mm. thick, are placed in the following solution for from two to six days, the time depending upon the age and character of the tissue, the temperature at which fixation is carried on, and the elements which it is desired to impregnate:

Osmic acid, 1-per-cent. aqueous solution, 1 part.
Potassium bichromate, 3.5-per-cent. aqueous solution, 4 parts.

As a rule, the longer the hardening the fewer are the elements stained, but these few are clearer. The tissue is next transferred to silver nitrate as in the slow method. Pieces of tissue should be tried each day until a satisfactory result is obtained. The pieces may be kept in silver nitrate some time, but not in alcohol, and are better cut without embedding, the pieces being simply washed in 95-per-cent. alcohol several hours, then gummed to the block with celloidin, cut in 95-per-cent. alcohol, and mounted as in the slow method.

(*c*) *Mixed Method.*—Specimens are placed in the bichromate solution for about four days, then from one to three days in the osmium-bichromate mixture (see Rapid Method), after which they are transferred to the silver solution (see Slow Method).

(*d*) *Formalin-bichromate Method.*—Tissues are placed for from two to six days in the following solution:

Formalin,	10 to 20 parts.
Potassium bichromate, 3-per-cent. aqueous solution,	90 to 80 parts.

Subsequent treatment with silver is the same as in the previously described method. The results resemble those of the slow method. The specimens may be kept in strong alcohol. The method is satisfactory only for the adult cerebrum and cerebellum.

(2) GOLGI BICHLORID METHOD.—Material, which need not be cut into small pieces, remains for several months in the potassium-bichromate solution (see Slow Silver Method), after which it is transferred to a 0.25-per-cent. to 1-per-cent. aqueous solution of mercuric chlorid for from four to twelve months or longer, the solution being changed as often as discolored. The degree of impregnation must be determined by frequently testing the material, but is usually indicated by the appearance of small white spots on the surface of the tissue.

A modification of the bichlorid method, known as the *Cox-Golgi Method*, often gives good results. The following fixing solution is used:

Potassium bichromate, 5-per-cent. aqueous solution,	20 parts.
Mercuric chlorid, 5-per-cent. aqueous solution,	20 parts.
Distilled water,	40 parts.

After mixing the above, add

Potassium chromate, 5-per-cent. aqueous solution,	16 parts.

Tissues remain in this fluid for from two to five months.

In the Golgi silver methods the result of the treatment, first with bichromate and then with silver nitrate, is that a precipitate is formed in the tissue, a chromate or some other silver salt, which in favorable cases is largely confined to certain of the nerve cells and their processes. It must be remembered that only a few of the cells and processes are stained, these often only partially, and that other irregular precipitations are usually present. In the mercury methods, the bichromate of potassium and the bichlorid of mercury may be used combined in the same solution. There are other modifications of the Golgi methods, in which similar precipitates of other metallic salts are secured.

Golgi specimens should be dehydrated and embedded as rapidly as possible. This is especially true of specimens treated by the rapid and the mixed methods. Those treated by the slow silver method and by the bichlorid method are more permanent, and more time may be taken with their dehydration. Thick sections should be cut (75 to 100μ) and mounted in xylol-balsam. After the rapid method, it is safer to mount without a cover-glass; after the slow method, specimens may be mounted with or without a cover. The balsam should be hard, and melted at the time of using. (See Mounting, page 26.)

Cajal's Methods for Staining the Neurofibrils in the Nerve-cells

In these methods, besides the neurofibrils, the cell processes and especially the axis cylinders are often beautifully displayed, the stain giving a picture in this respect much more general than that of the Golgi methods, but much more specific, and sharper than that of the ordinary stains.

The methods consist mainly of two steps: (1) The staining of the tissue in a solution of silver nitrate; (2) the further reduction of the silver stain with a weak photographic developer. Three methods, or variations, are here given:

(1) Pieces about 0.5 cm. thick are placed in a liberal quantity of from 1-per-cent. or 1.5-per-cent. (new-born or embryonic mammalian material) to 5-per-cent. (adult material) solution of silver nitrate and kept at a temperature of 32° to 40° C. for two to five days. When properly stained (shown by a yellowish or light brown coloration of freshly cut surfaces) the pieces are very briefly rinsed in distilled water and placed in: pyrogallol (or hydroquinone) 1 gm., distilled water 100 c.c., formalin 5 to 10 c.c., for twenty-four hours or more. They are then washed a few minutes in water and transferred to 95-per-cent. alcohol, which is changed when discolored, and where they may often be kept for some time without injury. They may then be embedded in celloidin or paraffin and sections cut, usually 15–25μ in thickness. Different depths of the blocks of tissue usually vary in stain, the most favorable being intermediate between the surface and centre of the block. Celloidin sections usually keep well in 95-per-cent. alcohol. They may be cleared in carbol-xylol, rinsed in xylol, and mounted in xylol-balsam or xylol-damar in the usual way. In delicate objects (study of pathological changes

in neurofibrils) it may be best to abbreviate the dehydration, and block and cut without infiltration with celloidin.

(2) Pieces are first placed in 95-per-cent. alcohol or in absolute alcohol (32° to 40° C.) for twenty-four hours. For neurofibrils it is better to add from 0.25 c.c. to 1 c.c. of ammonium hydrate to each 10 c.c. of the alcohol. They are then treated with silver nitrate 1 per-cent. or 1.5-per-cent., as in (1). This method gives better pictures of the cell processes and axis cylinders and a better fixation of the cells.

(3) Pieces are first placed in distilled water 100 c.c., formalin 20 c.c., ammonia 1 c.c., for twenty-four hours at 32°–40° C., washed in water twelve to twenty-four hours, and then treated with silver nitrate 1-per-cent. or 1.5-per-cent., as in (1). This method gives pictures of the terminations of nerve fibres on the periphery of nerve cells and their dendrites (end-feet or end-buttons of Auerbach).

In general it is best to avoid, in the above methods, any excessive exposure to the light while the pieces are in the silver bath (especially when the pieces are very small), though they may be brought into the light for examination and while being transferred to the reducing fluid.

Nissl's Method

This method is useful for studying the internal structure of the nerve cell. It depends upon a rapid fixation of the tissue, its subsequent staining with an aniline dye, and final decolorization in alcohol.

The aniline dye most commonly used is *methylene blue.* There are many variations and modifications of Nissl's method. The following is simple and gives uniformly good results:

Specimens are first fixed in mercuric-chlorid solution (page 8), in formalin (10-per-cent. aqueous solution), or in absolute alcohol, and embedded in celloidin.

Thin sections are stained in a 1-per-cent. aqueous solution of pure methylene blue (Grübler). The sections are gently warmed in the solution until steam begins to be given off. They are then washed in water and differentiated in strong alcohol. The degree of decolorization which gives the best results can be learned only by practice. Several alcohols must be used, and the last alcohol must be perfectly free from methylene blue. The sections are cleared in

equal parts xylol and cajeput oil and mounted in xylol-balsam. A contrast stain may be obtained by having a little eosin or erythrosin in the last alcohol.

Bielschowsky's Silver Impregnation Methods

These methods give pictures similar to those produced by Cajal's methods.

1. Fix thin pieces (1 cm. thick) of fresh material in acid-free formalin, 10 to 15 per cent. 2. Wash an hour in water. 3. Prepare frozen sections, as thin as possible. 4. Transfer from distilled water (using glass instruments) to silver nitrate 2 to 3 per cent., where they remain 24 to 48 hours. 5. Wash quickly in distilled water and place in the following ammoniacal silver solution: 5 cc. silver nitrate solution 10 per cent., + 5 drops 40 per cent. aqueous solution of pure sodium hydrate; add ammonia drop by drop, stirring after each drop, until the brown precipitate has just or not quite dissolved; add 20 ccm. distilled water. Leave sections in this 10 to 20 minutes, (or less) until they are deep brown. 6. Pass through distilled water and reduce (5 minutes) in 20 per cent. formalin (in tap water). 7. Wash quickly in distilled water and place in glacial acetic acid 5 drops + distilled water 20 ccm. until the sections change from brown to dark yellow. 8. Transfer to 2 to 3 drops gold chloride 1 per cent. (in distilled water) + 10 ccm. distilled water + 2 to 3 drops of glacial acetic acid until they become reddish violet (10 to 20 minutes). 9. Wash quickly in distilled water. Fix half minute in 10 ccm. hyposulphite of soda 5 per cent. + 1 drop of sodium sulphite. 10. Wash thoroughly, dehydrate, clean in carbol-xylol (1:10), and mount in balsam.

Better differentiation of axis-cylinders may be obtained by placing the sections 24 to 48 hours in pure, undiluted pyridin, washing thoroughly and then into the silver solution as in 4, etc.

Blocks (formalin material) to 1 ccm. may be impregnated *in toto* as follows: pure pyridin 3 to 4 days, thorough washing for several hours, silver nitrate 3 per cent. (incubator) 3 to 5 days, ammoniacal silver solution diluted with 4 vols. of water 24 hours, wash 2 hours, 20 per cent. formalin.

Weigert's Neuroglia Stain

This method stains the neuroglia fibers blue. Prepare glia mordant by dissolving 2.5 grams of fluorchrom in 100 ccm. boiling water,

extinguish flame and add 5 ccm. of 36 per cent. acetic acid and then 5 grams of finely powdered neutral copper acetate, stirring.

1. Fix pieces not over ¼ to ½ cm. thick in formalin 10 per cent., then place in the glia mordant or fix in the glia mordant to which 10 per cent. of formalin has been added. 2. Wash briefly in water; alcohol, celloidin or paraffin or frozen sections. 3. Reduction: transfer sections to ⅓ per cent. potassium permanganate 10 minutes, rinse briefly in two waters and leave for 1 to 2 hours in the following filtered solution: chromogen (Hoechst's Farbwerke) 10 grams + formic acid (sp. gr. 1.20) 10 ccm. + distilled water 200 ccm.; before using add 10 ccm. of 10 per cent. sol. of sodium sulphite. 4. Rinse twice in water. 5. Stain a short time, on the slide, in a hot saturated alcoholic (70 to 80 per cent.) solution of methyl violet, decanted when cool, to which is added 5 ccm. of an aqueous 5 per cent. solution of oxalic acid. Rinse in normal salt solution. 6. Flow over the section, briefly, a saturated solution of iodine in 5 per cent. potassium iodide solution. 7. Decolorize in anilin oil-xylol, equal parts. 8. Carefully remove the latter by repeatedly flooding the slide with xylol. 9. Balsam.

General References for Further Study of Technic.

Lee: The Microtomist's Vade-mecum.
Langeron, M.: Précis de Microscopie, Paris, 1916.
Mallory and Wright: Pathological Technic.

PART II

THE CELL

CHAPTER IV

THE CELL

In the simplest forms of animal life the entire body consists of a little albuminous structure, the essential peculiarity of which is that it possesses properties which we recognize as characteristic of living organisms. This albuminous material basis of life is known as *protoplasm*, while the structure itself is known as a *cell*. All plants and animals consist of cells and their derivatives, and if an attempt be made to resolve any of the more complex living structures into its

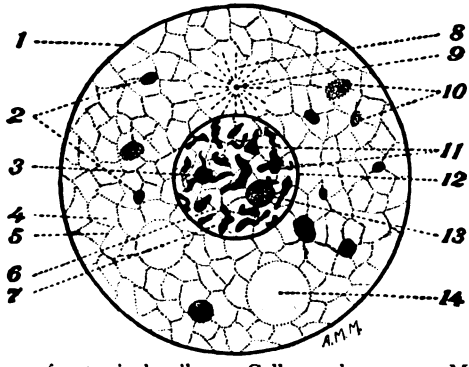

Fig. 1.—Diagram of a typical cell. 1, Cell membrane. 2, Metaplasm granules. 3, Karyosome or net-knob. 4, Hyaloplasm. 5, Spongioplasm. 6, Linin network. 7, Nucleoplasm. 8, Attraction-sphere. 9, Centrosome. 10, Plastids. 11, Chromatin network. 12, Nuclear membrane. 13, Nucleolus. 14, Vacuole.

component elements, it is found that the smallest possible subdivision still compatible with life is the cell. The cell may therefore be considered as the *histological element* or *unit of structure*. While presenting fundamental similarities which define them, cells vary greatly in size, shape and structure. Thus in the human body the cells vary in size from the small lymphocyte with a diameter of about 4μ to the giant cell of bone marrow with a diameter up to 100μ. Cells also vary greatly in shape from the typical spherical of the ovum to the very irregular stellate multipolar cell of the nervous

system. In multicellular organisms the element of pressure has frequently much to do with determining the shape of the cell. Also as most cells are soft and pliable their shapes frequently change in response to changes in function or in environment.

In most cells the structure of the protoplasm is not uniform throughout the cell but is differentiated to form certain special cell structures. Thus in most cells a portion of the protoplasm is specially modified to form a body known as the *nucleus*. Also at the surface of the cell there is usually some differentiation of the protoplasm to form a more or less distinct *cell wall* or *cell membrane*. An actively multiplying cell contains a minute structure associated with the reproductive function and known as the *centrosome*.

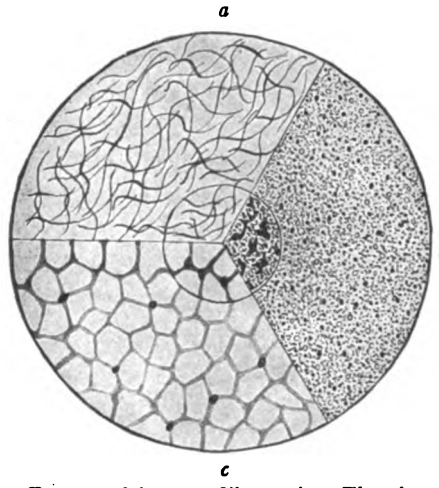

FIG. 2.—Diagram Illustrating Theories of Protoplasmic Structure. *a*, Fibrillar theory; *b*, granule theory; *c*, "foam" theory. (The general structure of cell body and nucleus corresponds.)

A *typical cell* thus consists of the following structures (Fig. 1): (1) The cell body; (2) the cell membrane; (3) the nucleus; (4) the centrosome. Of these only the cell body with its modified surface cytoplasm or cell membrane is present in all cells. A few cells contain, in their fully developed condition, no nuclei. In many mature cells it is impossible to distinguish a centrosome.

1. **The Cell Body.**—This consists of a viscid, colorless, semi-fluid substance, belonging to the general class of albumens and known as *protoplasm*. Protoplasm is alkaline in reaction and of complex chemical composition containing the elements carbon, hydrogen, oxygen and nitrogen in quite constant proportions, and smaller variable quantities of phosphorus, sulphur, iron and other substances. It contains a peculiar nitrogenous proteid, *plastin*. Structurally it can be differentiated into a formed element, *spongioplasm*, and a homogeneous element *hyaloplasm*. Distributed along the spongioplastic network are minute granules, *microsomes*. The exact rela-

tions which these elements bear to one another and to the cell as a whole have been the subject of much investigation and speculation. The following theories as to the ultimate structure of protoplasm have been at one time or another more or less generally accepted.

Altmann's granule theory considers protoplasm as composed of fine granules embedded in a gelatinous intergranular substance. Altmann believed these granules the ultimate vital elements, and for this reason gave them the name of bioblasts (Fig. 2, *b*).

Flemming's filar theory was similar to Altmann's except that fibrils (fila, filar mass or miton) replaced the granules in the fluid or semi-fluid ground substance (interfilar mass or paramiton).

Frommann's reticular theory looked upon protoplasm as composed of an active element, a network or reticulum of fine fibrils (spongioplasm), and of a more direct fluid or semi-fluid substance (hyaloplasm) filling the interstices of the network.

Bütschli's Foam Theory.—Bütschli considered protoplasm a foam or emulsion, the microscopic appearance of which can be simulated by artificial emulsions. He ascribed the appearance of a reticulum to the fact that each little foam space forms a complete cavity filled with fluid, the cut walls of these spaces giving a reticular appearance on section (Fig. 2, *c* and Fig. 3).

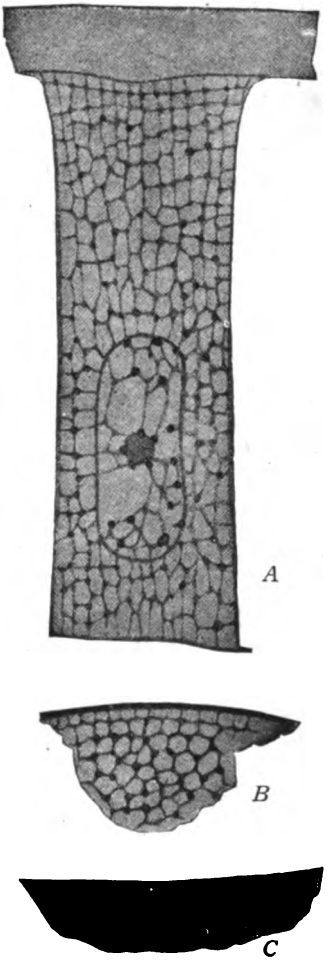

FIG. 3.—Foam or emulsion structure of protoplasm according to Butschli (Butschli). *A*, Epidermal cell of the earthworm. *B*, Peripheral cytoplasm of sea urchin's egg. *C*, Artificial emulsion of olive oil, sodium chlorid and water.

That the question as to the ultimate structure of protoplasm still remains unanswered is dependent mainly upon the extreme technical difficulties which have confronted the cytologist. Living protoplasm has a homogeneous glossy appearance, showing even under the highest magnification rarely more than a granular structure. It is usually only after death of the cell and the use of chemical fixatives and stains, that the so-called "structure" of protoplasm becomes visible. How closely the picture presented by such chemically treated protoplasm corresponds to the structure of living protoplasm is as yet unde-

termined. It is quite possible that the structure even of undifferentiated protoplasm or protoplasm proper, such as is found in early embryonal cells, is not entirely uniform. The protoplasm of the more highly specialized cells certainly differs markedly in structure and somewhat in chemical composition in different cells. It even differs in the same cell under different functional conditions. These differences are apparently due to special development of the protoplasm for its peculiar functions. Thus, for example, in the muscle cell and the nerve cell most of what in the embryonal cell was undifferentiated protoplasm has become differentiated into contractile or conductile fibers. The nucleus and a small amount of undifferentiated or less differentiated protoplasm remain and are probably largely active in maintaining the nutrition of the cell. Such changes in the protoplasm are of course permanent. Temporary or periodic changes in the structure of protoplasm are seen in such cells as the secreting cells of the pancreas or of the salivary glands where marked differences in the protoplasm occur, dependent upon whether the cell is in a resting, or actively secreting condition.

Protoplasm is thus probably best considered as the material basis of cell activity, *i.e.*, of life, rather than as a substance having fixed and definite chemical or morphological characteristics.

It is convenient to use the term *protoplasm* to mean the entire substance of the cell, *karyoplasm* to designate the protoplasm of the nucleus, and *cytoplasm* the protoplasm of the cell body exclusive of the nucleus.

Peculiar bodies known as *plastids* (Fig. 1) are of frequent occurrence in vegetable cells, and are also found in some animal cells. They are apparently to be regarded as a differentiation of the cytoplasm, but possess a remarkable degree of independence, being capable of subdivision and in some cases of existence outside of the cell.

In addition to the granules which are apparently an integral part of the protoplasmic structure, other granules and various cell "inclusions" occur, to which the term *metaplasm* (*paraplasm, deutoplasm*) *granules*, has been applied (Fig. 1). Some of these are intimately associated with the cell activities and represent either food substances in process of being built up into the protoplasm of the cell or waste products of cell metabolism. Others, such *e.g.*, as the glycogen granules of the liver cell or the mucous granules of the mucous cell, are specific secretion products. Still others are fat droplets, pigment granules, and various excrementitious substances.

When the protoplasm of a cell can be differentiated into a central granular area and a peripheral clear area, the former is known as *endoplasm*, the latter as *exoplasm*. When the exoplasm forms a

distinct limiting layer, but blends imperceptibly with the rest of the protoplasm, it is known as the *crusta*.

In some cells, minute channels or canals are present in the cytoplasm (Fig. 4). These channels may contain branching processes from other cells, forming what is known as a *trophospongium*. Some intracellular canaliculi are apparently secretory in character and may communicate with fine intercellular secretory channels. In this way the secretion of such cells as the serous cells forming the demilunes of mucous tubules (p. 227), or of the parietal cells of the stomach glands (Fig. 155), is carried out into the duct system of the gland. Other intracellular canaliculi, for example in ganglion cells, communicate with pericellular lymph spaces, thus apparently being concerned with the nutrition of the cell. Closed networks of canaliculi within the cell "apparato reticulare," having no extra cellular communications have also been described.

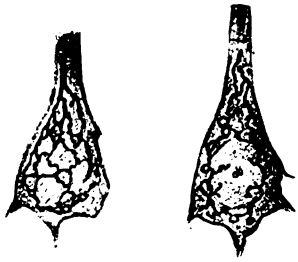

Fig. 4.—Two pryamidal cells from rabbit's cortex showing intracellular canals of Golgi (Cajal).

Mitochondria.—These are granular, rod-shaped or filamentous structures more dense than the fluid or semifluid surrounding remainder of the cytoplasm in which they lie They are found in all kinds of cells, in all stages of development, in all conditions of functional activity, in all species of plants and animals thus far studied. Mitochondria are therefore as definite elements of the cell body as the chromatins are of the nucleus. The investigation and discussion of the mitochondria and sequentially of the optically homogeneous ground substance in which they lie are occupying an ever-increasing place in cytology, and their importance looms large on the cytological horizon. It is more than probable that many of our deep rooted ideas as to the fundamental structure of protoplasm and of cytoplasmic differentiation may have to be radically modified and that the foregoing description of protoplasm and of the structure of the cell, especially of the cytoplasm, is, in the light of our present knowledge, more classical than accurate. Such description will however be for a time at least necessary as the terms used have become more or less fixed in cytological nomenclature and underlie our comparisons between normal and pathological cells and tissues.

For the following summary of the essentials of our present knowl-

edge of Mitochondria the writer is indebted to the most excellent and comprehensive review by Cowdry.[1]

(1) Mitochondria constitute a definite class of cytoplasmic

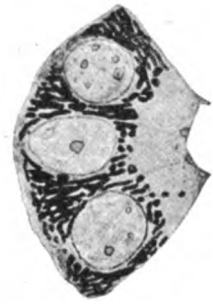

FIG. 4A.—Mitochondria in kidney cells of the white mouse. (Cowdry.)

granulations. They present even less variations than the chromatins and are present in all living matter.

(2) Chemically they are of a fatty, phosphatid nature.

(3) There appears to be[2] a constant number of mitochondria per unit volume of cytoplasm in normal nerve cells of a corresponding

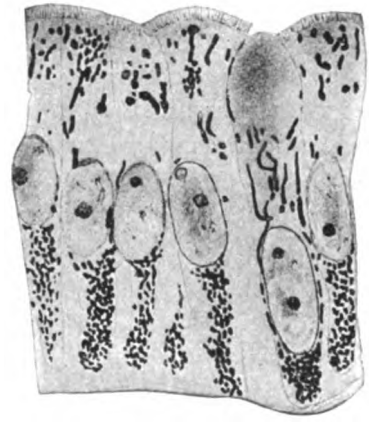

FIG. 4B.—Intestinal epithelium of white mouse, showing bipolar arrangement of mitochondria. (Cowdry.)

type in the mouse and this constant differs for different types of cells. The differences are slight. Should they prove general they might serve as a basis for classification and might furnish a valuable norm for comparison with pathological cells. Coupled with this in

[1] Contributions to Embryology. Pub. Carnegie Institute, Washington, Vol. VIII, 1918.

[2] Contributions to Embryology. Pub. Carnegie Institute, Washington, Vol. VI.

importance in the field of pathology is the fact that mitochondria are extremely sensitive to pathological changes and it has already been shown by Goetsch[1] that in colloid goitre without clinical symptoms of hyperthyreoidism the thyreoid cells show a reduced number of mitochondria, while in colloid goitre with symptoms of hyperthyreoidism the cells show a superabundance of mitochondria. They are thus indicators of an entirely different type of cellular activity than is the nucleus.

(4) The free movement of the mitochondria proves the rest of the cytoplasm, in which they lie, to be more or less fluid and free from any hindering alveolar or reticular structure.

(5) As to the function of the mitochondria, much has been claimed but little proved. They are certainly concerned in metabolic processes but their function is probably more fundamental than specialized. They have to do with the formation of fat, lipoid, pigment, and probably pre-secretion granules. The important rôles claimed for them in cell division and heredity have not been substantiated.

Recognizing the importance of the mitochondria, Cowdry calls attention to the importance of the optically homogeneous ground substance, to the fact that changes in the distribution of the visible constituents of the protoplasm may be made without disturbing greatly its vital processes, while a thorough mixing of the cytoplasm destroys the life of the cell. Further that "vital phenomena are totally incomprehensible unless there exists some structural organization in protoplasm."

The comparatively late discovery and still later appreciation of the importance of such conspicuous structures as mitochondria are probably explained by the devotion of cytologists to the study of fixed and hardened rather than of fresh tissues; to the use of fixatives such as alcohol and strong solutions of chloroform, acetic acid, etc. which acted as solvents of mitochondria; to the concentration of attention upon the nucleus as more easily studied than the cytoplasm, and interest in it as the dominant factor in the phenomena of mitosis and heredity; and later, to the concentration of the physiological chemists on the study of the proteins to the exclusion of the fatty substances among which are the mitochondria.

2. **The Cell Membrane** (Fig. 1).—In most vegetable cells the cell membrane is the most conspicuous part of the cell and was responsible for the name "cell" which the seventeenth-century botanists, over-

[1] Johns Hopkins Hosp. Bul., May, 1916.

looking the importance of the enclosed protoplasm, gave to the little spaces or cavities of which they thought plants composed. A distinct cell membrane is present in but few animal cells. An exception is seen in the fat cell where a distinct membrane exists. In most animal cells no membrane has as yet been demonstrated and this has led to a persistent denial of the existence of such a membrane. It is nevertheless probable that most if not all animal cells have some modification, however slight, of the periphery of their protoplasm which serves to retain the protoplasm within definite bounds, to protect it as it were and at the same time permit osmosis. When a membrane surrounds the cell, it is known as the *pellicula;* when cells lie upon the surface, and only the free surface of the cells is covered by a membrane, it is known as the *cuticula*.

3. **The Nucleus** (Fig. 1).—This is a vesicular body embedded in the cytoplasm. The typical nucleus. like the typical cell, is spheroidal, but the shape of the nucleus varies for different cells and corresponds somewhat to the shape of the cell body, *e.g.*, the rod-shaped nucleus of the elongated smooth muscle cell. It may also be modified by intracellular pressure as, *e.g.*, in the mucous cell and in the fat cell.

The position of the nucleus is usually near the center of the cell. It may, however, be eccentric. Such eccentricity may be due to pressure of cell contents as, *e.g.*, in the mucous cell and in the fat cell. Considered by earlier cytologists an unessential part of the cell, the nucleus is now known to be most intimately associated with cellular activities. It is not only essential to the carrying on of the ordinary metabolic processes of the cell, but is an active agent in the phenomena of mitosis, which in most cases determine cell reproduction.

As a rule, each cell contains a single nucleus. Some cells contain two nuclei (quite common in the liver cell, rare in the ovum and in the nerve cell). A few cells contain many nuclei, *e.g.*, the multinuclear "giant" cells of the spleen, bone-marrow, and certain tumors. Some cells, such as the human red blood cell and the respiratory epithelium, are, in their mature condition, non-nucleated. All non-nucleated cells, however, contained nuclei in the earlier stages of their development. Non-nucleated cells, while capable of performing certain functions, are wholly incapable of proliferation. The non-nucleated condition must, therefore, be regarded as not only a condition of maturity, but of actual senility, at least so far as reproductive powers are concerned.

In some of the lowest forms of animal life, the nuclear material instead of being grouped to form a definite body or nucleus, is more or less evenly distributed as granules through the cytoplasm.

Chemically the nucleus is extremely complex, being composed of the proteids nuclein, paranuclein, linin, paralinin, and amphipyrenin.

Morphologically also the nucleus is complex, much of the apparent structural differentiation being determined by the staining reactions of the different elements when treated with certain aniline dyes. The nuclear structures and their relations to the chemical constituents of the nucleus are as follows:

(*a*) The *nuclear membrane* (*amphipyrenin*). This forms a limiting membrane separating the nucleus from the cell protoplasm. It is doubtful whether the nuclear membrane is different either chemically or morphologically from the nucleoreticulum. It is wanting in some nuclei. When present it appears from its staining reactions to be structurally continuous with, and chemically identical with, in some cases, the linin, in others, the chromatin of the intranuclear network. It may be complete, or fenestrated allowing free communication between the cytoplasm and the nuclear contents.

(*b*) The *intranuclear network*, or *nucleoreticulum*, consists of a *chromatic element* (*nuclein* or *chromatin*) and of an *achromatic element* (*linin*). The linin constitutes the groundwork of the reticulum along which the chromatin granules are distributed. At nodal points of the network there are often considerable accumulations of chromatin forming "net-knots." Some of these are spheroidal resembling nucleoli and are known as *false nucleoli*, or *karyosomes*. Instead of a distinct network there may be disconnected threads or simply granules of chromatin. Chromatin is the most characteristic of the chemical constituents of the nucleus, the only one which contains phosphoric acid, and also, apparently, the only nuclear substance which is always transmitted from parent to daughter cell in cell-division. Fine granules have been described as occurring in the linin, differentiated from chromatin by the fact that they are most susceptible to acid dyes, while chromatin takes basic dyes. Such sharp distinction between linin and chromatin is not accepted by all cytologists. It is possible that they represent different stages in development of the same chemical substance, or that the differences in staining qualities may be due to differences in density or concentration.

(*c*) The *nucleolus* or *plasmosome* (*paranuclein, pyrenin*) is a small spherical body within the nucleus. Not infrequently there are several nucleoli. Similar cells vary as to the number of nucleoli they contain. The same cell may vary as to the number of its nucleoli under varying functional conditions. The nucleolus regularly disappears during mitosis, and during functional activity in some gland cells. It stains intensely with basic dyes. Its function is unknown.

(*d*) *Karyoplasm* (*nucleoplasm, nuclear fluid, nuclear sap*). This is the fluid or semi-fluid material which fills in the meshes of the nucleoreticulum.

While the nucleus is a perfectly distinct structure capable in some animal and in some vegetable cells of moving about more or less actively in the cytoplasm, and is usually separated by a membrane from the rest of the cell, a marked similarity exists between the structure of nucleoplasm and cytoplasm. This similarity is emphasized by the absence in some resting cells of any nuclear membrane, by the apparent direct continuity in some cases of nucleoreticulum

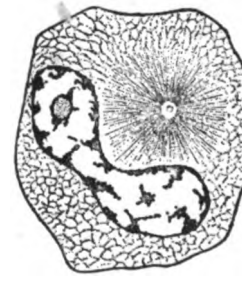

FIG. 5.—Spermatogonium from frog (Hermann). Single centrosome at center of attraction sphere or aster. Nucleus contains a plasmosome.

and cytoreticulum, and by the continuity of karyoplasm and cytoplasm in all cells during cell-division.

4. **The centrosome** (Fig. 5) is a small spheroidal body found sometimes in the nucleus, or more commonly in the cytoplasm near the nucleus. In actively dividing cells the centrosome is frequently double, this being apparently in preparation for the succeeding cell-division In some cases the centrosome is triple or even multiple. It was first found in the ovum and described as peculiar to that cell. It is now believed to occur in most, if not in all, animal cells. It usually consists of (1) a minute central granule or granules—the *centriole*, which stains intensely with iron-hæmatoxylin, and out-

side of which is (2) a clear zone, the *attraction sphere*. From this centre, radiations extend outward into the cytoplasm. There is much confusion of terms in connection with the centrosome, the term centrosome being by some applied to the entire structure including the radiating fibrils, by others to the central granule only, by still others to the central granule plus the surrounding clear area. By some the radiations are believed to be composed of a different substance than the general cytoplasm, which is designated *archoplasm*. The main significance of the centrosome is in connection with cell-division, under which head it will be further considered (p. 54*b*).

Vital Properties of Cells

It has already been noted that the essential peculiarity of the cell is that it possesses certain properties which are characteristic of life. By this is meant that a cell is able: 1. To nourish itself and to grow—*metabolism*. 2. To do its own particular work in the body economy—*special function*. 3. To respond to stimulation—*irritability*. 4. To move—*motion*. 5. To produce other cells—*reproduction*.

As would be expected, these properties, existing as they do in living cells, cannot always be sharply separated but frequently overlap. Thus, *e.g.*, in the muscle cell "motion" equals "special function."

In the simplest forms of animal life, where a single cell constitutes the entire individual, all of these functions are performed by the one cell. In all higher, that is, multicellular animals, there are not only many cells but many *kinds* of cells, and this morphological differentiation corresponds to a physiological differentiation, each group of cells developing along certain well-defined lines for the performance of its own special function.

1. **Metabolism.**—This term is used to designate those cellular activities which have to do with the nutrition of the cell. A cell is able (1) to take up from without substances suitable for its nutrition and to transform these into its own peculiar structure, and (2) to dispose of the waste products of intracellular activities. The former is known as *constructive metabolism* or *anabolism*, the latter as *destructive metabolism* or *katabolism*.

It is possible, for example, to watch an amœba send out projections (pseudopodia) (see p. 53) around an adjacent bit of food material. These projections coalescing finally completely enclose the food

material within the body of the amœba where it is acted upon by the protoplasm in such a way (digested) as to completely lose its identity and to finally become an integral part of the cytoplasm.

There is normally maintained within the cell a state of equilibrium between this constructive and destructive metabolism, between the intake of food on the one hand and the outflow of material products or of energy on the other. Stated as an equation, intake = outgo. Any marked + or − on one side of the equation without corresponding + or − on the other side must disturb this equilibrium and must result in physical changes within the cell. Thus any marked + in intake without corresponding + in outgo must result in growth of the cell, while any + in outgo without corresponding + in intake must tend toward diminution in bulk of cell and final destruction.

Associated with metabolism and growth is the phenomenon of differentiation. In a unicellular animal, or in such cells as leucocytes and ova, growth takes place uniformly in all directions. Even in such cells, however, modifications of internal structure occur, and in the vast majority of the many kinds of cells which make up the adult body a wide differentiation from the primitive type has taken place. This differentiation results from qualities inherent in the fertilized ovum and its early progeny, or from environmental influences, or usually both. Thus groups of cells are formed, the cells of one group differing from those of another, each to follow out its own particular line of development and to assume its own peculiar form and function in the adult organism.

The life-length of cells varies. Some cells, for example, some of those of the central nervous system, probably live throughout the life of the individual. At least there is good clinical evidence that once destroyed they are never replaced. Other cells, such for example as blood cells and many epithelial cells, are constantly wearing out and being replaced by new cells.

2. **Special Function.**—This is the special work which it is the part of the cell to perform. It varies greatly for different cells. Some cells, as, *e.g.*, the surface cells of the skin, appear to act mainly as protection for more delicate underlying structures. Other cells—gland cells—in addition to maintaining their own nutrition, produce specific substances (secretions), which are of great importance to the body as a whole. Still other cells, *e.g.*, nerve cells and muscle cells, have the power to store up their food substances in such a way as to

make them available in the form of energy. This appears to be accomplished by the building up within the cell of highly complex and, consequently, unstable molecular combinations. By reduction of these unstable combinations, molecules of greater stability and less complexity are formed. This results in the transformation of potential into kinetic energy, and the expenditure of this energy is expressed in function.

3. **Irritability** is that property which enables a cell to respond to external stimuli. Cells vary in respect to their irritability, the most markedly irritable cells in higher animals being those of the neuro-muscular mechanism. Stimulation may be mechanical, electrical, thermal, chemical, etc. The response of the cell to certain forms of chemical stimulation is known as *chemotaxis*. Some substances attract cells (positive chemotaxis); others repel cells (negative chemotaxis). Stimuli other than chemical possess similar properties, as indicated by the terms thermotaxis, galvanotaxis, etc. Some cells are so specialized as to react only to certain kinds of stimulation, *e.g.*, the retinal cells only to light stimuli.

4. **Motion.**—This is dependent wholly upon the protoplasm of the cell, and is exhibited in several somewhat different forms.

(*a*) *Amœboid Movement.* This consists in the pushing outward by the cell of processes (pseudopodia). These may be retracted or may draw the cell after them. In this way the cell may change both its shape and position (Fig. 6). While possessed by many animal cells, this property of amœboid movement is most marked in such

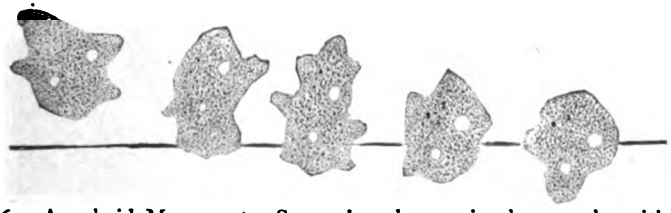

FIG. 6.—Amœboid Movement. Successive changes in shape and position of fresh-water amœba.

cells as the leucocytes or white blood cells. By their amœboid movements these cells are able to pass out of the blood vessels and as so-called "wandering cells" to circulate in the tissues. By means of their pseudopodia they can also surround tiny objects—granules, bacteria, etc., and sometimes digest or destroy them. Such cells are known as *phagocytes* and the phenomenon as *phagocytosis*. They

play an extremely important rôle in the body economy both in health and disease.

(*b*) ***Protoplasmic Movement.*** This occurs wholly within the lim-

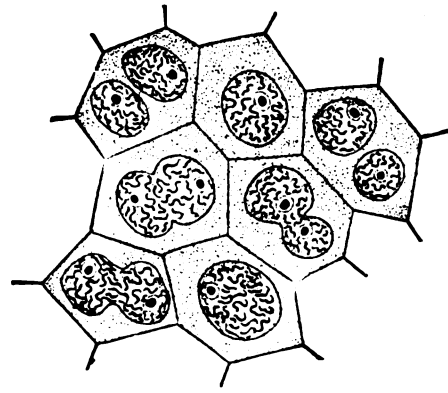

FIG. 7.—Epithelial cells from ovary of cockroach, showing nuclei dividing amitotically. (Wheeler.)

its of the cell, changing neither its shape nor position. It occurs in both plant and animal cells, and consists of a sort of circulation or "streaming" of the protoplasm. It is evidenced by the movement of

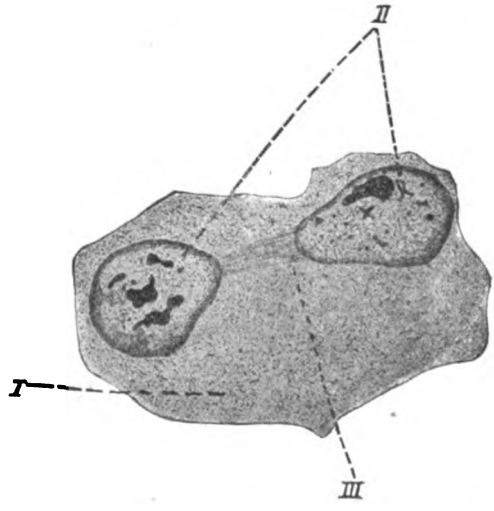

FIG. 8.—Epithelial cell from bladder showing amitotic division of its nucleus. (Nemiloff.) *I*, Cytoplasm; *II*, two daughter nuclei; *III*, fibrils uniting daughter nuclei.

minute granules present in the protoplasm, by changes in the position of the nucleus, etc.

(*c*) *Ciliary Movement.* This is the whipping motion possessed by little hair-like processes called cilia, which project from the surfaces of some cells.

Certain cells which are specialized for the particular purpose of motion as, *e.g.*, muscle cells, possess such powers of contraction that they are able to move not only themselves but other parts with which they are connected. This power of contractility is dependent upon the spongioplasm, the hyaloplasm playing a more passive rôle. In muscle cells the highly developed contractile powers appear to be due to the excessive development and peculiar arrangement of the spongioplasm.

5. **Reproduction.**—The overthrow of the long-held biological fallacy of spontaneous generation was soon followed by the downfall of a similar theory regarding the origin of cells. We now know that cells are derived from cells, and that the vast number and complex of cells which together form the adult human body are all derived from a *single primitive cell*, the *ovum*.

Reproduction of cells takes place in two ways, by *direct cell division* or *amitosis*, and by *indirect cell division* or *mitosis*. In both amitosis and mitosis the division of the cell body is preceded by division of the nucleus.

Direct Cell-division—Amitosis (Figs. 7 and 8).—In this form of cell-division the nucleus divides into two daughter nuclei without any apparent preliminary changes in its structure. The division of the nucleus may or may not be followed by division of the cell body, in the latter case resulting in the formation of polynuclear cells. Until recently this form of cell-division was considered uncommon in higher animals where Flemming looked upon it as a degenerative phenomenon, usually associated with pathologic processes and tending toward death, rather than a normal method of cell-increase. Such strict limitation of amitosis to pathological conditions is probably not warranted. It is a common method of cell division in the protozoa and has been described in many animal species including vertebrates. It occurs especially in embryonic tissues and in other conditions of rapid growth. Amitosis and mitosis may occur simultaneously in the same tissue, in which case it is the smaller, less perfectly developed cell that more frequently divides amitotically. A change to a less favorable environment may cause cells dividing mitotically to undergo amitosis, the former method being resumed on their return to their former surroundings.

INDIRECT CELL-DIVISION.—MITOSIS (Figs. 11, 12).—This is the usual type of normal cell division. It may be observed in practically all rapidly growing tissues, that is in all growing plants and animals. It is probably the only type of cell division which occurs in the sex cell. In mitosis, as in amitosis the nucleus first undergoes division into two daughter nuclei and, soon after, the cytoplasm divides, thus resulting in the formation of two complete daughter cells. In mitosis, however, the division of both nucleus and cytoplasm occurs only after the nucleus and certain cytoplasmic structures have passed through characteristic and very complicated changes. These changes affect coincidently both nuclear and cytoplasmic structures and occur as a continuous process. It is more convenient, however, for the sake of clearness of description, to arbitrarily divide the series of changes into stages or phases, it being of course understood that the successive phases run the one over into the other without any distinct lines of demarkation. Thus we recognize in mitosis: (*a*) the *prophase;* (*b*) the *metaphase;* (*c*) the *anaphase;* (*d*) the *telophase.* The prophase is the stage of preparation on the part of the nucleus for division; the metaphase, the actual separation of the nuclear elements; the anaphase, the formation of the two daughter nuclei; the telophase, the reconstruction of the two daughter resting nuclei and the division of the cytoplasm.

(*a*) *The Prophase* (Fig. 9, *B*, *C*, *D*) is marked by the following changes, all of which are preparatory to the actual cell division to follow.

1. The centrosome, or more specifically, the centriole, if single, divides into two daughter centrioles. In most cells, however, which are in active mitosis, the centrosome is already double (diplosome) (Fig. 11, *A*), having undergone division as early, frequently, as the anaphase of the preceding mitosis.

Each daughter centriole is surrounded by a clear area, the *centrosphere.* Radiating from the centrosphere are delicate fibrils or rays, the *astral rays*, the whole constituting the *attraction sphere.* The two daughter centrioles, each surrounded by its attraction sphere now move further apart but remain connected by fine fibrils probably derived from the linin. These fibrils connecting the two centrosomes form a spindle-shaped figure known as the *central* or *achromatic spindle* (Fig. 11, *B*, *C*, *D*), while the entire figure consisting of the two centrioles surrounded by centrospheres, astral rays and connecting achromatic spindle constitute the *amphiaster* (Fig. 11, *D*).

2. During or immediately following the formation of the amphiaster, important changes take place in the nucleus. It increases in size and loses the reticular appearance of the resting nucleus, its chromatic elements becoming arranged in a long spireme-thread or in several shorter threads, the *closed skein* or *closed spireme*. This next

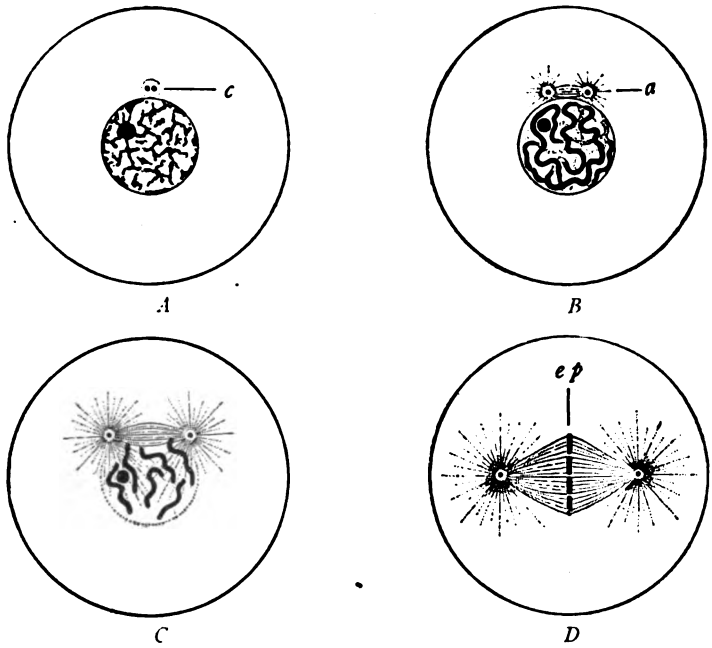

FIG. 9.—Diagrams of Successive Phases of Mitosis.

A, *Resting cell*, with reticular nucleus and true nucleolus; *c*, attraction sphere with two centrosomes.

B, *Early prophase*. Chromatin forming continuous thread—the spireme; nucleolus still present; *a*, amphiaster; the two centrosomes connected by fibrils of achromatic spindle.

C, *Later prophase*. Segmentation of spireme to form the chromosomes; achromatic spindle connecting centrosomes; polar rays; mantle fibres; fading of nuclear membrane.

D, *End of prophase*. Monaster—mitotic figure complete; *ep*, chromosomes arranged around equator of nucleus; fibrils of achromatic spindle connecting centrosomes; mantle fibres passing from centrosomes to chromosomes. (E. B. Wilson, "The Cell," The Macmillan Co.)

becomes thicker and more loosely arranged, thus forming the *open spireme*. That some chemical as well as morphological change has taken place in the transformation of the reticulum of the resting nucleus into the spireme is shown by the marked increase in staining intensity, the spireme taking a much darker stain than the reticulum.

Late in the prophase the nucleolus and nuclear membrane disappear. The cytoplasm and karyoplasm then become continuous and both spireme and amphiaster lie free in the general cell protoplasm (Fig. 9, *C*).

3. The spireme next breaks up into a number of segments—*chromosomes* (Fig. 9, *C*). These are usually rod-shaped at first, later they may become U's or V's or may even become spheroidal. The chromosomes now arrange themselves regularly around the equator of the nucleus, their closed ends being directed centrally.

The details of the transformation of the reticulum into chromosomes vary. In some cases a single spireme-thread is formed. In others the spireme-thread first splits longitudinally into two threads before segmenting into chromosomes. Again the spireme-thread may show segmentation into chromosomes from the beginning. In still other cases the chromosomes apparently form directly from the reticulum without the intervention of the spireme stage. It is most important to note that while the number of chromosomes varies for different species of plants and animals, it is *fixed and characteristic for a given species.* Thus in Ascaris megalocephala (much used for study on account of its small number of chromosomes) the number is 4, in the mouse 24, in man, it has been variously estimated.[1] This means that whenever mitosis occurs in Ascaris, the spireme-thread invariably segments into 4 chromosomes. Chromosomes and amphiaster now constitute the *mitotic figure* which at this stage is known as the *monaster*, its formation marking the end of the prophase.

(*b*) *Metaphase* (Fig. 10, *E*). This marks the beginning of actual division of the nucleus. Each chromosome splits longitudinally (longitudinal cleavage) into two *daughter chromosomes*, each containing exactly one-half the chromatin of the parent chromosome. U- and V-shaped chromosomes always begin to split at the apex, from which point the separation extends to the open ends.

(*c*) *Anaphase* (Fig. 10, *F*, *G*).—An equal number of daughter chromosomes now travels along the fibrils of the achromatic spindle—apparently under the influence of the mantle fibres—toward each

[1] Guyer (Biol. Bul. Marine Biol. Lab. Wood's Hole, Mass., Vol. XIX) describes twenty-two chromosomes in human spermatogonia, of which two are "accessory". Apparently half the resulting spermatids contain ten chromosomes, the other half twelve, two of which are accessory. Guyer concludes that the probable somatic number for the human male is twenty-two, for the female twenty-four. Winiwarter (Arch. de Biol. T. 27, 1912) describes forty-seven chromosomes as somatic for the white human male, forty-eight for the female, with two kinds of spermatozoa, one with twenty-three, the other with twenty-four chromosomes.

daughter centrosome around which they become grouped. In this way are formed two *daughter stars*, the mitotic figure being known at this stage as the *diaster* (Fig. 10, *G*). These daughter stars are at first connected by the fibrils of the achromatic spindle. In this stage may also occur beginning division of the cell body. In actively dividing cells each centrosome frequently undergoes division at this stage, resulting in four centrosomes to the cell.

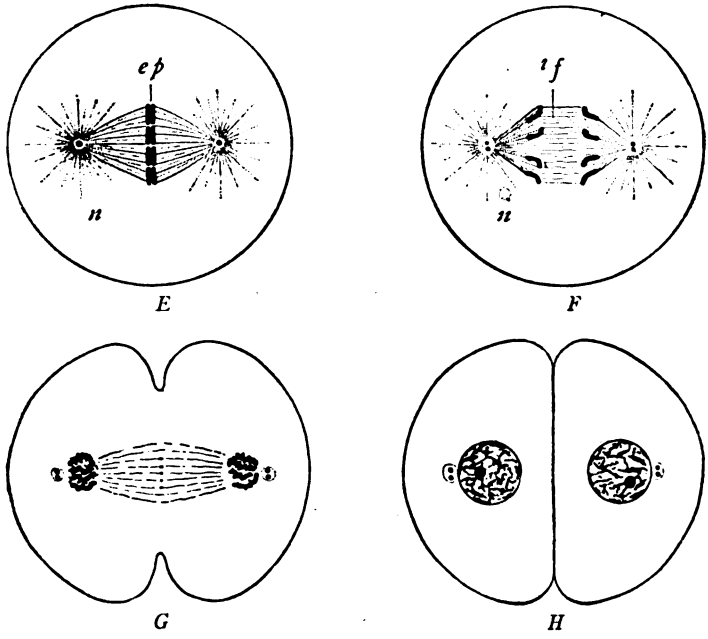

FIG. 10.—Diagrams of Successive Phases of Mitosis.

E, *Metaphase.* Longitudinal cleavage; splitting of chromosomes to form daughter chromosomes, *ep*; *n*, cast-off nucleolus.

F, *Anaphase.* Daughter chromosomes passing along fibrils of acromatic spindle toward centrosomes; division of centrosomes; *if*, interzonal fibres or central spindle.

G, *Late anaphase.* Formation of diaster; beginning division of cell body.

H, *Telophase.* Reappearance of nuclear membrane and nucleolus; two complete daughter cells, each containing a resting nucleus. (E. B. Wilson, "The Cell," The Macmillan Co.)

(*d*) *Telophase* (Fig. 10, *H*).—This is marked by division of the cell protoplasm and consists of a cycle of changes, by means of which each group of daughter chromosomes is transformed into the chromatin network of a *resting nucleus*. These changes are the same as those described in the prophase, but occur in the reverse order, the chromosomes uniting to form the spireme, and the spireme becoming transformed into the nuclear network. The result is the formation

of two *daughter cells*. The nuclear membrane reappears, as does also the nucleolus. Each daughter cell is thus provided with a resting nucleus. The fact that the number of chromosomes which enter into the formation of the chromatic reticulum of the nucleus of each daughter cell is the same as the number into which the spireme of the parent cell divided, has suggested the hypothesis that the chromosomes maintain their identity even during the resting stage.

The time required for the mitotic process is usually from one-half to three-quarters of an hour. Exceptionally it is prolonged to several hours.

The rôle which each part of the cell plays in the vital activities of the cell, and the physiological correlation of these various parts, have been but partially determined. Experiments upon some of the protozoa show that if the cell be divided into two parts, one part containing the nucleus, the other part non-nucleated, the behavior of the two parts is very different. The part containing the nucleus soon again becomes a complete cell with all the properties which the cell originally possessed. The non-nucleated part responds somewhat to stimulation, is capable of some movement, makes some feeble attempts at digestion, but is incapable of secretion, of reconstructing the complete cell, of reproduction, and soon dies. Even when a small part of the nucleus remains in the cut-off piece of cytoplasm reconstruction may take place. On the other hand a nucleus completely deprived of its cytoplasm is incapable of reconstructing the cell. In Infusoria each cell has two nuclei, a macro-nucleus and a micro-nucleus, the former connected with nutrition, the latter with reproduction. These facts together with the behavior of the nucleus during the ingestion of food, during secretion, and even during motion, warrant the belief that while in all probability most of the actual work of the cell takes place in the cytoplasm, the nucleus exerts a more or less controlling influence over all cell activities.

The parts which the several cell structures play in mitosis have been the subjects of much study and are as yet not fully determined.

As to the behavior of the chromatic portion of the mitotic figure little doubt exists. It originates in the chromatic portion of the nuclear reticulum of the parent cell and its destination is the chromatic portion of the reticulum of the daughter cells.

The rôle of the centrosome in mitosis is not so clear. It has been called the "dynamic centre" of the cell because in most cases it appears to be the active agent in initiating and probably further directing the mitotic process. The origin of the astral fibres is not always the same. In Infusoria the centrosome is found within the nucleus and both amphiaster and chromosomes are of nuclear origin. In some of the higher plants the amphiaster is derived wholly from the spongioplasm. In the egg cells of Echinoderm, part of the amphiaster (central spindle) is of nuclear, the remainder (asters) of cytoplasmic origin. That the centrosome is not always the active factor in mitosis is shown by the

fact that in the higher plants no centrosome can be demonstrated during any stage of mitosis, and also that in some cases the chromosomes divide without previous division of the centrosome. Between mitotic periods the centrosome with or without its aster may remain as an integral part of the resting cell. It may, on the other hand, entirely disappear during the resting stage.

Branca calls attention to the fact that the centrosome is an organ of no "constancy, permanence, or specificity," (1) that in certain cells it is impossible to demonstrate a centrosome at any time; (2) that when a centrosome has been demonstrated for a certain type of cell, it cannot always be found even in that type of cell; (3) that certain parts of the centrosome, the rays, are cytoplasmic, while another part, the centriole, reacts like nuclear material (chromatin). He concludes that the centrosome is a portion of the protoplasm "temporarily differentiated for a specific function; not unlike the basal filaments which appear temporarily in gland cells when they become active, both being functional forms of protoplasm which can succeed each other as the cell changes the character of its function."

It is through the above-described process of cell-division that new cells are produced to replace those worn out as a result of their labors or destroyed by injury. It is through the same process that the vast number of cells which make up the adult body are developed from one original cell—the ovum. Such powers of evolution are not, however, inherent in the ovum itself, but, in sexual reproduction, are acquired only after its union with germinal elements from the male. This union of male and female germinal elements is known as *fertilization of the ovum.*

Fertilization of the Ovum

Prior to and in preparation for fertilization, both male and female cells must pass through certain changes. These are known as *maturation of the spermatozoön* on the male side (p. 350) and of the *ovum* on the female (p. 363).

The *spermatozoön* (Fig. 11) is developed from a cell of the seminiferous tubule of the testis. The nucleus of this cell so divides its chromosomes that *each spermatozoön contains just one-half the number of chromosomes characteristic of cells of the species.* These are contained in the *head* of the spermatozoön, which thus represents the *nucleus* of the male sexual cell, the *middle piece* probably containing the *centrosome,* the tail piece the *remains of the protoplasm.*

The nucleus of the *ovum* or *germinal vesicle* also passes through a series of changes by which it loses one-half its chromosomes. The germinal vesicle or nucleus of the ovum first undergoes mitotic

division with the usual longitudinal cleavage of its chromosomes and the formation of *two daughter nuclei*. One of these and its centrosome are extruded from the cell as the *first polar body*. The remaining nucleus and centrosome again divide mitotically, only in this second division, instead of the usual longitudinal cleavage of chromosomes, by which each daughter nucleus is provided with the same number of chromosomes as the mother nucleus, the chromosomes simply separate, *one-half going to each daughter nucleus*. One of the daughter nuclei and its centrosome are now extruded as the *second polar body*. The polar bodies ultimately disappear, as does also the centrosome remaining within the egg. This leaves in the now matured ovum a single nucleus, which is known as the *female pronucleus*, and which *contains one-half the number of chromosomes characteristic of cells of the species*.

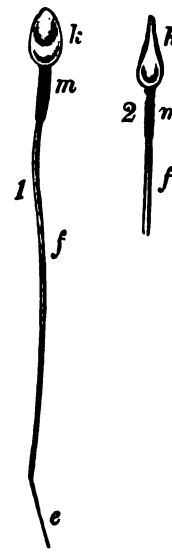

FIG. 11.—Human Spermatozoa. (After Retzius.) 1, Head seen on flat; 2, head seen on edge; *k*, head; *m*, body; *f*, tail; *e*, end piece.

During this process in some animals—in others after its completion—the spermatozoön enters the ovum. The head of the spermatozoön becomes the *male pronucleus*, the middle piece becomes a *centrosome*, while the tail is, in some instances at least, left behind as the spermatozoön enters the egg. The chromatin of the male pronucleus next becomes arranged as chromosomes. Male and female pronuclei now lose their limiting membranes and approach each other, their chromosomes intermingling. *As each pronucleus contained one-half the number, the monaster thus formed contains the full number of chromosomes characteristic of the species.* Meanwhile the male centrosome, formed from the body of the spermatozoön, divides into *two daughter centrosomes*. These with their radiating fibrils have the same arrangement relative to the monaster of mingled male and female chromosomes, already described under mitosis. By longitudinal cleavage of these chromosomes, as in ordinary mitosis, two sets of daughter chromosomes are formed. Each set passes along the filaments of the achromatic spindle to its centrosome. Thus is formed the *diaster*. By continuation of the mitotic process two new nuclei are formed, each nucleus containing the number of chromosomes characteristic of the species, and each being made up *equally of male and female chromosome elements*. Thus

occurs the first division of the fertilized ovum into two daughter cells. By similar mitotic processes these two cells become four, the four cells become eight, etc. This is known as *segmentation of the ovum*.

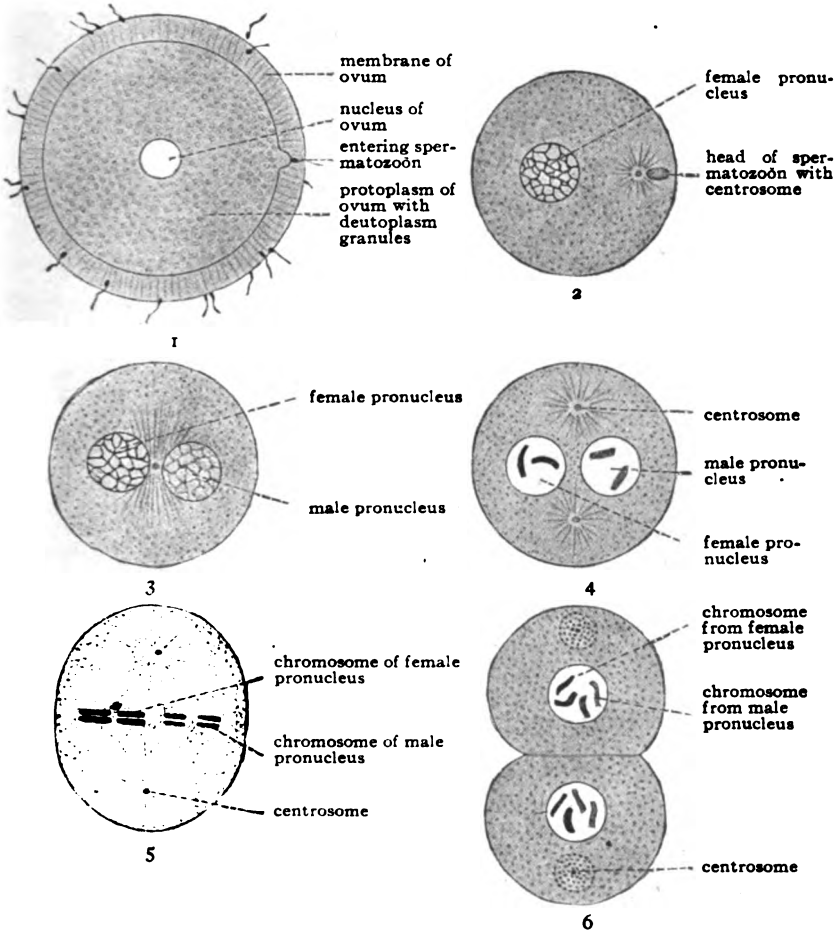

FIG. 12.—Diagram of Fertilization of the Ovum. (The somatic number of chromosomes being four.) (From Bohm and von Davidoff, after Boveri.)

1, Ovum surrounded by spermatozoa, only one of which is in the act of penetration. Toward the latter the protoplasm of the ovum sends out a process; 2, Head of spermatozoön has entered ovum, its body becoming the male centrosome, its tail having disappeared; 3, The head of spermatozoön has become the male pronucleus. Male and female pronuclei approach each other. Between them is the (male) centrosome; 4, The spiremes of male and female pronuclei have each formed two chromosomes. The centrosome has divided; 5, Male and female chromosomes have mingled and by longitudinal cleavage (see Mitosis, p. 54,b) have become eight. These become arranged in the equatorial plane of the ovum. Mantle fibres extend from centrosomes to chromosomes; 6, Division of the ovum; two daughter cells, each containing a daughter nucleus. Each daughter nucleus contains four chromosomes, two derived from each pronucleus.

The earlier generations of these cells are morphologically alike and are known as *blastomeres*. Soon, however, these cells become spread out and at the same time differentiated into *two primary*

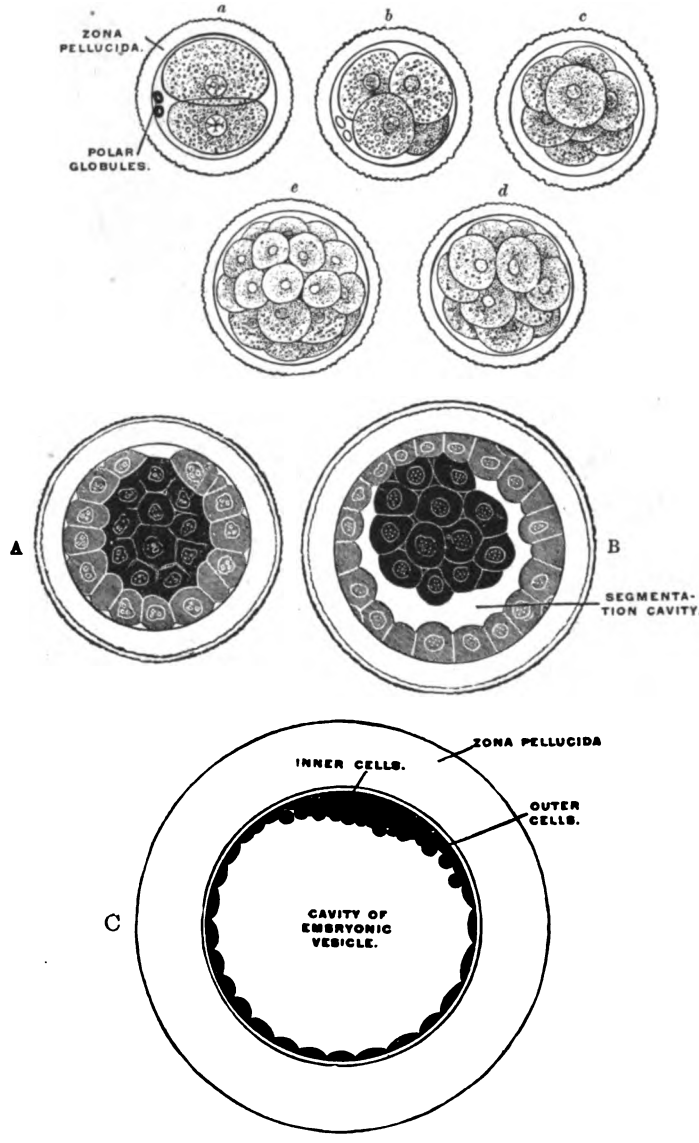

FIG. 13.—Segmentation of the Ovum. (From Gerrish, after van Beneden.)

a, Two-cell stage resulting from first division of fertilized ovum; *b*, four-cell stage; *c*, *d*, *e*, later stages. *A*, Differentiation into inner and outer cells; *B*, Formation of segmentation cavity; *C*, Embryonic vesicle, showing two primary germ layers. *Outer cells*, ectoderm; *inner cells*, entoderm.

germ layers. The outer of these is known as the *ectoderm* or *epiblast*, the inner as the *entoderm* or *hypoblast*. Between these two layers and derived from them a third layer is formed, the *mesoderm* or *mesoblast*. These three layers constitute the *blastoderm*.

As to what determines and controls fertilization, comparatively little is known. As in ordinary mitosis, the origin of the centrosome is obscure. In some forms, at least, the centrosome of the spermatid enters into the formation of the middle piece of the spermatozoön. The male centrosome thus enters the ovum. It is also known that in some eggs the egg-centrosome disappears soon after the extrusion of the second polar body, and that the centrosome of the fertilized egg develops in close relation to the middle piece of the spermatozoön. These facts point to the male centrosome as the centrosome of fertilization.

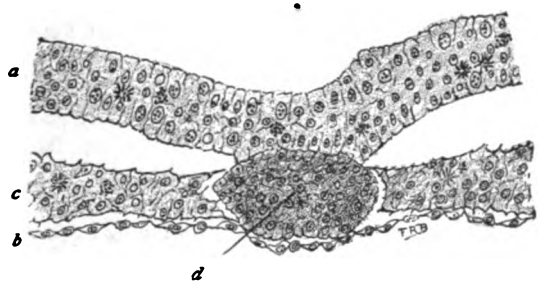

FIG. 14.—The Two Primary Germ Layers; from transverse section through primitive groove of a chick of 27 hours' incubation. *a*, Ectoderm (outer germ layer); *b*, entoderm (inner germ layer); *c*, mesoderm (middle germ layer); *d*, anlage of notochord.

The ovum and spermatozoön are apparently brought together by a definite attraction on the part of the ovum toward the spermatozoön. The nature of this attraction is unknown. It is possibly chemical, and is exerted only between ova and spermatozoa of the same species. This has been proved for lower forms by mixing ova of one species and spermatozoa from several species in an inert medium when only spermatozoa of the same species will attach themselves to the ova. That the attractive force lies in the cytoplasm is shown by the fact that small pieces of the egg protoplasm free from nuclear elements will exert sufficient powers to cause spermatozoa to enter them.

As to the point of entrance of the spermatozoön, some eggs may be entered at any point, others are permeable at but one point.

One spermatozoön only is required for fertilization, and when this spermatozoön has entered, the egg apparently loses its power of attracting spermatozoa, or else develops some actual defense against further entrance of spermatozoa.

TECHNIC

1. Fresh cells may be studied by gently scraping the surface of the tongue, transferring the mucus thus obtained to a glass slide and covering with a coverglass.

2. Red blood cells from the frog are prepared as follows: After killing the

frog the heart is opened and the blood allowed to drop into a tube containing Hayem's fluid (sodium chlorid 1 gm., sodium sulphate 5 gm., mercuric chlorid 0.5 gm., distilled water 100 c.c.). After shaking, the cells are allowed to settle for from twelve to twenty-four hours. The fixative is then replaced by water, the tube again shaken, the cells allowed to settle, and the water is replaced with 80 per-cent. alcohol tinged with iodin. After from twelve to twenty-four hours the alcohol is decanted and the tube partly filled with alum-carmine solution (page 22). About twenty-four hours usually suffices for staining the nuclei. The alum-carmine is then poured off and the cells well shaken in water. After settling, the water is replaced by glycerin, to which a small amount of picric acid has been added. In this the cells may be permanently preserved. The nuclei are stained red by the carmine, the cytoplasm yellow by the picric acid.

3. Surface cells from the mucous membrane of the bladder. The bladder is removed from a recently killed animal, pinned out mucous membrane side up on a piece of cork and floated, specimen side down, on equal parts Müller's fluid and Ranvier's alcohol (technic, 5, p. 7, and *a*, p. 4) for from twenty-four to forty-eight hours. The specimen is then washed in water and the cells removed by gently scraping the surface. These may then be stained and preserved in the same manner as the preceding. Cells from the different layers should be studied; also the appearance of the large surface cells seen on flat and on edge, showing pitting of under surface by cells beneath.

4. Amœboid movement may be studied by watching fresh-water amœbæ or white blood cells. A drop of water containing amœbæ is placed on a slide, covered, and a brush moistened with oil is passed around the cover to prevent evaporation. The activity of the amœbæ may be increased by slightly raising the temperature. An apparatus known as the warm stage is convenient for demonstrating amœboid movement. A drop of blood, human, or better from one of the cold-blooded animals, may be used for the study of amœboid movement in the white blood cells. It should be placed on a slide, covered, and immediately examined on the warm stage.

5. Ciliary movement is conveniently studied by removing a small piece of the gill of an oyster or mussel, teasing it gently in a drop of normal salt solution and covering. The cilia being very long, their motion may be easily studied, especially after it has become slow from loss of vitality.

6. Mitosis. The salamander tadpole and the newt are classical subjects for the study of cell-division. The female salamander is usually full of embryo tadpoles in January and February. The embryos are removed and fixed in Flemming's fluid (technic 8, p. 8), after which they may be preserved in equal parts of alcohol, glycerin, and water. Mitotic figures may be found in almost any of the tissues. Pieces of epidermis from the end of the tail, the parietal peritoneum, and bits of the gills are especially satisfactory. If the newt's tail is used, it should be fixed in the same manner, embedded in paraffin and cut into thin sections. These are stained with Heidenhain's hæmatoxylin, (technic 3, p. 21.)

Certain vegetable tissues, such as the end roots of a young, rapidly growing onion or magnolia buds, are excellent for the study of mitosis. The technic is the same as for animal tissues.

General References for Further Study of the Cell

Branca, A.: Histologie, Paris, 1906.

Conklin, E. G.: Karyokinesis and Cytokinesis. *Jour. Acad. Nat. Sci. of Phila.*, vol. xii, 1902.

Cowdry: Contributions to Embryology. Pub. Carnegie Ins., Washington, vol. viii, 1918.

Harper, E. H.: The Fertilization and Early Development of the Pigeon's Egg. *Amer. Jour. of Anat.*, vol. iii, No. 4, 1904.

Hertwig, O.: Die Zelle und die Gewebe, 1898.

Hertwig, R.: Eirife, Befruchtung u. Furchungsprozess. In Hertwig's *Handbuch d. vergleich. u. experiment. Entwickelungslehre der Wirbeltiere*, Bd. I, Teil I, 1903.

Lillie, F. R.: A Contribution toward an Experimental Analysis of the Karyokinetic Figure. *Science*, New Series, vol. xxvii, 1908.

McMurrich: The Development of the Human body.

Minot: Human Embryology. A Laboratory Text-book of Embryology.

Sobotta, J.: Die Befruchtung u. Furchung des Eies der Maus. *Arch. f. mik. Anat.*, Bd. xlv, 1895.

Wilson, E. B.: The Cell in Development and Inheritance, 2d ed., 1900.

PART III

THE TISSUES

CHAPTER V

HISTOGENESIS—CLASSIFICATION

ECTODERM, mesoderm, and entoderm (see page 63) are known as the primary layers of the blastoderm. They differ from one another not only in position, but also in the structural characteristics of their cells. The separation of the blastomeres into these three layers represents the first morphological differentiation of the cells of the developing embryo. By further and constantly increasing differentiation are developed from these three primary layers all tissues and organs, each layer giving rise to its own special group of tissues. The tissue derivations from the primary layers of the blastoderm are as follows:

Ectoderm.—(1) Epithelium of skin and its appendages—hair, nails, sweat, sebaceous and mammary glands, including smooth muscle of sweat glands.

(2) Epithelium of mouth and anus, of glands opening into mouth, taste buds, and enamel of teeth.

(3) Epithelium of nose and of glands and cavities connected with nose.

(4) Epithelium of external auditory canal and of membranous labyrinth.

(5) Epithelium of anterior surface of cornea, of conjunctiva, of crystalline lens, of lacrymal gland, of lacrymal canal, and of pars nervosa, pars ciliaris and pars iridica retinæ, also muscle tissue of sphincter and dilator pupillæ.

(6) Epithelium of male urethra, except prostatic portion.

(7) Epithelium of medulla of suprarenals, of pineal bodies, of posterior portion of pituitary body and of a few other small ductless glands.

(8) Entire nervous system, including neuroglia and linings of central canal and ventricles of brain.

Entoderm.—(1) Epithelium of digestive tract (excepting mouth and its glands and anus), and of glands connected with digestive tract including liver, gall bladder and pancreas.

(2) Epithelium of respiratory tract, except nostrils, and of its glands.

(3) Epithelium of bladder except the trigonum, of female urethra, of vaginal vestibule and glands of Bartholin, of prostatic portion of male urethra, prostatic glands and glands of Cowper.

(4) Epithelium of tympanum and of Eustachian tube.

(5) Epithelium of thyreoid and parathyreoid, reticulum of thymus, and Hassall's corpuscles.

Mesoderm.—(1) All the connective or supporting tissues except neuroglia.

(2) Lymphatic organs with the exception of Hassall's corpuscles and reticulum of the thymus.

(3) Blood cells and bone-marrow.

(4) Striated, cardiac and smooth muscle (with the possible exception of smooth muscle of sweat glands and of iris).

(5) Endothelium lining blood-vessels and lymphatics.

(6) Mesothelium lining serous membranes—pleura, pericardium, peritoneum, joints, bursæ, tendon sheaths and chambers of the eye.

(7) Epithelium of genito-urinary system with the exception of the urethra and a large part of the bladder.

(8) Epithelium of the suprarenal cortex.

In all but the lowest forms of animal life the body consists of an orderly arrangement of many kinds of *cells*. From the cells is developed a substance which lies outside the cells and is known as *intercellular substance*. This may be small in amount, just sufficient to unite the cells, as in epithelium, or it may so predominate as to determine the character of the tissue, as in some forms of connective tissue. It does not always completely separate the cells which may be connected across the intercellular substance by extensions of their protoplasm, as in the "intercellular bridges" of epithelium or the anastomosing processes of connective-tissue cells. Less commonly cells are united in such a multinuclear continuum that their boundaries are almost or wholly lost. Such a structure is known as a *syncytium*. The association of a particular type of cell with a particular type of intercellular substance is known as a *tissue*. The character of a tissue depends upon the character of its cells, of its intercellular substance, and their relations to each other. Further differentiation of cells and intercellular substance within a particular tissue gives rise to various sub-groups of the tissue. The association of tissues to form a definite structure for the performance of a particular function is known as an *organ*. The physiological association of organs constitutes a *system*. The fact that chemical changes take place in intercellular substance as well as in cells has led to the suggestion that the intercellular substance is endowed with the same

vital properties as the cell. The consensus of opinion is, however, that the intercellular substance is derived originally from the cell, is replenished by the cell, is dependent upon the cell for its nourishment, and is incapable of activity or existence apart from the cell.

A scientific classification of the tissues is at present impossible.

The foregoing list of tissue derivations shows how unsatisfactory is any attempt at classification on the basis of histogenesis, many tissues which are morphologically similar being derived from two or even all three of the blastodermic layers.

The following is the usual classification of adult tissues: (1) Epithelial tissues; (2) connective tissues; (3) blood; (4) muscle tissue; (5) nerve tissue.

Of these, epithelium and connective tissue may be regarded as the more elementary tissues, being common to both plants and animals. Blood is sometimes classified among the connective tissues. Muscle and nerve are the most highly specialized tissues and are peculiar to animals. While the individuality of the tissues classified is recognized, the physiological necessities of nutrition, innervation, etc., scarcely permit the existence of any one tissue alone by itself. Thus blood and blood vessels permeate almost all tissues except epithelium, while the latter is everywhere traversed by elements of nerve tissue.

CHAPTER VI

EPITHELIUM (INCLUDING MESOTHELIUM AND ENDOTHELIUM)

General Characteristics.—Epithelium is derived from all three germ layers. In general it covers surfaces and lines cavities and diverticula from them, for example, the duct glands. Thus located, it serves for protection, takes part in the formation of neuroepithelial end organs for the reception of stimuli, and is the active agent in the elaboration of various secretions and excretions. Epithelium consists almost wholly of cells. The intercellular substance is merely sufficient to attach the cells to one another and is, consequently known as *cement substance.* A characteristic of this cement substance is its reaction to silver nitrate (Figs. 16, 28, 29). In some instances the protoplasm of adjacent epithelial cells is seen to be even more

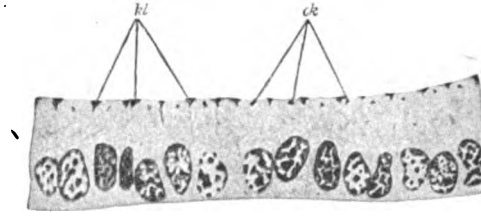

FIG. 15.—Simple Cylindrical Epithelium from Uterus of Monkey—Iron-alum-hæmatoxylin Stain. (Krause.) *kl*, cement wedges separating the free ends of the cells; *ck*, centrioles.

closely associated, the intervening cement substance being bridged over by delicate processes of protoplasm which pass from one cell to another and are known as "*intercellular bridges*" (see Fig. 20, p. 77). It seems probable that the minute spaces between the processes serve as channels for the passage of food (lymph) to the cells. Reference to Figs. 159 and 191 shows that a precipitation of silver also occurs in some tubules filled with glandular secretions. It is possible that the so-called intercellular cement may be of the nature of an intercellular lymph. The surface cells of epithelium are united by continuous cement substance in larger amount (Fig. 15), in which there are apparently no spaces. In this way escape of lymph is prevented.

Epithelial cells vary in size and shape, the element of pressure being a frequent determining factor. They are often extremely elastic, allowing great changes in shape and relation. Thus the epithelium of the collapsed bladder is thick and the cells columnar, but as the bladder fills, the cells become flatter until in complete distention the epithelium is thin and consists of flattened cells. Their protoplasm may be clear, finely or coarsely granular, or pigmented. Each cell usually contains a single well-defined nucleus. Two or more nuclei are sometimes present. Some epithelial cells are, when fully matured, non-nucleated, *e.g.*, respiratory epithelium of lung.

When epithelium rests upon connective tissue, it is usually separated from the latter by a thin, apparently homogeneous membrane known as the *basal membrane* or *membrana propria.* Authorities differ as to whether this membrane is of connective-tissue or of epithelial origin.

Surface epithelial cells frequently have thickened free borders or *cuticulæ*, which unite to form a continuous membrane, the *cuticular membrane.* Striations extend from the cytoplasm into the cuticulæ. A still greater specialization of the surface of the cell is seen in the ciliated cell. In this cell fine hair-like projections—*cilia*—extend from the surface of the cell.

Some epithelial cells show important changes dependent upon their functional activities. An example of this is seen in the mucous cell in which there is a transformation of the greater part of the cytoplasm into, or its replacement by, mucus.

Epithelia are devoid, as a rule, of both blood- and lymph-vessels. An exception to this is the stria vascularis of the cochlea. Nerves, on the other hand, are abundant.

Classification.—Epithelia may be classified according to shape and arrangement of cells as follows:

(1) Simple Epithelium.—(*a*) Squamous; (*b*) columnar.

(2) Stratified Epithelium.—(*a*) Squamous; (*b*) columnar.

(3) Mesothelium and Endothelium.

Specializations of the above-mentioned types are known as: (*a*) Ciliated epithelium; (*b*) pigmented epithelium: (*c*) glandular epithelium; (*d*) neuro-epithelium.

Pigment may occur in any type of epithelium. Cilia are found only in the simple columnar and stratified columnar forms.

Simple Epithelium

In simple epithelium the cells are arranged in a single layer.

(*a*) *Simple squamous epithelium* consists of flat scale-like cells which are united by an extremely small amount of intercellular sub-

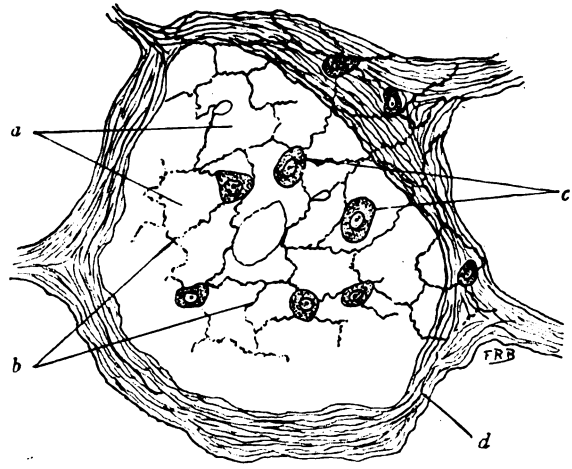

FIG. 16.—From Section of Cat's Lung, stained with silver nitrate, showing outlines of the Simple Squamous Epithelium Lining the Air Vesicle. *a*, Two epithelial cells; *b*, the wavy stained intercellular substance; *c*, fœtal cells; *d*, connective tissue.

stance. The edges of the cells are smooth or serrated. Seen on flat, they present the appearance of a mosaic. Seen on edge, the cells appear fusiform, being thickest at the center, where the nucleus

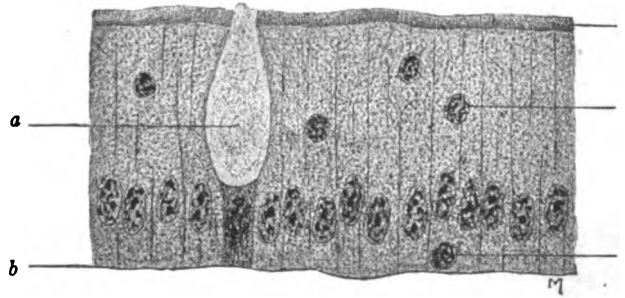

FIG. 17.—Simple Columnar Epithelium from the Human Small Intestine. *a*, Mucous (goblet) cell; *b*, basement membrane; *c*, thickened free border (cuticula); *d*, leucocyte among the epithelial cells; *e*, replacing cell.

is situated, and thinning out toward the periphery. Simple squamous epithelium has but a limited distribution in man. It occurs in the lungs as non-nucleated respiratory epithelium, in Bowman's

capsule of the renal corpuscle, in the descending arm of Henle's loop of the uriniferous tubule, in the retina in the form of pigmented cells, and on the posterior surface of the anterior lens capsule.

(*b*) ***Simple columnar epithelium*** consists of a single layer of elongated cells. The bases of the cells are usually separated from the underlying connective tissue by a basement membrane. The nucleus is, as a rule, in the deeper part of the cell, near the basement membrane. Many of these cells have prominent thickened free borders or cuticulæ. This form of epithelium is often ciliated. The height of the cell varies greatly, there being all gradations from ***high columnar*** to ***low cuboidal.*** Simple columnar epithelium lines the gastro-intestinal canal, the uriniferous tubule (excepting the descending arm of Henle's loop), simple tubular glands, the ducts of some compound tubular glands, the smaller bronchi, the membranous and penile portions of the male urethra, and the gall-bladder.

In simple columnar epithelium, in addition to the single row of epithelial cells, there are found lying near the basement membrane, between the bases of the epithelial cells, small, spherical, or irregular cells, which frequently show mitosis and which are known as *replacing cells*. They appear to develop into columnar epithelial cells as they are needed to replace older cells. The so-called *pseudo-stratified epithelium* is a form of simple columnar epithelium, in which, from crowding of the cells, the nuclei have come to lie at different levels, thus giving the appearance of stratification (Fig. 18).

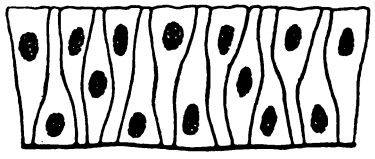

FIG. 18.—Diagram of Pseudostratified Epithelium, showing Nuclei situated at Different Levels.

Stratified Epithelium

In stratified epithelium the cells are arranged in more than one layer.

(*a*) ***Stratified squamous epithelium*** is developed from simple epithelium by the growth of new cells between the old cells and the underlying connective tissue. It consists of several layers of cells. The number of layers varies but the shape and arrangement of the cells are quite characteristic. The cells of the deepest layer, those lying on the basement membrane which separates the epithelium

from the underlying connective tissue are usually small regularly placed cuboidal cells of uniform size which in tangential sections appear as a distinct row of cells. Passing toward the surface the cells, still small, become irregular in shape and arrangement, then larger and as the surface is approached flatter, until the typical squamous surface cells are reached. The deeper cells are the softer younger cells and in the layers just above the basal layer mitotic figures are frequent. Here also are often found very distinct protoplasmic intercellular connections ("intercellular bridges," (Fig. 20), see also p. 72). Extensions of cell protoplasm similar to the intercellular bridges have been described as passing from the deepest cells toward or into the underlying connective tissue. The inter-

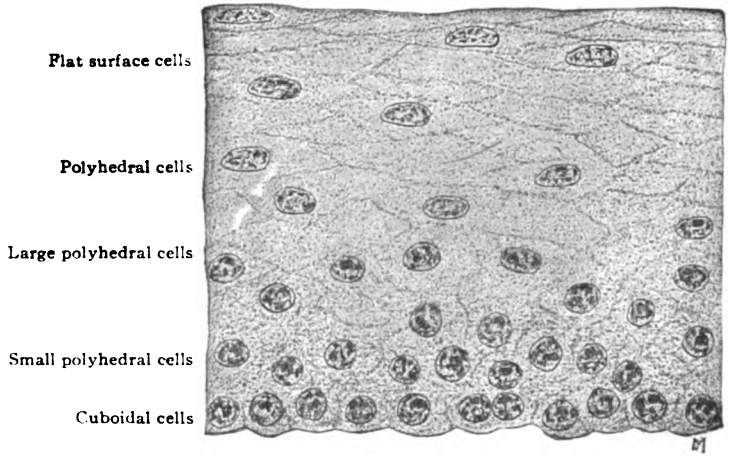

FIG. 19.—Stratified Squamous Epithelium from Cat's Œsophagus.

cellular spaces appear first as vacuoles in the exoplasm, the protoplasmic walls of the vacuoles being the "bridges." The spaces are best developed in the thicker epithelia thus lending support to the view that they have to do with the nutrition of the cells. As the cells become flatter, cells without nuclei are seen and become more numerous as the surface is approached, until on the surface, especially of parts exposed to air and unmoistened, hard cornified, non-nucleated cells containing keratin predominate. Such cells are in process of dying and being cast off. In the epithelium of mucous membranes where the surface is kept moist, there are fewer non-nucleated cells, the cells are softer and contain less keratin. In hair and nail, the surface cells though hornified are nucleated.

It is thus seen that in stratified squamous epithelium only the surface cells are squamous. This form of epithelium rests upon a more or less distinct basement membrane, which is frequently thrown up into folds by papillæ of the underlying connective tissue. Stratified squamous epithelium forms the surface of the skin and of mucous membranes of cavities opening upon it, mouth and œsophagus, conjunctiva, external ear, vagina and external sheath of hair follicle.

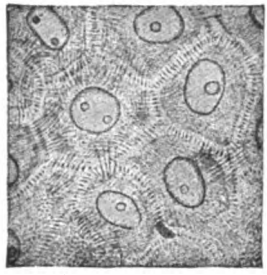

FIG. 20.—Epithelial Cells from the Stratum Spinosum of the Human Epidermis showing "Intercellular Bridges." ×700. (Szymonowicz.)

(*b*) *Stratified Columnar Epithelium.*—Only the surface cells are columnar, the deeper cells being irregular in shape. The surface cells frequently send long processes down among the underlying cells. The free surface is often marked by a well-developed cuticula. Some epithelia of this type are ciliated. Stratified columnar epithelium is found in the larynx, nose, palpebral conjunctiva, largest of the gland ducts, the vas deferens, and part of the male urethra.

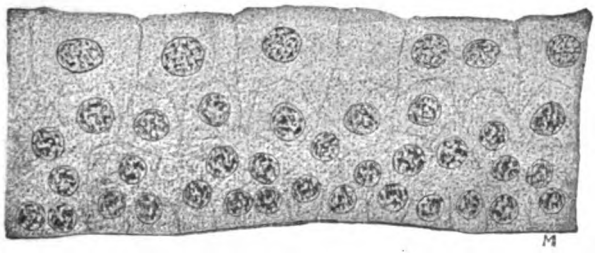

FIG. 21.—Transitional Epithelium from the Human Bladder.

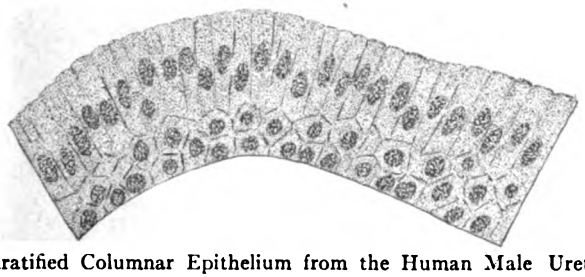

FIG. 22.—Stratified Columnar Epithelium from the Human Male Urethra. ×400.

Stratified epithelium composed of only from three to six layers of cells is sometimes designated "*transitional epithelium.*" This

type of epithelium usually rests upon a basement membrane free from papillæ. The surface cells are large and frequently contain two or three nuclei. Their free surfaces are flat, while their under surfaces show depressions due to pressure from underlying cells. The deeper

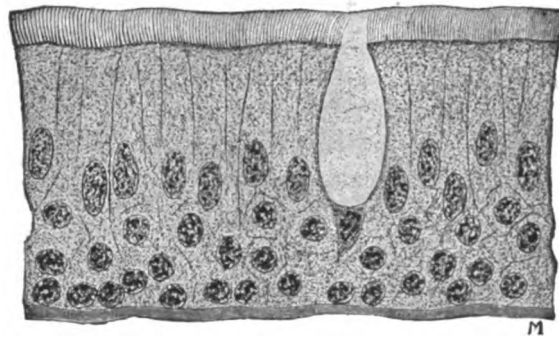

FIG. 23.—Stratified Columnar Ciliated Epithelium from the Human Trachea. A mucous (goblet) cell also is present.

cells are polygonal or irregularly cuboidal. This form of epithelium lines the bladder, ureter, pelvis of the kidney, and prostatic portion of male urethra.

FIG. 24.—Isolated Ciliated Cells and Goblet Cells from Dog's Trachea. ×700.

MODIFIED FORMS OF EPITHELIUM

(*a*) *Ciliated Epithelium.*—In this form of epithelium, fine hair-like processes—cilia—extend from the surface of the cell. These cilia vary from twelve to twenty-five for each cell and may be short as in

the trachea or long as in the epididymis. There is usually a well-defined cuticula from which the cilia appear to spring. According to Apáthy, the cilia extend through the cuticula, giving to the latter a striated appearance (Fig. 25). Just beneath the cuticula each cilium shows a swelling—the *basal granule*. Lenhossék considers these granules centrosomes. The intracellular extensions of the cilia con-

Fig. 25.

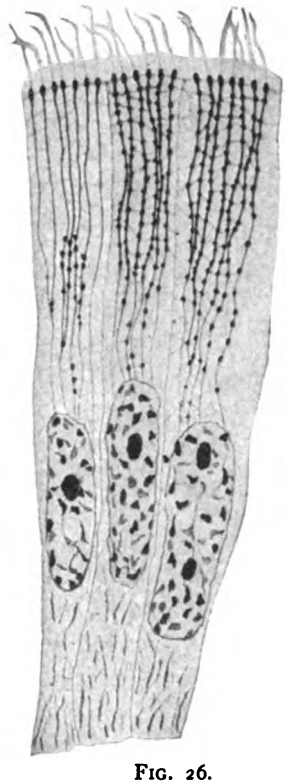

Fig. 26.

Fig. 25.—Ciliated Epithelial Cell from Intestine of Mollusk (Engelmann), showing *a*, cuticula, *b*, basal granules, and *c*, intracellular extensions of cilia.

Fig. 26.—Tangential Section through Three Cells of Skin of Aurodonta. (Kolacĕv.) Iron-hæmatoxylin stain, showing relation of cilia to basal granules and cytoreticulum.

verge toward the nucleus, and are continuous with the reticular or fibrillar structure of the cell body (Fig. 26). The motion of cilia is wave-like, the wave always passing in the same direction. Various explanations of ciliary motion have been given. It has been suggested that it is due to the contractile powers of the spongioplasm, also that it is due to changes in surface tension of the film of protoplasm which covers each cilium.

Cilia are confined to the surface cells of simple columnar and stratified columnar epithelium.

Simple columnar ciliated epithelium occurs in the smaller bronchi, uterus, Fallopian tubes and central canal of the spinal cord.

Stratified columnar ciliated epithelium occurs in large bronchi, trachea, larynx, nose, Eustachian tube, vas deferens and epididymis.

(*b*) ***Pigmented epithelium*** consists of cells the cytoplasm of which contains brown or black pigment (Fig. 27). It is usually present in the form of spherical or rod-like granules. Examples of it are seen in the pigmented epithelium of the retina and in the pigmented cells of the deeper layers of the epidermis in colored races.



FIG. 27.—Pigmented Epithelial Cells from the Human Retina (×350), showing different degrees of pigmentation. The clear spots in the centres of the cells represent the unstained nuclei.

(*c*) *Glandular Epithelium.*—This forms the essential or secreting element of glands and is mostly of the simple cylindrical variety, frequently modified to conical to conform to their concentric arrangement with reference to the gland lumen. The general features of glandular epithelium are described on p. 217. The different kinds of glands and their epithelia are described among the organs.

(*d*) *Neuro-epithelium.*—This is a highly specialized form of epithelium which occurs in connection with the end organs of nerves, under which heading it will be described.

Mesothelium and Endothelium

While recognizing the present tendency toward considering those tissues formerly classified as endothelium, as simple squamous epithelium, the correctness of the newer classification still remains *sub judice* and, so long as this is the case, we prefer to retain the certainly much more convenient classification of Minot, which coincides with his subdivision of the mesoblast. According to this classification for those tissues which resemble epithelium in structure and which are derived from the sublayer of the mesoderm which he designates the mesenchyme, the term *endothelium* is retained. The term *mesothelium* is used for those tissues which resemble epithelium but are de-

rived from a subdivision of the mesoderm which he designates the mesothelial layer.

Mesothelium and endothelium are similar in structure. Each consists of thin flattened cells with clear or slightly granular proto-

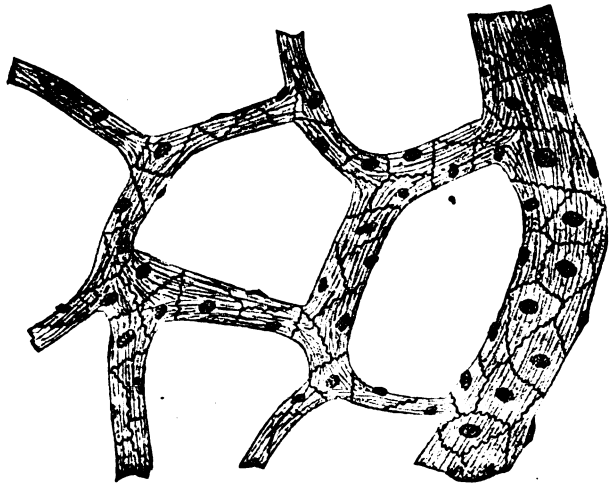

FIG. 28.—Mesothelium from Omentum of Dog Treated according to Technic 7, p. 82. ×350. Black wavy lines indicate the intercellular cement substance. The mesothelial cells cover the strands of connective tissue, the fibres of the latter being visible through the transparent cell bodies.

plasm and bulging oval or spherical nuclei. The edges of the cells are usually wavy or serrated. The cells are united by an extremely small amount of intercellular "cement" substance, which is usually indistinguishable except by the use of a special technic.

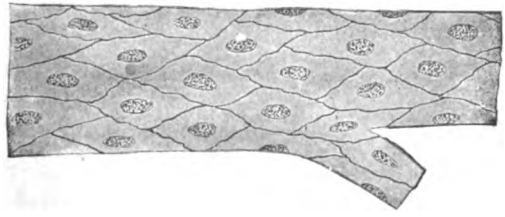

FIG. 29.—The Endothelium of a Small Blood-vessel. Silver nitrate stain. ×350.

Endothelium forms the walls of the blood and lymph capillaries and lines the entire blood-vessel and lymph-vessel systems.

Mesothelium lines the body cavities—the pleura, the pericardium and the peritoneum.

Recent researches make it seem probable that the surface cells

of serous membranes are modified connective-tissue cells rather than epithelium.

TECHNIC

1. Simple Squamous Epithelium.—That of the lung may be demonstrated by injecting with silver solution (technic 1, p. 28) through a bronchus and then immersing the tissue in the same solution. The lungs of young kittens furnish especially satisfactory material.

2. Simple Columnar Epithelium.—A piece of small intestine, human or animal, is pinned out flat on cork and fixed in formalin-Müller's fluid (technic 6, p. 7). Sections are cut perpendicular to the surface, stained with hæmatoxylin and eosin (technic 1, p. 23) and mounted in glycerin tinged with eosin (p. 25). Little processes known as villi project from the inner surface of the intestine. These are covered by a single layer of columnar epithelial cells. The cuticulæ and cuticular membrane are usually well shown. Among the simple cylindrical cells are seen large clear or slightly blue-stained cells. These are known from their secretion as mucous cells, from their shape as goblet cells, and are classed as modified epithelium of the glandular type. These should be studied in their various stages of secretion, from the cell in which only a small amount of mucus is present near the outer margin, to the cell whose protoplasm is almost wholly replaced by mucus. Some cells will be found in which the surface has ruptured and the mucus can be seen pouring out of the cell.

3. Stratified Squamous Epithelium.—The cornea furnishes good material for the study of stratified squamous epithelium. An eye is removed from a freshly killed animal and the cornea cut out and fixed in formalin-Müller's fluid. Sections are cut perpendicular to the surface, and treated as in the preceding. The cells are laid down in from six to eight layers. The œsophagus may be used instead of the cornea, its mucous membrane being lined by a somewhat thicker epithelium.

4. Transitional Epithelium.—This is conveniently studied in the mucous membrane of the bladder. Technic same as 2, above.

5. Stratified Columnar Epithelium.—A portion of trachea from a recently killed animal is treated according to the same technic. The surface cells are ciliated so that this specimen also serves to demonstrate that type of modified epithelium. Isolated cells or clumps of cells may be obtained from the trachea in the manner described in technic 3, p. 64.

6. Pigmented Epithelium.—Fix a freshly removed eye in formalin-Müller's fluid (p. 7). After hardening, cut transversely and remove the vitreous and retina. The pigmented cells remain attached to the inner surface of the chorioid, and may be removed by gently scraping. They may be preserved and mounted in glycerin.

7. Mesothelium.—Part of the omentum of a recently killed animal is removed and washed in water, care being taken not to injure the tissue in handling. The water is then replaced by a 1 to 500 aqueous solution of silver nitrate. After half an hour the specimen is removed from the silver, washed in water, transferred to 80-per-cent. alcohol and placed in the sunlight until it becomes light brown in color. It is then preserved in fresh 80-per-cent. alcohol. The nuclei may be

stained with hæmatoxylin (technic 5, p. 21). The specimen should be mounted in glycerin. Wavy black lines indicate the intercellular cement substance. The nuclei of the mesothelial cells are stained blue, those of the underlying connective-tissue cells a paler blue. It must be borne in mind in studying this specimen that the strands or trabeculæ of the omentum are not composed of mesothelium, but of fibrous connective tissue, and that the flat mesothelial cells merely lie upon the surface of the connective-tissue strands.

8. Endothelium may be demonstrated by removing the bladder from a recently killed frog, distending it with air and subjecting it to the same technic. By this means the intercellular substance of the endothelium of the blood-vessels of the bladder wall is stained and the outlines of the cells are thus shown.

CHAPTER VII

THE CONNECTIVE TISSUES

UNDER this head are classified Connective Tissue Proper, Cartilage, and Bone.

General Characteristics.—The most prominent characteristic of the connective tissues is the predominance of the intercellular substance. In this respect the connective tissues differ markedly from epithelium. In most forms of connective tissue the cellular elements are very similar and it is the intercellular substance and not the cells which determines the physical character of the tissue. Thus, for example, the hardness of bone and teeth, the firmness and elasticity of cartilage, the toughness of tendon, the softness of subcutaneous connective tissue, are all due to the character and arrangement of the intercellular elements.

The rôle of the connective tissues is mainly passive, and the cells, instead of playing the most active part, as in epithelial, muscle and nerve tissues, serve mainly for the maintenance of the nutrition of the more important intercellular substance. The latter thus predominates in function as well as in quantity, its character according with the specific function of the tissue. Thus, where rigidity and preservation of form are essential, are found connective tissues with such intercellular substance as occurs in bone, where toughness and elasticity, such types of intercellular substance as occur in tendon and cartilage, where softness and flexibility, such loosely arranged intercellular elements as are present in areolar tissue.

Most of the connective tissues are extremely vascular, differing also in this respect from epithelium. An exception to this rule is hyalin cartilage.

A very close relation exists between the different forms of connective tissue as evidenced by a marked tendency and ability of one form to be closely united to, or to be transformed into, or to be replaced by, another form. This may be progressive in line of development or retrogressive in line of degeneration. For example the close physical union which exists between tendon and bone or between cartilage and bone or tendon: or the manner in which the forms of bone are first laid down in connective tissue, which is replaced by bone, or by cartilage

followed by bone. Again in the callus which occurs in the uniting of fractures, there is first fibrous tissue, then bone, or there may be an intervening cartilaginous stage, or repair may fail of completion, leaving permanent connective tissue or cartilage.

The correlation of the different forms of connective tissue is also shown by the fact that in different species the same anatomical structure is sometimes formed by different members of the group. Thus in some birds the leg tendons are formed of bone, while in certain fish the skeletal system is cartilaginous. In Mammals the sclera of the eye is fibrous connective tissue. In Batrachians the same structure is cartilage, in Birds, bone.

Development.—All of the connective tissues have a common origin in the more loosely arranged portion of the mesoderm which is known as the mesenchyme. This consists at first wholly of small spheroidal or ovoid cells. These cells unite to form a network or syncytium with closely packed nuclei. As the cytoplasm increases more rapidly than the nuclei, the latter become more widely separated. There next takes place a differentiation which by some has been described as a differentiation of the cytoplasm into a central portion or endoplasm surrounding the nucleus, and a peripheral portion or exoplasm, by others as a differentiation into cells and a primitive intercellular or ground substance. Such a tissue is known as embryonal connective tissue (Fig. 30) and is widely distributed throughout the embryo. It represents a stage in the development of the more specialized forms of connective tissue.

Portions of this embryonal connective tissue develop fibres. The first formed fibres are known as white or fibrillated fibres or, because of their chemical constitution, as collagenous fibres. Somewhat later other fibres appear which are known as yellow or elastic fibres and consist of elastin. This differentiation of fibres gives rise to connective-tissue proper. At other points in the mesenchyme, cartilaginous material appears. These points are numerous and widely separated and each represents a chondrification center or point of development of cartilage. At some points in the connective tissue or in the cartilage there are depositions of lime salts—calcification. This is followed by the formation of true bone—ossification.

Regarding the development of the connective-tissue fibrils, there are two theories: (1) According to one, they are developed directly from the protoplasm of the connective-tissue cells. The cells increase in length, and each shows a differentiation into an endoplasmic and an ectoplasmic portion. Fine granules appear in the ectoplasm, become arranged in rows and unite to form fibrils. Such cells are known as *fibroblasts*, and their fibrils are the fore-runners of the intercellular fibrils of connective tissue. (2) According to the other theory the fibrils are developed from the matrix, minute granules first becoming arranged in rows and later uniting to form fibrils.

Regarded as opposing theories, there is in reality but little antagonism between them, it being probable that what has been described by some observers as ectoplasm has been considered by others intercellular substance. Whichever theory is accepted, the entire intercellular substance, fibres and ground substance are ultimate derivatives of the cell. Recent studies, especially those of Mall, are decidedly in favor of the first of the theories given above, that is of the intracellular or ectoplasmic origin of the connective-tissue fibrils.

Two similar theories exist as to the development of elastic fibres, a cellular theory and an extracellular theory. As in the case of the white fibrils the weight of evidence points to their development in the ectoplasm, apparently in much the same manner as the white fibrils.

Classification:—

- Connective Tissue
  - Connective Tissue Proper
    - (1) Embryonal
    - (2) Fibrillar
      - (*a*) loose or areolar (fat tissue, pigmented tissue)
      - (*b*) formed (tendon and aponeurosis)
    - (3) Elastic
    - (4) Reticular
  - Cartilage
    - Hyalin
    - Fibrous
    - Elastic
  - Bone

CONNECTIVE TISSUE PROPER

EMBRYONAL CONNECTIVE TISSUE

This is the least differentiated of the connective tissues and has been already partly described (p. 85). It is not found in the normal human adult but is described on account of its important developmental relations to the mature forms. It is also of interest from the standpoint of pathology as it is the type of connective tissue found in certain new growths, and also occurs during connective-tissue repair after injuries. Its structure varies considerably for different developmental stages. The younger forms are little more than mesenchyme with irregular stellate branching and anastomosing cells scattered through an apparently structureless or slightly fibrillated semifluid ground substance. The earliest fibrils are all of the white variety, delicate elastic fibres making their first appearance somewhat later. Older forms contain more distinct fibres of both varieties. To a somewhat more differentiated embryonal tissue in which the ground substance is rich in mucin, the name *mucous tissue* has been given (Fig. 30). It consists of a mucin-containing ground substance in which are small bundles of fine white fibrils and irregular branching cells. There are no elastic fibres. It occurs as Wharton's jelly in the umbilical cord. By some the vitreous of the eye is classed as mucous tissue. It contains only a few cells and only slight traces of a reticular fibrillation.

FIBRILLAR CONNECTIVE TISSUE

Fibrillar connective tissue, also known as *white fibrous tissue*, and itself sometimes called *connective tissue proper*, consists of cells and fibres lying in a basement or ground substance. The elements of fibrillar tissue may be classified as follows:

- Cells
  - 1. Fixed
    - (*a*) Ordinary connective-tissues cells.
    - (*b*) Plasma cells.
    - (*c*) Mast cells.
    - (*d*) Clasmatocytes
  - 2. Wandering.
- Intercellular substance
  - (*a*) Fibres
    - white or fibrillated,
    - yellow or elastic.
  - (*b*) Ground or basement substance.

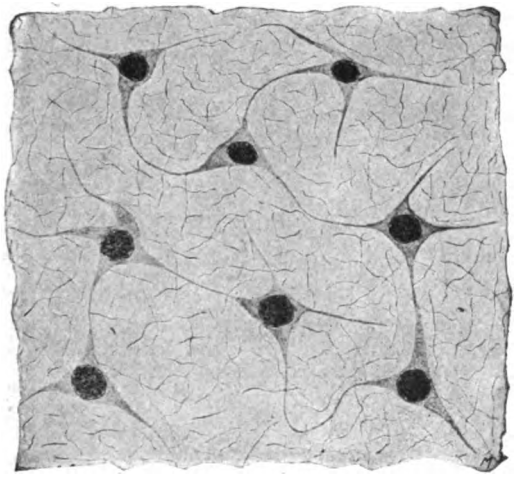

FIG. 30.—Mucous Connective Tissue from Umbilical Cord of Eight-inch Fœtal Pig. ×600. At this stage the ground substance shows some fibrillation.

Connective-tissue Cells.—(*a*) *The ordinary fixed connective-tissue cell* is often the only connective-tissue cell seen in ordinary sections. It is an irregular shaped cell, often quite flattened with clear or slightly granular cytoplasm and an oval nucleus. (Figs. 31 and 32.) In loosely arranged tissue where the cells are well separated, the cell is usually stellate with many branches, which anastomose with branches of neighboring cells. In a dense tissue such as the cornea, these cells apparently lie in little cell spaces or lacunæ from which minute channels (*canaliculi*) extend in all directions to unite with canaliculi from adjoining spaces (Fig. 33). Delicate cell processes extend into the canaliculi and there anastomose with processes from other cells thus forming a sort of syncytium (Fig. 34). Owing to the extreme sensitiveness of the protoplasm of the connective-tissue cell to most fixatives its usual

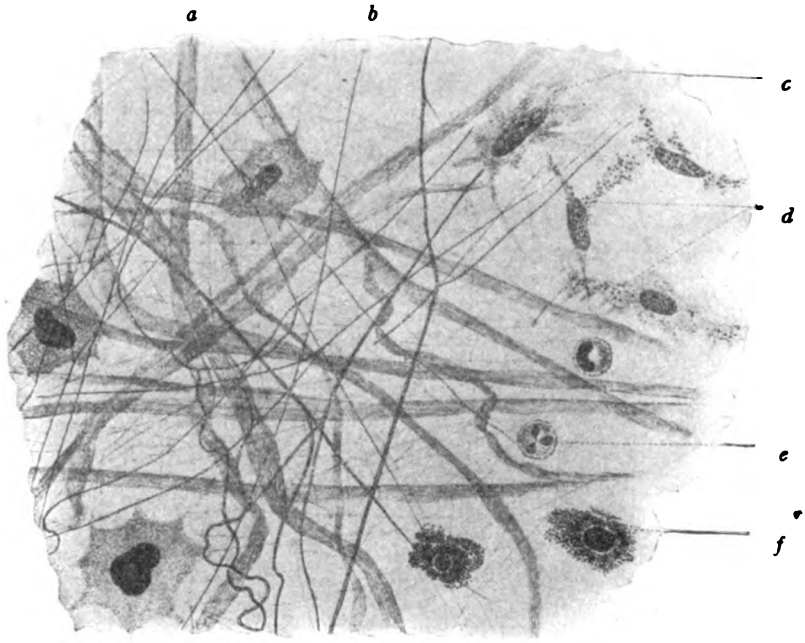

FIG. 31.—Areolar Connective Tissue (Rauber-Kopsch).
a, White fibre. *b*, Elastic fibre. *c*, Fixed connective tissue cell. *d*, Clasmatocyte. *e*, Leucocyte (wandering cell). *f*, Mast cell.

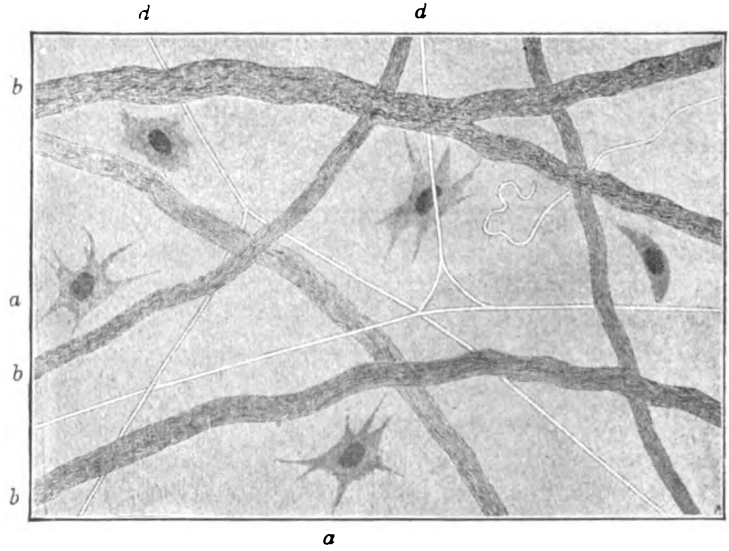

FIG. 32.—Fibrillar Connective Tissue (Areolar Type) from Subcutaneous Tissue of Rabbit (technic 2, p. 100). ×500. *a*, Fixed connective-tissue cell; *b*, fibrillated fibres; *c*, elastic fibre with curled broken end; *d*, elastic fibres showing Y-shaped branching.

appearance is that of a minute amount of cytoplasm shrunken down around a nucleus. Somewhat similar cells with more coarsely granular or vacuolated cytoplasm have been designated "*clasmocytes*" (Ranvier). By some these are believed to be of leucocyte-origin, by others to be an earlier stage in the development of the fixed connective-tissue cell.

(*b*) *Plasma Cells.*—These cells occur mainly near the smaller blood-vessels. Their protoplasm is finely granular and stains with basic aniline dyes. They frequently contain vacuoles. Their nuclei are small, spherical and usually excentric. Small plasma cells

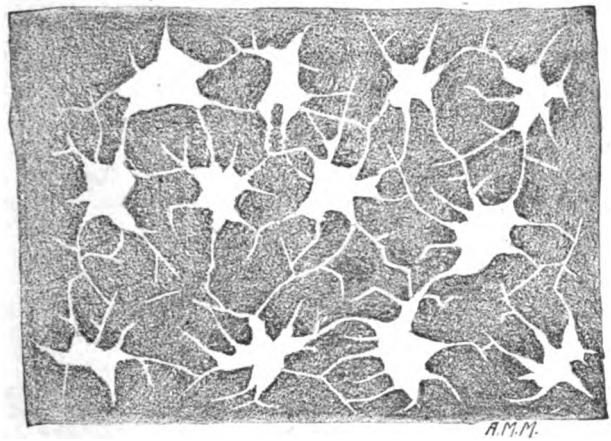

FIG. 33.—Section of Human Cornea cut Tangential to Surface. ×350. (Technic 9, p. 101.) Connective-tissue Cell Spaces (Lacunæ) and Anastomosing Canaliculi, white; Intercellular Substance (Ground Substance and Fibres), dark.

are about the size of leucocytes, which they closely resemble. Large plasma cells are larger than leucocytes and richer in protoplasm. Some consider them as derived from leucocytes, others as a modified form of the ordinary fixed connective-tissue cell.

(*c*) *Mast cells* are spherical or irregular-shaped cells, found like the preceding in the neighborhood of the blood-vessels. Their protoplasm contains coarse granules which stain intensely with basic aniline dyes (Fig. 31). They are believed by some investigators to be connected with the formation of fat; by others to represent a stage in the development of the fixed connective-tissue cell.

(*d*) *Clasmatocytes.*—These are large, mostly spindle shaped cells with granular protoplasm.

Connective-tissue cells may be pigmented (Fig. 35). In such cells the cytoplasm is more or less filled with brown or black pigment

granules. In man pigmented connective-tissue cells occur in the skin, chorioid and iris.

The so-called *wandering cells* (Fig. 31) are not properly a part of connective tissue, being merely amœboid white blood cells (see page

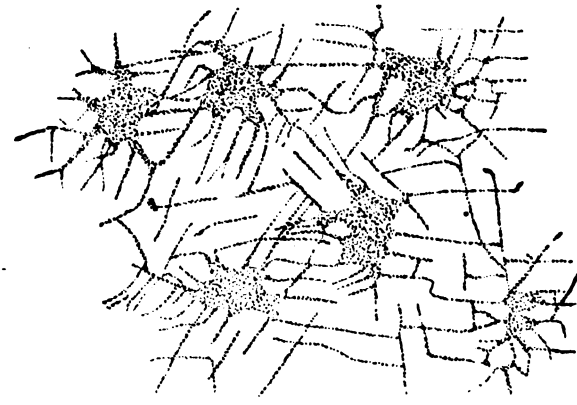

FIG. 34.—Section of Human Cornea cut Tangential to Surface. ×350. (Technic 8, p. 101.) Connective-tissue Cells with Anastomosing Processes, stained; Intercellular Substance. (Ground Substance and Fibres), unstained.

111) which have passed out from the vessels into the tissues. They are not peculiar to connective tissue, being found in other tissues.

The Intercellular Substance.—(*a*) *Fibres. White* or *fibrillated fibres* are bundles of extremely fine fibrillæ (0.5μ in diameter) (Fig. 32). The fibrillæ lie parallel to one another giving the fibre a striated appearance and are united by a small amount of cement substance. The fibrillæ do not branch. The fibre bundles, on the other hand, branch dichotomously and anastomose. White fibres are soft and flexible but very slightly elastic. Chemically they consist of an albuminous material known as collagen, and are for this reason sometimes called collagenous fibres. On boiling, they yield *gelatin*.

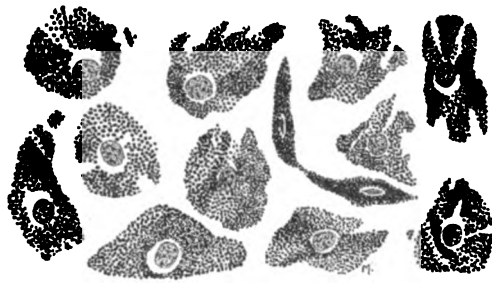

FIG. 35.—Pigmented Connective-tissue Cells from Chorioid Coat of Human Eye. ×350. (Technic 7, p. 100.)

Yellow or *elastic fibres* are apparently homogeneous, highly refractive fibres, varying in diameter from 1 to 10μ (Fig. 32). They branch and anastomose, forming networks. The smaller fibres are

round on cross section, the larger flattened or hexagonal (Figs. 45 and 46). Their elasticity is easily demonstrated in teased specimens by curling of the broken ends of the fibres (Fig. 32). On boiling they yield *elastin*. Although, when subjected to the usual technic, elastic fibres appear homogeneous, they are probably composed of a thin sheath or membrane, enclosing the more granular elastin. The latter stains intensely with magenta, the sheath remaining unstained.

In addition to the white fibres and elastic fibres above described, so-called "reticular" fibres are frequently present in fibrillated connective tissue. (See p. 98.)

(*b*) *Basement* or *ground substance* constitutes the matrix in which the connective-tissue cells and fibres lie. It also occurs in extremely minute amounts between the individual fibrillæ of the white fibres, where it acts as a cement substance (Fig. 31). Difficulty in seeing this ground substance is due to its transparency. It may be demonstrated by staining with silver nitrate. (See technic 9, p. 100.)

Much variation exists in regard to the proportions of the different elements. This gives rise to variations in the physical characteristics of the tissue. When fibres predominate over cells and ground substance, the tissue is dense and hard and is known as *dense fibrous tissue*. The terms *fine* connective tissue and *coarse* connective tissue designate the character of the *fibres*. When many cells are present, the tissue is softer and is known as *cellular* connective tissue.

According to the arrangement of the white fibres, fibrous connective tissue is subdivided into *areolar* or *loose connective tissue* and *formed* or *dense fibrous connective tissue*.

Areolar or Loose Connective Tissue

Areolar or loose connective tissue is a form of fibrillar tissue in which as the name indicates there is a loose and irregular arrangement of fibres and cells. Both white and elastic fibres are present though the former are the more abundant. These cross and interlace in all directions leaving between them meshes or areolæ. Filling the meshes and forming the ground substances in which cells and fibres lie is a coagulable, transparent fluid or semifluid material, which takes on a granular light brown appearance on treating with silver nitrate. By the same method are demonstrated irregular lymph channels lined by thin endothelium. The number and coarseness of the fibres, the relative number of cells, and the amount of ground

substance vary greatly. Thus some areolar tissue is quite dense and firm, others soft and succulent with all gradations between. Areolar tissue is the most widely distributed of all the connective tissues being in larger or smaller amounts almost everywhere present. Thus it connects skin and mucous membranes with the underlying structures, accompanies all blood vessels, forms the framework of all organs, etc.

FAT TISSUE.—*Adipose tissue* or *fat tissue* is a form of areolar tissue in which some of the cells have become changed into fat cells. Fat tissue is peculiar among the connective tissues in that the cells and

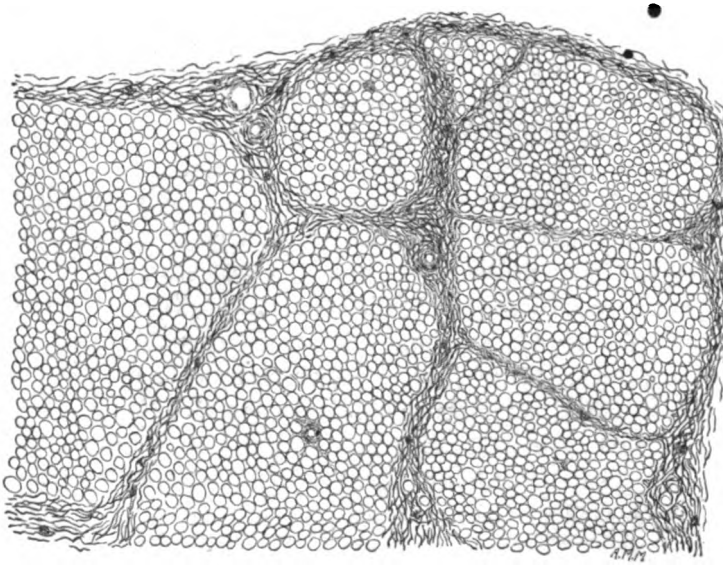

FIG. 36.—Fat Tissue from Human Subcutaneous Tissue (Child) to show Lobulation. ×25. (Technic 1, p. 99.)

not the intercellular substance make up the bulk and determine the character of the tissue. The adult fat cell is surrounded by a distinct *cell membrane*, and almost the entire cell is occupied by a single droplet of fat (Figs. 37 and 38). The nucleus, flattened and surrounded by a small amount of cytoplasm, is usually found pressed against the cell wall (Fig. 38). This appearance of a distinct cell membrane enclosing the spherical fat droplet, with the nucleus and cytoplasm pressed into a crescent-shaped mass at one side, has given rise to the term "signet-ring cell." Fat cells which occur singly,

or in small groups, or in the developing fat of young animals are spherical (Fig. 37). In large masses of adult fat, the closely packed cells are subjected to pressure and are polyhedral (Fig. 38). Fat cells are usually arranged in groups or lobules, each lobule being separated from its neighbors by fibrillar connective tissue (Fig. 36).

The appearance which adult fat presents can be understood only by reference to its histogenesis. Fat cells are developed directly

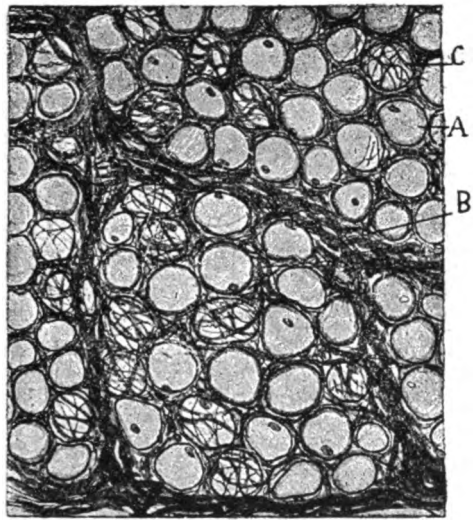

FIG. 36*A*.—Section of Subcutaneous Adipose Tissue from two months old dog. (Cajal.) The young fat cells not having been subjected to long pressure as in the adult, appear mostly spheroidal. A, Fat cell cut approximately through center and including nucleus; *B*, broad trabeculæ of interlobular connective tissue. Separating the individual fat cells is the finer intralobular connective tissue: C, Tangential section of fat cell showing overlying or underlying connective tissue reticulum.

from embryonic connective-tissue cells whether from any connective tissue cell or only from a specially differentiated connective tissue cell has not been determined. According to Schreier who has followed the formation of fat cells in the subcutaneous areolar tissue of Hagfish embryos, the earliest fat granules are formed from mitochondria. Larger droplets are due to coalescence of smaller. In the human embryo they are first distinguishable as fat cells about the thirteenth week. The connective-tissue cells which are to become fat cells gather in groups in the meshes of the capillary network which marks the ending of a small artery. *Each group is destined to become an adult fat lobule* (Fig. 39).

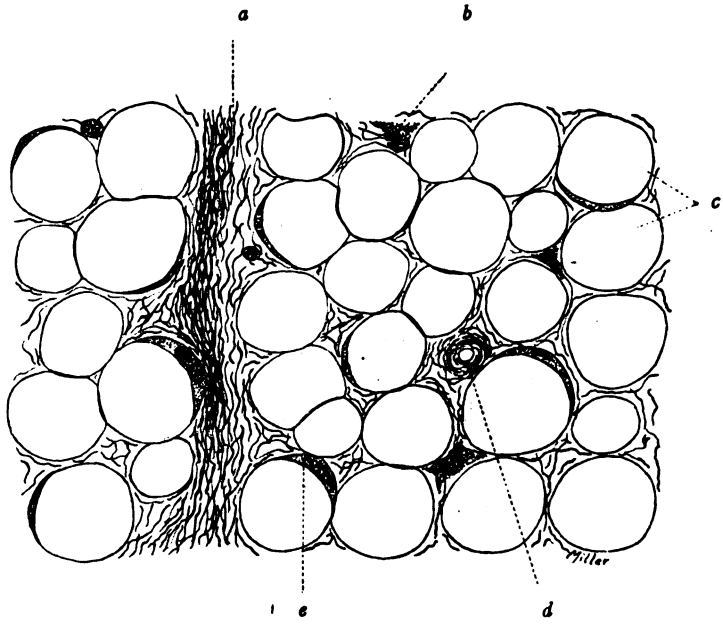

FIG. 37.—Young Fat from Human Subcutaneous Tissue. (Child.) ×175. (Technic 11, p. 101.) *a*, Interlobular connective tissue; *b*, fixed connective-tissue cell; *c*, fat cells *d*, artery; *e*, nucleus of fat cell and remains of cytoplasm ("signet ring").

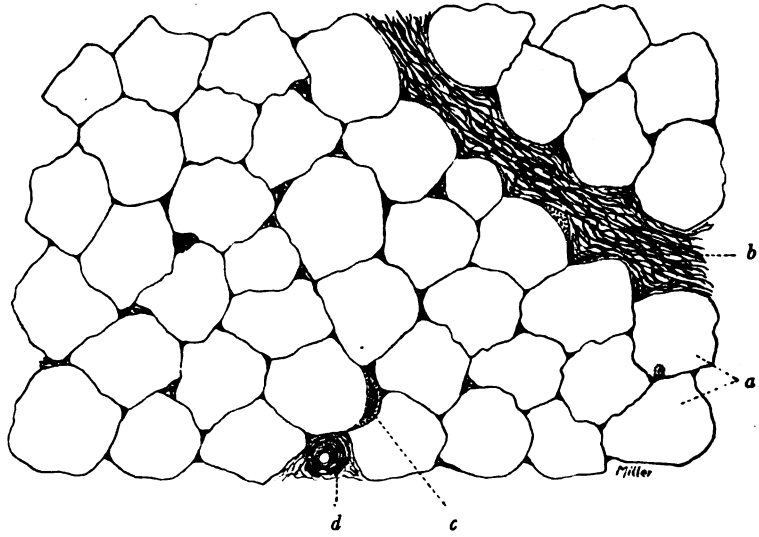

FIG. 38.—Adult Fat Tissue from Human Subcutaneous Tissue. ×175. (Technic 11, p. 101.) *a*, Fat cells; *b*, interlobular connective tissue; *c*, nucleus of fat cell and remains of cytoplasm ("signet ring"); *d*, artery.

Fat first appears as minute droplets in the cytoplasm of the embryonic connective-tissue cell (Fig. 40). These small droplets in-

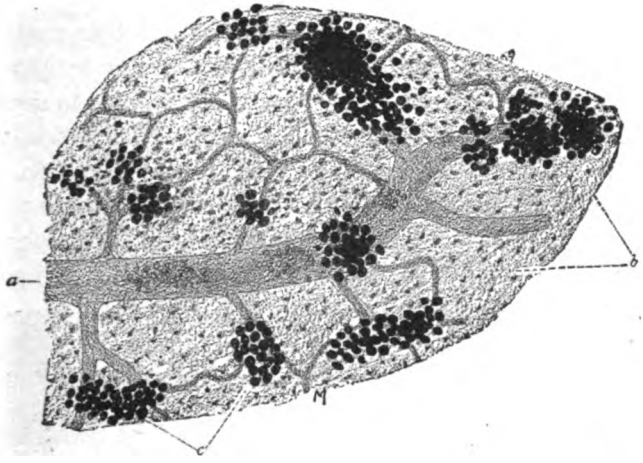

FIG. 39.—Developing Fat Tissue from Subcutaneous Tissue of Five-inch Fœta, Pig. ×75. (Technic 12, p. 101.) *a*, Arteriole breaking up into capillary network; *b*, embryonal connective tissue; *c*, embryonal fat lobule developing around blood-vessels.

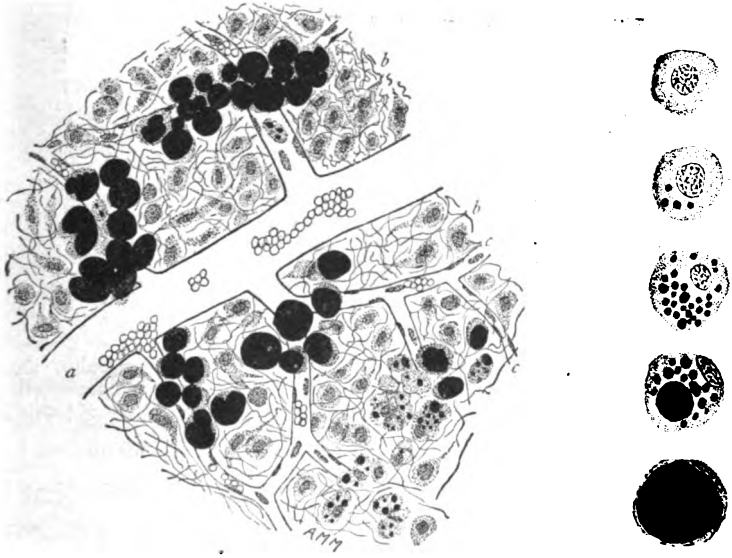

FIG. 40.—Developing Fat Tissue from Subcutaneous Tissue of Five-inch Fœtal Pig. (Technic 12, p. 101.) *a*, Arteriole breaking up into capillary network; *b*, embryonal connective tissue, embryonal cells from which fat cells are developing; *c*, capillaries. Fat droplets stained black. At the right are five individual cells showing stages of development from an embryonal cell to an adult fat cell.

crease in number and finally coalesce to form a single larger droplet. This increases in size and ultimately almost wholly replaces the cyto-

plasm. In this way the nucleus and remaining cytoplasm are pressed to one side and come to occupy the inconspicuous position which they have in adult fat.

The blood supply of fat is rich and the adult lobule maintains its embryonic vascular relations, in that the vascular supply of each lobule is complete and independent. One artery runs to each lobule, where it breaks up into an intralobular capillary network, which in turn gives rise to the intralobular veins, usually two in number.

Fat is thus seen to be a connective tissue in which some of the cells have undergone specialization. There still remain, however, embryonal connective-tissue cells which are not destined to become fat cells, but which develop into cells and fibres of ordinary fibrous connective tissue. A few of these remain among the fat cells to become the delicate intralobular connective tissue seen in adult fat. The majority are, however, pushed to one side by the developing lobules, where they form the interlobular septa.

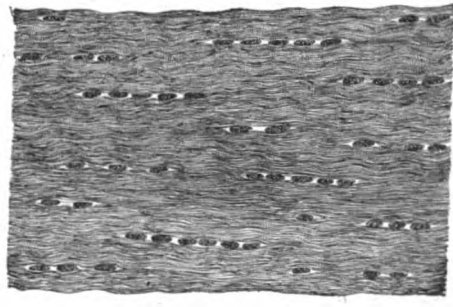

FIG. 41.

FIG. 42.

FIG. 41.—Longitudinal Section of Tendon from Frog's Gastrocnemius. ×250. The nuclei of the flattened cells are seen lying in rows between the connective-tissue fibres.
FIG. 42.—Teased tendon fibres with cells lying on their surface. ×400. (Ranvier.)

Formed or Dense Fibrous Connective Tissue

In formed connective tissue the tissue elements instead of being disposed irregularly as in areolar tissue, are arranged with some regularity or order, thus giving the tissue more or less definite form.

Tendons and *ligaments* are examples of formed connective tissue in which the fibres all run in approximately the same direction (Fig. 41). Elastic fibres are absent or present in very small numbers. The predominance of the white fibres and their parallel arrangement result in great strength with almost no extensibility. While

the individual fibrils do not branch, groups of fibrils pass from one bundle to another. There is little ground substance and cells are comparatively few. The latter are, however, so characteristic as to have received the name of tendon cells (Fig. 43). They are irregularly rectangular cells, have rather more breadth than length and are arranged in characteristic rows between the fibre bundles. The cell margins are contiguous and the usually excentric nuclei tend to lie in adjacent sides of two cells, thus giving the cells the appearance of being arranged in pairs (Fig. 42). Thin plate-like extensions of the cell (Fig. 43) pass into the ground substance between the fibre bundles and when the cell is seen on flat, the greater thickness of the cell through the extensions gives the optical effect of dark lines in the cell body.



FIG. 43.

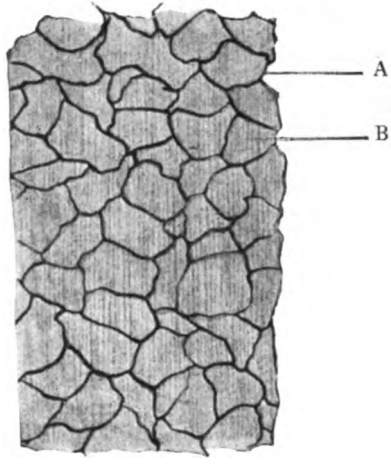

FIG. 44.

FIG. 43.—Tendon Cells from the Tail of a Rat. Stained by methylene-blue (*intra vitam*). (Bohm-Davidoff.)

FIG. 44.—Pavement Endothelium of Tendon of Rat. *A*, intercellular substance impregnated with silver nitrate; *B*, tendon fibres. ×115. (Branca.)

Aponeuroses.—In thin aponeurotic tissue the fibres are disposed in two planes, the fibres of one plane running approximately at right angles to those of the other plane. The cells resemble tendon cells and lie upon the fibre bundles. In thicker aponeuroses the fibres are arranged in planes but their disposition is more irregular.

ELASTIC TISSUE

Elastic fibres occurring in fibrous connective tissue have been described. When the elastic fibres predominate the tissue is known as *elastic tissue.* Almost pure elastic tissue is found in the ligamentum nuchæ of quadrupeds. In man it occurs mainly in the ligamenta subflava, in some of the laryngeal ligaments, in the walls

of the trachea and bronchi and of arteries. In the ligamentum nuchæ the fibres are coarse (10 to 15μ) and arranged in bundles separated from one another by white fibrous tissue containing con-

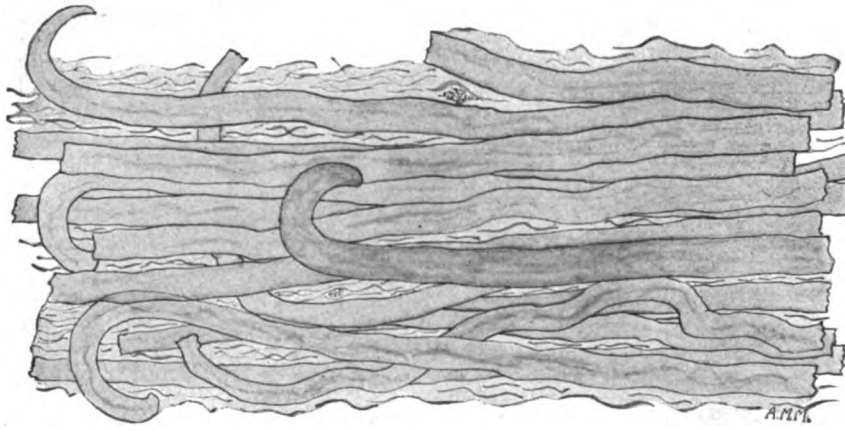

FIG. 45.—Coarse Elastic Fibres from Ligamentum Nuchæ. ×500. Teased specimen. (Technic 10, p. 101.)

nective-tissue cells. This white fibrous tissue also penetrates the bundles and separates the individual elastic fibres. A few white fibres and connective-tissue cells are also present (Figs. 45 and 46).

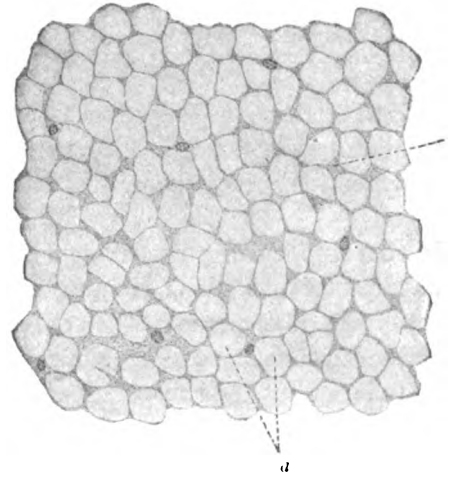

FIG. 46.—Cross Section of Coarse Elastic Fibres from Ligamentum Nuchæ. ×500. (Technic 10, p. 101.) *a*, Elastic fibres; *b*, white fibrous tissue and cement substance. The nuclei are the nuclei of fixed connective-tissue cells.

Elastic tissue may be arranged as thin *membranes*, as *e.g.*, in the walls of blood-vessels. These membranes are usually described as composed of a dense mass of flat, ribbon-like elastic fibres, which

interlace in such a manner as to leave openings in the membrane. Hence the term "fenestrated membrane." They have been recently described as consisting of a central layer composed of elastin, staining with magenta, and on either side a thin, transparent sheath unstained by magenta. This is seen to correspond to Mall's description of the structure of the elastic fibre. Only the middle of these layers is fenestrated.

RETICULAR TISSUE

Reticular connective tissue is a form of fibrillar connective tissue. It consists of extremely delicate fibrils with no ground

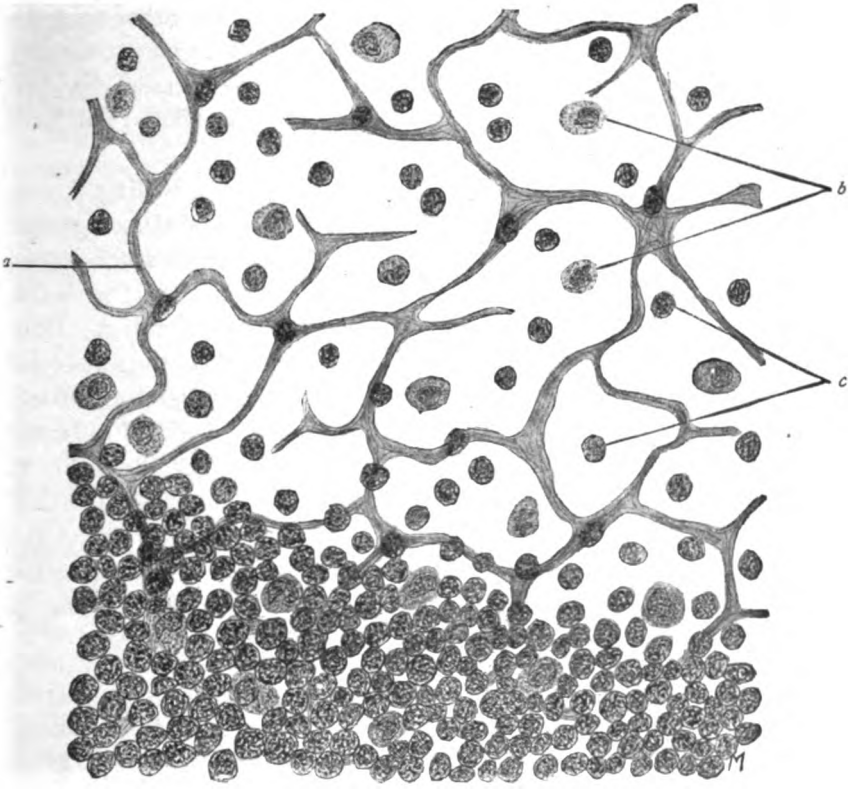

FIG. 47.—Reticular Tissue from a Human Lymph Node. (Technic, 13, p. 101.) *a*, Reticular connective tissue, in the meshes of which are suspended *b*, leucocytes, and *c*, lymphocytes. The reticular connective tissue is present also in the more dense lymphatic tissue seen in the lower part of the figure, but is not visible on account of the closely packed cells.

substance. The fibrils are grouped in larger or smaller bundles which form a network or feltwork enclosing spaces, thus constitut-

ing a reticulum. The fibrils present much the same microscopic appearance as the white fibres of areolar tissue. Also in certain organs, *e.g.*, the lymph nodes, the direct continuity of the fibres of the coarser fibrous tissue of the trabeculæ with the fibrils of the reticular tissue can be easily demonstrated. In some locations, *e.g.*, in the lymph nodes (Fig. 47) the cells of the reticular tissue lie upon the surface of the fibrils and so completely invest them that the fibrillar character of the tissue cannot be seen until the overlying cells have been removed. This has led to two views regarding the relations between the cells and fibres of reticular tissue, one that the relation is the same as in other forms of connective tissue, the cells lying on the fibres but being entirely separate from them, the other that the fibres run through the protoplasm of the cells. This view considers reticular tissue a less differentiated type than fibrous tissue, development having stopped at a point where the cells (fibroblasts) still have fibrils running through their protoplasm.

Reticular tissue has been described as yielding on boiling, a substance called by some *elastin* by others *reticulin* instead of gelatin which results from boiling fibrous tissue. Other recent studies upon the chemistry of reticular tissue are not however in accord with this view, reticular tissue being found to yield gelatin on boiling. Both tissues resist pancreatic digestion, and the question as to the structural and chemical relations of the two tissues remains at present unsettled.

Reticular connective tissue forms the framework of adenoid tissue and of bone-marrow. It is also present in large amounts in the spleen and in the mucous membrane of the gastro-intestinal tract, lung, liver, kidney, and other organs where it forms the finer part of the framework, supporting the capillaries, and often apparently serving as a basement membrane for the gland cells.

TECHNIC

1. Areolar Tissue, to show White and Elastic Fibres.—Remove a bit of the subcutaneous tissue, as free from fat as possible, from a recently killed animal. Place it upon a mounting slide and with teasing needles quickly spread it out in a thin layer. During this manipulation the specimen should be kept moist by breathing on it. Put a drop of sodium chlorid solution upon the specimen and cover.

As the specimen is unstained, a small diaphragm should be used for the microscopic examination.

The white fibres are straight or wavy, are crossed in all directions, and are longitudinally striated. The elastic fibres have been stretched and show as sharp lines with curled ends where the fibres are broken.

Place a drop of hydric acetate, 1-per-cent. aqueous solution, at one side of the cover and a bit of filter paper at the other side. The filter paper absorbs the salt solution, which is replaced by the hydric acetate. The latter causes the white fibres to swell and become indistinct while the elastic fibres show more plainly.

2. Areolar Tissue, to show Cells and Elastic Fibres.—Prepare second specimen of areolar tissue in the same manner as the preceding. Instead of mounting in salt solution, allow it to become perfectly dry, then stain in the following solution:

Gentian violet, saturated aqueous solution,	40 c.c.
Water,	60 c.c.

Wash thoroughly, dry, and mount in balsam.

The nuclei of the fixed connective-tissue cells are stained violet. Their delicate cell bodies show as an irregular haze around the nuclei. Both nuclei and cell bodies appear cut in all directions by the stretched elastic fibres. Wandering cells (leucocytes) may usually be seen. Plasma cells are frequently not demonstrable, and mast cells are only occasionally present. The elastic fibres are stained violet. The white fibres are almost unstained.

While these methods are most satisfactory for bringing out the different connective-tissue elements, they are misleading to the student in that they show a picture of connective tissue after special preparation, rather than as it usually appears in sections. For contrast the student should study carefully the connective tissue as it appears in sections through the skin, the mucous membranes and other organs.

3. Formed Connective Tissue.—Fibrous tissue arranged in the form of a network may be seen in the specimen of omentum (technic 7, p. 82).

4. Densely formed connective tissue may be studied in tendon. Cut through the skin of the tail of a recently killed mouse about half an inch from the tip and break the tail at this point. By pulling on the end of the tail this portion may now be separated from the rest of the tail, carrying with it long delicate tendon fibrils, which have been pulled out of their sheaths. These should be immediately examined in salt solution, using the high power and a small diaphragm. The fibrils are seen arranged in parallel bundles.

5. Place a drop of hydric acetate (2-per-cent. aqueous solution) at one side of the cover-glass, absorbing the salt solution from the opposite side by means of filter paper. The fibres swell and become almost invisible, while rows of connective-tissue cells (tendon cells) can now be seen. The cells may be stained by allowing a drop of hæmatoxylin or of carmine solution to run under the cover. After the cells are sufficiently stained, the excess of stain is removed by washing, and the specimen mounted in glycerin.

6. Fix a small piece of any good-sized tendon in formalin-Müller's fluid (page 7). After a week, harden in alcohol, embed in celloidin, and make longitudinal and transverse sections. Stain strongly with hæmatoxylin, followed by picro-acid-fuchsin (page 24). Mount in balsam.

7. Pigmented connective-tissue cells are most conveniently obtained from the chorioid coat of the eye. Fix an eye in formalin-Müller's fluid (see page 7), cut in half, remove chorioid and retina and pick off the dark shreds which cling to the outer surface of the chorioid and inner surface of the sclera. These may

be transferred directly to glycerin, in which they are mounted, or the bits of tissue may be first stained with hæmatoxylin (page 21). In addition to the pigmented cells should be noted the ordinary fixed connective-tissue cells which lie among them. Only the nuclei of these cells can be seen.

8. Connective-tissue cells to show anastomosing processes.—Stain a cornea with gold chlorid (see page 28). Sections are made tangential to the convex surface and are mounted in glycerin.

9. Connective-tissue cell spaces (lacunæ) and their anastomosing canaliculi may be demonstrated by staining a cornea with silver nitrate (see page 28). The silver stains the ground substance of the cornea, leaving the lacunæ and canaliculi unstained. The relation which this picture bears to the preceding should be borne in mind (see Figs. 31 and 32).

10. Coarse elastic fibres may be obtained from the ligamentum nuchæ, which consists almost wholly of elastic tissue. A piece of the ligament is fixed in saturated aqueous solution of picric acid and hardened in alcohol. A bit of this tissue is teased apart on a glass slide in a drop of pure glycerin, in which it is also mounted. Before putting into glycerin, the specimen may be stained with picro-acid-fuchsin. This intensifies the yellow of the elastic fibres and brings out in red the fibrillar connective tissue. Pieces of the ligament fixed and hardened in the same manner may be embedded in celloidin and cut into longitudinal and transverse sections. These stained with picro-acid-fuchsin show well the relation of the coarse elastic fibres (yellow) to the more delicate fibrous tissues (red).

11. Fat Tissue.—Human subcutaneous fat as fresh as possible is fixed in formalin-Müller's fluid (technic 6, p. 7), hardened in alcohol and embedded in celloidin. Sections are stained with hæmatoxylin and picro-acid-fuchsin (technic 3, p. 24). The alcohol and ether of the celloidin remove the fat from the fat cells, leaving only the cell membranes. The fat gives the celloidin a milky appearance. Such celloidin does not cut well. The celloidin should, therefore, be changed until it ceases to turn white. The sections are cleared in oil of origanum or carbol-xylol, and mounted in balsam. The fibrillar tissue is stained red by the fuchsin, and the protoplasm of the fat cell yellow by the picric acid. Fat tissue may also be satisfactorily stained by Sudan III or Scharlack R. For details see p. 31.

12. Developing Fat Tissue.—Remove bits of tissue from the axilla or groin of a five-inch fœtal pig, or other fœtus of about the same development. Fix twenty-four hours in a 1-per-cent. aqueous solution of osmic acid (technic 10, p. 31), wash thoroughly and mount in glycerin. A part of the tissue mounted should be thoroughly teased, the rest gently pulled apart. The teased portion will show the fat cells in various stages of development. The unteased part will usually show brownish blood-vessels and the grouping of fat cells around them, to form embryonic fat lobules. Note the developing connective tissue between the groups of fat cells. It is from this that the areolar tissue, which envelops and separates the lobules of adult fat, is developed.

13. Reticular Tissue.—Fix a lymph node in formalin-Müller's fluid (technic 6, p. 7), and stain very thin sections with hæmatoxylin and picro-acid-fuchsin (technic 3, p. 24). In the lymph sinuses of the medulla the reticulum can usually be plainly seen.

CARTILAGE

Cartilage is a form of connective tissue in which the ground substance is firm and dense and determines the physical character of the tissue. On boiling it yields *chondrin*. *Cartilage cells* are differentiated connective-tissue cells. While varying greatly in shape they are most frequently spherical or oval. Each cell lies in a cell space or *lacuna*, which in life it completely fills. In most fixed cartilage tissue, however, there is considerable space between the cell and lacuna, due to shrinkage of the cell. The intercellular substance immediately surrounding a lacuna is frequently arranged concentrically, forming a sort of *capsule* which is sharply outlined on the side toward the cell but shades imperceptibly into the surrounding intercellular substance. Fine canaliculi connecting the lacunæ are present in some of the lower animals and have been described in human carti-

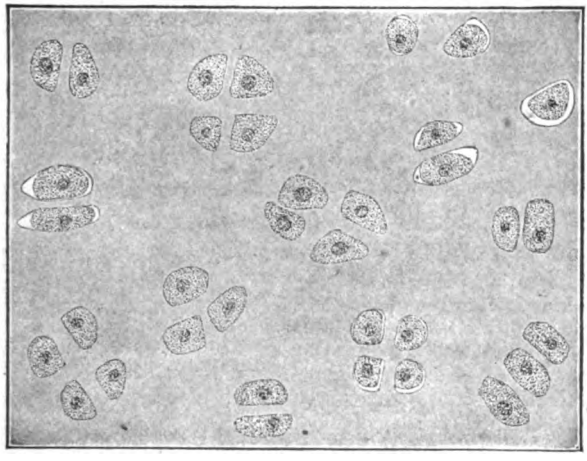

FIG. 48.—Hyaline Cartilage from Head of Frog's Femur. ×350. (Technic 1, p. 104.) Groups of cartilage cells in apparently homogeneous matrix.

lage. They can be demonstrated, however, in human cartilage, only by special methods, and probably represent artefacts.

Cartilage contains no blood-vessels, and in human cartilage no lymph channels have been positively demonstrated.

Cartilage is subdivided according to the character of its intercellular substance into three varieties: (1) hyaline, (2) elastic, (3) fibrous.

1. **Hyaline Cartilage** (Fig. 48).—This occurs usually as hard gristly plates surrounded by a layer or layers of dense vascular fibrous connective tissue, the perichondrium. Peripherally the perichon-

drium consists mostly of fibres with few cells, but as the cartilage is approached, cells become more numerous, especially in immediate proximity to the cartilage. This layer is known as the *chondrogenetic layer* and it is from these cells that the cartilage cells are derived.

The cartilage itself consists of cells and ground substance. The cells occur singly or in groups of two or multiples of two. An entire group of cells frequently lies in one lucuna surrounded by a single capsule. Such a group of cells has developed within its capsule from a single parent cell and the form of the group depends upon the directions of the successive planes of division. In some cases delicate hyaline partitions separate the cells of a group. The cells are spherical or oval, with flattening of adjacent sides. The nucleus is centrally placed, and has a distinct intranuclear network and membrane. The cytoplasm is finely granular, and may contain droplets of fat, of glycogen, or of both. Toward the perichondrium the arrangement of the cells in groups is less distinct. Here the cells are fusiform and parallel to the surface.

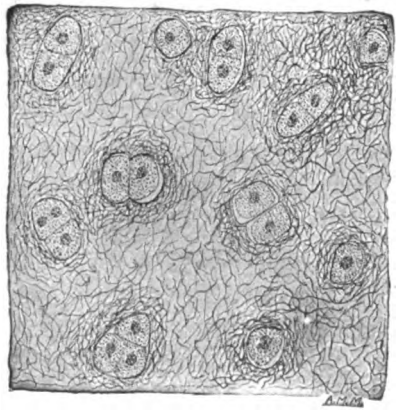

FIG. 49.—Elastic Cartilage from Dog's Ear. ×350. (Technic 2, p. 104.) Groups of cartilage cells in fibro-elastic matrix.

The intercellular matrix, when subjected to the usual technic, appears homogeneous. Some investigators using special methods of technic, such, *e.g.*, as artificial digestion, consider this apparently structureless matrix as being made up of bundles of fine fibrils, which interlace in all directions and are apparently quite similar to those found in fibrous connective tissue. Still other fibres have been described as being demonstrable in alcohol fixed material especially in developing cartilage, these fibres running from the perichondrium to lose themselves in the capsules of the most superficial cells. Deeper in the cartilage the fibres have a radial arrangement running from one capsule to adjacent capsules. Their significance is not known. Considered by some as artefacts, they are looked upon by others as lymph routes through the cartilage.

Hyaline cartilage forms the articular cartilages of joints, the costal cartilages, and the cartilages of the nose, trachea, and bronchi. In the embryo a young type of hyaline cartilage, known as embryonal

cartilage, forms the matrix in which most of the bones are developed.

2. **Elastic cartilage** (Fig. 49) resembles hyaline, but differs from the latter in that its hyaline matrix contains a large number of elastic fibres. These vary in size, many being extremely fine. The elastic fibres branch and run in all directions, forming a dense network of interlacing and anastomosing fibres.

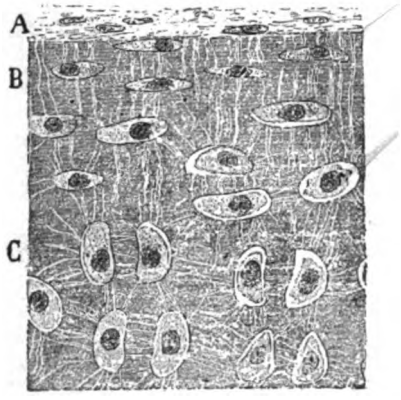

FIG. 49*A*.—Section through Costal Cartilage of Young Dog (Cajal). Alcohol fixation. A, perichondrium; B, flattened superficial cells; C, deep cells. The white lines running from space to space are considered by some as artefacts, by others as fibrils, by still others as lymph channels (see text).

Elastic cartilage occurs in the external ear, the Eustachian tube, the epiglottis, and in some of the laryngeal cartilages.

3. **Fibrous cartilage** (Fig. 50) is composed mainly of fibrillar connective tissue. The fibres may have a parallel arrangement, or may run in all directions. Cells are few, and are usually arranged in rows of from two to six, lying in elongated cell spaces between the fibre bundles.

Fibrous cartilage occurs in the inferior maxillary and sternoclavicular articulations, in the symphysis pubis, and in the intervertebral discs.

Cartilage, except where it forms articular surfaces, is covered by a membrane, the *perichondrium*. This is composed of fibrillar connective tissue, and blends without distinct demarcation with the superficial layers of the cartilage.

Like the other connective tissues, cartilage develops from mesoderm. It is at first *wholly cellular*. Each cell forms a *capsule* around itself, and by blending of these capsules are formed the first elements of the *intercellular matrix*. This increases in quantity and assumes the structural characteristics of one of the forms of cartilage. The

white fibres of fibro-cartilage and the yellow fibres of elastic cartilage develop in the same manner as in fibrillar and elastic tissue. Continued growth of cartilage takes place probably mainly by transformation of the chondrogenetic inner layer of the perichondrium into cartilage, also by proliferation of the cartilage cells and growth and fusion of their capsules.

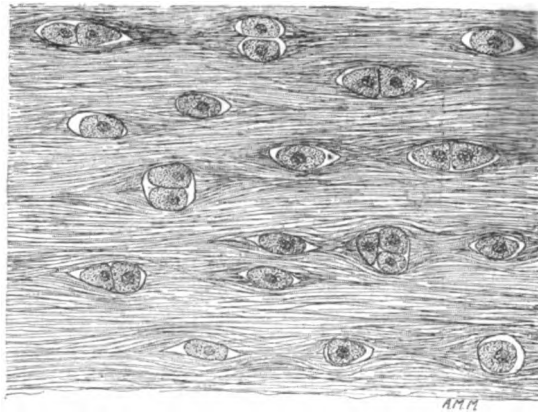

FIG. 50.—Fibrous Cartilage from Dog's Intervertebral Disc. ×350. (Technic 3, below.) Groups of cartilage cells in matrix of fibrillar connective tissue.

TECHNIC

(1) Hyaline Cartilage.—Remove a frog's femur and immediately immerse the head in saturated aqueous solution of picric acid. Cut sections tangential to the rounded head, keeping knife and bone wet with the picric acid solution. As bone must be cut, a special razor kept for the purpose should be used. Cut sections as thin as possible. The first sections consist wholly of cartilage. As bone is reached, the cartilage is confined to a ring around the bone. Mount in the picric-acid solution, cementing the cover-glass immediately.

(2) Elastic Cartilage.—Remove a piece of cartilage from the ear and fix in formalin-Müller's fluid (technic 6, p. 7). Stain sections strongly with hæmatoxylin, followed by picro-acid-fuchsin (technic 3, p. 24). Clear in carbol-xylol and mount in balsam. The capsules around the cartilage cells are thick and, as they usually retain some hæmatoxylin, can be readily seen. Note also the flattened cartilage cells near the surface, and the perichondrium.

(3) Fibro-cartilage.—Fix pieces of an intervertebral disc in formalin-Müller's fluid. Sections are stained either with hæmatoxylin-eosin or with hæmatoxylin-picro-acid-fuchsin and mounted in balsam.

BONE

Bone is a form of connective tissue in which the matrix is rendered hard by the deposition in it of inorganic matter, chiefly the

phosphate and the carbonate of calcium. These salts are not merely deposited in the matrix, but are intimately associated and combined with its histological structure. The intimacy of this association of the organic and inorganic constituents of bone is shown by the fact that, though the salts compose two-thirds of bone by weight, it is impossible to distinguish them by the highest magnification. Furthermore, if either the lime salts are dissolved out by means of acids (decalcification) or the organic matter removed by heating (calcination), the histological structure of the bone still remains.

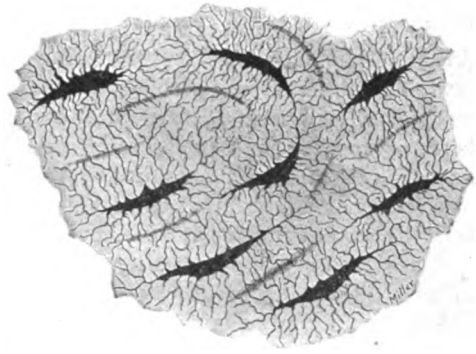

FIG. 51.—Bone Tissue showing Lacunæ and Canaliculi. ×700. (Technic 1, p. 106.)

Like the other connective tissues, bone consists morphologically of *cells* and *intercellular substance.*

Bone cells or *bone corpuscles* lie in distinct *cell spaces* or *lacunæ.* From the lacunæ pass off in all directions minute canals—*canaliculi*—which anastomose with canaliculi of neighboring lacunæ (Fig. 51). At the surface of bone these canaliculi open into the periosteal lymphatics. A complete system of canals is thus formed, which traverse the bone and serve for the passage of nutritive fluids. The bone cells themselves (Fig. 52) are flat, ovoid, nucleated cells, with numerous fine processes, which extend in all directions into the canaliculi. In young developing bones the processes of adjacent cells anastomose. In adult bone the processes extend but a short distance into the canaliculi, and probably do not anastomose.

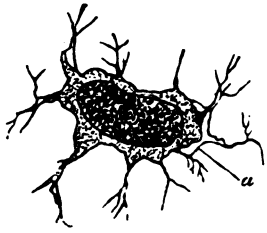

FIG. 52.—Bone Cell and Lacuna. (Joseph.) At *a* the cell body has shrunken, allowing the outline of the lacuna to be seen.

The basement substance or matrix has a fibrous structure, closely resembling that of fibrillar connective tissue, and it is in this fibrillar matrix that the lime salts are deposited. The fibrils are held together by cement substance into bundles. In most bone the bundles are fine and arranged in layers or *lamellæ.* Less commonly the fibre bundles are coarser and have an irregular arrangement.

TECHNIC

(1) For the study of the minute structure of bone a section of undecalcified or hard bone is required. Part of the shaft of one of the long bones is soaked for several days in water and all the soft parts are removed. It is then placed in equal parts alcohol and ether to remove all traces of fat and thoroughly dried (the handle of a tooth or nail brush frequently furnishes good material and is already dried). Thin longitudinal and transverse sections are now cut out with a bone saw. One surface is next ground smooth, first on a glass plate, using emery and water, then on a hone. The specimen is now fastened polished side down on a block of wood or glass by means of sealing wax, and the other side polished smooth in the same manner as the first, the bone being ground as thin as possible. The sealing wax is removed by soaking in alcohol and the specimen looked at with the low power. If not thin enough, it is gently rubbed on a fine hone. It is then soaked in equal parts alcohol and ether, dried thoroughly, and mounted in hard balsam. This is accomplished by placing a small bit of hard balsam on a slide, melting, pushing a bit of the bone into the hot balsam, covering and cooling as quickly as possible. The object of the hard balsam and quick cooling is to prevent the balsam running into the lacunæ and canaliculi and obscuring them by its transparency. The air imprisoned in the lacunæ and canaliculi causes them to appear black when viewed by reflected light.

(2) The structure of the bone cell is best studied in sections of decalcified bone which has first been carefully fixed. (See technic 1, p. 202.)

CHAPTER VIII

THE BLOOD

BLOOD is best considered as a tissue, the intercellular substance of which is fluid. This fluidity of the intercellular substance allows the formed elements or cells to move about freely, so that there is not the same definite and fixed relation between cells and intercellular substance as in other tissues. There are about 5 litres of blood in the adult body, blood thus constituting about one-thirteenth of the entire body weight.

The fluid intercellular substance or *plasma* is slightly alkaline in reaction. It consists of serum albumen, globulin, fibrinogen and inorganic salts, chiefly the chlorid, carbonate, bicarbonate and phosphate of soda. The reaction of blood is distinctly alkaline, due mainly to the phosphate of soda. Its specific gravity is about 1.030, while that of the whole blood is about 1.060. The bulk of the plasma is about equal to that of the red and the white cells.



FIG. 53.—Cells from Human Blood. × 600. (Technic 2, p. 114.) 1, Red blood cell seen on flat; 2, red blood cell seen on edge; 3, red blood cells forming rouleaux; 4, 4, small and large lymphocytes; 5, mononuclear leucocyte; 6, transitional leucocyte; 7, polymorphonuclear leucocyte, containing neutrophile granules; 8, polynuclear leucocyte, containing eosinophile granules; 9, mononuclear leucocyte, containing basophile granules.

The formed elements of the blood are: (1) Red blood cells (red blood corpuscles, erythrocytes); (2) white blood cells (colorless corpuscles—leucocytes); (3) blood platelets (thrombocytes); (4) blood dust (hæmatokonia).

1. **Red blood cells** (erythrocytes) (Fig. 53, 1, 2, 3) are in man non-nucleated circular discs.[1] Their average diameter is about 7.5μ, their thickness 2μ at the thin centre.[2] A few red blood cells of a diameter of 8μ to 8.5μ (macrocytes) and about the same number of red cells only about one-half the usual diameter (microcytes)

[1] Some observers describe the red blood cell as bell- or cup-shaped. (Lewis: Jour. Med. Research, N. S., vol. v, 1904; Radasch: Anat. Anz. xxviii, 1906. Weidenreich: Ergebn. d. Anat., 1903, 1904, 1909; Arch. f. mikr. Anat., lxi, 1903, lxix, 1906.)

[2] As this is a quite uniform average diameter and as red blood cells are to be seen in almost every microscopic field, the diameter of the red blood cells is frequently used as a unit of microscopic measurement.

are usually present. Red blood cells are biconcave, with rounded edges. Seen on the flat, the difference in thickness between centre and periphery is evidenced by the difference in refraction (Fig. 53, 1). Seen on edge, the shape resembles that of a dumb-bell (Fig. 53, 2). Singly or in small numbers, red blood cells have a pale straw color, due to the presence of hæmoglobin. Redness is apparent only when the cells are seen in large numbers. If fresh blood be allowed to stand for a moment, the red cells are seen to adhere to one another by their flat surfaces, forming rows or rouleaux (Fig. 53, 3).

Subjected to the usual technic, the red blood cell appears homogeneous. By the use of special methods, this apparently homogeneous substance can be separated into (*a*) a color-bearing proteid—*hæmoglobin*, and (*b*) a *stroma*, the latter representing the protoplasm of the cell. Peripherally the stroma probably forms an extremely delicate cell membrane, although the presence of any membrane whatever is denied by some. It is the hæmoglobin which gives color to the corpuscles. Hæmoglobin is a complex proteid, which can be resolved into a globulin and a pigment, *hæmatin*. It is held in solution or in suspension in the stroma.

Red blood cells are soft and elastic, and are easily twisted to accommodate themselves to the smallest capillaries. This elasticity results in their assuming many shapes, the most common next to their disc shape being that of a cup or cap.

The red blood cell is extremely susceptible to changes in the plasma. Thus even slight evaporation of the plasma results in osmosis between the now denser surrounding fluid and the contents of the cell. This causes fluid to leave the cell, with the result that the latter becomes spheroidal and irregularly shrunken, with minute knob-like projections from its surface. This is known as *crenation* of the red cell. The addition of water to blood, thus decreasing the specific gravity of the plasma, has the opposite effect, resulting in swelling of the cell. It also causes solution of the hæmoglobin, which leaves the cell, the latter then appearing colorless, with a faint circular outline—the membrane of the cell. This separation of the hæmoglobin from the corpuscle is also caused by freezing and thawing, by heat (60°C.), by the addition of dilute acids, ether, or chloroform.

Dilute alkaline solutions and bile first cause the red corpuscles to swell and become spherical, and then to dissolve. This is known as *hæmolysis*, and may also be effected by mixing the blood of one species with that of another. Dilute acetic acid causes swelling and

fading of the red cells, with the formation of prismatic crystals of hæmoglobin.

The red blood cells number from 4,500,000 to 5,000,000 per cubic millimeter of blood.

2. **White blood cells** (leucocytes) (Fig. 53, 4 to 9 inclusive) are colorless nucleated structures which have a generally spherical shape, but which are able to change their shape on account of their powers of amœboid movement. They have a diameter of from 5 to 10μ, and are much less numerous than the red cells, the proportion being about one white cell to five hundred red cells, or about 10,000 to the cubic millimeter. This proportion is, however, subject to wide variation.

Leucocytes may be classified as follows: (*a*) Lymphocytes; (*b*) mononuclear leucocytes; (*c*) transitional leucocytes; (*d*) polymorphonuclear or polynuclear leucocytes.

(*a*) LYMPHOCYTES (Fig. 53, 4).—These vary in diameter from 5 to 8μ, and are sometimes subdivided into small lymphocytes and large lymphocytes. The nucleus is spherical, stains deeply, and almost completely fills the cell, the cytoplasm being confined to a narrow zone around the nucleus. Lymphocytes constitute about 20-per-cent. of the white blood cells.

(*b*) MONONUCLEAR LEUCOCYTES (Fig. 53, 5 and 9) are of about the same size as large lymphocytes. The nucleus, however, stains more faintly and is smaller, while the cytoplasm is greater in amount. From 2-per-cent. to 4-per-cent. of the white cells are mononuclear leucocytes.

(*c*) TRANSITIONAL LEUCOCYTES (Fig. 53, 6) occur in about the same numbers as the preceding, and are of about the same size. There is relatively more cytoplasm, and the nucleus, instead of being spherical, is crescentic or horseshoe or irregular in shape. These cells represent a transitional stage between the mononuclear and the polymorphonuclear and polynuclear varieties.

(*d*) POLYMORPHONUCLEAR AND POLYNUCLEAR LEUCOCYTES (Fig. 53, 7, 8) constitute about 70-per-cent. of the white blood cells. Their size is about the same as that of the mononuclear form, but they are somewhat more irregular in shape. The appearance of the nucleus is characteristic. In the polymorphonuclear form the nucleus consists of several round, oval, or irregular nuclear masses connected with one another by cords of nuclear substance. These cords are frequently so delicate as to be distinguished with difficulty. The

polynuclear form is derived from the polymorphonuclear by breaking down of the connecting cords, leaving several separate nuclei or nuclear segments.

Granules in small numbers may be present in the protoplasm of any of the leucocytes, but the protoplasm of about 70 per cent. of all leucocytes is so distinctly and regularly granular that by some authors a primary division into granular leucocytes and non-granular leucocytes is made. Under this classification, lymphocytes and some mononuclear leucocytes are placed in the non-granular group, while transitional leucocytes, polymorphonuclear leucocytes and some mononuclear leucocytes, are placed in the granular group. Aniline dyes may be divided into acid, basic and neutral, according to whether the coloring matter is an acid, a base, or a combination of an acid and a base, and the granules of the granular leucocytes react in a definite manner to these dyes, thus allowing the following classification:

Granular leucocytes
1. neutrophile.
2. acidophile (eosinophile).
3. basophile.

As the neutrophile granules are fine and the eosinophile granules coarse, a classification of leucocytes into finely granular and coarsely granular is sometimes made.

1. *Neutrophile Leucocytes.*—These are the most numerous of all leucocytes, making up about 68 per cent. Their protoplasm is thickly studded with very fine granules which stain violet with a mixture of eosin (acid) and toluidin blue (basic). Most neutrophiles are polymorphonuclear, a few are transitional. They have a wide distribution, being found not only in the blood itself, but in the spleen and lymph nodes and as wandering cells in various tissues and organs.

2. *Acidophile Leucocytes* or, because the most common acid dye used is eosin, eosinophile. The granules in these cells are coarse and sharply defined. They stain strongly with acid dyes. Eosinophiles are mainly polymorphonuclear, more rarely they are transitional. They make up from 1 per cent. to 4 per cent. of all leucocytes. In certain pathological conditions their number is greatly increased.

3. *Basophile Leucocytes.*—The granules in these cells are rather coarse and irregular in shape and are distributed unevenly through

the cytoplasm. They stain strongly with basic dyes. They are present in small numbers (Ehrlich, 0.2 per cent. to 0.5 per cent.) in normal blood, or they may not be demonstrable. Ehrlich identifies them with the "mast cells" which are found in various tissues and organs, especially in areolar connective tissue, but this identity has been questioned.

Upon the basis of the foregoing description the following classification of leucocytes on the basis of granulation may be made.

- Leucocytes
  - Non-granular
    - Lymphocytes 22-25 per cent.
    - Mononuclear leucocytes 1-4 per cent.
  - Granular
    - Neutrophile 65-72 per cent. (mainly polymorphonuclear, few transitional and mononuclear)
    - Acidophile 1-4 per cent. (mainly polymorphonuclear, few transitional and mononuclear)
    - Basophile 0.2-0.5 per cent. (mononuclear and transitional)

The function of the red cells is primarily the carrying of oxygen from the lungs to the tissues and of carbonic acid from the tissues to the lungs. This oxygen-carrying ability is dependent upon the hæmoglobin and is directly proportionate to the number of red cells and to the richness of the individual cells in hæmoglobin. In the capillaries of the tissues and again in the capillaries of the lung the hæmoglobin is undergoing constant change. The hæmoglobin of arterial blood is known as oxyhæmoglobin, of venous blood as reduced hæmoglobin. The difference is readily demonstrable by the spectroscope.[1]

Amœboid Movement.—That leucocytes possess in a marked degree the power of amœboid movement has been noted (p. 52). On account of this motility leucocytes are able (1) to leave the blood-vessels (diapedesis) and move about freely in the tissues (wandering cells), (2) to surround and take up substances from without (phagocytosis). (See also p. 52.)

Diapedesis.—This power is directly dependent upon motility and while possessed by all leucocytes is most markedly characteristic of the polymorphonuclear forms.

Phagocytosis.—Phagocytic powers are not possessed equally by all leucocytes, but are confined largely to the mononuclear

[1] Of interest in this connection is the fact that in poisoning by illuminating gas, a very definite and stable combination of the carbon dioxid with the hæmoglobin is formed (carboxyhæmoglobin). It is this substance which determines the darker red color of the blood in this condition and is apparently the cause of death.

and polymorphonuclear forms. Such cells can take up foreign substances, bacteria, degeneration products, etc., carry them to other parts of the body or entirely outside the body (salivary corpuscles), or apparently absorb or digest them. (See also p. 52.)[1]

3. **Blood platelets** (thrombocytes) are minute round or oval bodies from 2μ to 4μ in diameter. They are colorless and vary in shape. In fixed preparations they often appear stellate. Their number has been variously estimated. The average is probably about 200,000 to 300,000 per cubic millimeter of blood. In the blood stream they are separate, but show a marked tendency to agglutination directly the blood is drawn. Some comparatively recent observations tend toward considering the platelets as true cells. Thus they have been described as amœboid, as having the same chemical composition as cells, and as containing either granules of chromatin or distinct nuclear structures. The so-called thrombocytes of Ovipara are larger than those of man and are unquestionably nucleated cells. Their appearance is, however, wholly unlike human thrombocytes and the identity of the two forms is doubtful.

Various functions have been ascribed to the thrombocytes. Under certain conditions—exposure to air passing over a roughened vessel wall—the fibrinogen is precipitated as fine crystals of fibrin. Thrombin, or prothrombin, probably a blood platelet derivative, is apparently the active element in determining the precipitation of the fibrinogen. The formed elements of the blood are carried down in the precipitation and there is thus formed a solid mass, the blood clot or thrombus, leaving a clear defibrinated fluid almost free from cells, the blood serum. The time required for the clotting of human blood outside the body is usually from two to eight minutes according to conditions. In certain individuals otherwise apparently normal, also in certain diseases, the blood clots more slowly, a matter of some surgical importance.

4. **The blood dust** (hæmatokonia) occurs in the form of small refractive granules.

In the blood of the lower mammals and in herbivorous animals small droplets of fat derived from the chyle are found. They are

[1] It is to be noted that phagocytosis is not confined to leucocytes but has been observed in other cells, *e.g.*, fixed connective-tissue cells including endothelium. It is also to be noted that phagocytic cells are not equally phagocytic to all substances. In other words phagocytes apparently have some powers of selection. Thus if two kinds of bacteria be presented to them, they may take up only one kind, or one kind much more readily than the other.

known as *elementary granules* and are not present in normal human blood.

Development of the Blood

At an early stage of embryonic development certain mesodermic cells of the area vasculosa, which surrounds the embryo, become arranged in groups known as *blood islands*. It is from these "islands" that both blood and blood-vessels develop. The peripheral cells arrange themselves as the primitive vessel walls, within which the central cells soon become free as the first *blood corpuscles*. In this way vascular channels are formed, inside of which are developing blood cells. This division of the mesoblastic cells of the blood islands into (1) endothelial cells of the vessel walls and (2) progenitors of the blood cells or primitive blood cells, is quite generally accepted. From this point, however, opinions diverge, the two main theories of blood-cell formation being known as the polyphyletic and the monophyletic theories.

According to the polyphyletic theory, after the original division of the mesoblast cells of the blood islands into vessel wall cells (endothelium) and blood cells (primary blood cells), the latter go on to the development of erythroblasts and these to the development of erythrocytes. Leucocytes develop later in connective tissue, in the liver, spleen and bone marrow, while lymphocytes have their origin in the germ centers of the lymphoid organs. There are thus three separate sources of blood cells: (1) Red blood cells, originally from erythroblasts of the blood islands; in adult life from the erythroblasts of the bone marrow and possibly of spleen; (2) leucocytes, first in connective tissue, liver, spleen and marrow; in adult life in the marrow; (3) lymphocytes, in the lymphoid organs. According to the polyphyletic theory these three types are genetically independent and remain so throughout life, the cells of each type undergoing mitotic division to produce new cells of the same type only.

According to the monophyletic theory the blood-cell-forming elements of the blood islands fall into two groups as regards their future development: (1) cells which give rise to primary erythroblasts, these to secondary erythroblasts and these again to erythrocytes, thus completing the line of red blood cells, and (2) cells which remain undifferentiated, not only in the embryo but throughout life, and retain the capability of differentiating into erythroblasts or into white blood cells, either leucocytes or lymphocytes. According to Weidenreich[1] and other supporters of this theory, red and white blood cells stand in very close genetic relation. He claims that an undifferentiated mother cell exists which is capable of differentiating either in the direction of the red cell or of the white cell; that this mother cell exists not only in the embryo but throughout life and is constantly giving birth to cells which are to develop into red blood cells or white blood cells to replace those being constantly used up and cast off. Morphologically the mother cell is apparently identical with the lymphocyte. In post-embryonic life, this mother cell is found in marrow in the germ centers of lymphoid organs and possibly in connective tissue. On the other hand a once differentiated cell remains a differentiated cell, and while able to divide mitotically and thus

[1] *Anat. Rec.*, vol. iv., Sept., 1910.

give rise to cells of its own kind, it is never capable of producing cells of any other kind.

Two views are held in regard to the manner in which the embryonic nucleated red cell gets rid of its nucleus in becoming the non-nucleated red cell of the adult. According to one the nucleus is absorbed within the cell and gradually secreted; according to the other the nucleus, as a whole, is extruded.

In early embryonic life especially active proliferation of red cells occurs in the blood-vessels of the liver. This has led to the considering of the liver as a blood-forming organ. The liver cells themselves, however, take no actual part in the formation of blood cells, the blind pouch-like venous capillaries of the liver, with their slow-moving blood currents, merely furnishing a peculiarly suitable place for cellular proliferation. Before birth the splenic pulp and bone marrow become blood-forming organs. In the adult the bone marrow is probably, under normal conditions, the main if not the sole seat of red-cell formation.

During fœtal life the number of nucleated red cells constantly diminishes, while the number of non-nucleated red cells increases. At birth there are usually but few nucleated red cells in the general circulation, although even in the adult they are always found in the red bone-marrow.

The origin of the blood platelets is not known. They have been described as originating in the extruded nuclei of the red cells, as disintegrating leucocyte products, as red cells in process of development, as red cells in process of disintegration, as albuminoid precipitates, as a specific blood cell. According to Wright,[1] they are derived from the megakaryocytes of bone marrow and other blood-forming organs.

TECHNIC

(1) Fresh Blood.—Prick a finger with a sterile needle. Touch the drop of blood to the centre of the slide and cover quickly. For immediate examination of fresh blood no further preparation is necessary. Evaporation may be prevented by cementing, or by smearing a rim of vaseline around the cover-glass.

(2) Blood Smears.—From the same or a second prick take up a drop of blood along the edge of a mounting slide. Quickly place the edge against the surface of a second slide and draw the edge across the surface in such a manner as to leave a thin film or smear of blood. Allow the smear to become perfectly dry and stain by technic 12, p. 32. By this method the acidophile granules are stained red, basophile granules purple, and neutrophile granules a reddish-violet.

Good results may also be obtained by fixing the dried smear for half an hour in equal parts alcohol and ether and staining first in a strong alcoholic solution of eosin, then in a rather weak aqueous solution of methylene blue.

[1] *Jour. Morph.*, xxi, 1910.

CHAPTER IX

MUSCLE TISSUE

WHILE protoplasm in general possesses the property of contractility, it is in *muscle tissue* that this property reaches its highest development. Moreover, in muscle this contractility is along definite



FIG. 54.—Isolated Smooth Muscle Cells from Human Small Intestine. ×400. (Technic 1, p. 129.) Rod-shaped nucleus surrounded by area of finely granular protoplasm; longitudinal striations of cytoplasm.

directions, and is capable of causing motion, not only in the cell itself, but in structures outside the cell.

Muscle may be classified as: (1) Involuntary smooth muscle; (2) voluntary striated muscle; (3) involuntary striated muscle or heart muscle.

Involuntary Smooth Muscle.—This is the simplest form of muscle tissue and consists of long spindle-shaped cells (Fig.

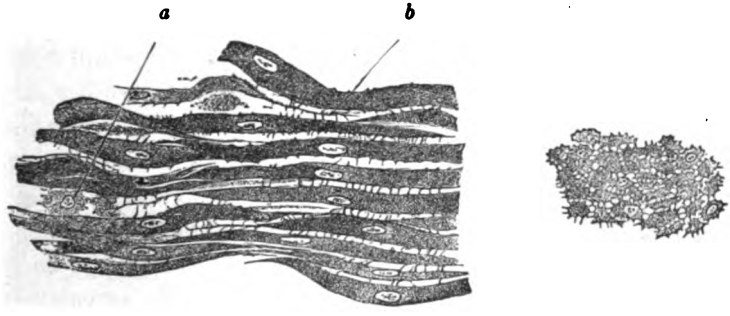

FIG. 55.—Apparent Intercellular Bridges of Smooth Muscle. *A*, From longitudinal section of intestine of guinea-pig; *B*, from transverse section of intestine of rabbit. ×420. *a*, Nerve cell; *b*, end of muscle cell. (Stöhr.)

54) which are prismatic on transverse section (Fig. 55). The length of the smooth muscle cell varies usually from 30 to 200μ, its width from 3 to 8μ,[1] except in the pregnant uterus where the cells frequently attain a much greater size. Less commonly the smooth

[1] In the walls of very small blood-vessels smooth muscle cells 15 to 20μ are found. (Apathy).

muscle cell is flattened, and, in tissues rich in elastic fibres, *e.g.*, the media of some arteries, especially the aorta, is quite irregular in shape. The central thickest part of each cell contains an elliptical or long rod-shaped nucleus. The nucleus has a rather coarse intranuclear network and one or more nucleoli. In some cells a centrosome has been demonstrated. It lies outside and usually just to one side of the nucleus. The irregular, wavy and twisted nuclei often seen are probably due to contractions of the cytoplasm. The nucleus is surrounded by an area of finely granular cytoplasm, most abundant at the poles of the nucleus where it frequently forms a little pointed cap. The rest of the cytoplasm shows delicate longitudinal striations, which probably represent a longitudinal arrangement of the spongioplasm. These fibrils are extremely fine, are frequently present in small numbers, are not arranged in bundles, are apparently homogeneous and anisotropic, and are often very difficult of demonstration. The fibrils lie in a less differentiated cytoplasm. The smooth muscle cell has no such distinct envelop as the sarcolemma of striated muscle. The outer cytoplasm is, however, modified to form a delicate cell membrane or at least a modified surface layer.

FIG. 56.—Preparation of Smooth Muscle Cells to show Fibrillar Structure. From intestine of Triton. ×2300. (Heidenhain.)

The cells are united by a small amount of intercellular "cement" substance which reacts to silver nitrate. Intercellular "bridges" similar to those connecting epithelial cells have been described (Fig. 55), but are regarded by many observers as artefacts. By others fine

intercellular fibrils are described as continuous from cell to cell, thus forming a syncytium. Between and surrounding the smooth muscle cells is a network of delicate connective-tissue fibrils (Fig. 57).

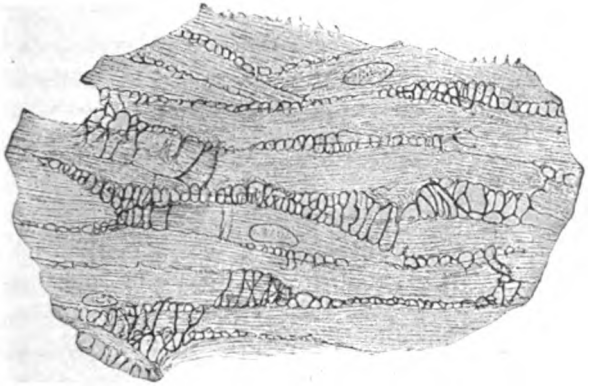

FIG. 57.—Longitudinal Section of the Musculature of Cat's Intestine to show Intercellular Connective Tissue. (Bohemann.)

These are not apparent in sections which have been subjected to the usual technic, but can be demonstrated either by digesting the smooth muscle cells by means of trypsin, thus bringing out the undigestible collagenous fibrils, or by special staining methods.

FIG. 58.—Elastic Fibres in the Smooth Muscle of Intestine of Cat. (Holmgren.)

Smooth muscle cells may be arranged in layers of considerable thickness, the cells having a definite direction, as in the so-called "musculature" of the intestine (Figs. 58 and 59). In such masses

of smooth muscle the cells are separated into groups or bundles by connective tissue. Smooth muscle cells may be arranged in a sort of network, the cells crossing and interlacing in all directions, as in the wall of the frog's bladder. Again, they may be scattered in small groups or singly among connective-tissue elements, as in the villi of the small intestine and in the capsules and trabeculæ of some glands.

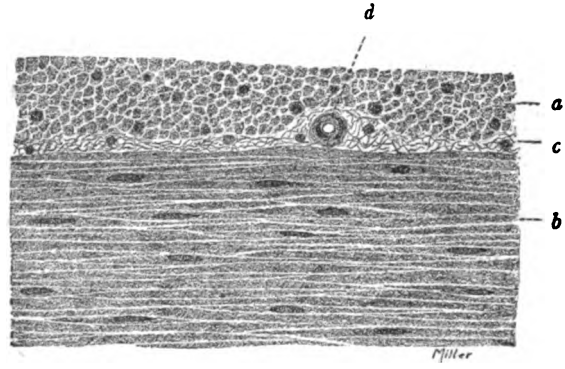

FIG. 59.—Smooth Muscle from Longitudinal Section of Cat's Small Intestine, showing Portions of Inner Circular and Outer Longitudinal Muscle Coats with Intervening Connective Tissue. ×350. (Technic 3, p. 129.) *a*, Transversely cut cells of inner circular layer; in comparatively few has the plane of section passed through the nucleus; *b*, longitudinally cut cells of outer longitudinal layer. In many of the cells the plane of section has not passed through the nucleus; *c*, intermuscular septum (connective tissue); *d*, small artery.

Voluntary Striated Muscle.—This consists of cylindrical fibres from 50 to 130 mm. in length and from 10 to 100μ in diameter. Generally speaking, the fibres of greater diameter are found in the larger animals. There is apparently no relation between the size of the muscle and either the length or diameter of its component fibres. There is also no relation of length to diameter, within the same muscle, fibres of many different sizes intermingling.

Each muscle fibre consists of a delicate sheath, the *sarcolemma*, enclosing the *muscle substance proper*, in which lie the *muscle nuclei*.

The *sarcolemma* is a clear, apparently structureless, very elastic membrane, which adheres so closely to the underlying muscle substance as to be indistinguishable in most preparations. In teased specimens it may frequently be seen at the torn ends of the fibres (Fig. 60). In staining reaction it differs from both white and elastic tissue and is apparently to be considered a distinct cell membrane.

The *muscle substance* consists of *ergastoplasm* (*fibrillæ*) and

sarcoplasm (interfibrillar substance) and shows two sets of striations (Fig. 61), longitudinal striations and cross striations. The longitudinal striations are due to parallel running ultimate fibrillæ (Fig. 61, *a*), which lie in and are more or less separated from one another by the sarcoplasm. Each fibrilla when examined, unstained, by reflected light is seen to be composed of alternating light and dark segments. As like segments lie in the same transverse plane, the whole muscle fibre appears composed of alternate light and dark bands (Figs. 61 and 62), and this distinction is maintained even in stained specimens, as the light bands stain little if any, with most staining agents, while the dark bands react strongly to stains. The light band is composed of a singly refracting (isotropic) substance, the dark band of a doubly refracting (anisotropic) substance. Through the middle of the light band runs a fine line (*Krause's line*, Fig. 61, *c*, 62, *c*), while an even finer line (*Hensen's line*, Fig. 61, *a*, 62, *a*) can sometimes be seen running through the middle lighter portion of the dark band. Both Krause's and Hensen's lines cross the intervening sarcoplasm as well as the fibrillæ and extend to the sarcolemma, thus completely crossing the fibre. As all of these structures run through the entire thickness of the fibre, they in reality constitute *discs* of muscle substance (Fig. 62). By means of certain chemicals these discs may be separated, the separation taking place along the lines of Krause. Each "muscle disc" thus consists of that portion of a fibre included between two adjacent lines of Krause and is composed of a central dark disc, and on either side one-half of each adjacent light disc. A muscle fibre is thus seen to be divisible longitudinally into *ultimate fibrillæ* (Fig. 61, *a*), transversely into *mus-*

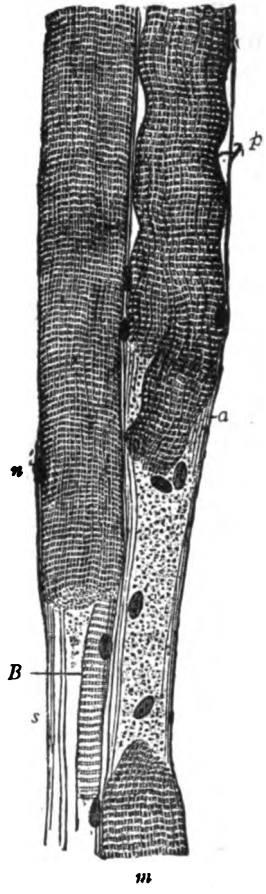

FIG. 60.—Semidiagrammatic Drawing of Parts of two Muscle Fibres which have been broken, showing the relations between Muscle Substance Proper and Sarcolemma (Ranvier.) *m*, *a*, Retracted ends of muscle substance, between which is seen the sarcolemma with several adherent muscle nuclei; *B*, thin layer of muscle substance which has adhered to the sarcolemma; *n*, muscle nucleus; *s*, sarcolemma; *p*, space between sarcolemma and muscle substance.

cle discs (Fig. 62, *f*). What is known as the *sarcous element of Bowman* is that portion of a single fibrilla which is included in a single disc, *i.e.*, between two adjacent lines of Krause (Fig. 62, *b*).

The *sarcoplasm* is not evenly distributed throughout the fibre. On cross section irregular trabeculæ of sarcoplasm are seen extending in from the sarcolemma (Fig. 63). These separate the fibrillæ into bundles, the *muscle columns of Kölliker*. A transverse section



FIG. 61.

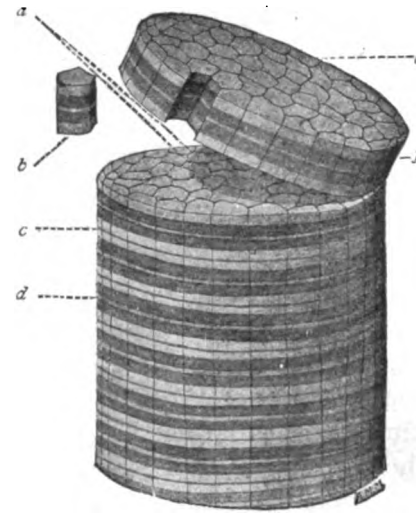

FIG. 62.

FIG. 61.—Portion of Striated Voluntary Muscle Fibre. ×350. (Technic 4, p. 129.) The fibre is seen to be marked transversely by alternate light and dark bands. Through the centre of the light band is a delicate dark line (Krause's line); through the centre of the dark band a fine light line indicates Hensen's line. The black line outlining the fibre represents the sarcolemma. *a*, Fibrillæ; *b*, muscle nucleus; *c*, Krause's line; *d*, Hensen's line.

FIG. 62.—Diagram of Structure of a Muscle Column of Kölliker. The appearance presented by the cross-cut muscle column = Cohnheim's field. *a*, Muscle fibrillæ; *b*, sarcous element; *c*, Krause's line; *d*, Hensen's line; *e*, Cohnheim's field; *f*, muscle disc.

of one of these columns presents the appearance of a network of sarcoplasm and of interfibrillar cement substance enclosing the fibrillæ. This appearance is known as *Cohnheim's field* (Figs. 62 and 63).

Many of the details of structure of striated muscle have been determined by studies upon the muscles of lower animals, more particularly of the wing muscles of insects. These details are extremely complicated and the numerous terms

used to designate the same structure very confusing. The following is the scheme of structure and the nomenclature according to Heidenhain (Fig. 64).

The older terms *muscle cell* for the smooth muscle cell, and *muscle fibre* for the analogous multinuclear element of striated muscle are retained, also Apathy's *myofibril* for the ultimate fibrilla, Kolliker's *muscle column* for the smallest bundles of fibrils, and *sarcoplasm* for interfibrillar substance.

The muscle fibre is subdivided into a series of segments by transverse discs which completely cross the fibre, involving both fibrillæ and sarcoplasm and are attached to the sarcolemma. This disc (ground membrane—membrane of Krause) Heidenhain designates the *telophragma* (Z). That part of a fibre which lies between two telophragmata is an *inokomma*. The middle of each inokomma is crossed by a disc (Hensen's membrane) which also involves both fibrillæ

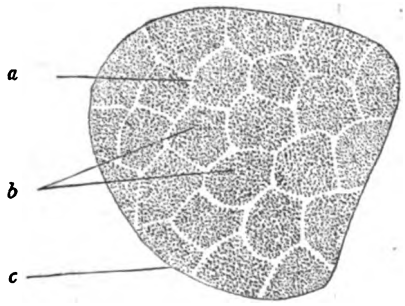

FIG. 63.—Semidiagrammatic Drawing of Transverse Section of a Voluntary Muscle Fibre, showing Sarcolemma; sarcoplasm separating fibrils into bundles, each bundle constituting a muscle column of Kölliker and the appearance of its cross-cut end being Cohnheim's field. *a*, Sarcoplasm; *b*, Cohnheim's fields; *c*, sarcolemma.

and sarcoplasm and is attached to the sarcolemma. This membrane having apparently the same structure as the telophragma is designated the *mesophragma* (M). The mid-portion of the inokomma consists of an isotropic substance (Q), the ends of isotropic (J). That portion of Q which lies on either side of M is lighter than the rest of Q and is designated Qh(h = hell = clear). That portion of J which lies close on either side of Z is darker than the rest of J and is designated Jd(d = dicht = thick). In the sarcoplasm between the fibrillæ are granules; those in J are arranged in a regular row and are known as J-granules, those in Q are more irregularly placed and are known as Q-granules. In Fig. 64 are also shown the "cross-fibre-nets" which are brought out by metallic impregnation and which possibly represent intracellular canals.

Two varieties of striated voluntary muscle fibres are distinguished, *white fibres* and *red fibres*. The difference between the two is due to the relative amounts of myofibrillar and of sarcoplasmic substances, the white fibres being made up of closely placed myofibrils with little sarcoplasm while in the red fibres the sarcoplasm is much more abundant. Red fibres are somewhat more slender than white, and contain deeply placed nuclei in addition to the nuclei just

beneath the sarcolemma. White fibres contract more rapidly than red, but, containing, as they do, less undifferentiated protoplasm (sarcoplasm), are more easily fatigued under the strain of oft repeated contractions. In man white fibres are in the large majority, red

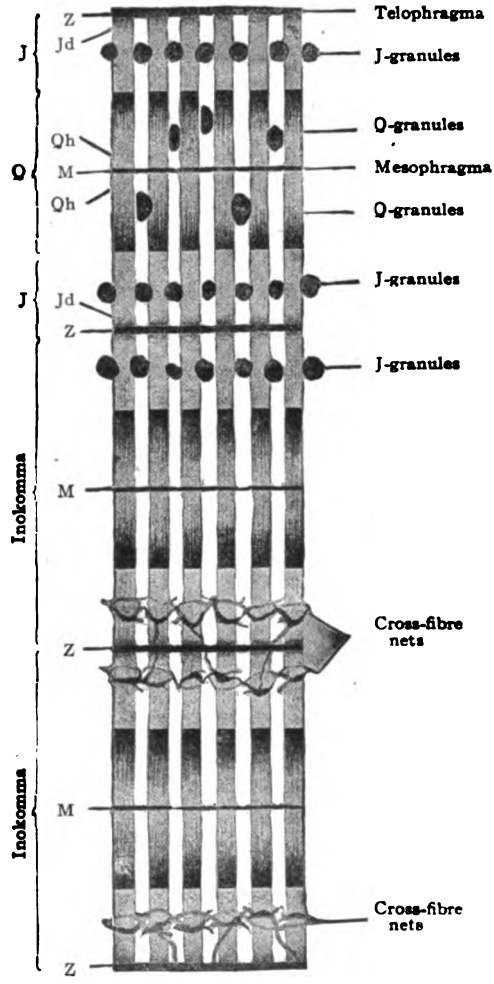

FIG. 64.—Scheme of Structure of Striated Voluntary Muscle Fibre with Nomenclature of Heidenhain. (Heidenhain.)

fibres never occurring alone, but mingled with white fibres in some of the more active muscles, such as those of respiration and mastication. In some of the lower animals are found muscles made up wholly of red fibres.

Muscle fibres ending within the substance of a muscle have pointed extremities. Where muscle fibres join tendon, the fibre ends in a rounded or blunt extremity. Details of the exact union of muscle fibre and tendon are disputed. According to some the sarcolemma completely envelops the end of the fibre (Fig. 65*a*) and to this are attached the terminal fibrils of the tendon, the granules along the junction being considered by some as belonging to a sort of tendo-muscular cement substance. According to others the sarcolemma passes off from the muscle fibre to become continuous with the tendon fibres. More recently attempts have been made to prove the direct continuity of myofibril with the tendon fibre. Probably much of the union between muscle and tendon depends upon the continuity or at least upon the intermingling of tendon fibres with the inter- and intrafascicular connective tissue (p. 212) (see also pp. 212–214 and Figs. 128, 129, 130).

Muscle fibres are usually unbranched. In some muscles—*e.g.*, those of the tongue and of the eye—anastomosing branches occur. When muscle fibres end in mucous membranes—*e.g.*, the muscle fibres of the tongue—their terminations are often branched.

Muscle fibres are multinuclear, some of the large fibres containing hundreds or even thousands of nuclei.[1] In the white fibres the nuclei are situated at the periphery just beneath the sarcolemma. In red fibres some of the nuclei are centrally placed.

Involuntary Striated Muscle (Heart Muscle).—This, as its name implies, is a striated muscle not under control of the will. It occurs only in the cardiac musculature. Like voluntary muscle, heart muscle is striated both longi-

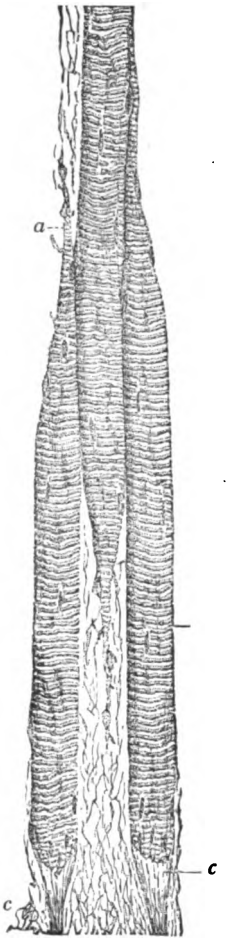

FIG. 65.—Semidiagrammatic Illustration of Endings of Muscle Fibres within a Muscle and in Tendon. (Gage.) *a*, Tapering end of fibre terminating within the muscle; the lower end of the central fibre shows the same method of termination; *c*, *c*, each fibre terminates above in pointed intramuscular ending, below in blunt ending connected with tendon.

[1]Stöhr calls attention to the fact that such a structure may be considered either a multinuclear cell or a syncytium and that there is really no true distinction between the two.

tudinally and transversely. Like smooth muscle, on the other hand, it is composed of units which at least resemble cells and have long been called heart muscle cells. Heart muscle also resembles smooth muscle in that there is usually but one nucleus to a cell and this nucleus is centrally placed instead of lying at the periphery as in voluntary muscle. Also the sarcolemma if present at all is extremely delicate and is probably, as in smooth muscle, only a modification

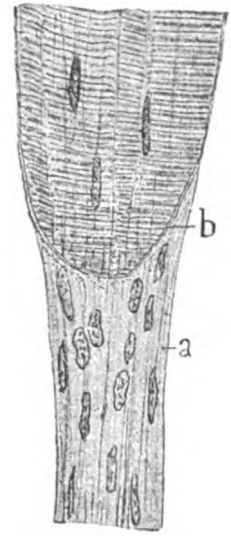

FIG. 65*A*.—Union of a Muscle Fibre with a Tendon Fasciculus. (Cajal.) *a*, White fibres; *b*, Sarcolemma.

of the surface sarcoplasm. The amount of sarcoplasm throughout the cell is large. Around the nucleus is an area of sarcoplasm free from fibrillæ. This area often extends some distance toward the ends of the cell.

Heart muscle fibres are not the parallel-running, unbranched fibres of voluntary muscle, but, while having a generally parallel arrangement, give off side branches which anastomose, making it impossible to trace a single fibre for any great distance. These side branches have the same structure as the main fibre except that they are for the most part of smaller diameter and are non-nucleated.

The striations of heart muscle are less distinct than are those of voluntary muscle, but apparently represent very similar structures. The longitudinal striations indicate *fibrillæ* lying in the sarcoplasm.

From the central mass of sarcoplasm which surrounds the nucleus, strands radiate toward the periphery. These strands, anastomosing, separate the fibrillæ into columns, the *muscle columns of Kölliker.* In cross section these present the appearance described under voluntary muscle as *Cohnheim's fields.* The disposition of the sarcoplasm, extending outward from the region of the nucleus like the spokes of a wheel, gives to the cross section a characteristic radiate appearance (Fig. 68), not seen in cross sections of voluntary muscle. The transverse markings represent, as in voluntary muscle, alternate *light* and *dark discs.* Through the middle of the light disc can be

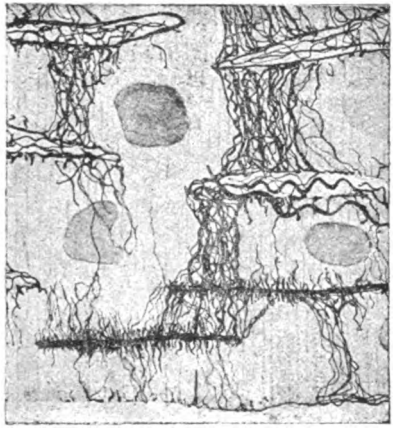

FIG. 65*B*.—Connective Tissue of Human Heart Muscle (Cajal after Achúcarro and Calandre).

seen the *membrane of Krause.* McCallum describes Krause's membrane as crossing not only the fibrillæ, but also the sarcoplasm, as in the voluntary muscle fibre. The sarcoplasm he describes as further subdivided by membranes, which are transversely continuous with Krause's membranes, into minute discs. The centre of the cell around the nucleus is wholly composed of these little discs of sarcoplasm.

Peculiar to heart muscle are what appear in longitudinal sections to be dark lines which cross transversely both main fibres and side branches. These are known as *intercallated discs* and divide the muscle fibre into irregular, short, thick cylindrical segments (Fig. 69). A disc may pass straight across a fibre, or it may cross it in a series of steps, or it may extend only part way across the fibre. It always

touches at some point one of the ground membranes[1] and sometimes entirely fills the space between two ground membranes which lie unusually close together. Special technic has demonstrated the fact that the fibrillæ do not stop at the disc but are continuous through it, although they show in passage some modification of structure.

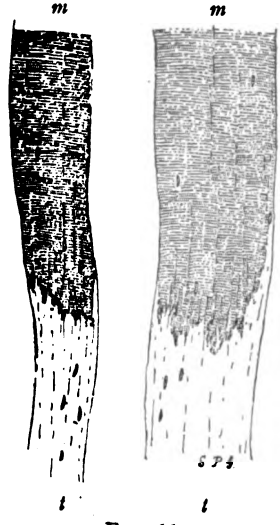

FIG. 66.

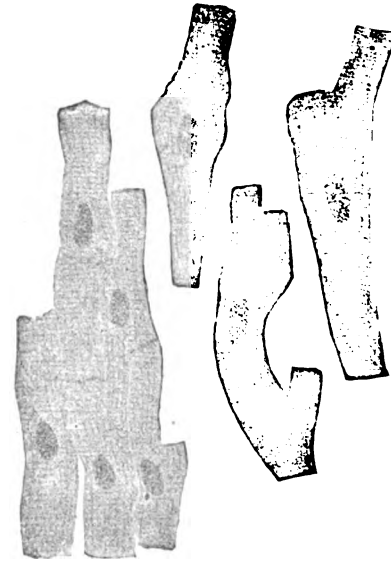

FIG. 67.

FIG. 66.—Two Muscle Fibres from Upper End of Human Sartorius, to show connection of muscle and tendon. ×350. (Gage.) *m*, Muscle fibres; *t*, tendon fibres.

FIG. 67.—Muscle Cells from the Human Heart (technic 6, p. 129), showing lateral branches and lines of union between cells. ×500.

The one question which has been most discussed in regard to the structure of heart muscle and which remains still unanswered is whether heart muscle is cellular or a syncytium. The solution of the problem is of course dependent upon the determination of the significance of the intercalated discs—whether or not they represent true cell boundaries. The segments into which the heart muscle fibre is divided by the discs have long been described as cells. The fact that the nuclei are usually placed about midway between two discs; that the discs show the same staining reaction as intercellular substance when subjected to the action of silver nitrate, and the ease with which heart muscle may be separated into "cells," especially in young animals and in lower vertebrates, by use of those chemicals usually used to break down intercellular cement; have all been used as arguments in favor of a cellular structure. On the other hand, the fact that it has not been proved that the segments bounded by the discs correspond to the original myoblasts; that in the later stages of development of heart muscle the type of nuclear division is usually amitotic, a type frequently unac-

[1] Some authorities deny this.

companied by division of the cytoplasm; that the fibrillæ pass uninterrupted through the discs; that some discs only partially cross a fibre; that some segments contain more than one nucleus while others are non-nucleated; all favor a syncytial interpretation. How open the question still remains is shown by the fact that Heidenhain regards the "cells" as "growth segments"; that Marceau considers them non-contractile "supports" for the fibrillæ; that Jordan from his work on humming-birds concludes that they are a coarser development of the anisotropic bands; while Schaffer looks upon them as post-mortem contraction artefacts.

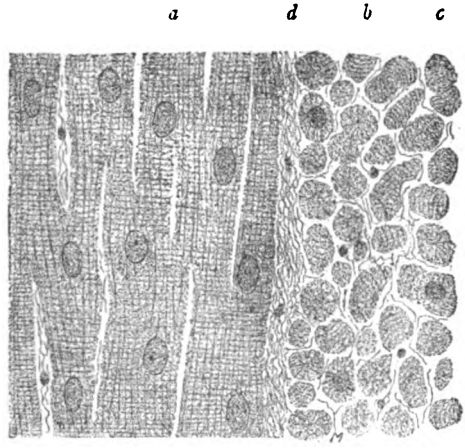

FIG. 68.—Section of Heart Muscle. ×350. (Technic 7, p. 129.) *a*, Cells cut longitudinally; *b*, cells cut transversely (only three nuclei have been included in the plane of section); *c*, cells cut obliquely; *d*, connective-tissue septum.

DEVELOPMENT OF MUSCLE TISSUE

Smooth Muscle.—In the higher animals, muscle tissue with the exception of that connected with the sweat, lacrymal and mammary glands, which is of ectodermic origin, is derived wholly from mesoderm. The cells (myoblasts) which are to become smooth muscle cells develop in the general mesenchymal tissue among cells which are to become connective-tissue cells and with which they are at first apparently identical. In becoming a smooth muscle cell the myoblast changes its shape, becoming greatly elongated, its nucleus at the same time becoming oval or rod shaped. Such cells anastomose freely. During these changes in shape, delicate longitudinal fibrils appear in the cytoplasm. Just how these fibrils originate is not known, but they probably represent a specialization and rearrangement of the spongioplasm.

Striated Voluntary Muscle.—This develops from the mesoblastic somites. Each somite early divides into an outer part, sclerotome or cutis plate, and an inner part, the myotome or muscle plate. Cells of the myotome soon show changes which distinguish them as myoblasts or muscle-forming cells. These cells, which are at first spherical, become elongated and spindle shaped. The nucleus is at this stage centrally placed and the spongiplasm is in the form of a reticulum.

Fibrillar arrangement of the spongioplasm first appears around the periphery where granules form in the cytoplasm and become arranged in rows lengthwise of the cell. The central portion of the cell is at this stage still occupied by reticular spongiolasm and the nucleus. These granules next unite to form delicate fibrils. New fibrils form both by longitudinal arrangement of more granules

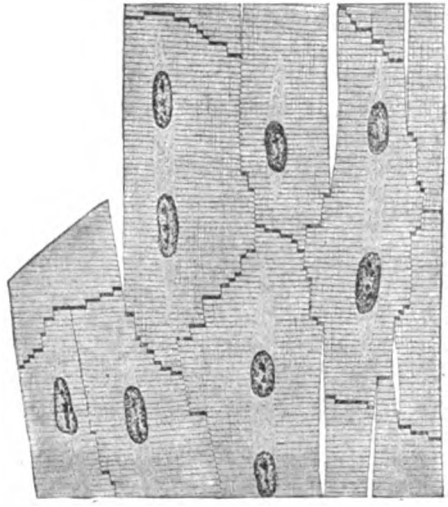

FIG. 69.—Longitudinal Section of Heart Muscle of Rabbit (Werner) showing cross and longitudinal striations and intercalated discs. In several "areas" two nuclei are seen.

FIG. 70.—Longitudinal Section of Heart Muscle (Przenoski), showing continuity of fibrils through intercalated disc.



FIG. 71.—Myoblasts in Different Stages of Development. (Godlewski.)
The upper cell represents a myoblast with granular cytoplasm (from sheep embryo of 13 mm.); the middle, a myoblast with fibrils in process of formation (from guinea-pig embryo of 10 mm.); the lower, a myoblast with still further differentiated, segmented fibrils (from a rabbit embryo of 8.5 mm.).

and by longitudinal splitting of fibrils already formed, until they finally fill the entire cell. After the union of the granules to form fibrils the latter are apparently homogeneous, but later differentiate into the alternate light and dark substances which determine the cross striations characteristic of striated muscle. Just how this differentiation takes place is not known. During this

process of fibrillation the nucleus has been undergoing mitotic division without corresponding division of the cytoplasm. In white fibres these nuclei migrate to the surface and come to lie just beneath the sarcolemma. The sarcoplasm in which the fibrils lie probably represents the remains of the undifferentiated protoplasm (hyaloplasm).

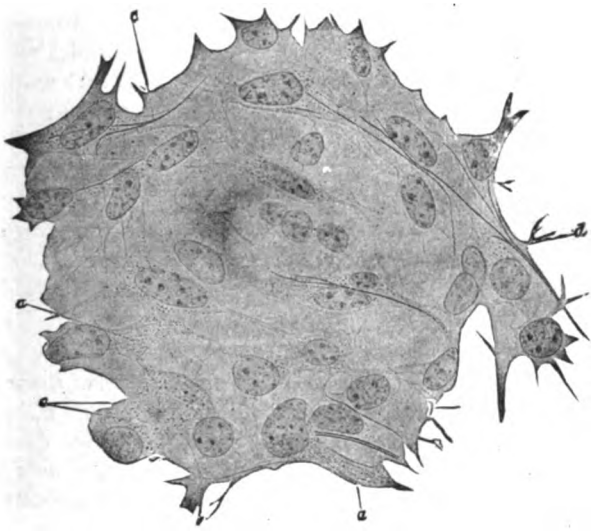

FIG. 72.—From a Section of Developing Heart Muscle from a Rabbit Embryo of 9 mm. (Godlewski.)

a, Cell body with granules arranged in series; *b*, cell body with centrosome and attraction sphere; *c*, branching fibril; *d*, fibrils extending through several cells.

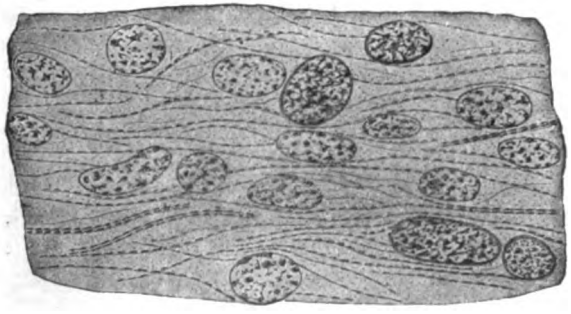

FIG. 73.—From a Section of Developing Heart Muscle in a Rabbit Embryo of 10 mm. (Godlewski.)

The fibrils are segmented, indicating the beginning of the cross striation characteristic of heart muscle.

Some authorities deny the origin of the muscle fibre from a single cell, describing it as derived from a number of myoblasts which unite to form a fibre.

Heart muscle develops from mesenchyme. The myoblasts are at first small, spheroidal, and closely arranged. With the appearance of intercellular substance

the cells become seprated and irregular in shape, and anastomose to form a syncytium. A little later the cells become arranged in parallel columns and cross markings, the "intercalated discs" appear, dividing the syncytium into the so-called "heart-muscle cells." Whether these coincide with the original myoblasts is not known. As in voluntary muscle, fibrils first develop in the periphery of the cell apparently by union of granules which arrange themselves in lines lengthwise of the cell. The fibrils increase in number and invade the entire cell except the small area of undifferentiated protoplasm which remains around the nucleus. Later the fibrils show the alternate light and dark markings or cross striations. As with voluntary muscle the way in which these cross markings develop is not known.

Attention has already been called (p. 53) to the spongioplasm as the contractile element of protoplasm. It is to be noted that in the development of muscle no new element appears, the *contractile fibrillæ representing nothing more than a specialization of the already contractile spongioplasm.*

TECHNIC

(1) Isolated Smooth Muscle Cells.—Place small pieces of the muscular coat of the intestine in 0.1-per-cent. aqueous solution of potassium bichromate, or in 30-per-cent. alcohol for forty-eight hours. Small bits of the tissue are teased thoroughly and mounted in glycerin. Nuclei may be demonstrated by first washing the tissue and then staining for twelve hours in alum carmine (p. 22). This is poured off, the tissue again washed in water and preserved in eosin-glycerin, which gives a pink color to the cytoplasm.

(2) Potassium hydrate in 40-per-cent. aqueous solution is also recommended as a dissociater of smooth muscle cells. Pieces of the muscular coat of the intestine are placed in this solution for five minutes, then transferred to a saturated aqueous solution of potassium acetate containing 1-per-cent. hydric acetate for ten minutes. Replace the acetate solution by water, shake thoroughly, allow to settle, pour off water, and add alum-carmine solution (p. 22). After twelve hours' staining, wash and transfer to eosin-glycerin.

(3) Sections of Smooth Muscle.—Fix small pieces of intestine in formalin-Müller's (technic 6, p. 7) or in Zenker's fluid (technic 10, p. 8). Thin transverse or longitudinal sections are stained with hæmatoxylin-eosin (technic 1, p. 23), and mounted in balsam. As the two muscular coats of the intestine run at right angles to each other, both longitudinally and transversely cut muscle may be studied in the same section.

(4) Striated Voluntary Muscle Fibres.—One of the long muscles removed from a recently killed animal is kept in a condition of forced extension while a 1-per-cent. aqueous solution of osmic acid is injected into its substance at various points by means of a hypodermic syringe. Fixation is accomplished in from three to five minutes. The parts browned by the osmic acid are then cut out and placed in pure glycerin, in which they are teased and mounted.

(5) Sections of Striated Voluntary Muscle.—Fix a portion of a tongue in formalin-Müller's fluid or in Zenker's fluid (p. 8). Thin sections are stained with hæmatoxylin-picro-acid-fuchsin (technic 3, p. 24) and mounted in balsam.

As the muscle fibres of the tongue run in all directions, fibres cut transversely, longitudinally, and obliquely may be studied in the same section. The sarcolemma, the pointed endings of the fibres, and the relation of the fibres to the connective tissue can also be seen.

(6) Isolated heart-muscle cells may be obtained in the same manner as smooth muscle cells. (See technic 1, above.)

(7) Sections of Heart Muscle.—These are prepared according to technic 3 (above). By including the heart wall and a papillary muscle in the same section, both longitudinally and transversely cut cells are secured. The stain may be either hæmatoxylin-eosin (technic 1, p. 23), or hæmatoxylin-picro-acid-fuchsin (technic 3, p. 24).

CHAPTER X

NERVE TISSUE

The Neurone

In most of the cells thus far described the protoplasm has been confined to the immediate vicinity of the nucleus. In the smooth muscle cell was seen an extension of protoplasm to a considerable distance from the nuclear region, while in the connective-tissue cells of the cornea the protoplasmic extensions took the form of distinct processes. Processes, often extending long distances from the cell body proper, constitute one of the most striking features of nerve-cell structure. Some of these processes are known as nerve fibres; and nerve tissue was long described as consisting of two elements, *nerve cells* and *nerve fibres*. With the establishment of the unity of the nerve cell and the nerve fibre, the nerve cell with its processes was recognized as the *single structural unit* of nerve tissue. This unit of structure is known as a *neurone*. The *neurone* may thus be defined as a *nerve cell with all of its processes*.

In the embryo the neurone is developed from one of the ectodermic cells which constitute the wall of the primitive neural canal. This embryonic nerve cell, or *neuroblast*, is entirely devoid of processes. Soon, however, from one end of the cell a process begins to grow out. This process is known as the *axone* (axis-cylinder process, neuraxone, neurite). Other processes appear, also as outgrowths of the cell body; these are known as *protoplasmic processes* or *dendrites*.

Each adult neurone thus consists of a *cell body*, and passing off from this cell body two kinds of processes, the *axis-cylinder process* and the *dendritic processes* (Fig. 74).

An important exception to this rule is presented by the cells of the cerebro-spinal ganglia (Fig. 300). Here the typical neurone has two processes, a peripheral process, and a central process which enters the central nervous system. Both processes have a typical axis-cylinder structure. Some authorities have interpreted the peripheral process as a modified dendrite.

I. The Cell Body.—Like most other cells, the nerve cell body consists of a mass of protoplasm surrounding a nucleus (Fig. 75).

Nerve cell bodies vary in size from very small cell bodies, such as those found in the granule layers of the cerebellum and of the olfactory lobe, to the large bodies of the Purkinje cells of the cerebellum and of the motor cells of the ventral horns of the cord, which are among the largest in the body. There is as much variation in shape as in size, and some of the shapes are characteristic of the regions in which the cells are situated. Thus, many of the bodies of the cells

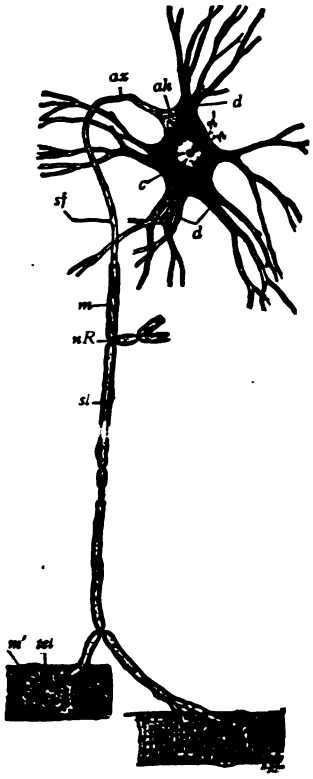

FIG. 74.

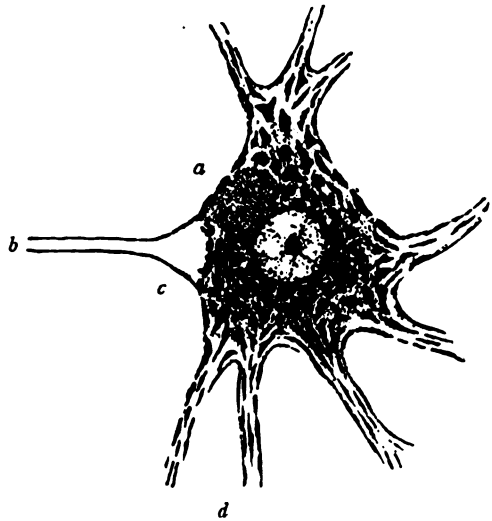

FIG. 75.

FIG. 74.—Scheme of Peripheral Motor Neurone. (Barker.) The cell body, protoplasmic processes, axone, collaterals, and terminal arborizations in muscle are all seen to be parts of a single cell and together constitute the *neurone*. *c*, Cytoplasm of cell body containing chromophilic bodies, neurofibrils, and perifibrillar substance; *n*, nucleus; *n'*, nucleolus; *d*, dendrites; *ah*, axone hill free from chromophilic bodies; *ax*, axone; *sf*, branch (collateral); *m*, medullary sheath; *n R*, node of Ranvier where branch is given off; *sl*, neurilemma (probably not present in central nervous system); *m'*, striated muscle fibre; *tel*, motor end plate.

FIG. 75.—Large Motor Nerve Cell from Ventral Horn of Spinal Cord of Ox, showing Chromophilic Bodies. (From Barker, after von Lenhossék.) *a*, Pigment; *b*, axone; *c*, axone hill; *d*, dendrites.

of the spinal ganglia are spheroidal; of most of the cells of the cortex cerebri, pyramidal; of the cells of Purkinje, pyriform; of the cells of the ventral horns of the cord, irregularly stellate. According to the number of processes given off, nerve cells are often referred to as *unipolar*, *bipolar*, or *multipolar*.

The NUCLEUS of the nerve cell (Fig. 75) differs in no essential

from the typical nuclear structure. It consists of (1) a nuclear membrane, (2) an intranuclear network of linin and chromatin, (3) an achromatic nucleoplasm, and (4) a nucleolus.

The CYTOPLASM of the nerve cell consists of at least two distinct elements: (1) Neurofibrils, and (2) perifibrillar substance. In most nerve cells a third element is present, (3) chromophilic bodies.

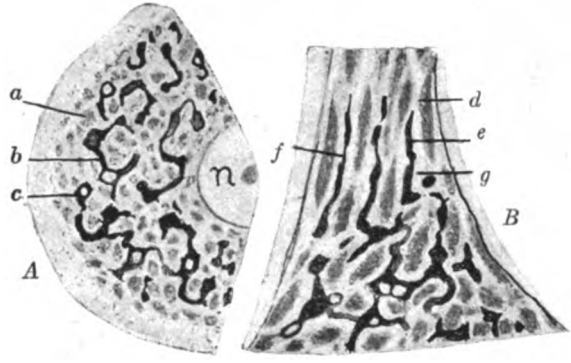

FIG. 76.—Portions of (*A*) ganglion cell and (*B*) large cell of cord showing canaliculi (reticular apparatus) of Golgi and chromophilic bodies of Nissl. Silver impregnation. (Cajal.) *a* and *d*, Nissl bodies; *b*, *e* and *f*, impregnated canaliculi; *c*, nodule with vacuole; *g*, the spaces occupied by unstained neurofibrils.

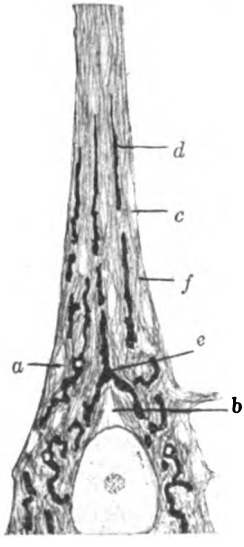

FIG. 76*a*.

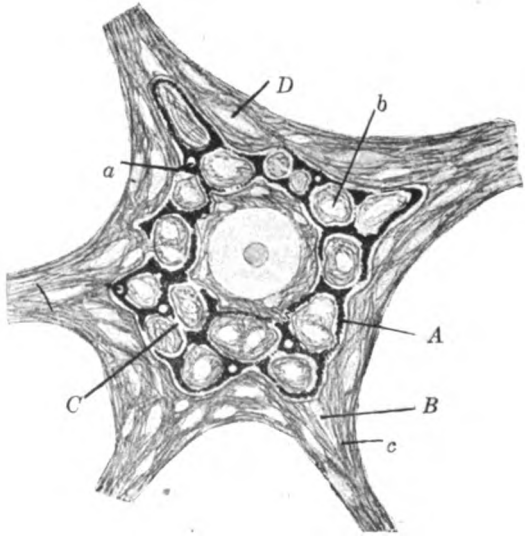

FIG. 76*b*.

FIG. 76*A*.—Portion of giant pyramidal cell showing canaliculi and neurofibrils. (Cajal.) *a*, *b* and *c*, unstained Nissl bodies; *d* and *e*, impregnated canaliculi; *f*, neurofibrils.

FIG. 76*B*.—Scheme showing relations between the canaliculi of Golgi-Holmgren, their argentophile contents, neurofibrils and Nissl bodies. (Cajal.) *A*, impregnated argentophile substance within the canaliculi; *C*, lacunæ of the reticulum; *a*, vacuole in an argentophile nodule; *B*, *b* and *D*, Nissl bodies; *c*, neurofibrils.

(1) The *neurofibrils* are delicate fibrils which are continuous throughout the cell body and its processes. In the body of the cell they cross, interlace and probably anastomose (Figs. 76 and 77).

(2) The *perifibrillar substance* (Fig. 77) is a fluid or semi-fluid substance which both in the cell body and in the processes surrounds and separates the neurofibrils. It is believed by some to be like the fibrils, continuous throughout the cell body and processes, by others to be interrupted at certain points in the axone (see p. 142).

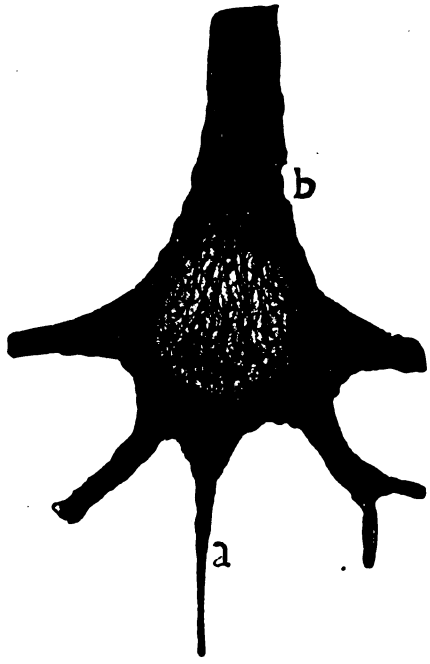

FIG. 77.—Body of Large Pyramidal Cell from Cortex of Cat. Silver Method of Cajal. Shows nucleus pale and arrangement of neurofibrils within the cell; *a*, axone; *b*, main or apical dendrite. (Cajal). In this picture the neurofibrils are shown as anastomosing.

(3) The *chromophilic bodies* (Fig. 75) are granules or groups of granules which occur in the cytoplasm of all of the larger and of many of the smaller nerve cells. They are basophilic and chemically are probably closely allied to the chromatin in the nucleus. They are best demonstrated by the method of Nissl (page 39) which also stains the chromatin. In certain small cells the amount of cytoplasm is extremely small and only the nuclei stain with the Nissl method. Such cells are found in the granule layers of the cerebellum, olfactory

lobe, and retina. They are known as *caryochrome cells*. In other, larger, nerve cells the chromophile bodies in the cytoplasm, as well as the chromatin in the nuclei, are shown by the Nissl stain. These cells are known as *somatochrome cells*. The nuclei of the caryochrome type usually have deeply staining nuclei with either a dense chromatin network or numerous chromatin bodies while the somatochrome type usually have vesicular nuclei with a single nucleolus apparently containing the bulk of the chromatin. Taking as an example of this latter type of cell one of the motor cells of the ventral horn of the cord and subjecting it to the Nissl technic, we note that the cytoplasm is composed of two distinct elements: (*a*) a clear, unstained *ground substance*, and, scattered through this, (*b*) deep-blue-staining masses, the *chromophilic bodies* (Fig. 75). These bodies are granular in character and differ in shape, size, and arrangement. They may be large or small, regular or irregular in shape, may be arranged in rows or in an irregular manner, may be close together, almost filling the cell body, or quite separated from one another. Presenting these variations in different types of cells, the appearance of the chromophilic bodies in a particular type of cell remains constant, and has thus been used by Nissl as a basis of classification.[1]

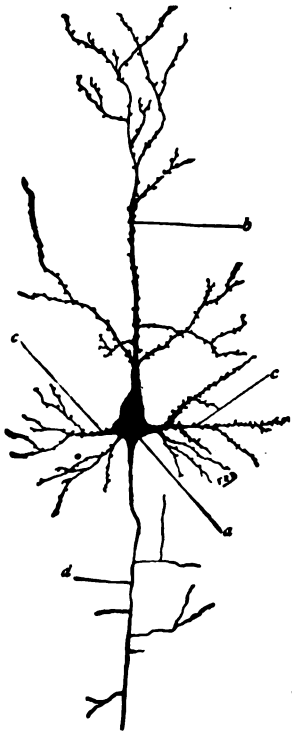

FIG. 78.—Pyramidal Cell from Human Cerebral Cortex. (Golgi bichlorid method. See 2, p. 37.) Golgi cell type I. *a*, Cell body; *b*, main or apical dendrite showing gemmules; *c*, lateral dendrites showing gemmules; *d*, axone with collaterals. Only part of axone is included in drawing.

The cells of the cerebrospinal ganglia usually contain smaller, more irregularly arranged chromophilic bodies than those described above in the motor cells. The attempt has been made to use these differences as criteria in determining the afferent or efferent character of other nerve cells within the central nervous system.

In cells stained by Nissl's method the cytoplasm between the chromophilic bodies remains unstained and apparently structureless,

[1] For this classification, the significance of which is somewhat doubtful, the reader is refered to Barker, "The Nervous System and Its Constituent Neurones."

and it is this part of the cytoplasm that corresponds to the neurofibrils and a part at least of the perifibrillar substance. (Fig. 76.)

The relation which the appearance of the Nissl-stained cell bears to the structure of the living protoplasm is still undetermined. According to some investigators the Nissl bodies exist as such in the living cell. Others believe that they are not present in the living cell, but represent precipitates due either to postmortem changes or to the action of fixatives. The significance of the Nissl picture from the standpoint of pathology lies in the fact that when subjected to a given technic, a particular type of nerve cell always presents the same appearance ("equivalent picture"), and that this appearance furnishes a norm for comparison with cells showing pathological changes, and which have been subjected to the same technic.

Many nerve cells contain more or less brownish or yellowish *pigment* (Fig. 75). This pigment, which is a lipochrome, is not present in the cells of the new-born, but appears in increasing amounts with age. Its significance is not known. Another black pigment known as melanin is present in certain cells in the central nervous system (*e.g.*, the substantia nigra). This pigment is said to increase in amount until adolescence.

In addition to its characteristic structure, the nerve cell may contain many elements found in other cells (p. 46). Golgi, Holmgren, Cajal, and others have also demonstrated a network of *canaliculi* within the nerve cell similar to that found in other cells (p. 47). For relations of neurofibrils and chromophilic bodies to canaliculi see Fig. 76. There are also found in nerve cells the *mitochondria* or *chondriosomes*, granular or elongated bodies similar to those found in other cells (p. 47).

II. The Protoplasmic Processes or Dendrites.—These have a structure similar to that of the cell body, consisting of neurofibrils, perifibrillar substance, and, in somatochrome cells, chromophilic bodies (Figs. 75 and 76). Dendrites branch dichotomously, become rapidly smaller, and usually end at no great distance from the cell body (Figs. 78 and 79).

III. The Axone.—This differs from the cell body and dendrites in that it contains no chromophilic bodies (Fig. 75), consisting wholly of neurofibrils and perifibrillar substance. Not only is it entirely achromatic itself, but it always takes origin from an area of the cell body, the *axone hill* (Fig. 75), which is also free from chromophilic bodies. It is as a rule single, and while usually arising from the body of the cell may be given off from one of the larger protoplasmic trunks. Some few cells have more than one axone,

and nerve cells without axones have been described. In Golgi preparations the axone is distinguished by its straighter course, more uniform diameter, and smoother outline (Fig. 78). It sends off few branches (*collaterals*), and these approximately at right angles. Both axone and collaterals usually end in *terminal arborizations*. In most cells the axone extends a long distance from the cell body. Such cells are known as *Golgi cell type I or long axone neurones* (Fig. 78). In others the axone branches and ends in the gray matter in the vicinity of its cell of origin—*Golgi cell type II or short axone neurones* (Fig. 79).

FIG. 79.—Golgi Cell Type II. from Cerebral Cortex of Cat. (Kölliker.) *x*, Coarse protoplasmic processes with gemmules easily distinguishable from the more delicate, smoother axone, *a*. The latter is seen breaking up into a rich plexus of terminal fibres near its cell of origin, practically the entire neurone being included in the drawing.

As they leave the cell body the neurofibrils of the axone converge to a very narrow portion of the axone, where the perifibrillar substance is much reduced in amount, or according to some, entirely interrupted. Beyond this the fibrils become more separated and the perifibrillar substance more abundant.

Some axones pass from their cells of origin to their terminations as "naked" axones, *i.e.*, uncovered by any sheath. Other axones are enclosed by a thin membrane, the *neurolemma* or *sheath* of *Schwann*. Still others are surrounded by a sheath of considerable

thickness known as the *medullary* or *myelin sheath.* The axone together with its neurolemma and medullary sheaths, when present, constitute the *nerve fibre.*

Depending upon the presence or absence of a medullary sheath, *nerve fibres* may thus be divided into two main groups—*medullated nerve fibres* and *non-medullated nerve fibres.*

1. NON-MEDULLATED NERVE FIBRES (non-myelinated nerve fibres) (Fig. 80). These are subdivided into non-medullated nerve fibers

FIG. 80.

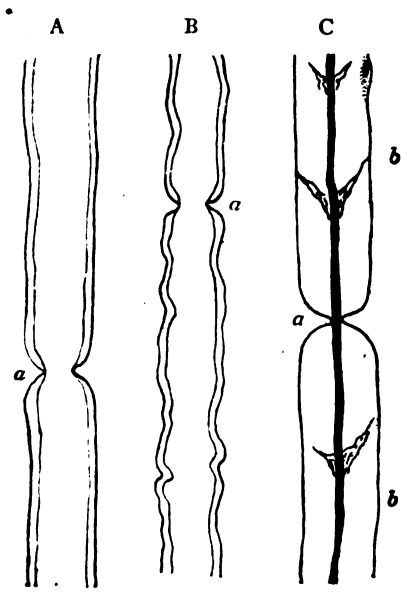

FIG. 81.

FIG. 80.—Non-medullated Nerve Fibres with Neurolemma, only the nuclei of which can be seen. × 300.

FIG. 81.—A, Fresh nerve fibre from sciatic nerve of rabbit teased apart in normal salt solution, showing broad unshrunken axone and comparatively thin medullary sheath. B, Showing crenation of medullary sheath which occurs soon after placing fibres in salt solution. C, Same after fixation and staining with picro-acid-fuchsin, showing shrunken axone and broad medullary space. The latter usually contains irregular clumps of myelin. *a*, Node of Ranvier; *b*, incisures of Schmidt; *c*, nucleus of neurolemma.

without a neurolemma and non-medullated nerve fibres with a neurolemma.

(*a*) *Non-medullated nerve fibres without a neurolemma* are merely naked axones. In the central nervous system there is no well-defined neurolemma. The non-medullated fibres which occur in the central nervous system thus belong to this category (comp. p. 140).

(*b*) *Non-medullated nerve fibres with a neurolemma—fibres of Remak* (Fig. 80). In these the axone is surrounded by a delicate homogeneous, nucleated sheath, the *neurolemma* or *sheath of Schwann* (see p. 139). These axones are described by some writers as having no true neurolemma, but merely a discontinuous covering of flat connective-tissue cells, which wrap around the axone and correspond to the endoneurium of the nerve trunk (see page 436). The

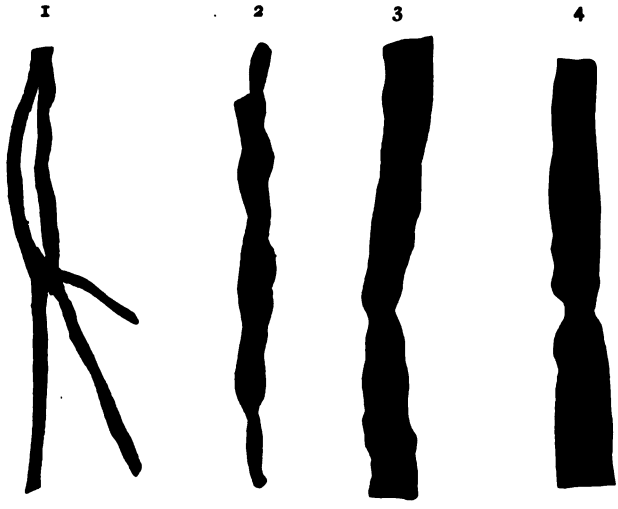

FIG. 82.—1, Fibres of Remak; 2, nerve fibre from central nervous system (medullated but without sheath of Schwann); 3 and 4, nerve fibres from the sciatic of frog, showing nodes of Ranvier, and in 4 the incisures of Schmidt.

majority of the axones of the cells of the sympathetic ganglia and also many of the processes of the cerebrospinal ganglion cells (afferent peripheral nerve fibres) fall under this category.

2. MEDULLATED NERVE FIBRES (myelinated nerve fibres). These, like the non-medullated, are subdivided according to the presence or absence of a neurolemma into medullated axones with a neurolemma and medullated axones without a neurolemma.

(*a*) *Medullated nerve fibres with a neurolemma* constitute the bulk of the fibres of the cerebro-spinal peripheral nerves. Each fibre consists of (1) an axone or axis-cylinder, (2) a medullary sheath, and (3) a neurolemma.

(1) The *axone* is composed of neurofibrils continuous with those of the cell body, and like them lying in a perifibrillar substance or neuroplasm (Fig. 86). In the fresh condition the axone is broad,

and shows faint longitudinal striations corresponding to the neurofibrils, or appears homogeneous (Fig. 81, *A*). Fixatives usually cause the axone to shrink down to a thin axial thread, whence its older name of axis-cylinder (Fig. 81, *C*). A delicate membrane has been described by some as enveloping the axone. It is known as the *axolemma* or *periaxial sheath* (Fig. 84).

(2) The *medullary sheath* (Figs. 82 and 84) is a thick sheath largely composed of a semi-fluid substance resembling fat and known as *myelin*. In the fresh state the myelin has a glistening homogeneous appearance. It is not continuous, but is divided at intervals of from 80 to 600μ by constrictions, the *nodes* or *constrictions* of *Ranvier*. That portion of a fibre included between two nodes is known as an *internode* (Fig. 84). Tne length of the internode is usually proportionate to the size of the fibre, the smaller fibres having the shorter internodes. In fresh specimens the medullary sheath of an internode appears continuous (Fig. 81, *A*), but in fixed specimens it is broken up into irregular segments, *Schmidt-Lantermann segments*, by oblique clefts which pass from neurolemma to the axolemma or axone, and are known as the *clefts* or *incisures* of *Schmidt-Lantermann* (Fig. 81, *C*). By various methods a fine network is brought out in the medullary sheath, the *neurokeratin network*. In myelinated fibres the axone has no myelin sheath for a short distance at its origin from the nerve-cell, at points where branches are given off, at the nodes of Ranvier and near the termination of the fibre or of its branches.

(3) The *neurolemma* or *sheath of Schwann* (Figs. 86, *B*, and 85) is a delicate structureless membrane which encloses the myelin. At the nodes of Ranvier the neurolemma dips into the constriction and

FIG. 83.—Diagrammatic Representation of Portions of Two Medullated Nerve Fibres, as seen in Longitudinal Section, stained with Osmic Acid. (Length of internode is proportionately shortened.) *R*, *R*, Nodes of Ranvier, with axis cylinder passing through; *a*, neurolemma; *c*, nucleus surrounded by protoplasm, lying at about the middle of the internode between the neurolemma and the medullary sheath. (From drawing by J. E. Neale in Quain's Anatomy.)

comes in contact with the axone or axolemma. Silver nitrate staining shows a black transverse line at the node of Ranvier. This line represents the boundary between two neurolemma cells. Against the inner surface of the neurolemma, usually about midway between two nodes, is an oval-shaped nucleus, the *nucleus of the neurolemma* (Figs 80, *C*, and 85). Each nucleus is surrounded by an area of granular protoplasm, and makes a little depression in the myelin and a slight bulging of the neurolemma (Fig. 81, *C*). According to most observers no neurolemma is present in the central nervous system (see *b*, p. 140*a* and p. 148).

In addition to the above-described sheaths, most medullated fibres of peripheral nerves have, outside the neurolemma, a nucleated sheath of mesodermal connective-tissue origin, known as the sheath of Henle (Fig. 85).

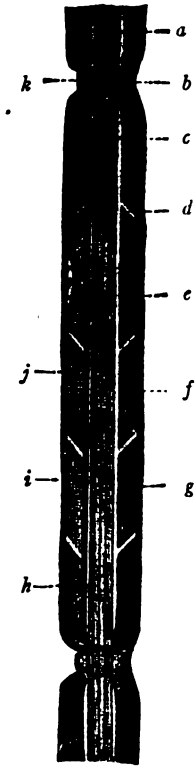

FIG. 84.

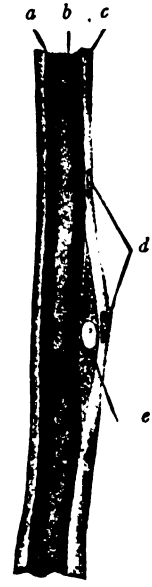

FIG. 85.

FIG. 84.—Diagram of Structure of a Medullated Nerve Fibre of a Peripheral Nerve, showing two different views (one on each side) as to relations of neurolemma and axolemma and their behavior at the nodes of Ranvier. (Szymonowicz.) *a*, Neurofibrils; *b*, cement substance; *c*, axone; *d*, incisure of Schmidt; *e*, nucleus of neurolemma; *f*, medullary sheath; *g*, sheath of Schwann; *h*, axone; *i*, axolemma; *j*, sheath of Schwann; *k*, node of Ranvier.

FIG. 85.—Piece of Medullated Nerve Fibre from Human Radial Nerve. ×400. Osmic-acid fixation and stain. (Szymonowicz.) *a*, Medullary sheath; *b*, axone; *c*, sheath of Henle; *d*, nuclei of Henle's sheath; *e*, nucleus of neurolemma.

Two views as to the relation of the axolemma to the neurolemma are illustrated in Fig. 84. According to one the neurolemma is continuous, merely dipping into the nodes of Ranvier, where it touches the axolemma or the axone. According to the second both neurolemma and axolemma are interrupted at the node, but unite with each other there to enclose completely the medullary substance of the internode.

According to the views illustrated in Fig. 86, that part of the axone which lies between two nodes is enveloped by a cell or by several cells forming a syncytium. The outer homogeneous membrane there pictured would thus be of the nature of a cell membrane or cuticle, and would correspond to the neurolemma. The trabeculæ (protoplasmic strands and

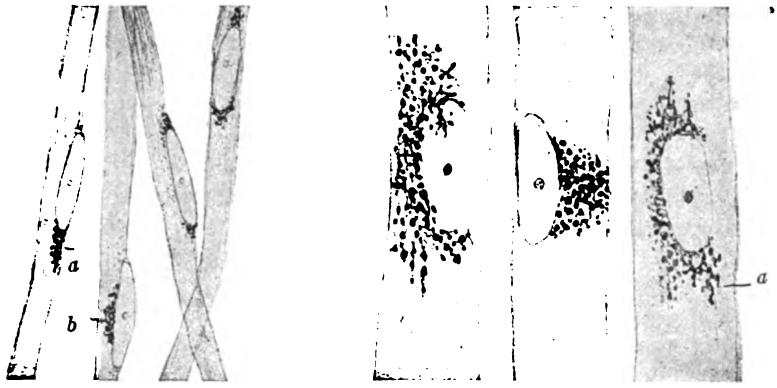

FIG. 85*a*.—A Canaliculi of Golgi in the cytoplasm of the sheath cells of four fibers of Remak. Formal-uranium silver impregnation method of Cajal. (Cajal.) *a*, Canaliculi at the end of the nucleus; *b*, canaliculi at the side of the nucleus. *B*, Similar preparation of three medullated fibers (adult cat). The canaliculi are here more extensive.

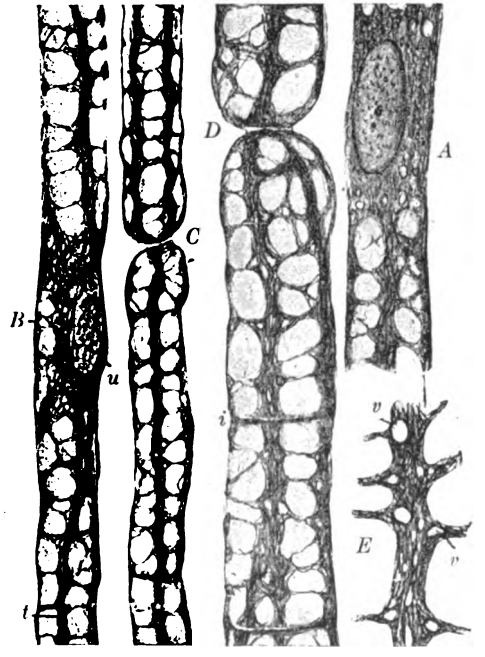

FIG. 85*b*.—Five dissociated Medullated Nerve Fibres from the sciatic nerve of an adult cat showing the fibrillar protoplasm of the neurolemma cells. Formal-uranium silver impregnation method of Cajal. (Cajal.) *A* and *B*, cytoplasm in the vicinity of the nucleus; *C*, a fine fibre; *D*, a coarse fibre, the letter is placed at a node of Ranvier, where the cytoplasm forms a collar around the fibre; *E*, longitudinal cytoplasmic band, more highly magnified; *i*, hoop of cytoplasm encircling the fibre at an incisure; *n*, nucleus of neurolemma cell; *v*, vacuoles in a cytoplasmic band.

neurokeratin network, of which some of the larger strands would represent the incisures of Schmidt) would correspond to the spongioplasm, and just along the outer side of the axone would constitute the axolemma. The myelin would thus be enclosed within the cylindrical neurolemma cell which surrounds the axone (see also p. 148). Other authorities, however, regard the myelin sheath with its enclosed incisures as distinct from the neurolemma cell.

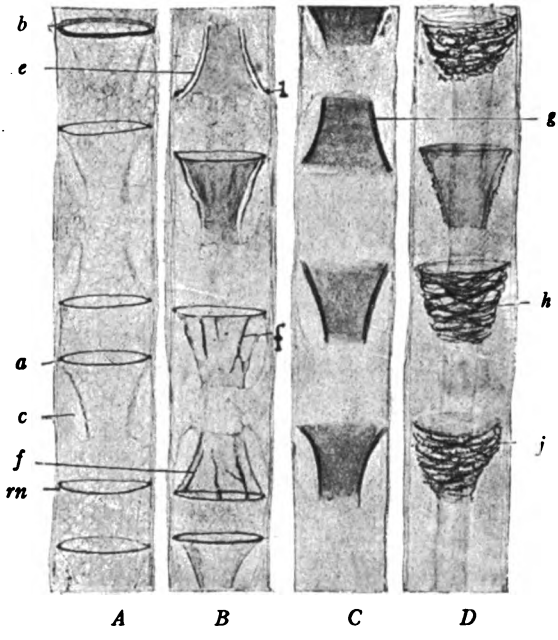

FIG. 85*c*.—Four Medullated Nerve Fibres showing various structures demonstrated by the formal-uranium silver impregnation method of Cajal. (Cajal.) *A*, Fibre showing only the rings in the neurolemma cytoplasm. *a*, Rings opposite an incisure; *b*, a thick ring; *c*, an incisure; *n*, a ring at some distance from an incisure. *B*, Fibre showing the rings and also the membranes of the incisures partly stained; *e*, membrane of the incisure; *f*, dark strips which apparently reenforce the membrane; *i*, optical section of a ring; *C*, Fibres in which the membranes of the incisures alone are stained; *g*, incisure completely impregnated. *D*, *h* and *j*, impregnated incisures showing fibrous structure.

The neurolemma protoplasm is not confined to the vicinity of the nucleus but extends in several longitudinal bands along the length of the internode connected by various transverse trabeculæ. The protoplasm presents a fibrillar appearance (Fig. 85*b*). Near the nucleus it contains the canaliculi of Golgi, also certain cell products such as the bodies of Elzholz, of a fatty nature, and the π and μ granules of Reich. At various places along the fibre the cell also contains certain peculiar rings, sometimes opposite the clefts, connected by longitudinal threads. Mitochondria are also present. In the myelin sheath, besides the myelin and the incisures, there are mitochondria along its inner and outer surfaces and the protoplasmic trabeculæ already mentioned (p. 140).

In the incisures there have been distinguished an infundibular membrane or cement substance, plasmatic spaces between the latter and the myelin, granules, and curious spiral filaments (the apparatus of Golgi-Rezzonies) (Fig. 85*c*). Around the axis-cylinder at the node of Ranvier a circle or "bracelet" of spines has been described.

Medullated nerve fibres vary greatly in size. The finer fibres have a diameter of from 2 to 4μ, those of medium size from 4 to 10μ,

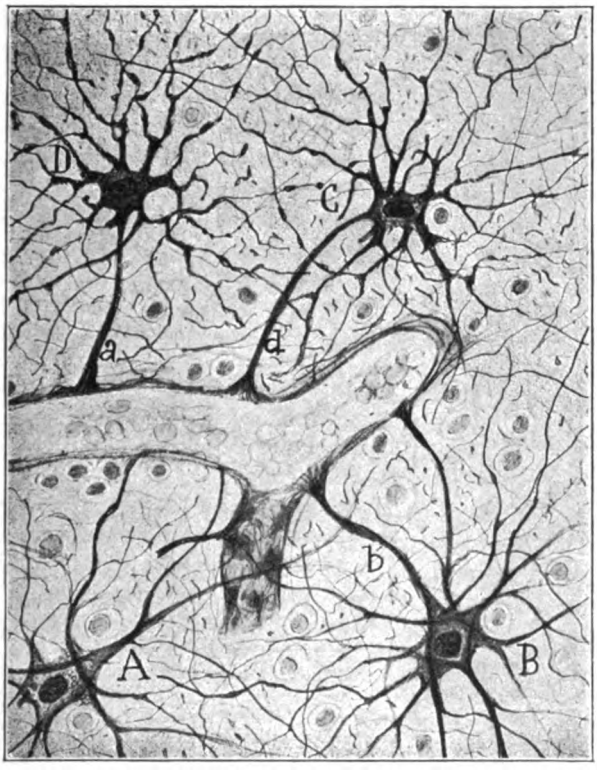

FIG. 85*d*.—Neuroglia Cells. Adult human cerebrum. Cajal's gold impregnation. (Cajal.) *A*, *B*, *C* and *D*, four neuroglia cells; *a* and *b*, expansions of processes of neuroglia cells in apposition with a blood-vessel, forming the membrana gliæ perivascularis. In *A* the glia fibrils are shown.

the largest from 10 to 20μ. They have few branches, and these are always given off at the nodes of Ranvier.

(*b*) ***Medullated nerve fibres without a neurolemma.*** As mentioned above (p. 137) there is no well defined neurolemma sheath (membrane) in the central nervous system, the neurolemma cells being

represented by the neuroglia cells investing the nerve fibres. Irregular and rather indefinite nodes of Ranvier have been described (comp. p. 148). The structure of the myelinated fibres of the central nervous system is otherwise similar to the above-described structure of a medullated nerve fibre with a neurolemma.

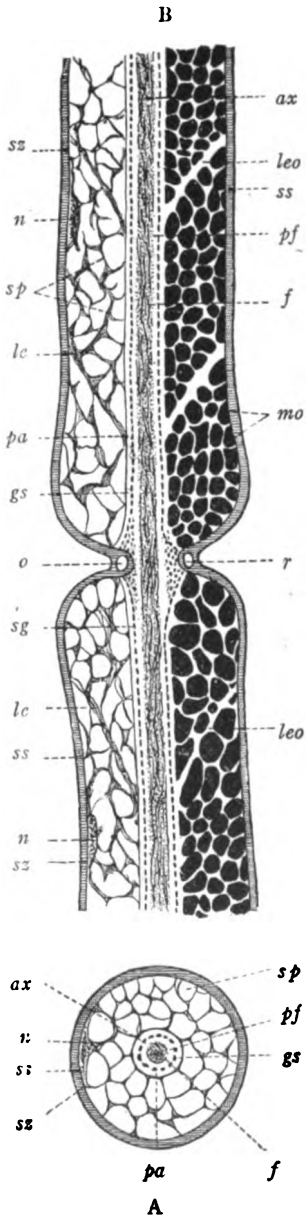

As to the physiological significance of the structural elements of the neurone, we have little absolute knowledge but certain fairly well-grounded theories.

That portion of the neurone which surrounds the nucleus—the cell body—is, as already stated, the *genetic centre* of the neurone, the nucleus as in other cells being probably concerned in the general cell metabolism. From the behavior of the processes when cut off from the cell body it is evident that the latter is the *trophic* or *nutritive centre* of the neurone.

It is probable that in most or perhaps all neurones the usual direction of conduction along the axone is cellulifugal, *i.e.*, from cell body to terminal arborization. The dendrites and cell body would receive and probably integrate the various nerve impulses received by the neurone. In other words, the dendrites and cell body *receive*, the axone *transmits*, and the axone branches and terminal arborizations *distribute*. This general direction of conduction indicates a certain polarity of the neurone. While the cerebro-spinal ganglion cell is obviously polar-

FIG. 86.—Scheme of Structure of Medullated Peripheral Nerve Fibre of a Fish (Nemiloff). A, Cross section; B, longitudinal section; on left, fibre is shown as stained *intra vitam* with methylene blue; on right, myelin is shown black as in osmic acid staining, with the incisures of Schmidt indicated; *sz*, cells of sheath of Schwann; *n*, their nuclei; *ss*, sheath of Schwann; *sp*, processes of the cells of sheath of Schwann or the myelin sheath network; *le*, larger trabeculæ of protoplasmic framework of medullary sheath arranged obliquely to axis-cylinder and forming the so-called "funnels"; *leo*, clear streaks in fibres treated with osmic acid, corresponding to *le*, incisures of Schmidt; *mo*, myelin blackened with osmic acid; *ax*, axis-cylinder; *pa*, periaxial space around axis-cylinder; *gs*, "coagulum sheath," granules probably representing coagulated fluid in periaxial space; *pf*, peripheral, non-fibrillar, part of axis-cylinder; *f*, neurofibrils of axis-cylinder; *r*, ring-like thickening of Schwann's sheath at node of Ranvier; *o*, cavity in *r*.

ized, yet if its peripheral process be regarded as an axone, the latter would evidently constitute an exception to conduction along the axone being cellulifugal. There are cases (*e.g.*, unipolar cerebro-spinal ganglion cell) where the nervous impulse may apparently pass from one process to another without traversing the body of the cell.

Regarding the chromophilic substance, certain facts, such for example as the entire absence of chromophilic bodies in many nerve cells, which nevertheless undoubtedly functionate; the absence of these bodies in all axones; the diminution of the chromatic substance during functional activity; its much greater diminution if activity be carried to the point of exhaustion; these together with its behavior under certain pathological conditions, all favor the theory that the stainable substance of Nissl is not the active nerve element of the cell, but is rather of the nature of a nutritive element.

There thus remain to be considered as possible factors in the transmission of the nervous impulse the neurofibrils and the perifibrillar substance. While a few investigators are inclined to magnify the importance of the latter, the majority agree in considering the *neurofibrils as the principal conducting mechanism of the neurone.* The already referred to observations of Bethe regarding the interruption of the perifibrillar substance at the constricted portion of the axone and at the nodes of Ranvier, would, if true, be obviously in favor of this view. It is also obvious that if the neurofibrils are the *sole* conducting substance and if they do not anastomose within the body of the vertebrate neurone, we would be driven to conclude there must be an extracellular anastomosis. The probability, however, is rather against both of these premises. The neurofibrils are probably a differentiation of the spongioplasm, while the perifibrillar substance and chromophilic bodies are specializations of the hyaloplasm.

As to the manner in which neurones are connected, there are two main theories, the *contact theory* and the *continuity theory.*

According to the *contact theory* each neurone is a distinct and separate entity. Association between neurones is by contact or contiguity of the terminals of the axone of one neurone with the cell body or dendrites of another neurone, and never by continuity of their protoplasm. This theory, which is known as the "neurone theory" and which received general acceptance as a result of the work of Golgi, His, Forel, Cajal, and others, has been recently called in question by such prominent neurologists as Apáthy, Bethe, Held, and Nissl, on the ground that in some cases the neurofibrils are continuous throughout a series of neurones. The point of contact between two neurones is called a *synapsis* (Fig. 83), and the conception that there is some kind of interruption or discontinuity in neural circuits involving more than one neurone has proved useful to physiologists. It affords an explanation of certain differences between conduction through a circuit of two or more neurones and conduction through a nerve fibre alone. For example, an impulse takes longer to traverse the circuit than to traverse a nerve fibre of equal length. Also a stimulus may pass in either direction along a nerve fibre, but cannot be "reversed" along a circuit. Based upon the contact theory is the so-called "retraction hypothesis," which held that a neurone being associated with other neurones only by contact was able to retract its terminals, thus breaking the association and throwing itself, as it were, out of circuit.

According to the *continuity theory*, while the perifibrillar substance is interrupted as above described, the neurofibrils are continuous. According to this theory the neurofibrils, which form a plexus or network within the cell body and dendrites, are connected with a *pericellular network—the Golgi net* —which closely invests the cell body and its dendrites. Externally the Golgi net is further connected with the neurofibrils of the axones and collaterals of other nerve cells. This connection is either direct, or, as some believe, through another general (diffuse) *extracellular network*. The neurofibrils are thus, accord-

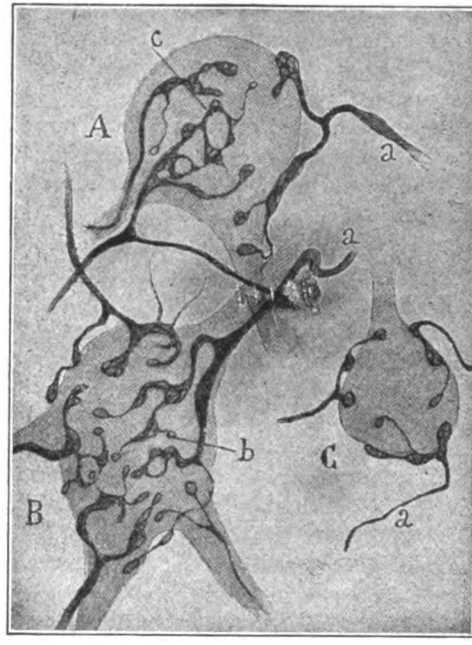

FIG. 87.—*A*, *B*, *C*, Three cells of the Ventral Cochlear Nucleus of Rabbit, showing terminals of fibres of the cochlear nerve and their relations to the cell bodies (Cajal). *a*, *a*, *a*, Fibres of the cochlear nerve, which break up into terminal arborizations upon the cells; *b*, *c*, terminal rings. The points of contact between the terminals of the axone of one neurone and the cell body and dendrites of the other neurone constitute a "synapsis."

ing to this theory, continuous and form two or possibly three continuous networks: (*a*) an intracellular network, (*b*) a pericellular network (Golgi), and (*c*) a more diffuse extracellular network, lying between the cells. The existence of (*c*) is extremely doubtful and it seems probable that the Golgi network is either non-nervous or an artefact. Thus the main point at issue is whether the neurofibrils, in such pericellular terminals as are illustrated in Fig. 87, are continuous with the neurofibrils within the cell enveloped or are separate from the latter. The latter view appears, at present, to be the better supported.

The individuality of the neurone and the interdependence of its various parts are strikingly shown by its behavior when injured. That degenerative changes, which progress to complete disappearance of the nerve structures, take place in

the distal part of a nerve when that nerve is cut across has long been accepted as one of the fundamental laws of neuropathology (law of Wallerian degeneration). In terms of the neurone concept this would mean that an axone cut off from its cell of origin degenerates and disappears and this behavior of the axone would accord with the already stated fact that the cell body is the trophic center of the neurone. The degenerative changes in the axone are best shown in their earlier stages by an osmic acid (p. 8) or by a Marchi (p. 35) stain. Later, when the degenerated fibres have been largely replaced by connective tissue, the Weigert method is most satisfactory, especially in the central nervous system. In this case, of course, the degeneration is indicated by an absence of stain, while in the Marchi method a positive picture of the degenerating myelin sheaths is

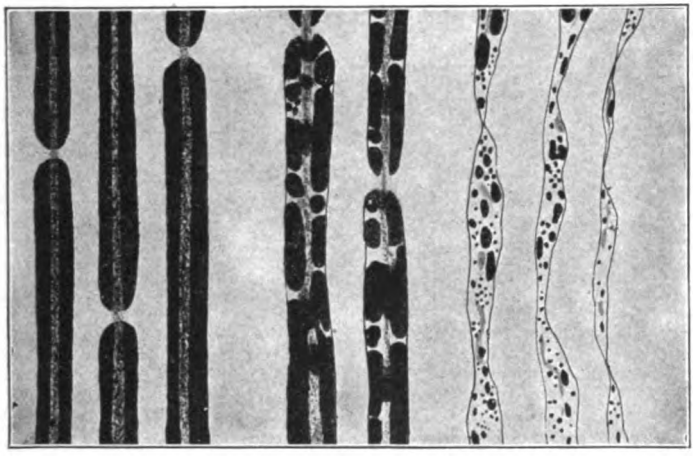

A *B* *C*

FIG. 88.—*A*, Normal Nerve Fibres from Sciatic Nerve of Rabbit, osmic acid fixation and stain; each fibre shows node of Ranvier. *B*, Two fibres from distal part of rabbit's sciatic five days after cutting the nerve; shows segmentation of myelin; *C*, three fibres from distal part of rabbit's sciatic three weeks after cutting nerve; most of the myelin has been absorbed and only traces of the axones remain.

seen. When the nerve is cut the first changes affect the cut ends and seem to be of a traumatic character such as formation of bulbous enlargements of the ends of the axones, increase and separation of neurofibrils and formation of sprouts. This phase is soon passed over in the distal stump, while in the central it may pass over into a beginning regeneration of the nerve fibres. In the distal portion a degeneration of the nerve fibres throughout their length and including their terminal arborizations now takes place. All parts of the nerve fibre are affected. In the medullary sheath the changes consist in segmentation of the sheath, breaking up of the segments into granules and finally complete absorption (Fig. 88). While undergoing these physical changes chemical changes are also taking place in the myelin which result in its breaking down into simpler fatty substances which give the fat reaction to the Marchi stain. At the same time the neurofibrils become irregular and granular and the axis-cylinders finally disappear.

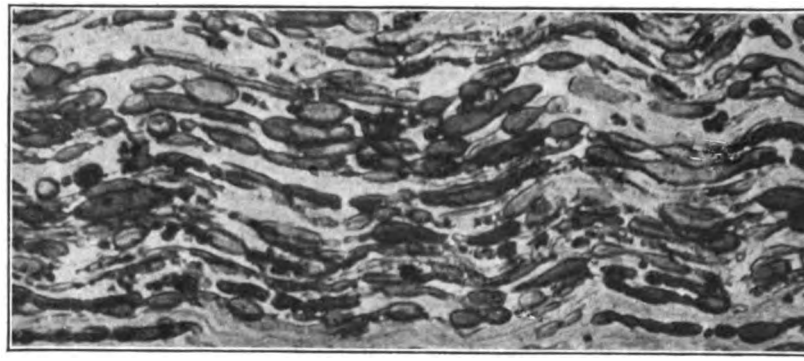

A. Distal stump of a nerve cut 3 to 5 days previously. Osmic stain.

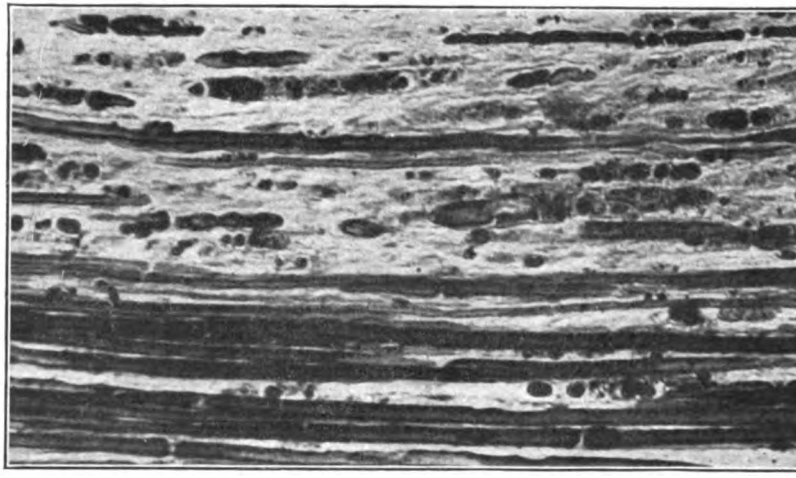

B. Distal stump of a nerve partly cut 12 to 15 days previously. Osmic. Normal fibres and two nodes of Ranvier are shown at the bottom.

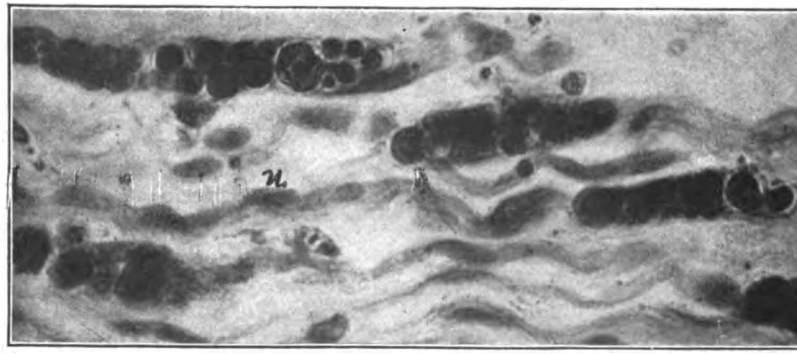

C. Distal stump of a nerve cut 12 to 15 days previously. Osmic and Weigert's iron hæmatoxylin. In addition to the degenerating myelin, several band fibres and their nuclei (*e.g.*, at *n*) are shown.

The neurolemma cells of the peripheral nerve fibres are peculiar in that they do not degenerate; instead of this their protoplasm increases, and their nuclei proliferate. These cells are apparently concerned in the disintegration and absorption of the myelin. They also form protoplasmic bands which play an important part in the regeneration of the nerve (see below). The same rule holds good for dendrites as for axones as far as it has been possible to determine, namely, that cut off from their cells of origin they undergo complete degeneration.

At the time the law of Wallerian degeneration was established it was believed that the central portion of the nerve and the cell bodies remained intact after division of the nerve. More recently the method of Marchi (for nerve fibres) and

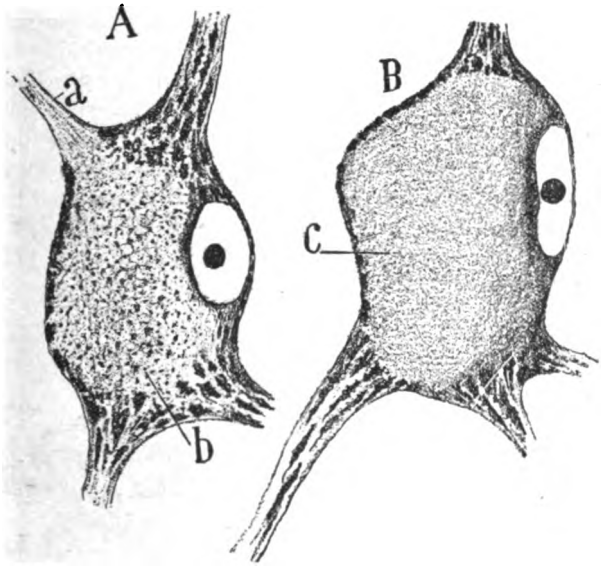

FIG. 89.—Two Motor Cells from Ventral Horn of Dorsal Cord of Rabbit; fifteen days after cutting major sacro-sciatic nerve. *A*, Cell in which the chromophilic bodies appear disintegrated and nucleus eccentric; *B*, cell showing more advanced chromatolysis, the chromophilic substance being present only in the dendrites and around the nucleus in the form of a homogeneous mass; nucleus causes bulging of surface of cell.

the method of Nissl (for neurone bodies) have shown marked degenerative changes in the parts proximal to the lesion. The extent and rapidity of these changes are dependent mainly upon three factors (1) the type of neurone—some neurones being apparently more resistant than others to injury; (2) the character of the injury—*e.g.*, tearing the nerve causing the greatest reaction; cutting the nerve, a reaction of less intensity; pinching the nerve, the least degree of reaction; and (3) the location of the injury, an injury near the cell body causing more effect centrally than one at a distance. In other words, the effect depends upon the percentage of the neurone cut off. If the injury is very near the cell body the latter may ultimately disappear, the proximal portion of the nerve fibre which remains attached to it undergoing a final degeneration similar to that of the distal severed portion. In the cell body there is an initial turgescence,

followed by disintegration and disappearance of the chromophilic bodies beginning near the centre of the cell, and a displacement of the nucleus toward the periphery. This reaction on the part of the cell body to injury to its axone—"central chromatolysis" and "nuclear eccentricity"—is sufficiently characteristic to have led to the designation "axonal degeneration" (Fig. 89).

If the neurone body survive the injury regeneration takes place. This consists in a reappearance of the chromophilic substance, beginning near the nucleus, a return of the nucleus to its normal position, and a slow subsidence of the turgescence. While this is going on the axones of the central stump grow across the scar to the protoplasmic bands beyond formed by the neurolemma cells of the peripheral stump, and find their way along or in them to their former terminations. According to some authorities the neurolemma cells can do more than this and form, in young animals at least, new nerve fibres which, however, do not persist unless they form connections with the central stump. The outgrowth (centrogenetic) theory seems more probable than the latter (autogenetic) theory.

In the central nervous system the degeneration of the nerve fibre is similar to that of the peripheral nerve fibre the neuroglia reacting much as does the neurolemma cell except that the process is more complicated and that no band fibres are formed (see p. 145). Complete regeneration of nerve fibres does not, however, take place in the central nervous system, there being at most simply an abortive attempt.

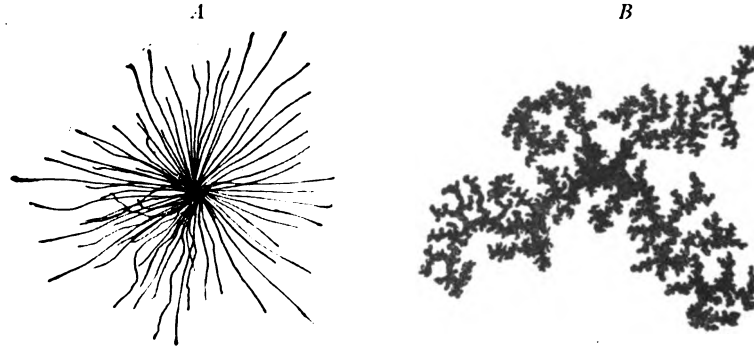

FIG. 90.—*A*, Neuroglia Cell—Spider Type—Human Cerebrum. *B*, Neuroglia Cell—Mossy Type—Human Cerebrum.

The rapidity of the above degenerative and regenerative changes varies according to the metabolic activity of the animal, *i.e.*, they are much more rapid in warm-blooded than in cold-blooded animals, and in summer than during hibernation. They are also influenced by the age of the animal.

The importance of these degenerations from the standpoint of anatomy lies in the fact that, by using such methods as Nissl, Weigert, and Marchi, one is enabled to trace the connections between cell bodies and nerve fibres throughout the nervous system.

Neuroglia

This is a peculiar form of connective tissue found only in the nervous system. Unlike the other connective tissues, neuroglia is of ectodermic origin, being developed from the ectodermic cells which line the embryonic neural canal. These cells, at first morphologically identical, soon differentiate into *neuroblasts* or future neurones, and *spongioblasts* or future neuroglia cells, the latter most probably being in the form of a syncytium. Later this syncytium

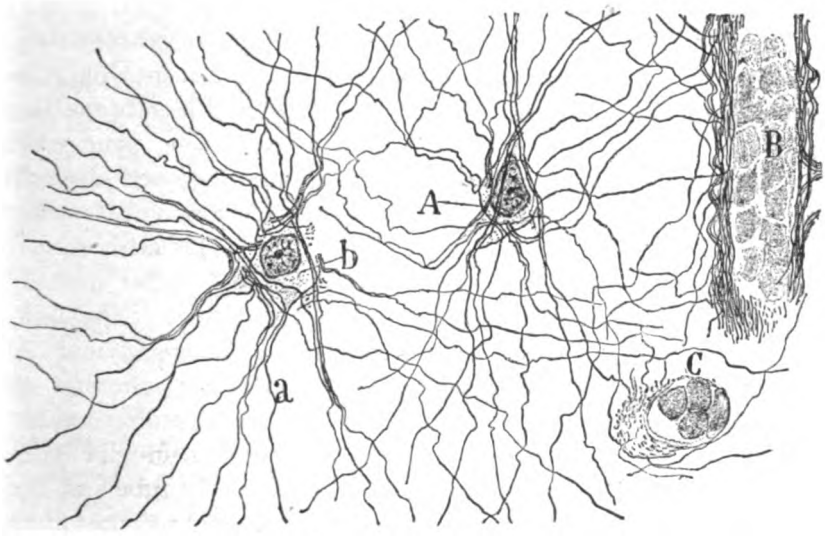

FIG. 91.—Neuroglia Cells and Fibres from the White Matter of the Human Cerebellum stained by Weigert's neuroglia stain. *A*, Neuroglia cell; *B*, blood-vessel cut longitudinally, and *C*, blood-vessel cut transversely, showing enveloping neuroglia fibres; *a*, neuroglia fibres; *b*, cytoplasm of neuroglia cell. (Cajal.)

differentiates fibres, the neuroglia fibres, which, according to Weigert and others, may be entirely separate from the cells (Fig. 91), but more probably lie wholly or at least partly within them. In the syncytium there are also to be distinguished an endoplasm of granular protoplasm and a clear ectoplasm which may perhaps be regarded as a matrix. (See also Fig. 324.) The structure of neuroglia would thus be analogous to that of fibrous connective tissue, *i.e.*, composed of cells, the *neuroglia cells*, a fibrillar substance, the *neuroglia fibres*, and a *ground substance*. The Golgi method apparently reveals a great variety of neuroglia cells which may be divided into cells with straight radiating unbranched processes, *spider cells*, and rough thick branching cells, *mossy cells*. It seems probable that in the

former both cells and fibres are stained while in the latter only portions of the cells or syncytium, this method not differentiating between cells and fibres.

An increased activity of the neuroglia, due it may be to some pathological cause, is indicated by increase in the endoplasm, by proliferation of the nuclei, and by some cells detaching themselves from the syncytium and becoming amœboid. Such amœboid cells may convey various products of degeneration to the vicinity of the perivascular lymph spaces. There may also result a temporary increase in the glial fibres (gliosis).

According to good authorities a continuous glial membrane forms the outer boundary of the ectodermal elements of the central nervous system, *i.e.*, the nerve tissue and glia. This glial membrane is of course in apposition with the mesodermic connective tissue which forms the pia or inner covering of the brain and cord and also with the connective tissue of the adventitia of the blood-vessels which penetrate the central nervous system. The glial membrane is formed by superficial flattened cells and processes of other glial cells which come into contact with the connective tissues. The lining of the cavity of the neural tube is formed by the ependymal cells which are a form of neuroglia cells. These cells are columnar epithelial cells each with a process penetrating a variable distance into the wall of the neural tube and joining the general neuroglia syncytium. Their nuclei lie near the central cavity of the tube and they contain glia fibres. The inner lining of the chorioid plexuses of the brain is a single layer of cuboidal epithelial cells which are believed to have a secretory function and contribute to the production of the cerebro-spinal fluid. It is probable that the ependyma cells also have a secretory activity.

The neurolemma cells also probably originate from the neural tube. If this is the case it is evident that they may be regarded as a special form of neuroglia cell. It has already been seen that in pathological changes they behave similarly to the neuroglia cells in the central nervous system.

The apparent absence of a definite neurolemma sheath in the central nervous system would be due to the irregular arrangement of the neuroglia cells investing the nerve fibres and to an absence of a definite membrane. These differences are comprehensible when it is remembered that in the central nervous system the nervous elements (neurones) are, so to speak, imbedded in a mass of neuroglia, while in the peripheral nervous system the corresponding investment of each individual neurone body and nerve fibre is in contact with mesodermal connective tissue. The reason for the absence of complete regeneration in the central

nervous system is not clear. It may be connected with the above differences of arrangement and the consequent failure of the neuroglia cells to form definite "band fibres" such as those formed by the neurolemma cells.

TECHNIC

(1) Pieces of the cerebral cortex are stained by one of the Golgi methods. If the rapid or mixed silver method is used, sections must be mounted in hard balsam without a cover; if the slow silver or the bichlorid method is used, the sections may be covered. Sections are cut from 75 to 100μ in thickness, cleared in carbol-xylol or oil of origanum and mounted in balsam. This section shows only the external morphology of the neurone. It is also to be used for studying the different varieties of neuroglia cells as demonstrated by Golgi's method (see page 147).

(2) Thin transverse slices from one of the enlargements of the spinal cord are fixed in absolute alcohol. Thin sections (5 to 10μ) are stained by Nissl's method (page 39) and mounted in balsam. This section is for the purpose of studying the internal structure of the nerve cell and processes as demonstrated by the method of Nissl.

(3) Medullated Nerve Fibres (fresh).—Place a small piece of one of the sciatic or lumbar nerves of a recently killed frog in a drop of salt solution and tease longitudinally. Cover and examine as quickly as possible. Note the diameter of the axone and of the medullary sheath and the appearance of the nodes of Ranvier. An occasional neurolemma nucleus can be distinguished.

(4) Medullated nerve fibres—fibres from the cauda equina (this material has the advantage of being comparatively free from fibrous connective tissue)—are fixed in formalin-Müller's fluid (technic 5, p. 7), and hardened in alcohol. Small strands are stained twenty minutes in strong picro-acid-fuchsin solution (technic 2, p. 24), washed thoroughly in strong alcohol, cleared in oil of origanum, thoroughly teased longitudinally and mounted in balsam.

General References for Further Study of Tissues

Barker: The Nervous System.

Bethe: Allgemeine Anatomie und Physiologie des Nervensystem.

Cabot: A Guide to the Clinical Examination of the Blood for Diagnostic Purposes.

Ewing: Clinical Pathology of the Blood.

Hertwig: Die Zelle und die Gewebe.

Kölliker: Handbuch der Gewebelehre.

Prenant, Bouin et Maillard: Traité d'Histologie.

Ramon y Cajal, S.: Histologie du Système nerveux de l'homme et des vertébrés.

Ranvier: Traité Technique d'Histologie.

Schäfer: Quain Anat., Vol. on Histology.

Van Gehuchten: Le Système nerveux de l'homme.

Wood: Laboratory Guide to Clinical Pathology.

PART IV

THE ORGANS

GENERAL STRUCTURE.

A tissue such as any one of those described in the preceding chapters scarcely exists in the pure state, that is alone by itself, in the adult body. Two or more tissues are always associated and such an association of two or more tissues for the purpose of performing a definite function constitutes an *organ*.

In practically all cases one of the tissues is connective tissue, the main function of which is to form a supportive framework for the more active specific tissue of the organ. The connective tissue is often spoken of as the *interstitial tissue*, the specific tissue as the *parenchyma*. In many cases the connective tissue forms a definite covering or capsule. From the capsule strands of connective tissue frequently extend down into the organ where they divide and subdivide to form its connective tissue framework. Sometimes the subdivision of the organ by connective tissue is quite regular, macroscopic subdivisions being marked off by coarse connective tissue septa, and these again being subdivided by finer septa. In such case the former are known as *lobes*, the latter as *lobules*.

But while an organ has been defined as consisting of two or more tissues and while in general one of these tissues is the connective tissue framework and the other the specific functioning tissue of the organ, such a simple combination of two tissue does not actually exist, for all organs are supplied with blood and lymph which are distributed to them and through them by the blood and lymph vessels. There are thus carried into the organs not only the blood and lymph themselves, but also the tissues which compose the walls of the blood and lymph vessels. Also every organ has its nerve supply; thus nerve tissue is distributed through all organs.

Many organs are hollow tubes and their study is the study of the structure of the walls of the tube, such, *e.g.*, are the stomach and intestines, the heart and the blood-vessels, the trachea and bronchi. Other organs not so apparently tubular still show their tubular structure on closer analysis, such, *e.g.*, are the lungs and the duct glands.

As an organ has a specific function and as this function is performed mainly by the specific cells of the organ, these cells show variations in structure dependent upon whether the organ is at work or at rest.

Many adult organs are so complex that it is possible to understand

them only by reference to their development from more simple structures.

From the foregoing it follows that in studying an organ there are to be considered primarily:

(1) The specific tissue of the organ. (Parenchyma.)
(2) The connective tissue framework. (Interstitial tissue.)
(3) The blood supply.
(4) The nerve supply.
(5) Function.
(6) Development.

CHAPTER XI

THE CIRCULATORY SYSTEM

THE circulatory apparatus consists of two systems of tubular structures, the blood-vessel system and the lymph-vessel system, which serve, respectively, for the transmission of blood and lymph.

THE BLOOD-VESSEL SYSTEM

This consists of (*a*) a central propelling organ, the *heart;* (*b*) a series of efferent tubules—the *arteries*—which by branching constantly increase in number and decrease in calibre, and which serve to carry the blood from the heart to the tissues; (*c*) minute anastomosing tubules—the *capillaries*—into which the arteries empty and through the walls of which the interchange of elements between the blood and the other tissues takes place; (*d*) a system of converging tubules —the veins—which receive the blood from the capillaries, decrease in number and increase in size as they approach the heart, and serve for the return of the blood to that organ.

The entire system—heart, arteries, veins, capillaries—has a common and continuous lining, which consists of a single layer of endothelial cells. Of the capillaries this single layer of cells forms the entire wall. In the heart, arteries, and veins, the endothelium serves simply as the lining for walls of muscle and connective tissue.

Capillaries

It is convenient to describe these first on account of their simplicity of structure. A capillary is a small vessel from 4.5 to 16μ in diameter. Its wall consists of a single layer of endothelial cells. The cells are somewhat elongated in the long axis of the vessel. The smaller the calibre of the capillary the more elongated are the cells. Two endothelial cells suffice to complete the circumference of small capillaries, while larger require three or four. The protoplasm is clear or finely granular. The nuclei are oval, their long axes running lengthwise of the vessel. In fixed material the nuclei bulge into the lumen. In

the living condition the lining of the capillary is probably nearly smooth. According to some investigators a delicate cuticle limits the cytoplasm on the side toward the lumen. The edges of the cells are serrated and are united by a small amount of intercellular substance (p. 81), which can be demonstrated by the silver-nitrate stain.[1] In certain capillaries—those of the early embryo, of the kidney glomeruli, of the chorioid coat of the eye, of the liver—no cell boundaries can be made out. In these capillaries the endothelium appears to be of the nature of a syncytium (p. 70). Capillaries branch without diminution in calibre, and these branches anasto-

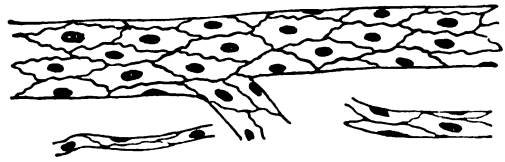

FIG. 92.—Large and Small Capillaries. Silver-nitrate and hæmatoxylin stain (technic 7, p. 82), to show outlines of endothelial cells and their nuclei.

mose to form capillary networks, the meshes of which differ in size and shape in different tissues and organs (Figs. 92, 93, 94). The largest meshed capillary networks are found in the serous membranes and in the muscles, while the smallest are found in the glands, as, *e.g.*, the liver. The largest capillaries are found in the liver, the smallest in muscles.

In such thin membranous parts as the web of the frog's foot, or the wall of the frog's bladder, the blood may be observed as it flows through the arteries, capillaries, and veins. The current is seen to be fastest in the arteries, and faster in the centre of the vessel than at its periphery. It is slower in the veins and slowest in the capillaries. In the case of the frog's bladder, the mere exposure to the air acts as a sufficient irritant to cause slight inflammatory changes, and the leucocytes may be seen adhering to the walls of the capillaries and passing through them into the tissues. The capillary, both from the thinness of its wall and from the slowness with which the blood passes through it, is peculiarly adapted for the interchange of material between the blood and the tissues, and it is probable that it is in the capillary that all such interchange takes place.

[1] Some authors describe delicate protoplasmic anastomoses between the cells and an irregular precipitation of the silver nitrate corresponding to the spaces between the anastomosing threads. These spaces are interpreted as intercellular channels through which the leucocytes and plasma pass. Intracellular spaces reacting to silver nitrate and supposed to have a similar function have also been described.

Arteries

The wall of an artery consists of three coats:

(1) An inner coat, the *intima*.

(2) The middle coat, the *media*.

(3) An outer coat, the *adventitia*.

The intima consists of a single layer of endothelial cells, continuous with and similar to that forming the walls of the capillaries, or,

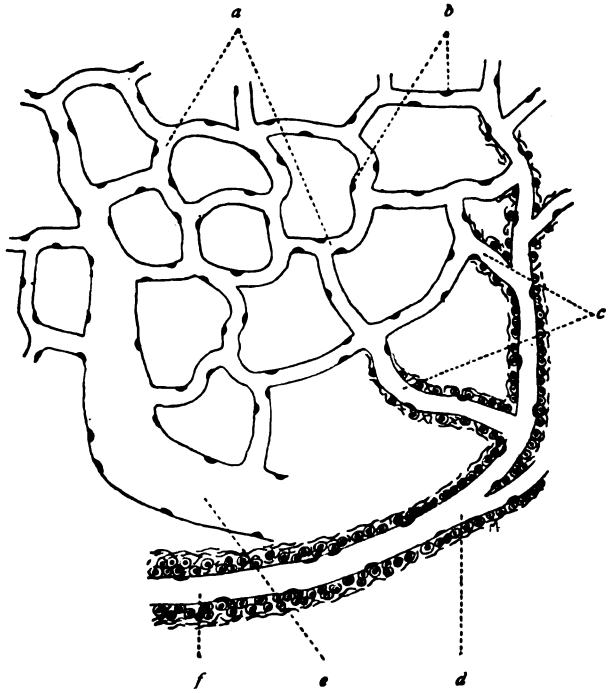

FIG. 93.—Diagram of Capillaries and Small Artery showing their structure and relations. *a*, Capillaries; *b*, nuclei of capillary endothelium; *c*, precapillary arteries; *d*, arteriole; *e*, large capillary; *f*, small artery.

in arteries of considerable size, of this layer plus more or less connective tissue. The middle coat consists mainly of smooth muscle, the outer of connective tissue.

The structure of these three coats varies according to the size of the artery, and while the transition between them is never abrupt, it is convenient, for purposes of description, to distinguish (*a*) small arteries, (*b*) medium sized arteries, and (*c*) large arteries.

Small Arteries.—Passing from a capillary to an artery, the first change is the addition of a thin sheath of connective tissue, the fibres

of which are disposed longitudinally, around the outside of the endothelial tube. A little farther back isolated smooth muscle cells, circularly arranged, begin to appear between the endothelium and the connective tissue. Such an artery is known as a *precapillary artery*. The next transition is the completion of the muscular coat, the muscle cells now forming a continuous layer. Such an artery, consisting of three distinct coats, the middle coat composed of a single continuous layer of smooth muscle cells, is known as an *arteriole* (Fig. 93, *d*; Fig. 94, *b*).

Medium-sized Arteries.—This group comprises all the named arteries of the body with the exception of the aorta and the pulmonary. Their walls are formed of the same three coats found in the arteriole, but the structure of these coats is more elaborate.

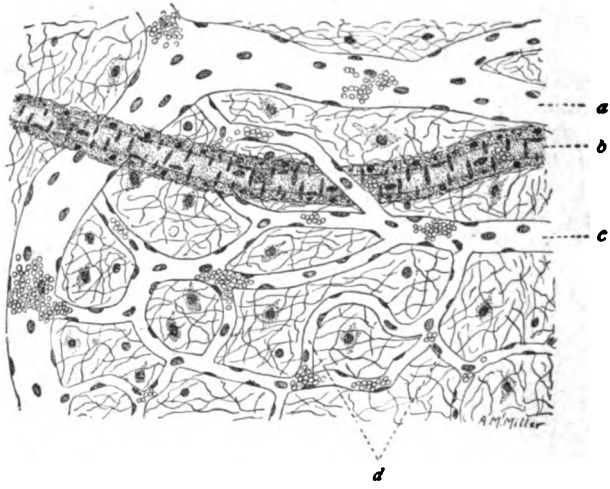

FIG. 94.—Capillary Network from Human Pia Mater, showing also an arteriole in "optical section" and a small vein. ×350. (Technic 1, p. 164.) *a*, Vein; *b*, arteriole; *c*, large capillary; *d*, small capillaries.

1. The INTIMA consists of three layers (Fig. 95).

(*a*) An inner endothelial layer already described.

(*b*) A middle layer, the intermediary layer of the intima. This is composed of delicate white and elastic fibrils which run longitudinally, and connective-tissue cells.

(*c*) An outer layer, the elastic layer of the intima, or *membrana elastica interna*—a thin fenestrated membrane of elastic tissue. This membrane is intimately connected with the media and marks the boundary between the latter and the intima. In the smallest of

the medium-sized arteries the intermediary layer is often wanting, the endothelial cells resting directly upon the elastic membrane. Owing to the extensive amount of elastic tissue in their walls, there is a postmortem contraction of arteries which results in the intima being thrown up into folds. For this reason the elastic membrane presents, in transverse sections of an artery, the appearance of a wavy band (Fig. 95).



FIG. 95.—From Cross-section through Walls of Medium-sized Artery and its Accompanying Vein. ×75. (Technic 3, p. 164.) *A*, Intima of artery; *a*, its endothelial layer; *b*, its intermediary layer; *c*, its elastic layer; *B*, media of artery; *C*, adventitia, the upper part belonging to the artery, the lower to the vein; within the adventitia are seen the vasa vasorum; *D*, media of vein; *E*, intima of vein; *i*, its intermediary layer; *j*, its endothelial layer.

2. The MEDIA is a thick coat of circularly disposed smooth muscle cells (Fig. 95, *B*). Its thickness depends largely upon the size of the vessel, though varying somewhat for different vessels of the same size. A small amount of fibrillar connective tissue supports the muscle cells. Elastic tissue is present in the media, the amount being usually proportionate to the size of the vessel. In the smaller of the medium-sized arteries, the elastic tissue is disposed as delicate fibrils among the muscle cells. In larger arteries many coarse fibres are intermingled with the fine fibrils. When much elastic tissue is present the muscle cells are separated into more or less well-defined groups. In such large arteries as the subclavian and the carotid, elastic tissue

occurs not only as fibrils but also as circularly disposed plates or fenestrated membranes.

3. The ADVENTITIA (Fig. 95, *C*) is composed of loose fibrous connective tissue with some elastic fibres. Occasionally there are scattered smooth muscle cells. Both smooth muscle cells and elastic fibres are arranged longitudinally. The adventitia does not form a definitely outlined coat like the media or intima, but blends



FIG. 96.—From Transverse Section of Dog's Aorta. ×60. (Technic 4, p. 164.) Intima; *b*, media; *c*, adventitia; *d*, vasa vasorum; *e*, elastic tissue; *f*, endothelium.

externally with the tissues surrounding the artery and serves to attach the artery to these tissues. In some of the larger arteries the elastic tissue of the adventitia forms an especially well-defined layer at the outer margin of the media. This is known as the *membrana elastica externa*. In general, it may be said that the thickness of the adventitia and the amount of elastic tissue present are directly proportionate to the size of the artery.

Large arteries like the aorta (Fig. 96) have the same three coats as small and medium-sized arteries. The layers are not, however, so distinct. This is due mainly to the excessive amount of elastic

tissue in the media (Fig. 97), which makes indistinct the boundaries between intima and media, and between media and adventitia. The walls of the aorta are thin in proportion to the size of the vessel, increased strength being obtained by the decided increase in the amount of elastic tissue. Of the *intima*, the endothelial cells are short and polygonal; the intermediary layer similar to that of a medium-sized artery; the elastic layer less distinct and often broken up into several



FIG. 97.—From Transverse Section of Dog's Aorta, to show Elastic Tissue. ×60. (Technic 7, p. 165.) Elastic tissue stained black. *a*, Intima; *b*, media; *c*, adventitia.

thin layers. The *media* consists mainly of elastic tissue arranged in circular plates or fenestrated membranes. Between the elastic-tissue plates are groups of smooth muscle cells and some fibrillated connective tissue. The *adventitia* resembles that of the medium-sized artery. There is no external elastic membrane.

Certain arteries have structural peculiarities. The arteries of the brain and cord are thin-walled in proportion to their calibre, the inner elastic membrane is especially well defined, and there are few elastic fibres in the media. In the renal, cœliac, mesenteric, and external iliac arteries there is little or no connective

tissue separating the endothelium from the media. In the subclavian, the media contains longitudinal muscle cells. Longitudinally running muscle cells occur in the adventitia of the umbilical arteries, in the iliac, splenic, renal, superior mesenteric and dorsalis penis. The radial, femoral and cœliac arteries have comparatively little elastic tissue, while in the common iliac, carotid, and axillary the elastic tissue is in excess of the muscular.

Veins

The walls of veins resemble those of arteries. There are the same three coats, *intima*, *media*, and *adventitia*, and the same elements enter into the structure of each coat (Fig. 95). Venous walls are not, however, so thick as those of arteries of the same calibre, and the coats are not so distinctly differentiated from one another. The transition from capillary through the precapillary vein to the small vein is similar to that described under arteries (page 157). Unlike the artery, the thickness of the wall of a vein and its structure are not directly proportionate to the size of the vessel, but depend also upon other factors such as the position of the vein and the support given to its walls by surrounding structures.

Of the INTIMA the endothelial layer and the intermediary layer are similar to those of the artery. The elastic layer is not always present, is never so distinct, and is not wavy as in the artery (Fig. 95). The result is a lack of demarcation between intima and media, the connective tissue of the intermediary layer of the intima merging with the mixed muscle and connective tissue of the media. Projecting at intervals from the inner surfaces of the walls of some veins are *valves*. These are derived entirely from intima and consist of loose connective tissue covered by a single layer of endothelium. Beneath the endothelium of the convex surface of the valve (the surface directed peripherally or against the blood current) is a rich network of elastic fibres continuous with the elastic tissue of the intima of the adjacent vein wall. The connective tissue along the opposite margin of the valve is entirely free from or contains very few elastic fibres. Valves are especially large and strong in the larger veins of the lower limbs. They are absent in the veins of the brain and cord and their membranes, in the veins of bones, in the umbilical vein, and in most of the visceral veins with the exception of some branches of the portal.

The MEDIA of veins is thin as compared with that of arteries of the same size. It consists of fibrous and elastic tissue and circularly

disposed smooth muscle cells. In most veins the amount of muscle is comparatively small and the cells are distributed in groups through the connective tissue. The media is thickest in the veins of the lower extremities, especially the popliteal, and in the veins of the skin. In the veins of the head and abdomen the media is very thin, while in the subclavian and superior vena cava and in the veins of bones, of the pia mater, dura mater, and retina, there is an almost entire absence of media.

The ADVENTITIA is well developed in proportion to the media and forms the bulk of the vessel wall. It consists of mixed fibrous and elastic tissue and usually contains along its inner margin small bundles of longitudinally disposed smooth muscle cells.

Arteries are as a rule empty after death, while veins contain blood. The absence of much elastic tissue in the walls of the veins prevents any such extensive post-mortem contraction as occurs in the arteries. Veins tend to collapse after death, but are usually prevented from doing so by the presence of blood in them.

In the iliac and femoral veins, longitudinally disposed muscle occurs in the inner part of the media. The umbilical vein, like the corresponding artery, has three distinct muscular coats. Longitudinal muscle fibres are present in the adventitia of the superior vena cava (hepatic and abdominal portion) and of the portal and hepatic veins. In the upper portion of the inferior vena cava, in the superior vena cava, the jugular, innominate, and subclavian, there is little muscle tissue in any of the coats, while in the veins of the brain and its membranes, the retina, the placenta and the bones, no muscle is present.

Vasa Vasorum.—Medium and large arteries and veins are supplied with small nutrient vessels—vasa vasorum. These vessels run in the adventitia, small branches penetrating the media (Figs. 95 and 96).

Lymph channels are found on the outer surface of many blood-vessels. Some of the smaller vessels are surrounded by spaces lined by endothelium—*perivascular lymph spaces*. These communicate with the general lymphatic system.

Nerves.—The walls of the blood-vessels are supplied with both medullated and non-medullated fibres. The latter are axones of sympathetic neurones. As these nerves control the calibre of the vessels they are known as vasomotor nerves. They form plexuses in the adventitia, from which are given off branches which penetrate the media and terminate on the muscle cells. The medullated fibres are the peripheral arms of spinal or cranial ganglion cells.

The larger fibres run in the connective tissue outside the adventitia. From these are given off branches which enter the media, divide repeatedly, lose their medullary sheaths, and terminate mainly in the media, although some fibres have been traced to their terminations in the intima.

TECHNIC

(1) Capillaries, Arterioles, Small Arteries, and Veins.—Fix an entire brain, or slices about an inch thick from its surface, in formalin-Müller's fluid for twenty-four hours (technic 6, p. 7). Remove the pia mater, especially the thinner parts which lie in the sulci between the convolutions, and harden in graded alcohols. Select a thin piece, stain with hæmatoxylin (lightly) and eosin (strongly) (technic 1, p. 23), and mount in balsam or in eosin-glycerin. The veins, having thin walls and being usually well filled with blood, appear distinct and red from the eosin-stained red cells. The arteries, having thicker walls, in which are many hæmoglobin-stained nuclei, have a rather purple color. Between the larger vessels can be seen a network of anastomosing capillaries with their thin walls and bulging nuclei. Some are filled with blood cells; others are empty with their collapsed walls in apposition. Note the appearance of an arteriole, first focusing on its upper surface, then focusing down through the vessel. In this way what is known as an "optical section" is obtained, the artery appearing as if cut longitudinally. Trace the transition from arteriole to precapillary artery and the breaking up of the latter into the capillary network. Similarly follow the convergence of capillaries to form a small vein.

(2) Instructive pictures of the relations of arteries, capillaries, and veins in living tissues may be obtained by curarizing a frog, distending the bladder with normal saline introduced through a small catheter or cannula, opening the abdomen and drawing out the bladder, which can then be arranged upon the stage of the microscope. The passage of the blood from the arteries through the capillary network and into the veins is beautifully demonstrated.

(3) For studying the structure of the walls of a medium-sized artery and vein remove a portion of the radial artery, or other artery of similar size, and its accompanying vein, together with some of the surrounding tissues. Suspend the vessels, with a small weight attached, in formalin-Müller's fluid (technic 6, p. 7). Sections should be cut transversely, stained with hæmatoxylin-eosin (technic 1, p. 23), or with hæmatoxylin-picro-acid fuchsin (technic 3, p. 24), and mounted in balsam. The vessels of the adventitia—vasa vasorum—are convenient for studying the structure of arterioles and small veins.

(4) Fix a piece of aorta in formalin-Müller's fluid, care being taken not to touch the delicate endothelial lining. Stain transverse sections with hæmatoxylin-eosin or with hæmatoxylin-picro-acid fuchsin and mount in balsam.

(5) The outlines of the lining endothelial cells may be demonstrated as follows: Kill a small animal, cut the aorta, insert a glass cannula and, under low pressure, thoroughly wash out the entire vascular system with distilled water. Follow the water by a one-per-cent. aqueous solution of silver nitrate. Remove some of the smaller vessels, split longitudinally, mount in glycerin, and expose

to the direct sunlight. After the specimen has turned brown examine with the low power. The outlines of the cells should appear brown or black.

(6) The endothelium of the smaller vessels and capillaries may also be demonstrated in the specimen described under technic 8, p. 83.

(7) The elastic tissue of the blood-vessels is best demonstrated by means of Weigert's elastic-tissue stain. Prepare sections of medium-sized vessels and of the aorta, as above described (3), and stain as in technic 3, p. 28.

The Heart

The heart is a part of the blood-vessel system especially differentiated for the purpose of propelling the blood through the vessels.

The main mass of the heart wall consists of a special form of muscle tissue already described as heart muscle (page 123). This constitutes the *myocardium*. On its inner and outer sides the myocardium is covered by connective-tissue membranes lined, respectively, with endothelium and mesothelium and known as the *endocardium* and *epicardium*.

The MYOCARDIUM varies in thickness in different parts of the heart, being thickest in the left ventricle, thinnest in the auricles. A ring of dense connective tissue, the *auriculo-ventricular ring*, completely separates the muscle of the auricles from that of the ventricles, except in the median septum where the auricular and ventricular muscle is continuous. The auricular muscle consists of an outer coat common to both auricles, the fibres of which have a transverse or somewhat oblique direction, and of an inner coat, independent for each auricle, the fibres of which are longitudinally disposed. Bundles of these fibres stand out as ridges along the inside of the auricles. They are more strongly developed in the right than in the left auricle. Between the two coats bundles of muscle fibres are frequently found which run in various directions.

The disposition of the muscle tissue of the ventricles is much more complicated. It is usually described as composed of several layers, the fibres of which run in different directions. The meaning of these fibre layers becomes apparent when we study the arrangement of the fibres in embryonic hearts in which the connective tissue has been broken down by maceration. Thus dissected, the muscle of the ventricles is seen to consist mainly of two sets of fibres, a *superficial set* and a *deep set*. These run at approximately right angles to each other. Both sets of fibres begin at the auriculo-ventricular rings. The superficial fibres wind around both ventricles in a spiral

manner, becoming constantly deeper, to terminate in the papillary muscles of the opposite ventricle. The deeper fibres pass from the auriculo-ventricular ring around the ventricle of the same side, through the interventricular septum and terminate in the papillary muscles of the opposite ventricle.

The ENDOCARDIUM covers the inner surface of the myocardium and forms the serous lining of all the chambers of the heart. At the arterial and venous orifices it is seen to be continuous with and similar in structure to the intima of the vessels. It consists of two layers: (*a*) an inner composed of a single layer of endothelial cells, corresponding to the endothelial lining of the blood-vessels; and (*b*) an outer composed of mixed fibrous and elastic tissue and smooth muscle cells. Externally the endocardium is closely attached to the myocardium.

Strong fibrous rings (*annuli fibrosi*), composed of mixed fibrous and elastic tissue, surround the openings between auricles and ventricles. Similar but more delicate rings encircle the openings from the heart into the blood-vessels.

The *heart valves* are attached at their bases to the annuli fibrosi. They are folds of the endocardium, and like the latter consist of fibrous and elastic tissue continuous with that of the rings and covered by a layer of endothelium.

The EPICARDIUM is the visceral layer of the pericardium It is a serous membrane like the endocardium, which it resembles in structure. It consists of a layer of mixed fibrous and elastic tissue covered over by a single layer of mesothelial cells. Beneath the epicardium there is usually more or less fat.

Blood-vessels.—Blood for the nutrition of the heart is supplied through the coronary arteries. The larger branches run in the connective tissue which separates the bundles of muscle fibres. From these, smaller branches pass in among the individual fibres, where they break up into a rich capillary network with elongated meshes. From the myocardium, capillaries penetrate the connective tissue of the epicardium and endocardium. The auriculo-ventricular valves are supplied with blood-vessels, while in the semilunar valves blood-vessels are wanting.

Lymphatics.—Lymph channels traverse the epicardium and endocardium and enter the valves. Within the myocardium minute lymph vessels have been demonstrated between the muscle fibres and accompanying the blood-vessels.

Nerves.—These are derived from both cerebro-spinal (vagus) and sympathetic systems (cervical ganglia) and consist of both medullated and non-medullated fibres. Sympathetic ganglion cells are distributed in groups throughout the myocardium, the largest, lying in the epicardium near the base of the heart, being known as the cardiac ganglion or ganglion of Wrisberg. Among these cells the nerve fibres form plexuses from which both motor and sensory terminals are given off to the muscle. (For nerve endings in heart muscle see page 455.)

TECHNIC

(1) The Heart.—Cut pieces through the entire thickness of the wall of one of the ventricles, care being taken not to touch either the serous surface or the lining endothelium. Fix in formalin-Müller's fluid (technic 6, p. 7). Cut transverse and longitudinal sections; stain with hæmatoxylin-eosin (technic 1, p. 23) and mount in balsam.

(2) Treat the entire heart of a small animal (*e.g.*, guinea-pig or frog) in the same manner as the preceding, making transverse sections through both ventricles.

(3) An entire heart, human or animal, may be fixed in the distended condition by filling with formalin-Müller's fluid under low pressure and then tying off the vessels. The entire heart thus distended is placed in a large quantity of the same fixative.

Development of the Circulatory System

The blood-vessels and the heart begin their development separately and afterward become united. Both are derived from mesoderm, but while the heart develops within the embryo, the earliest blood-vessels and blood are developed from extra-embryonic mesoderm. The earliest vessels to be formed are the capillaries. These make their appearance in the mesodermic tissue near the periphery of the area vasculosa which surrounds the developing embryo. Here groups of cells known as "*blood islands*" differentiate from the rest of the mesodermic cells, appearing in the chick by the end of the first day of incubation. The superficial cells of these islands become flattened to form the endothelium, which is at this stage apparently a syncytium through which the nuclei are scattered and showing no evidences of cell boundaries. This endothelial syncytium surrounds the remaining more central cells, from which blood cells are developed. These represent the earliest blood-vessels. The channels, which are at first unconnected, anastomose and give rise to a network of channels which are the earliest capillaries. These develop rapidly in the area vasculosa and some of them increase in size to become arteries and veins, the smooth muscle and connective tissue of their walls being differentiated from the surrounding mesoderm. These grow toward, and finally into, the embryo where they unite with the heart. In granulation tissue, and in new growths in general, both normal and pathological, new blood-vessels apparently develop as off-shoots from other vessels. These are at first solid extensions

of endothelium which become hollowed out. In regard to the origin of the later vessels in the extraembryonic area, and those within the embryo, there are two views: (1) that they represent outgrowths from the original capillaries; (2) that they arise *in situ* in the same manner as the earliest capillaries and unite secondarily to form networks. The weight of evidence at present favors the latter view. The entire vascular system is at first represented by a network of capillaries. As development proceeds some of the channels enlarge to form the arteries and veins.

The heart first appears as an endothelial tube, the *primitive endocardium*, at a very early age of embryonic life, in the chick embryo during the first day of incubation. It apparently begins its rhythmic contraction before any

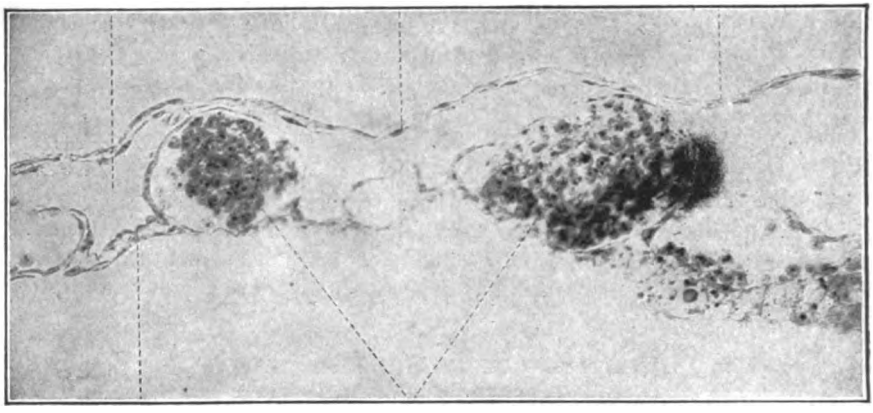

FIG. 98.—Section of Blastoderm of Chick of 42 Hours Incubation. Photograph. The cells of the blood islands are differentiated into nucleated red blood cells (erythroblasts) and the endothelium of the vessels.

contractile fibrils can be distinguished in its walls and before any connection with blood-vessels has been established. The origin of the cardiac endothelium is not definitely known. It is believed by some to be of entodermic origin, by others of mesodermic, by still others to be partly derived from each of these layers. Around this endothelial tube, but separated from it by a space, there develops from mesoderm an entirely distinct muscular tube, the *primitive myocardium*. These two tubes are at first united only in places by bands of connective tissue. Later they unite so that the inner tube, the *endocardium* becomes a lining for the outer tube, the *myocardium*. The union of the two heart tubes occurs very early. The foregoing description applies to the chick and to those mammals thus far studied. In the earliest human embryos (2 to 3 mm.) the heart is already a single, slightly coiled tube connected at its cephalic end with the ventral aorta and caudally with the omphalo-mesenteric veins. The *epicardium*, as the visceral layer of the pericardium, has a separate origin, being constricted off from that portion of the mesoderm which lines the primary body cavity.

THE LYMPH-VESSEL SYSTEM

The larger lymph vessels are similar in structure to veins. Their walls are, however, thinner than those of veins of the same calibre and they contain more valves. These are folds of the intima, and always occur in pairs. They are arranged with considerable regularity and in small vessels where the intima forms the entire wall there is a distinct bulging just above the valve which gives the vessel a quite characteristic appearance. They are capable of great distention, and when empty collapse so that their thin walls are in apposition.

The largest of the lymph vessels, the thoracic duct, has three well-defined coats: an *intima* consisting of the usual lining endothelium resting upon a subendothelial layer of delicate fibro-elastic tissue, the outermost elastic fibres having a longitudinal arrangement; a fairly thick *media* of circularly disposed smooth muscle cells which occur in groups separated by connective tissue containing a few elastic fibres and an *adventitia* of longitudinally running connective tissue containing elastic fibres and strengthened by bundles of longitudinal smooth muscle.

Lymph capillaries resemble blood capillaries in that their walls are composed of a single layer of endothelial cells. The cells are rather larger and more irregular than in blood capillaries, the capillaries themselves are larger, and, instead of being of uniform diameter throughout, vary greatly in calibre within short distances. In certain tissues dense networks of these lymph capillaries are found. Cleft-like lymph spaces—perivascular lymph spaces—partially surround the walls of the smaller blood-vessels.

Lymph spaces without endothelial or other apparent lining also occur. Examples of these are the *pericellular lymph spaces* found in various tissues and the *canaliculi* of the cornea and of bone (pages 87 and 105).

Similar in character to lymph spaces are the body cavities, *peritoneal*, *pleural*, and *pericardial*, with their linings of serous membranes. These cavities first appear in the embryo as a cleft in the mesoderm —*the cœlom*, *body cavity*, or *pleuroperitoneal cleft*. This cleft is lined with mesothelium beneath which the stroma is formed. These membranes not only line the cavities, but are reflected over most of the viscera of the abdomen and thorax. They consist of a *stroma* of mixed fibrous and elastic tissue, covered on its inner side by a layer

of *mesothelium*, the two being separated by a homogeneous basement membrane. The stroma contains numerous lymphatics. These have been described as communicating with the free surfaces by means of openings—*stomata*. Recent observations, however, would seem to indicate that these stomata are artefacts.

That the lymph-vessels form a definite and closed system of channels and are not in direct communication with the lymph spaces has been clearly demonstrated.

The origin of the lymphatic vessels is not clear. According to some investigators they originate as evaginations from the vascular system, starting as four buds, two from the veins of the neck, and two from the veins in the inguinal region. The two anterior buds appear first (pig embryo of 14.5 mm.) and are in communication with the anterior cardinal vein. A little later the posterior buds connected with the posterior cardinals appear. From these buds the entire lymphatic plexus develops by a process of evagination.

According to other investigators, the lymphatic vessels first appear as minute spaces in the mesenchyme of the axilla and groin (during second month in human embryo). These spaces enlarge and by sending off branches give rise to the network of lymphatic vessels. According to this veiw, the connection between lymphatic vessels and veins is secondary.

TECHNIC

(1) Remove a portion of the central tendon of a rabbit's diaphragm. Rub the pleural surface gently with the finger or with a brush to remove the mesothelium. Rinse in distilled water and treat with silver nitrate as in technic 7, p. 82. Mount in glycerin. If the silver impregnation is successful, the networks of coarser and finer lymphatics can be seen as well as the outlines of the endothelium of their walls. If care has been taken not to touch the peritoneal surface, the peritoneal mesothelium and the stomata are frequently seen.

(2) The Thoracic Duct.—Remove a portion of the thoracic duct, fix in formalin-Müller's fluid (technic 6, p. 7), and stain sections with hæmatoxylin-eosin (technic 1, p. 23).

General References for Further Study of the Circulatory System

Kölliker: Handbuch der Gewebelehre des Menschen, vol. iii.

Stöhr: Text-book of Histology.

Schäfer: Histology and Microscopic Anatomy, in Quain's Elements of Anatomy, tenth edition.

CHAPTER XII

LYMPHATIC ORGANS

Lymphatic Tissue[1]

So-called lymphatic tissue consists of reticular connective tissue and a special type of cells, lymphoid cells, which fill in the meshes of the reticulum. Lymphoid cells are small spheroidal cells, each having a single nucleus which almost completely fills the cell. Lymphatic tissue may be diffuse or circumscribed. In diffuse lymphatic tissue the cells are not closely packed and there is no distinct demarcation between the lymphatic and the surrounding tissues. An example of diffuse lymphatic tissue is seen in the stroma of the mucous membrane of the gastro-intestinal canal. In circumscribed lymphatic tissue the cells are very closely packed, often completely obscuring the reticulum. There is also a quite distinct demarcation between the lymphatic and the surrounding tissues. Such a circumscribed mass of lymphatic tissue is known as a lymph nodule.

The Lymph Nodes

Lymph nodes are small bodies, usually oval or bean-shaped, which are distributed along the course of the lymph vessels. In some regions they are arranged in series forming "chains" of lymph nodes as, *e.g.*, the axillary and inguinal.

Each lymph node is surrounded by a *capsule* of connective tissue which sends *trabeculæ* or *septa* into the organ. The capsule and septa constitute the *connective-tissue framework* of the node, and serve as a support for the lymphatic tissue (Fig. 99).

The *capsule* is composed of fibrous connective tissue. Toward the surface of the capsule the fibres are loosely arranged and there are comparatively few elastic fibres. This outer layer of the capsule

[1] In some earlier editions "lymphatic tissue" was placed according to name rather than structure among the tissues. As it consists of a connective tissue framework supporting a special type of cell which has a specific function, it is more properly classified as an organ. On account of the peculiar structure and wide distribution of the "tissue" and on account of convenience and long usage, the term "lymphatic tissue" is still retained.

blends with the surrounding tissues and serves, like the fibres of the arterial adventitia, to attach the organ to them. The inner layer of the capsule consists of a more dense connective tissue, is richer in elastic fibres, and contains some smooth muscle cells. At one point, known as the *hilum* (Fig. 99), there is a depression where the connective tissue of the capsule extends deep into the substance of the node. This serves as the point of entrance for the main arteries and nerves, and of exit for the veins and efferent lymph vessels.

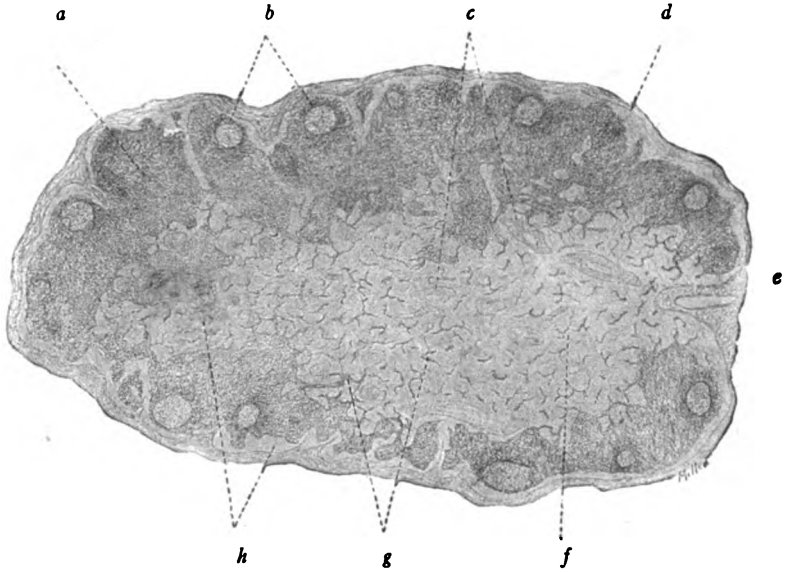

FIG. 99.—Section through Entire Human Lymph Node, including Hilum. ×15 (Technic 1, p. 176.) Dark zone, cortex; light central area, medulla. *a*, Lymph nodule of cortex; *b*, germinal centres; *c*, trabeculæ containing blood-vessels; *d*, capsule; *e*, hilum; *f*, lymph sinus of medulla; *g*, lymph cords of medulla; *h*, lymph sinuses of medulla and cortex.

The *connective-tissue septa*, which extend from the capsule into the interior of the node incompletely divide it into irregular intercommunicating compartments. In the peripheral portion of the node these compartments are somewhat spheroidal or pear-shaped. Toward the centre of the node the septa branch and anastomose freely, with the result that the compartments are here narrower, more irregular, and less well defined.

Within the compartments formed by the capsule and the septa is the *lymphatic tissue*. Near the capsule where the compartments are large and spheroidal or pear-shaped, the lymphatic tissue is arranged in masses which correspond in shape to the compartments.

These are known as *lymph nodules* (Fig. 99). In the centre of each nodule is usually an area in which the cells are larger, are not so closely packed, and show marked mitosis. As it is here that active proliferation of lymphoid cells takes place, this area is known as the *germinal centre* (Figs. 99 and 100). Immediately surrounding the germinal centre is a zone in which the lymphoid cells are more closely packed than elsewhere in the nodule (Fig. 100). This is apparently due to the active production of new cells at the germinal centre and the consequent pushing outward of the surrounding cells. In stained sections the centre of the nodule is thus lightly stained, while immediately surrounding this light area is the darkest

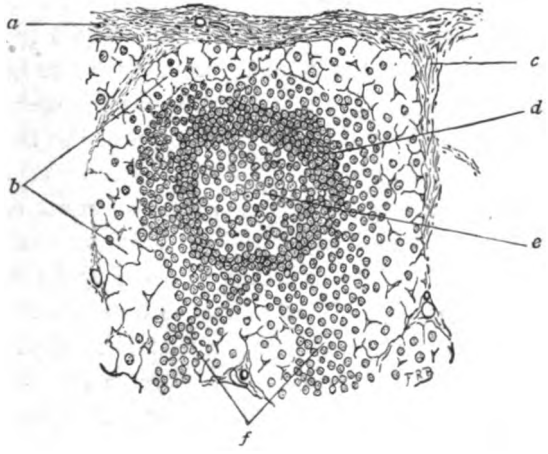

FIG. 100.—Section through Cortex and Portion of Medulla of Human Lymph Node (Technic 2, p. 176.) *a*, Capsule; *b*, lymph sinus; *c*, trabecula; *d*, closely packed cells at outer border of lymph nodule; *e*, germinal centre; *f*, lymph cords in medulla.

portion of the nodule (Fig. 100). From the inner sides of the nodule, strands of lymphoid tissue extend into the center of the node. These are known as *lymph cords*, and anastomose freely. The regular arrangement of the lymph nodules and trabeculæ in the peripheral portion of the node contrasts strongly with their irregular arrangement in the centre. This determines a division of the nodule into two zones, an outer peripheral zone or *cortex* and a central zone or *medulla*. In both cortex and medulla the lymphoid tissue is always separated from the capsule or from the septa by a distinct space—the *lymph sinus*—which is bridged over by reticular tissue containing comparatively few lymphoid cells (Fig. 100). These sinuses form a continuous system of anastomosing incompletely walled channels throughout the node.

The regular arrangement of trabeculæ and lymph nodules with sinuses between, which is characteristic of the cortex, makes this part of the organ easily understood. To appreciate the structure of the medulla it must be borne in mind that all of these cortical structures extend down into the medulla, the trabeculæ as anastomosing networks of connective tissue, the lymph nodules as cord-like structures which divide and anastomose, the sinuses as more or less clear channels which always separate the connective tissue from the lymph cords. These parts—trabecula, sinus, lymph cord—all anastomosing freely and most irregularly in the medulla, always maintain the same relation to one another as in the cortex, namely, that sinus is always interposed between lymph tissue and trabecula.

The *reticular connective tissue* (page 98), which forms a part of the lymphatic tissue proper, is continuous with the fibrous connective-tissue framework of the organ in such a manner that it is impossible to determine any demarcation between the two tissues. In the lymph nodules, and wherever the lymphoid cells are densely packed, the underlying reticular network is almost completely obscured. Crossing the sinuses, especially those of the medulla, and in specimens in which the cells have been largely washed out or removed by maceration, the reticular structure is well shown.

The *lymphoid tissue proper*, as represented by the lymph nodules and anastomosing lymph cords, is thus, as it were, *suspended* in the meshes of a reticulum which is swung from the capsule and trabeculæ. As both nodules and cords are everywhere separated from capsule and trabeculæ by the sinuses, and as these latter serve for the passage of lymph through the node, it is seen that the lymphatic tissue of the node is broken up in such a manner as to be bathed on all sides by the circulating lymph.

In addition to the definitely formed lymph nodes and the well-defined collections of lymph nodules, such as those of the tonsil or of Peyer's patches, small nodules or groups of lymphoid cells have a wide distribution throughout the various organs. While many of these collections of lymphatic tissue are inconspicuous, still the aggregate of lymph tissue thus distributed is by no means inconsiderable. The most important will be described in connection with the organs in which they occur.

Blood-vessels.—Those which enter the hilum carry the main blood supply to the organ. Most of the arteries pass directly into the lymphatic tissue, where they break up into dense capillary net-

works. Some of the arteries, instead of passing directly to the lymphatic tissue, follow the septa, supplying these and the capsule, and also sending branches to the surrounding lymphatic tissue. A few small vessels enter the capsule along the convexity of the organ and are distributed to the capsule and to the larger septa.

Lymphatics.—The afferent lymph vessels enter the node on its convex surface opposite the hilum, penetrate the capsule, and pour their lymph into the cortical sinuses. The lymph passes through the sinuses of both cortex and medulla, and is collected by the efferent

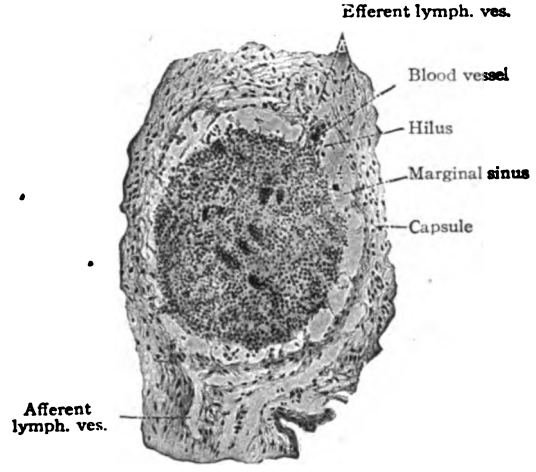

FIG. 101.—From a Section through the Axilla of a Human Embryo of 125 mm. (4–5 months), showing an Early Stage of a Lymph Gland. (Kling.)

lymph vessels which leave the organ at the hilum. Within the node the lymph comes in contact with the superficial cells of the nodules and of the lymph cords. These cells are constantly passing out into the lymph stream so that the lymph leaves the node much richer in cellular elements.

Nerves are not abundant. Both medullated and non-medullated fibres occur. Their exact modes of termination are not known.

Lymph.—This is a colorless fluid containing rather few formed elements in the way of white blood cells, blood platelets, granules and fat. Most of the cells are of the small lymphocyte type although some large lymphocytes and polymorphonuclear leucocytes are found. In the lymph of the intestinal mucosa, especially during digestion, fat droplets are present in large numbers giving the fluid a milky appearance. This is known as *chyle.*

Development.—The first indications of lymph node formation are found in the axilla and groin (pig embryo of about 30 mm.; human toward end of third month) in the connective tissue in which the lymphatic vessels are best developed (p. 170). Here groups of more closely packed cells appear. As the tissue is richly vascular it seems impossible to determine whether the closely packed cells originate within the blood-vessels or develop from fixed connective tissue cells. Each group of cells is the anlage of a lymph node (Fig. 101). The immediately surrounding connective tissue forms the capsule, while the lymph channels just beneath form the subcapsular or marginal sinus (Fig. 102). The point of main connection with outside blood-vessels becomes the hilum. As the lymph node

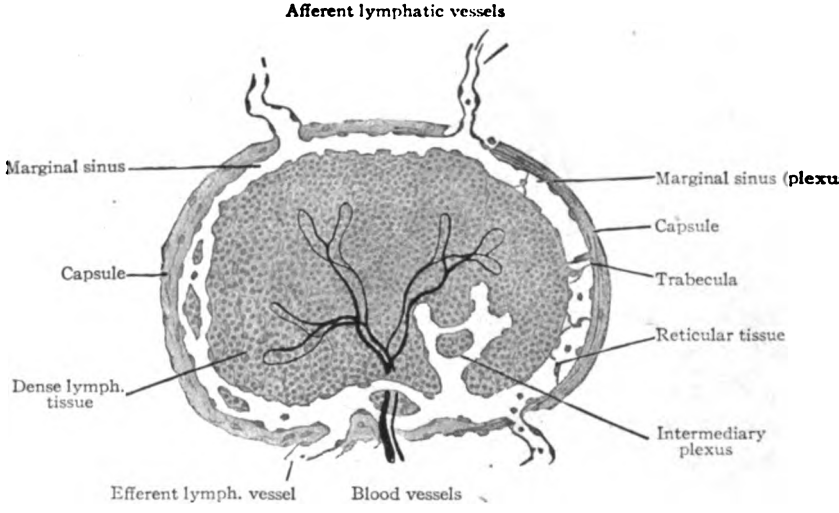

FIG. 102.—Diagram Illustrating a Stage (Later than Fig. 97) in the Development of a Lymph Gland. (Stöhr.)

grows outward, parts of the capsule remain within to form trabeculæ while the lymph channels within the nodule apparently develop as ingrowths from the marginal sinus (Figs. 101 and 102).

TECHNIC

(1) Remove several lymph nodes from one of the lower animals (ox, cat, dog, rabbit), fix in formalin-Müller's fluid (technic 6, p. 7), and harden in alcohol. Cut thin sections through the hilum, stain with hæmatoxylin-eosin (technic 1, p. 23), or with hæmatoxylin-picro-acid-fuchsin (technic 3, p. 24), and mount in balsam.

(2) Expose a chain of lymph nodules (*e.g.*, the cervical or inguinal of a recently killed dog or cat). Insert a small cannula or needle into the uppermost node and inject formalin-Müller's fluid until the node becomes tense. By now slightly increasing the pressure the fluid may be made to pass into the second node, and so through the entire chain. The nodes are then carefully dissected out

and placed for twenty-four hours in formalin-Müller's fluid, then hardened in alcohol. Sections are cut through the hilum, stained with hæmatoxylin-eosin or with hæmatoxylin-picro-acid-fuchsin and mounted in balsam. Near the centre of the chain are usually found nodes in which the lymph sinuses are properly distended. The most proximal nodes are apt to be overdistended, but for this very reason are often excellent for the study of the reticular tissue from which most of the cells have been washed out, especially in the medulla.

(3) Human lymph nodes may be treated by either of the above methods. Owing to the coalescence of their cortical nodules their structure is not so easily demonstrated as that of the lymph nodes of lower animals.

Hæmolymph Nodes

These are lymphoid structures which closely resemble ordinary lymph nodes, but with the essential difference that their sinuses are *blood sinuses instead of lymph sinuses*.

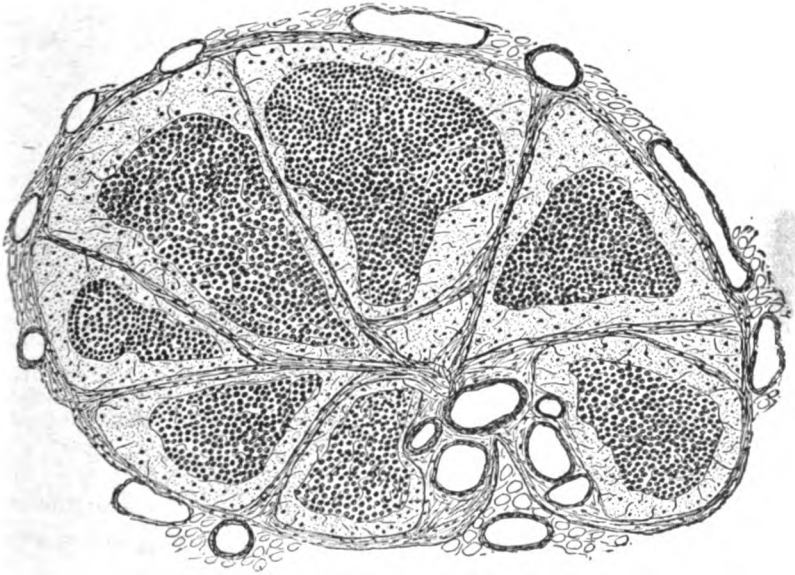

FIG. 103.—Section through Human Hæmolymph Node, including Hilum, showing capsule, trabeculæ, sinuses filled with blood, and lymph nodules. (Warthin.)

Each node is surrounded by a *capsule* of varying thickness, composed of fibro-elastic tissue and smooth muscle cells. From the capsule *trabeculæ* of the same structure pass down into the node, forming its framework (Fig. 103). Beneath the capsule is a *blood sinus*, which may be broad or narrow, and usually completely surrounds the node. Less commonly the sinus is interrupted by lymphoid tissue extending

out to the capsule. From the peripheral sinus branches extend into the interior of the node, separating the lymphoid tissue into *cords* or *islands*. The relative proportion of sinuses and lymphoid tissue varies greatly, some nodes being composed almost wholly of sinuses, while in others the lymphoid tissue predominates. There is usually a fairly distinct *hilum*. In many glands no differentiation into *cortex* and *medulla* can be made. Where there are a distinct medulla and cortex the peripheral lymphoid tissue is arranged in *nodules* as in the ordinary lymph node. *Reticular connective tissue* crosses the sinuses and supports the cells of the lymph nodules and cords (Fig. 104).

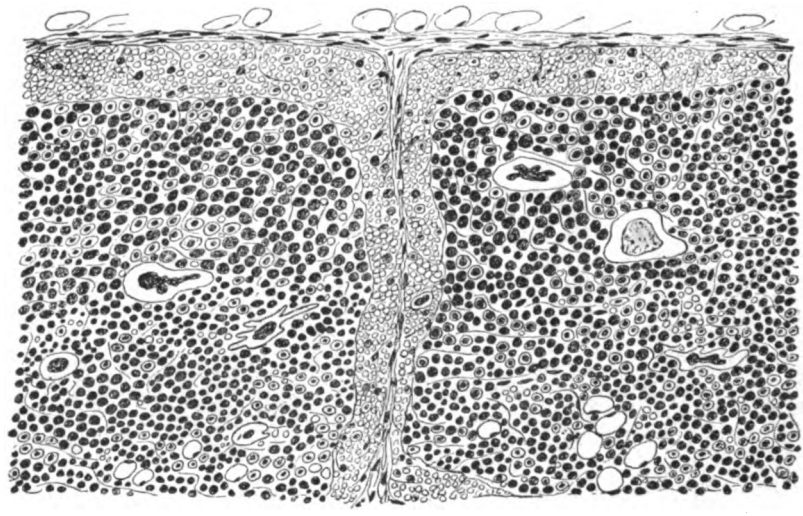

FIG. 104.—Section through Superficial Portion of Human Hæmolymph Node (Marrowlymph Node). (Warthin.) Capsule, trabeculæ, and parts of two adjacent nodules; sinuses filled with blood; among the lymph cells are large multinuclear cells resembling those of marrow, nucleated red blood cells, etc.

The cellular character of the lymphoid tissue has led to the subdivision of hæmolymph nodes into *splenolymph nodes* and *marrowlymph nodes*. In the *splenolymph node* the lymphoid tissue resembles that of the ordinary lymph node of the spleen. In the *marrowlymph node*, which is the much less common form, the lymphoid tissue resembles red marrow. There are no distinct nodules, and there is a quite characteristic distribution of small groups of fat cells. The most numerous cells are eosinophiles and mast cells (see page 110). Polynuclear leucocytes and large leucocytes with a single lobulated nucleus are less numerous. The very large multinuclear cells of red marrow are also found, but usually in small numbers.

Large *phagocytes* containing blood pigment and disintegrating red blood cells are found in both forms of hæmolymph nodes, but are most numerous in the splenolymph type. In nodes which have a brownish color when fresh, these phagocytes frequently almost completely fill the sinuses.

Further classification of hæmolymph nodes has been attempted, but is unsatisfactory, owing to the large number of transitional forms. Thus many nodes are transitional in structure betwen the hæmolymph node and the ordinary lymph node, between the splenolymph node and the marrowlymph node, and between the splenolymph node and the spleen.

Under normal conditions the hæmolymph nodes appear to be concerned mainly in the destruction of red blood cells; possibly also in the formation of leucocytes. Under certain pathological conditions they probably become centres for the formation of red blood cells.

Blood-vessels.—An artery or arteries enter the node at the hilum, and break up within the node into small branches, which communicate with the sinuses where the blood comes into intimate association with the lymphoid tissue. From the sinuses the blood passes into veins, which leave the organ either at the hilum or at some other point on the periphery. The course which the blood takes in passing through the hæmolymph node is thus apparently similar to that taken by the lymph in passing through the ordinary lymph node.

The relation of the hæmolymph node to the *lymphatic system* is not known, and like ignorance exists as to its *innervation*.

The development of the hæmolymph nodes is probably much the same as that of the lymph nodes, except for the relation of the latter to the lymphatic vessels, the sinuses of the hæmolymph nodes being developed from blood-vessels.

TECHNIC

Same as for lymph nodes (technic 1, p. 176). The nodes are found in greatest numbers in the prevertebral tissue, and are often difficult to recognize. Fixing the tissues in 5-per-cent. formalin aids in their recognition as it darkens the nodes while bleaching the rest of the tissues.

The Thymus

The thymus is usually described as an organ of fœtal and early extra-uterine life; reaching in man its greatest development at the end of the second year, after this age undergoing slow retrograde

changes into fat and connective tissue, until by the twentieth year scarcely a vestige of glandular tissue remains. More recent investigations tend to indicate a continued but less active development of the thymus up to the age of twelve to fifteen, slow retrograde changes with probably lessened but continued function to about age fifty, then more rapid replacement by fat and connective tissue. The fully developed thymus presents the following structure. The entire gland is surrounded by a rather delicate and loose connective-tissue capsule which attaches it to the surrounding tissues. From

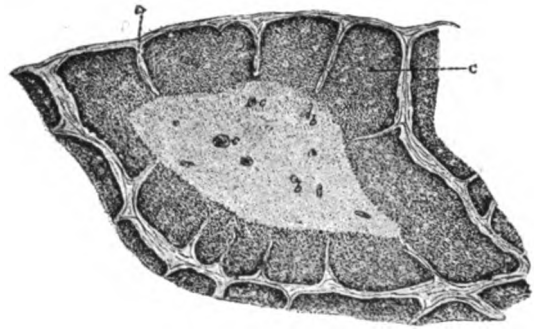

FIG. 105.—Section through lobule of child's Thymus. (Schafer.) One complete lobule is shown and edges of adjacent lobules. Between them is the interlobular connective tissue. The cortex (*c*) is seen composed of denser lymphoid tissue separated by trabeculæ (*tr*) into nodules (*c*); The central portion (medulla) of less dense lymphoid tissue, scattered through which are seen sections of blood vessels and of Hassall's corpuscles.

the capsule septa extend down into the organ. These branch and subdivide the gland into lobes and lobules.

From the perilobular connective tissue, septa extend into the lobule, incompletely separating it into a number of *chambers*. Each lobule consists of a *cortical portion* and a *medullary portion*. The cortex consists of ***nodules*** of compact lymphatic tissue, composed of reticular tissue and lymphoid cells, similar to those found in the lymph node. These occupy the chambers formed by the connective-tissue septa. The medulla consists of the same elements only more loosely arranged, the cells being much less closely packed, thus forming a more diffuse lymphatic tissue. There are also in the medulla no connective-tissue septa. In some lobules the more dense cortical substance completely encloses the medulla. It is common, however, for the medullary tissue to extend to the surface of a lobule at one or more points and to be there continuous with the medullary substance of an adjacent lobule. These interlobular connecting strands of medullary substance

are known as *medullary cords*. In the medulla are found a number of spherical or oval bodies composed of concentrically arranged epithelial cells. These are known as *Hassall's corpuscles* (Fig. 106), and represent the only remains of the original glandular epithelium. They are characteristic of the thymus. The central cells of the corpuscles are usually spherical and contain nuclei, while the peripheral cells are flat and non-nucleated. As the entire corpuscle takes a bright red stain with eosin-hæmatoxylin, the corpuscles stand out sharply from the surrounding bluish or pinkish lymphatic tissue. With low magnifications they are apt to be mistaken for blood-vessels.



FIG. 106.—Hassall's Corpuscle and Small Portion of Surrounding Tissue. ×600. (Technic page 182.)

Unlike the other lymphatic organs, the lymph nodules of the thymus contain no germinal centres. Mitosis can, however, usually be seen in the lymphoid cells. No definite lymph sinuses have been demonstrated. Nucleated red blood cells occur in the thymus, which must therefore be considered one of the sources of red blood cells as well as of lymphoid cells.

Blood-vessels.—The larger arteries run in the connective-tissue septa. From these, smaller intralobular branches are given off, which break up into capillary networks in the cortex and medulla. The capillaries pass over into veins. These converge to form larger veins, which accompany the arteries.

Of the **lymphatics** of the thymus little is known. They appear to originate in indefinite sinuses within the lymphoid tissue, whence they pass to the septa where they accompany the blood-vessels.

Nerves.—These are distributed mainly to the walls of the blood-vessels. A few fine fibres, terminating freely in the lymphatic tissue of the cortex and of the medulla, have been described.

The thymus originates in the entoderm in the region of the third branchial groove, first as two hollow evaginations of the endothelium of the pharyngeal cavity, which later become solid cords, and then separate entirely from the pharynx. The thymus thus begins its fœtal existence as a typical epithelial gland. Into this epithelial structure mesodermic cells grow and differentiate into *lymphatic tissue*. This almost completely replaces the epithelial tissue, only rudiments of which remain as Hassall's corpuscles.

Stöhr denies the mesodermic invasion of the thymus and consequently the lymphatic character of the gland. He considers the specific cells of the thymus as modified epithelial cells which have become "deceptively like lymphoid cells." This explanation has not, however, been generally accepted.

TECHNIC

Fix the thymus of a new-born infant in formalin-Müller's fluid (technic 6, p. 7), and harden in alcohol. Stain sections with hæmatoxylin-eosin (technic 1, p. 23), or with hæmatoxylin-picro-acid-fuchsin (technic 3, p. 24), and mount in balsam.

The Tonsils

The Palatine Tonsils or True Tonsils.—These are lymphatic organs, essentially similar in structure to those already described.

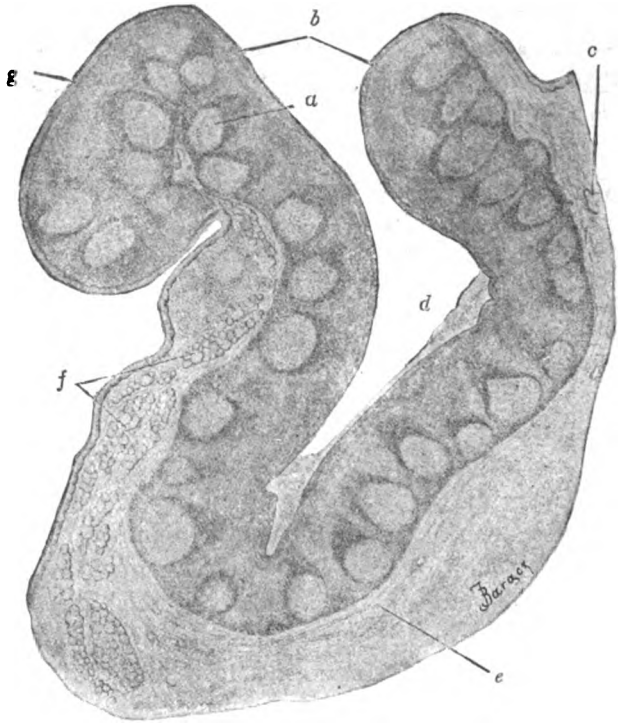

FIG 107.—Vertical Section of Dog's Tonsil through Crypt. ×15. (Szymonowicz.) *a*, Lymph nodule; *b*, epithelium of crypt; *c*, blood-vessel; *d*, crypt; *e*, connective-tissue capsule; *f*, mucous glands; *g*, epithelium of pharynx.

The usual fibrous *capsule* is present only over the attached surface, where it is firmly adherent on the one side to the tonsillar tissue and on the other to the surrounding structures from which it

separates the tonsils. From the capsule, connective-tissue *trabeculæ* extend into the substance of the organ and branch to form its framework. The free surface of the tonsil is covered by a reflection of the *stratified squamous epithelium* of the pharynx (Fig. 107). This epithelium presents the same structure as elsewhere in the pharynx, flat surface cells, beneath which are irregular cells, while the deepest cells are more or less distinctly columnar. The latter rest upon a papillated stroma from which they are separated by the *basement membrane*. At several places on the surface of the tonsil deep indentations or pockets occur. These are from ten to twenty in number, are known as the *crypts* of the tonsil (Fig. 107), and are lined throughout by a continua-

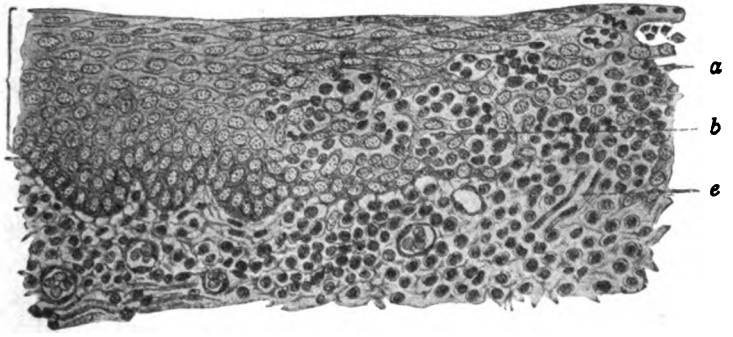

FIG. 108.—Vertical Section through Wall of Crypt in Dog's Tonsil, showing lymphoid infiltration of epithelium. ×150. (Böhm and von Davidoff.) *a*, Leucocytes in epithelium; *b*, space in epithelium filled with leucocytes and changed epithelial cells; *c*, blood-vessel; *d*, epithelium beyond area of infiltration; *e*, basal layer of cells.

tion of the surface epithelium which becomes thinner as the deeper part of the crypt is reached. Passing off from the bottoms and sides of the main or primary crypts are frequently several *secondary crypts*, also lined with the same type of epithelium.

The stroma consists of diffuse lymphatic tissue in which are found *nodules* of compact lymphatic tissue similar to those in the lymph node. Each nodule has a *germ centre*, where active mitosis is going on, and a surrounding zone of more densely packed cells. The nodules may have a fairly definite arrangement, forming a single layer beneath the epithelium of the crypts or may be arranged quite irregularly, several nodules uniting to form masses of dense lymphatic tissue. At various points on the surface of the tonsil, and especially in the crypts, occurs what is known as *lymphoid infiltration of the epithelium* (Fig. 108). This consists in an invasion of the epithelium by the underlying lymphoid cells. It varies from the presence of

only a few lymphoid cells scattered among the epithelium, to an almost complete replacement of epithelial by lymphoid tissue. In this way the latter reaches the surface and lymphoid cells are discharged upon the surface of the tonsil and into the crypts. These cells probably form the bulk of the so-called *salivary corpuscles*. In the connective tissue adjacent to the tonsil are numerous mucous glands, the ducts of which empty into the tonsillar crypts.

The Lingual Tonsils—Folliculi Linguales.—These are small lymphatic organs situated on the dorsum and sides of the back part of the tongue between the circumvallate papillæ and the epiglottis. They are similar in structure to the true tonsils. Each lingual tonsil has usually one rather wide-mouthed deep crypt (the *foramen cæcum linguæ*) which may be branched and which is lined with a continuation of the surface stratified squamous epithelium. Arranged around the crypt are the lymph nodules, each usually having a distinct germinal center and more or less sharply separated from the surrounding tissue by a fibrous capsule. In most crypts there is marked lymphoid infiltration of the epithelium with free "salivary corpuscles." Into these crypts frequently open the ducts of some of the mucous glands of the tongue.

The Pharyngeal Tonsils.—These are lymphatic structures which lie in the naso-pharynx. They resemble the lingual tonsils, except that they are, as a rule, not so sharply circumscribed. Hypertrophy of the pharyngeal tonsils, with consequent obstruction of the nasal openings, is common especially in children, constituting what are known as *adenoids*.

The **blood-vessels** have a distribution similar to those of the lymph nodes, but enter the organ along its entire attached side and not at a definite hilum.

Of the **lymphatics** of the tonsil little is known.

The **nerves** which are branches of the glosso-pharyngeal and of the spheno-palatine ganglion also enter the organ along its attached side.

The palatine tonsils make their first appearance during the third month of intra-uterine life as hollow evaginations of entoderm which grow down into the underlying mesenchyme, in the region of the second inner branchial groove. The earliest of the tonsillar lymphoid cells are apparently white blood cells which have migrated from the vessels of the stroma of the mucosa and have infiltrated the surrounding connective tissue. Further development of the tonsil is by proliferation of these cells. The crypts are at first solid ingrowths of surface epithelium. These later become hollowed out.

The lingual and pharyngeal tonsils begin their development during the later months of intra-uterine life. In the pharyngeal tonsils, definite nodules appear about the time of birth or during the first or second year. In the lingual tonsils the nodules are not fully formed until the fifth or sixth year.

TECHNIC

Normal human tonsils are so rare, owing to the frequency of inflammation of the organ, that it is best to make use of tonsils from one of the lower animals (dog, cat, or rabbit). Treat as in technic 1, p. 176, care being taken that sections pass ongitudinally through one of the crypts.

The Spleen

The spleen is a *lymphatic organ* and might be quite properly classed as a hæmolymph node. Its peculiar structure appears to depend largely upon the arrangement of its blood-vessels.

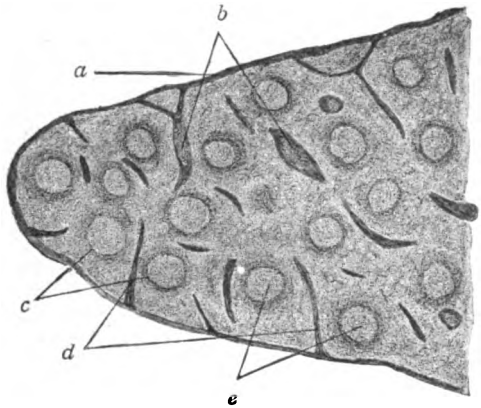

FIG. 109.—Section through Portion of Cat's Spleen, to show general topography. ×15. (Technic 1, p. 191.) *a*, Capsule; *b*, septa containing blood-vessels; *c*, center of lymph nodules; *d*, septa; *e*, germinal centres.

Except where attached, the spleen is covered by a serous membrane, the *peritoneum* (page 272). Beneath this is a *capsule* of fibrous tissue containing numerous elastic fibres and some smooth muscle cells. Along the broad attached surface this capsular connective tissue blends with the connective tissue of the posterior abdominal wall. From the capsule strong connective-tissue *septa*, similar to the capsule in structure, extend into the interior of the organ. These branch and unite with one another to form very incomplete anastomosing chambers. At one point on the surface of the spleen known as the hilum a deep indentation occurs. This marks the entrance

and exit of the large splenic vessels. Accompanying the vessels broad strands of capsular tissue extend deep into the organ where they radiate and subdivide, to form with smaller trabeculæ which extend in from other parts of the capsule, the *connective-tissue framework* of the organ (Fig. 109).

The chambers incompletely bounded by the connective-tissue septa are filled in with tissue resembling lymphatic tissue, composed of reticular connective tissue, lymphoid cells, and other varieties of cells described on p. 188. This tissue constitutes the *substantia propria* of the organ and is everywhere traversed by thin-walled vascular channels, the tissue and vascular channels together con-

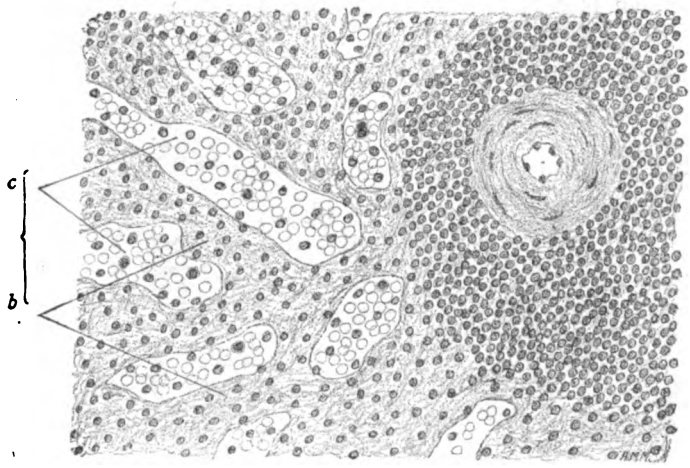

FIG. 110.—Section of Human Spleen, including portion of Malpighian body with its artery and adjacent splenic pulp. ×300. (Technic 2, p. 191.) *a*, Malpighian body; *b*, pulp cords, *c*, cavernous veins; *b* and *c* together constituting the splenic pulp.

stituting the *splenic pulp* (Fig. 110). Compact lymphatic tissue occurs in the spleen as spherical, oval, or cylindrical aggregations of closely packed lymphoid cells. These are known as *Malpighian bodies* or *splenic corpuscles* (Figs. 109 and 110) and are distributed throughout the splenic pulp. Each splenic corpuscle contains one or more small arteries. These usually run near the periphery of the corpuscle; more rarely they lie at the centre. Except for its relation to the blood-vessels, the splenic corpuscle is quite similar in a structure to the lymph nodule. It consists of lymphoid cells so closely packed as completely to obscure the underlying reticulum. In a child's spleen the centre of each corpuscle shows a distinct *germinal*

centre (see page 173). In the adult human spleen germ centres are rarely seen. The blood-vessels of the spleen have a very characteristic arrangement, which must be described before considering further the minute structure of the organ.

The *arteries* enter the spleen at the hilum and divide, the branches following the connective-tissue septa. The arteries are at first accompanied by branches of the *splenic veins*. Soon, however, the arteries leave the veins and the septa, and pursue an entirely separate

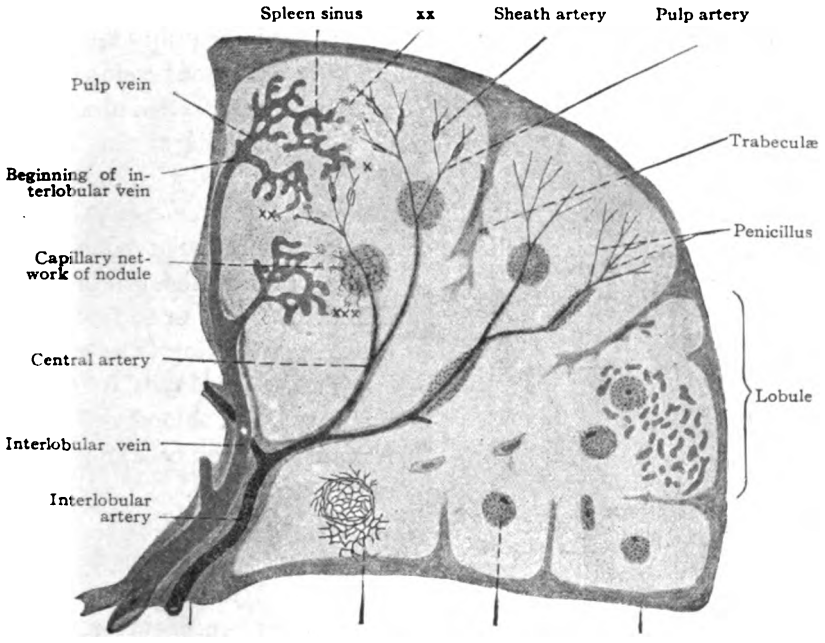

FIG. 111.—Scheme of Human Spleen. *x*, Opening of arterial capillaries into spleen sinus; *xx*, interruption of closed blood course at ends of arterial capillaries, at margin of nodule, *xxx*. For sake of clearness, sinus is placed too far from margin of nodule. (Stöhr.)

course through the splenic pulp. Here the adventitia of the smaller arteries assumes the character of reticular tissue and becomes infiltrated with lymphoid cells. In certain animals, as *e.g.*, the guinea-pig, this infiltration is continuous, forming long cord-like masses of compact lymphoid tissue. In man, the adventitia is infiltrated only at points along the course of an artery. This may take the form of elongated collections of lymphoid cells—the so-called *spindles*—or of distinct lymph nodules, the already mentioned *splenic corpuscles*. Although usually eccentrically situated with reference to the nodules,

these arteries are known as *central arteries*. They give rise to a few capillaries in the spindles, to a larger number in the nodules. Beyond the latter the arteries divide into thick sheathed terminal arteries—*pulp arteries*—which do not anastomose, but lie close together like the bristles of a brush or *penicillus*. The pulp arteries break up into unusually thick walled arterial capillaries which still retain an adventitia, the so-called *sheathed arteries*. These are of remarkably uniform diameter—6–8 cc—and empty into broader spaces from 10 to 40μ in diameter—the *spleen sinuses* or *ampullæ*—which in turn empty in to the *cavernous veins* of the splenic pulp (Fig. 110).

THE SPLENIC PULP.—The anastomosing cavernous veins break up the diffuse lymphatic tissue of the spleen into a series of anastomosing cords similar to those found in the medulla of the lymph node. These are known as *pulp cords* (Fig. 110), and with the cavernous veins constitute, as already mentioned, the *splenic pulp*. The pulp cords consist of a delicate framework of reticular connective tissue, in the meshes of which are found, in addition to lymphoid cells, the following (Fig. 112):

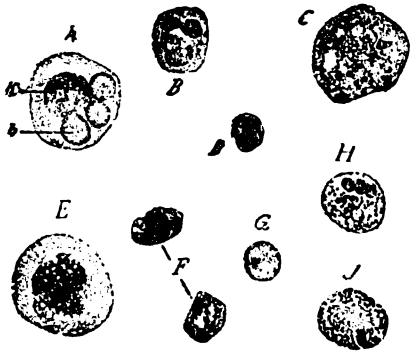

FIG. 112.—Isolated Spleen Cells. ×700. (Kölliker.) *A*, Cell containing red blood cells; *b*, blood cell; *k*, nucleus; *B*, leucocyte with polymorphous nucleus; *C*, "spleen" cell with pigment granules; *D*, lymphocyte; *E*, large cell with lobulated nucleus (megalocyte); *F*, nucleated red blood cells; *G*, red blood cell; *H*, multinuclear leucocyte; *J*, cell containing eosinophile granules.

(1) *Red blood cells*, including nucleated red blood cells and fragments of red cells in process of disintegration.

(2) *White blood cells.*

(3) *Mononuclear cells*, the so-called *spleen cells*. These are rather large, granular, spherical, or irregular cells. From the fact that blood pigment and red blood cells in various stages of disintegration are found in their cytoplasm, these cells are believed to be concerned in the destruction of red blood cells.

(4) *Multinuclear cells*. These are most common in young animals. Each cell contains a single large lobulated nucleus, or more frequently several nuclei. These cells resemble the osteoclasts of developing bone and the multinuclear cells of bone-marrow.

In macerated splenic tissue or in smears from the spleen, there are found, in addition to the above varieties of cells, long spindle-

shaped cells with bulging nuclei. These come from the walls of the cavernous veins.

Two views have been held regarding the vascular channels of the pulp. According to one, these channels have complete walls, the blood-vessel system of the splenic pulp being a *closed system* as in other organs. According to the other, the cavernous veins or spleen sinuses into which the arterial capillaries open, have fenestrated walls—*open system*. These fenestra are of sufficient size

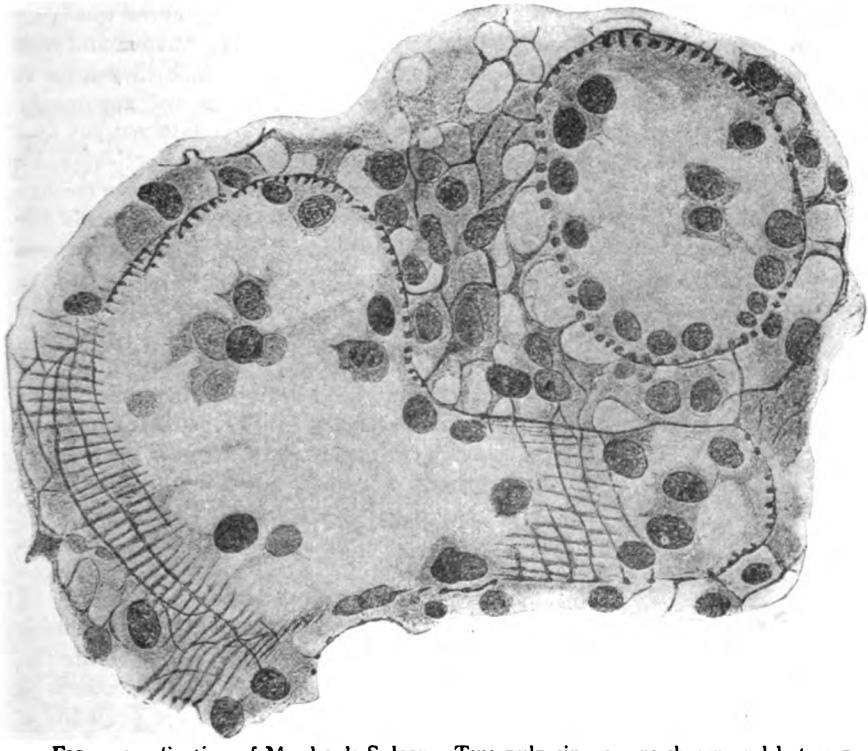

FIG. 113.—Section of Monkey's Spleen. Two pulp sinuses are shown and between them some of the reticular tissue of the pulp. The sinus in the upper right corner is cut transversely so that the longitudinal fibres of its wall are cut across and appear as a row of dots. The prominent dark nuclei belong to the endothelium. The other sinus is cut obliquely and a branch from it is seen partly in longitudinal section. It shows well the disposition of both longitudinal and circular fibres. (Mollier.)

to allow fluid and formed elements of the blood to pass out freely into the pulp cords and elements of the pulp cords to pass freely into the vessels. From these open-walled sinuses the veins proper take origin. The smaller veins, even those within the trabeculæ, have only endothelial walls. These uniting, form veins which enter the septa and ultimately converge to form the splenic veins which leave the organ at the hilum.

Mollier[1] describes the walls of the spleen pulp sinuses as having the following

[1] Arch. f. mikr. Anat., Bd. lxxvi, 1910–11.

structure. (1) A protoplasmic endothelial syncytium, with scattered oval nuclei (their long diameter lying in the long diameter of the vessel) and no evidence of cell boundaries. This syncytium is arranged as a network, the meshes of which are sometimes quite irregular, at other times quite regular and rectangular, with the long diameter of the mesh running in the long diameter of the vessel. This protoplasmic syncytium lines the sinus. (2) Outside the endothelial syncytium are closely-placed longitudinal fibres which lie upon the lengthwise-running strands of the protoplasmic reticulum (Fig. 113). (3) Outside the lengthwise-running strands transverse fibres or ring fibres which at rather longer intervals encircle the tube (Fig. 114). Both longitudinal and ring fibres are connective tissue (reticular), and the reticulum which they form is everywhere continuous with the reticulum of the pulp cords and apparently identical with it, except that to form walls, the reticulum is flattened out and usually has a more regular arrangement. The strands of the fibre reticulum lie upon the strands of the protoplasmic reticulum in such a way that the meshes correspond. A thin structureless fenestrated membrane lying just outside the endothelial syncytium has been described. The sinus walls probably possess a certain elasticity or contractility and undoubtedly change their diameter to accord with varying functional conditions. It follows that the meshes of the reticulum may be at one time widely open (congested spleen), at another partly open, at still another entirely closed. On the other hand the already noted (p. 188) remarkably uniform diameter of the sheathed arteries probably tends to prevent any sudden flooding of the sinuses and parenchyma.



FIG. 114.—Diagram of a Sinus of the Splenic Pulp, showing Relations of Longitudinal Fibres, Circular Fibres and Endothelial Nuclei. (Mollier.)

The main functions of the adult spleen in health appear to be the production of leucocytes and the destruction of red blood cells. It is possible that to a limited degree the spleen produces red blood cells. During fœtal life the spleen is actively engaged in the development of both red and white cells. Also in adult life a severe secondary anæmia or a pernicious anæmia may stimulate the spleen to resume production of red and white cells. The spleen can be removed without apparently seriously interfering with the body functions. Enlargement of lymph nodes and increased blood-forming activity of bone marrow as a result, have been described.

The ultimate origin of the spleen in man has not been definitely determined. The anlage of the spleen can be seen in embryos of five weeks as a thickening of the mesenchyme in the left dorsal mesogastrium and it was believed that the organ developed wholly from this mesenchyme. The mesothelium covering the thickened mesenchyme also shows thickening, and

demarcation between the two layers becomes almost entirely lost. Recent investigations have made it seem probable that the spleen develops in part at least from these mesothelial cells which grow down into the mesenchyme. In this case it is probable that mesenchyme gives rise to capsule, trabeculæ, and reticular connective tissue—the connective-tissue framework of the organ—while mesothelium is responsible for some at least of the various cellular elements of the splenic pulp.

Lymphatics are not numerous. In certain of the lower animals large lymph vessels occur in the capsule and septa. These are not well developed in man. Lymph vessels are present in the connective tissue of the hilum. They probably do not occur in the splenic pulp or in the splenic corpuscles.

Nerves.—These are mainly non-medullated, although a few medullated fibres are present. Among the latter are dendrites of sensory neurones whose cell bodies are situated in the spinal ganglia. They supply the connective tissue of the capsule, septa, and blood-vessels. The non-medullated fibres—axones of sympathetic neurones—accompany the arteries, around which they form plexuses. From these plexuses terminals pass to the muscle cells of the arteries, to the septa, to the capsule, and possibly also to the splenic pulp. The exact manner in which both medullated and non-medullated fibres terminate is as yet undetermined.

TECHNIC

(1) The spleen of a cat is more satisfactory for topography than the human spleen, as it is smaller, contains more connective tissue and its Malpighian bodies are more evenly distributed and more circumscribed. Fix in formalin-Müller's fluid (technic 6, p. 7), and harden in alcohol. Cut sections through the entire spleen. Stain with hæmatoxylin-eosin (technic 1, p. 23), or with hæmatoxylin-picro-acid-fuchsin (technic 3, p. 24).

(2) Human Spleen.—Small pieces are treated as in technic (1).

(3) Human Spleen (Congested).—Congested human spleens are usually easy to obtain from autopsies. Treat as in technic (1). The cavernous veins being distended with blood, the relations of the veins to the pulp cords are more easily seen than in the uncongested spleen. The contrasts are especially sharp in sections stained with hæmatoxylin-picro-acid-fuchsin.

(4) The cells of the spleen may be studied along the torn edges or in the thinner parts of any of the spleen sections. Or a smear may be made in a manner similar to that described in technic (page 114), by drawing the end of a slide across a freshly cut spleen surface and then smearing the tissue thus obtained across the surface of a second slide. Dry, fix in equal parts alcohol and ether (one-half hour), stain with hæmatoxylin-eosin and mount in balsam. Or the cut surface of the spleen may be scraped with a knife, the scrapings trans-

ferred to Zenker's fluid, hardened in alcohol, stained with alum-carmine (page 22 and technic 2, page 63) and mounted in eosin-glycerin.

General References for Further Study

Kölliker: Handbuch der Gewebelehre des Menschen, vol. iii.

Szymonowicz and MacCallum: Histology and Microscopic Anatomy.

Warthin: Hæmolymph Glands (with bibliography). Reference Handbook of the Medical Sciences, vol. iv.

Mall: Lobule of the Spleen. Bul. Johns Hopkins Hospital, vol. ix.—Architecture and Blood-vessels of the Dog's Spleen. Zeit. f. Morph. u. Anth., Bd. ii.

Oppel: Ueber Gitterfasern der menschlichen Leber und Milz. Anat. Anz., 6 Jahrg., S. 165.

CHAPTER XIII

THE SKELETAL SYSTEM

THE skeletal system consists of a series of bones and cartilages which are united by special structures to form the supporting framework of the body. Under this head are considered: (1) bones, (2) marrow, (3) cartilages, (4) articulations.

The Bones

A bone considered as an organ consists of bone tissue laid down in a definite and regular manner. If a longitudinal section be made through the head and shaft of a long bone, the head of the bone and also part of the shaft are seen to be composed of anastomosing bony

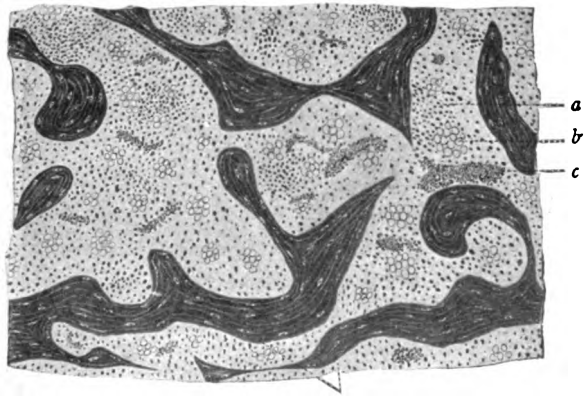

FIG. 115.—Section of Spongy Bone. ×75. (Technic 3, p. 202.) *a*, Marrow space; *b*, group of fat cells; *c*, blood-vessel; *d*, trabeculæ of bone

trabeculæ enclosing cavities. This is known as *cancellous* or *spongy bone.* The shaft of the bone consists of a large central cavity surrounded by spongy bone, which, however, passes over on its outer side into a layer of bone of great density and known as *hard* or *compact bone.* Spongy bone forms the ends and lines the marrow cavities of the long bones, and occurs also in the interior of short bones and flat

bones. Compact bone forms the bulk of the shafts of the long bones and the outer layers of the flat and the short bones.

In *compact bone* the layers or lamellæ of bone tissue have a definite arrangement into systems, the disposition of which is largely dependent upon the shape of the bone and upon the distribution of its blood-vessels.

In *spongy bone* (Fig. 115) there is no arrangement of the bone tissue into systems. The trabeculæ consist wholly of bony tissue laid down

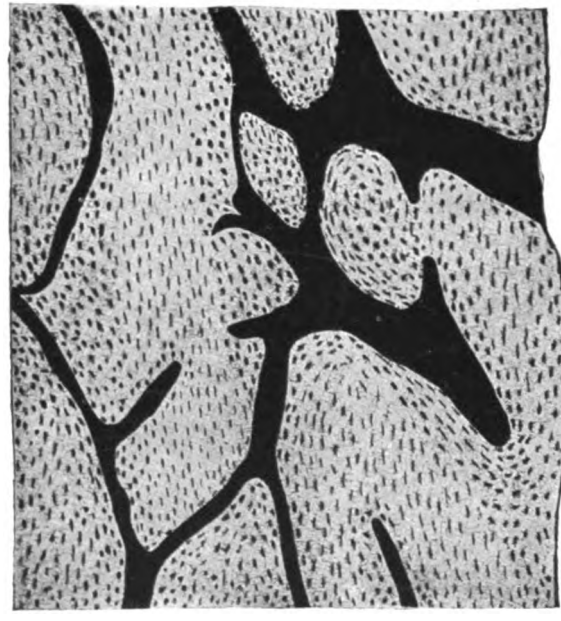

FIG. 116.—Longitudinal Section of Hard (Undecalcified) Bone: Shaft of Human Ulna. ×90. (Szymonowicz.) Haversian canals, lacunæ, and canaliculi in black.

in lamellæ. These trabeculæ anastomose and enclose spaces which contain marrow and which serve for the passage of blood-vessels lymphatics, and nerves.

On examining a longitudinal section of compact bone (Fig. 116) there are seen running through it irregular channels, the general direction of which is parallel to the long axis of the bone. These channels anastomose by means of lateral branches, and form a complete system of intercommunicating tubes. They are known as *Haversian canals*, contain marrow elements, and serve for the transmission of blood-vessels, lymphatics, and nerves. They anastomose not only with one another, but are in communication with the sur-

face of the bone and with the central marrow cavity. Between the Haversian canals most of the lamellæ run parallel to the canals.

In a cross section through the shaft of a long bone (Fig. 117), three distinct systems of lamellæ are seen. These are known as ***Haversian lamellæ***, ***interstitial lamellæ***, and ***circumferential lamellæ***.

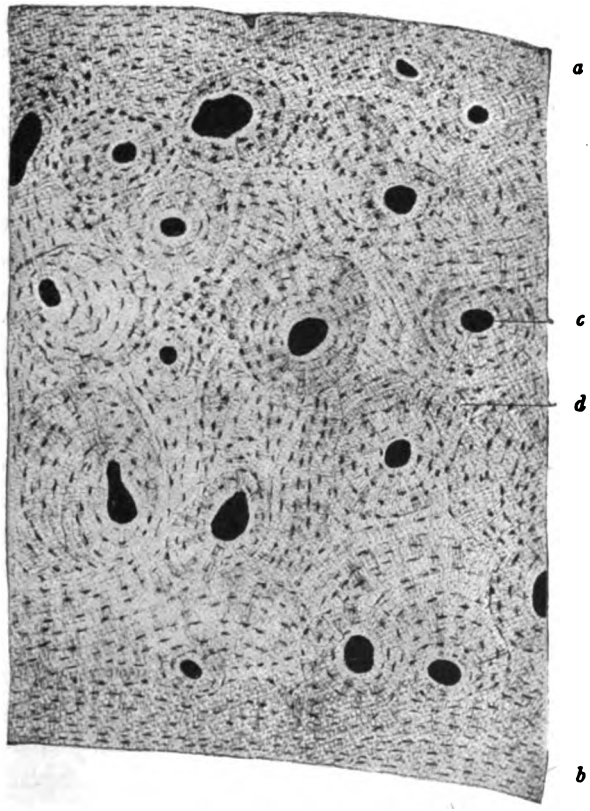

FIG. 117.—Cross-section of Hard (Undecalcified) Bone from Human Metatarsus. ×90. (Szymonowicz.) Haversian canals, lacunæ, and canaliculi in black. *a*, Outer circumferential lamellæ; *b*, inner circumferential lamellæ; *c*, Haversian lamellæ; *d*, interstitial lamellæ.

(1) HAVERSIAN LAMELLÆ (Fig. 118).—These are arranged in a concentric manner around the Haversian canals. Between the lamellæ, their long axes corresponding to the long axes of the Haversian canals, are the *lacunæ* with their inclosed *bone cells* (page 105). The lacunæ of adjacent lamellæ are usually arranged alternately. In a section of ordinary thickness the lacunæ are not nearly so numerous as the lamellæ, and are seen only between some of the lamellæ. The

lacunæ of a Haversian system communicate with one another and with their Haversian canal by means of the *canaliculi*. In Haversian systems the fibres of the matrix (see page 105) run in some lamellæ parallel to the canal, in others concentrically. Adjacent fibres thus frequently cross at right angles.

(2) INTERSTITIAL (INTERMEDIATE OR GROUND) LAMELLÆ (Figs. 117 and 118).—These are irregular short lamellæ, which occupy the spaces left between adjacent Haversian systems.

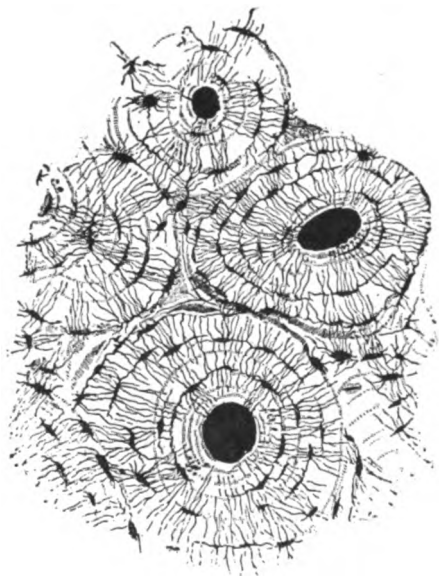

FIG. 118.—Transverse Section of Compact Bone from Shaft of Humerus. ×150 and slightly reduced. (Sharpey.) (Technic 1, p. 202.) Three Haversian canals with their concentric lamellæ and lacunæ; canaliculi connecting lacunæ with each other and with Haversian canal. Between the Haversian systems of lamellæ are seen the interstitial lamellæ.

(3) CIRCUMFERENTIAL LAMELLÆ (Fig. 117).—These are parallel lamellæ which run in the long axis of the bone, just beneath the periosteum and at the outer edge of the central marrow cavity. Occasionally circumferential lamellæ are absent, the Haversian systems abutting directly upon periosteum.

Channels for the passage of blood-vessels from the periosteum to the Haversian canals pierce the circumferential lamellæ. They are known as *Volkmann's canals*, and are not surrounded by concentric lamellæ as are the Haversian canals, but are mere channels through the bone. Similar canals pass from the inner Haversian canals into the marrow cavity.

The Periosteum.—This is a fibrous connective-tissue membrane which covers the surfaces of bones except where they articulate, and are covered with articular cartilage. It is firmly adherent to the superficial layers of the bone and consists of two layers. The outer layer is composed of coarse fibrillated fibres and contains the larger blood-vessels. The inner layer consists of fine white fibres and delicate elastic fibres which support the smaller blood-vessels. In growing bone a third layer, the osteogenetic layer, is present lying

next to the bone and consisting of loosely arranged connective tissue (areolar tissue) with numerous osteoblasts.

From the periosteum distinct bundles of white fibres, with often some elastic fibres, pierce the outer layers of the bone. These are known as the *perforating fibres of Sharpey*. When tendons and ligaments are attached to bone, their fibres are prolonged through the periosteum into the bone as *perforating fibres*.

The firmness of the adherance of periosteum to bone varies for different bones and for different parts of the same bone. In young growing bone the presence of an inner osteogenetic layer results in a rather loose attachment of periosteum. As bones grow older the periosteum becomes more and more firmly attached.

Bone Marrow

Bone marrow is a soft tissue which occupies the medullary and Haversian canals of the long bones and fills the spaces between the trabeculæ of spongy bone. It consists of a delicate reticular connective tissue, in the meshes of which lie various kinds of cells. In large marrow cavities there is a more or less definite arrangement of the reticular fibres to form a thin lining membrane known as the endosteum. Because of its function as a blood-forming organ it contains all varieties of blood cells as well as certain other cells. It is convenient to divide marrow cells primarily into (1) blood cells, adult and developmental forms, and (2) other cells.

- Marrow cells
  - Blood cells
    - White
      - Adult forms
        - Non-granular leucocytes
        - Granular leucocytes
      - Developmental forms—myelocytes
    - Red
      - Adult non-nucleated
      - Developmental forms
        - Primary erythroblasts
        - Secondary erythroblasts
  - Other cells
    - Giant cells
      - Megakaryocytes
      - Polykaryocytes
    - Fat cells
    - Plasma cells
    - Cells of the reticular tissue

The following description omits the adult forms of blood cells for which the student is referred to p. 107.

(1) *Myelocytes*.—These resemble the mononuclear and some of the transitional forms of leucocytes. The nucleus is large and may be lobulated. It contains a comparatively small amount of chromatin and therefore stains faintly. The cytoplasm is finely granular and stains with neutrophile dyes. Myelocytes are not present in normal

blood, but occur in large numbers in leukæmia. It is from the myelocytes that some and possibly all leucocytes, which are of bone-marrow origin, are derived.

(2) *Nucleated Red Blood Cells.*—These are divisible into *primary erythroblasts* and *secondary erythroblasts* or *normoblasts*. The former represents an earlier, the latter a later stage in the evolution of the non-nucleated adult red blood cell. The *primary erythroblast*, the younger of the two, has a wellformed nucleus with a distinct intranuclear network. The protoplasm contains but little hæmoglobin. In the *secondary erythroblast* the intranuclear network has disappeared and the protoplasm has become richer in hæmoglobin. The secondary erythroblast is converted into the adult red blood cell either by extrusion of its nucleus, or by the disintegration of the nucleus within the cell body. The number of erythroblasts present in a particular marrow is of course proportionate to the activity of red blood-cell formation.

(3) *Giant Cells.*—(a) Megakaryocytes. These are from 25–30μ in diameter and are distinctly amœboid. They have an abundant granular protoplasm which is usually acidophile, more rarely basophile. Peripherally the protoplasm is comparatively free from granules so that a clear exoplasm and a granular endoplasm may be distinguished. The nucleus varies greatly both in shape and size. It is usually single; may be spheroidal, but is more commonly lobulated with the lobules arranged in a circle or like the letter C. There are many nucleoli and centrosomes. The latter may be clumped or distributed through the protoplasm. When the nucleus is circular or C-shaped the centrosomes lie in the centre. Both mitosis and amitosis have been described in these cells. The origin and function of the megakaryocytes is unknown. Wright describes them (p. 114) as giving rise to the blood platelets, Stöhr as probably associated with the formation of leucocytes. They sometimes apparently entirely lose their protoplasm, thus giving rise to free giant nuclei.

(b) Polykaryocytes (myeloplaxes—osteoclasts). These are even larger than the megakaryocytes, having sometimes a diameter of 100μ. They are flat with a thickness of only 6–10μ and are rather scarce in adult bone. In developing bone they are numerous and lie near the bone or cartilage. Their protoplasm is granular and frequently contains fat droplets. They are multinuclear (5 to 40) and contain many centrosomes arranged in pairs, the number of pairs apparently corresponding to the number of nuclei. The nuclei may

be clumped near the centre of the cell or may be arranged in a ring or skein or irregularly. In development of bone these cells apparently have to do with its absorption. It is of interest to note that they are also found at the roots of milk teeth which are being absorbed, and Billroth describes them as apparently causing the absorption of ivory pegs which had been driven into bone.

Fat cells (p. 92), plasma cells (p. 89), mast cells (p. 89) and cells of the reticular connective tissue (p. 99) are found in marrow in varying numbers.

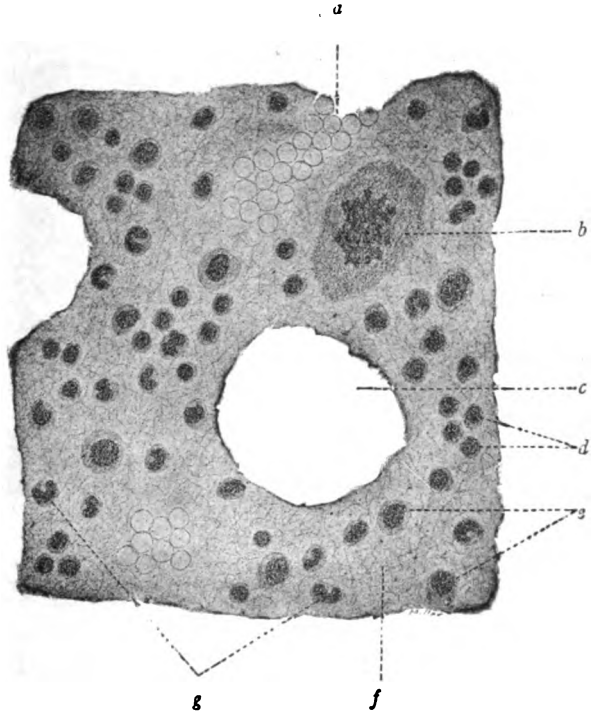

FIG. 119.—Section of Red Bone-marrow from Rabbit's Femur. ×700. (Technic 4, p. 202.) *a*, Red blood cells; *b*, myeloplax; *c*, fat space; *d*, nucleated red blood cells; *e*, myelocytes; *f*, reticular connective tissue; *g*, leucocytes.

While all marrow contains the elements described, their proportions vary greatly. Dependent upon the amount of fat present are distinguished two main varieties of marrow, red marrow and yellow marrow.

Red marrow is found in all bones of embryos and of young animals, also in the vertebræ, sternum, ribs, cranial bones, and epiphyses of long bones in the adult. In the diaphyses of adult long bones

the marrow is of the yellow variety. The difference in color between red marrow and yellow marrow is due to the much greater proportion of fat in the latter, yellow marrow being developed from the red by an almost complete replacement of its other elements by fat cells. The fatty changes which result in the transformation of red into yellow marrow begin in the later stages of bone development. They begin near the periphery and progress central-ward until

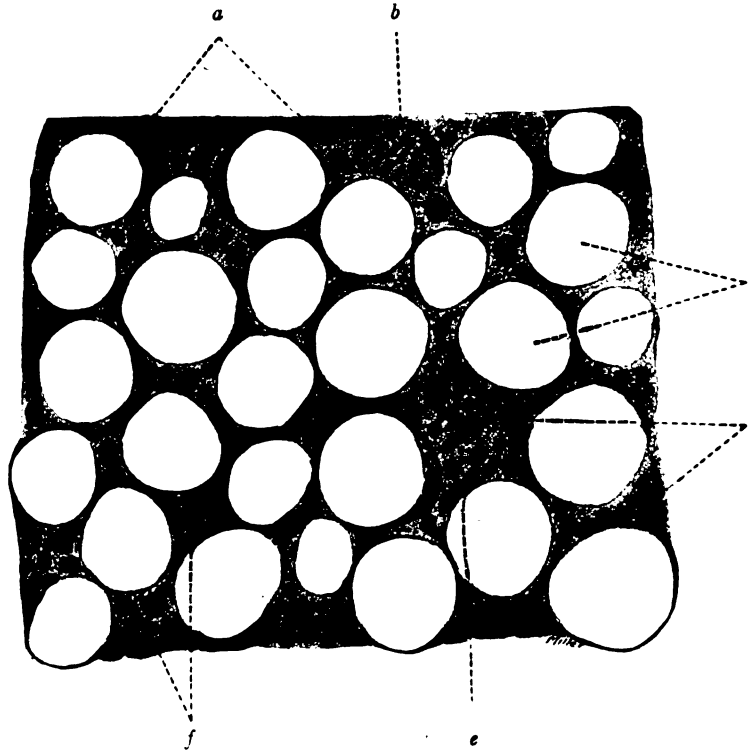

FIG. 120.—Yellow Marrow from Rabbit's Femur. ×560. (Technic 4, p. 202.) *a*, nucleated red blood cells; *b*, myeloplax; *c*, fat cells; *d*, myelocytes; *e*, reticular connective tissue; *f*, leucocytes.

finally all red marrow has been replaced by yellow. Exceptions are the heads (central ends) of the humerus and femur and the bones of the head and trunk where red marrow persists.

Red marrow is of especial interest as a blood-forming tissue, being in the healthy adult the main if not the sole source of red blood cells, and one of the sources from which the leucocytes are derived. (See also p. 113.) At the same time it is quite probable

that it functionates as a place where blood cells are destroyed. It is also active in the development of bone.

Yellow marrow (Fig. 120) consists almost wholly of fat cells, which have gradually replaced the other marrow elements. Under certain conditions the yellow marrow of the bones of the old or greatly emaciated undergoes changes due for the most part to the absorption of its fat. Such marrow becomes reddish and assumes a somewhat gelatinous appearance. It is known as "*gelatinous marrow.*" Under certain conditions, *e.g.*, fracture of shaft of long bone, yellow marrow may assume the character of red marrow and take an active part in the process of repair. It also serves as a storage place for fat.

The large marrow cavities, such as those of the shafts of the long bones, are lined by a layer of fibrous connective tissue, the *endosteum.*

Blood-vessels.—The blood-vessels of bone pass into it from the periosteum. Near the centre of the shaft of a long bone a canal passes obliquely through the compact bone. This is known as the *nutrient canal* and its external opening as the *nutrient foramen.* This canal serves for the passage of the nutrient vessels—usually one artery and two veins—to and from the medullary cavity. In its passage through the compact bone the nutrient artery gives off branches to, and the veins receive branches from, the vessels of the Haversian canals.

Each of the flat and of the short bones has one or more nutrient canals for the transmission of the nutrient vessels.

In addition to the nutrient canals the surface of the bone is everywhere pierced by the already mentioned (page 196) Volkmann's canals, which serve for the transmission of the smaller vessels. In compact bone these vessels give rise to a network of branches which run in the Haversian canals. In spongy bone the network lies in the marrow spaces. Branches from these vessels pass to the marrow cavity, and there break up into a capillary network, which anastomoses freely with the capillaries of the branches of the nutrient artery.

The *capillaries* of marrow empty into wide veins without valves, the walls of which consist of a single layer of endothelium. So thin are these walls that the veins of marrow were long described as passing over into open or incompletely walled spaces in which the blood came into direct contact with the marrow elements. These veins empty into larger veins, which are also valveless. Some of these converge to form the vein or veins which accompany the nutrient artery; others communicate with the veins of the Haversian canals.

Lymphatics with distinct walls are present in the outer layer of the periosteum. Cleft-like lymph capillaries lined with endothelium accompany the blood-vessels in Volkmann's and in the Haversian canals. The *lacunæ* and *canaliculi* constitute a complete system of lymph channels which communicate with the lymphatics of the periosteum, of Volkmann's and the Haversian canals, and of the bone-marrow.

Nerves.—Both medullated and non-medullated nerves accompany the vessels from the periosteum through Volkmann's canals, into the Haversian canals and marrow cavities. Pacinian bodies (page 439) occur in the periosteum. Of nerve endings in osseous tissue and in marrow little definite is known.

TECHNIC

(1) Decalcified Bone.—Fix a small piece of the shaft of one of the long bones —human or animal—in formalin-Müller's fluid (technic 6, p. 7) and decalcify in hydrochloric or nitric acid solution (page 10). After decalcifying, wash until all traces of acid are removed, in normal saline solution to which a little ammonia has been added. Dehydrate, and embed in celloidin. Transverse and longitudinal sections are made through the shaft, including periosteum and edge of marrow cavity. Stain with hæmatoxylin-eosin (technic 1, p. 23) and mount in eosin-gylcerin.

(2) Hard Bone.—Transverse and longitudinal sections of undecalcified bone may be prepared as in technic 1, p. 106.

(3) Spongy Bone.—This may be studied in the sections of decalcified bone, technic (1), where it is found near the marrow cavity. Or spongy bone from the head of one of the long bones or from the centre of a short bone may be prepared as in technic (2).

(4) Red Marrow.—Split longitudinally the femur of a child or young animal, and carefully remove the cylinder of marrow. Fix in formalin-Müller's fluid and harden in graded alcohols. Cut sections as thin as possible, stain with hæmatoxylin-eosin, and mount in balsam.

(5) Marrow: fresh specimen.—By means of forceps or a vice, squeeze out a drop of marrow from a young bone, place on the centre of a mounting slide, cover and examine it immediately.

(6) Place a similar drop of marrow on a cover-glass and cover with a second cover-glass. Press the covers gently together, slide apart and fix the specimen by immersion for five minutes in saturated aqueous solution of mercuric chlorid. Wash thoroughly, stain with hæmatoxylin-eosin, and mount in balsam.

Development of Bone

The forms of bones are first laid down either in *cartilage* or in *embryonic connective tissue*. The bones of the trunk, extremities, and parts of the bones

of the base of the skull develop in a matrix of cartilage. This is known as *intracartilaginous* or *endochondral ossification*. The flat bones, those of the vault of the cranium and most of the bones of the face, are developed in a matrix of fibrillar connective tissue—*intramembranous ossification*. A form of bone development, similar in character to intramembranous, occurs in connection with both intramembranous ossification and intracartilaginous ossification. This consists in the formation of bone just beneath the perichondrium—*subperichondrial ossification*—or, as with the development of bone perichondrium becomes periosteum—*subperiosteal ossification*.

There are thus three forms of bone development to be considered: (1) Intramembranous, (2) intracartilaginous, and (3) subperiosteal

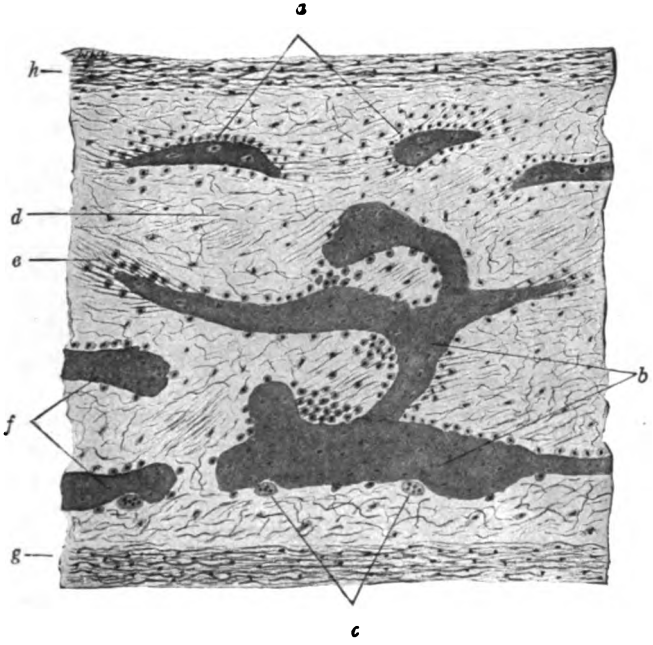

FIG. 121.—Intramembranous Bone Development. Vertical section through parietal bone of human fœtus. ×160. (Technic 1, p. 208.) *a*, Osteoblasts; *b*, bone trabeculæ; *c*, osteoclasts lying in Howship's lacunæ; *d*, internal periosteum; *e*, bone cells; *f*, calcified fibres; *g*, osteogenetic tissue; *h*, external periosteum (pericranium.)

1. **Intramembranous Development** (Fig. 121).—In intramembranous ossification the matrix in which the bone is developed is connective tissue. The process of bone formation begins at one or more points in this matrix. These are known as *ossification centres*. Here some of the bundles of white fibres become *calcified*, *i.e.*, become impregnated with lime salts. There is thus first established a *centre* or *centres of calcification*. Between the bundles of calcified fibres the connective tissue is rich in cells and vascular, and from its future rôle in bone formation is known as *osteogenetic tissue* (Fig. 121). Along the surfaces of the calcified fibres certain of the osteogenetic cells arrange themselves in a single layer (Figs. 121 and 122). These are now known as *osteoblasts* or "*bone*

formers." Under the influence of these osteoblasts a thin plate of bone is formed between themselves and the calcified fibres. This plate of bone at first contains no cells, but as the lamella of bone grows in thickness, the layer of osteoblasts becomes completely enclosed by bone. The osteoblasts are thus transformed into *bone cells* (Fig. 122), the spaces in which they lie becoming *bone lacunæ*. The bone cell is thus seen to be derived from the embryonic connective-tissue cell, the osteoblast being an intermediate stage in its development. In this way irregular anastomosing trabeculæ of bone are formed enclosing spaces (Fig. 121). The bony trabeculæ at first contain remains of calcified connective-tissue fibres, while the spaces, which are known as *primary marrow spaces*, contain blood-vessels, osteogenetic tissue, and developing marrow. The osteoblasts ultimately disappear and the spaces are then occupied by blood-vessels and marrow. The connective-tissue membrane has now been transformed into *cancellous* or *spongy bone* (Fig. 115).

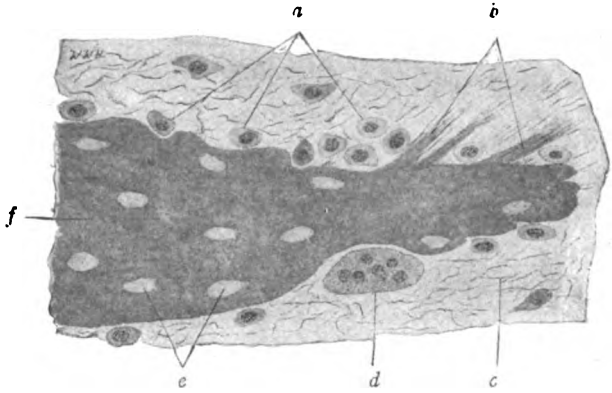

FIG. 122.—Intramembranous Bone Development. Vertical section through parietal bone of human fœtus. ×350. (Technic 1, p. 208.) *a*, Osteoblasts; *b*, calcified fibres; *c*, osteogenetic tissue; *d*, osteoclast lying in Howship's lacuna; *e*, bone lacunæ; *f*, bone.

The bone thus formed is covered on its outer surface by a layer of connective tissue, a part of the membrane in which the bone was formed, but which from its position is now known as the *periosteum*, or, in the case of the cranial bones, as the *peri-* or *epicranium* (Fig. 121).

In this form of bone development, occurring as it does in the bones of the skull, provision must be made for increase in the size of the cranial cavity to accommodate the growing brain. This is accomplished in the following manner: Along the surface of the bone, directed toward the brain, large multinuclear cells—*osteoclasts* or "*bone breakers*"—make their appearance (Fig. 122). The origin of these cells is not clear. Similar cells are conspicuous elements of adult, marrow. They have been variously described as derived from leucocytes from osteoblasts, or directly from the connective-tissue cells. A recent theory holds that they are derived by a process of budding from the endothelial cells, which form the walls of the capillaries. These osteoclasts apparently possess the power of breaking down bone. They are found mainly along its inner surface, and can be seen lying in little depressions—*Howship's lacunæ* (Fig. 122)—

which they have hollowed out in the bone. Between the outer surface of the bone and the pericranium is a layer of *osteogenetic tissue*, the innermost cells of which are arranged as *osteoblasts* along the outermost osseous lamellæ. Here they are constantly adding new bone beneath the pericranium. This new bone is laid down, not in flat, evenly disposed layers, but in the form of anastomosing trabeculæ enclosing marrow spaces.

It is thus seen that subperiosteal bone, like intramembranous, is at first of the spongy variety, and that with the development of the cranium the original intramembranous bone is entirely absorbed, together with much of the subperiosteal.

2. **Intracartilaginous Development.**—In this form of ossification an embryonal type of hyaline cartilage precedes the formation of bone, the cartilage corresponding more or less closely in shape to the future bone (Fig. 123). Covering the surface of the cartilage is a membrane of fibrillar connective tissue, the *perichondrium* or *primary periosteum*.

In most of the long bones the earliest changes take place within the cartilage at about the centre of the shaft (Fig. 123). Here the cartilage cells increase in size and in number in such a way that several enlarged cartilage cells come to lie in a single enlarged cell space, and the cartilage assumes the character of *hyaline cartilage*. The cell groups next arrange themselves in *rows* or *columns*, which at first extend outward in a radial manner from a common centre, but later lie in the long axis of the bone. During these changes in the cells there is an increase in the intercellular matrix and a deposit there of calcium salts. In this way the cartilage becomes calcified, the area involved being known as the *calcification centre*. Further growth of cartilage at the calcification centre now ceases and, as growth of cartilage at the ends of the bone continues, the central portion of the shaft appears constricted. The changes up to this point seem to be *preparatory* to actual bone formation.

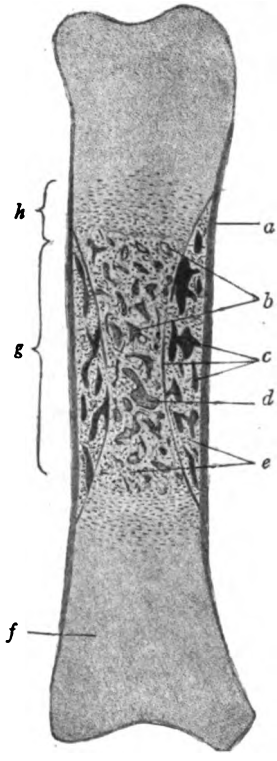

FIG. 123.—Intracartilaginous Bone Development. Longitudinal section of one of the bones of embryo sheep's foot, showing ossification centre. ×20. (Technic 2, p. 209.) *a*, Periosteum; *b*, blood-vessels; *c*, subperiosteal bone; *d*, intracartilaginous bone; *e*, osteogenetic tissue; *f*, cartilage; *g*, ossification centre; *h*, calcification zone.

Ossification proper begins by blood-vessels from the periosteum[1] pushing their way into the calcified cartilage at the calcification centre, carrying with them some of the osteogenetic tissue from beneath the periosteum. These blood-vessels with their accompanying osteogenetic tissue are known as *periosteal buds* (Fig. 124). Osteoblasts now develop from the osteogenetic tissue and appear to dissolve the calcified cartilage from in front of the advancing

[1] The term "periosteum" is admissible from the fact that the first bone actually formed is beneath the perichondrium, which thus becomes converted into periosteum

vessels. In this way the septa between the cartilage cell spaces are broken down, the cartilage cells disappear, and a central cavity is formed—the *primary marrow cavity*. From the region of the primary marrow cavity blood-vessels and osteogenetic tissue push in both directions toward the ends of the cartilage which is to be replaced by bone. These break down the transverse septa between the cell spaces, while many of the longitudinal septa at first remain to form the walls of long anastomosing channels, the *primary marrow spaces* (Fig. 125). As in intramembranous bone, these contain blood-vessels, embryonal

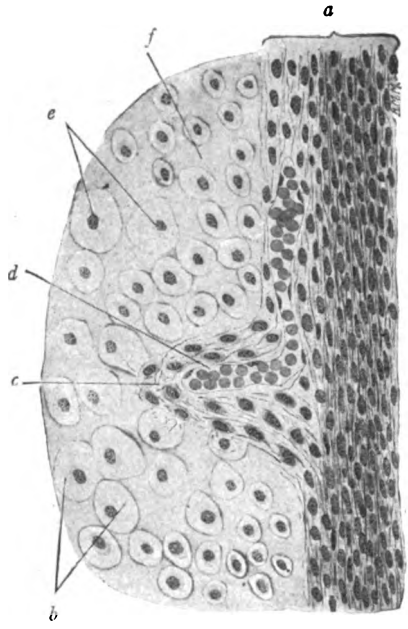

FIG. 124.

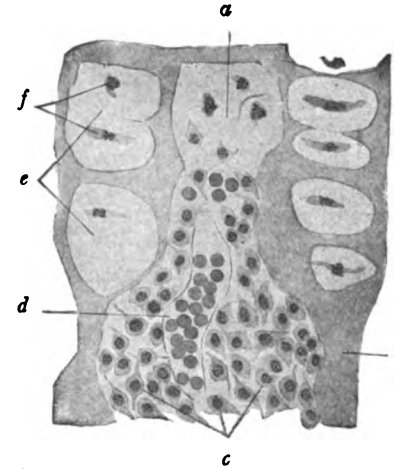

FIG. 125.

FIG. 124.—Intracartilaginous Bone Development. ×350. Showing osteogenetic tissue pushing its way into the cartilage (periosteal bud) at the ossification centre. *a*, Periosteum; *b*, cartilage cell spaces; *c*, periosteal bud; *d*, blood-vessel; *e*, cartilage cells; *f*, cartilage matrix.

FIG. 125.—Intracartilaginous Bone Development. Same specimen as Fig. 123 (×350), showing osteogenetic tissue pushing its way into the cartilage and breaking it up into trabeculæ; also formation of primary marrow spaces and disintegration of cartilage cells. *a* Disintegrating cartilage cells; *b*, cartilage trabecula; *c*, osteogenetic tissue in primary marrow space; *d*, blood-vessels; *e*, cell spaces; *f*, cartilage cells.

marrow, and osteoblasts, all of which are derived from the osteogenetic tissue brought in from the periosteum by the periosteal buds. The osteoblasts next arrange themselves in a single layer along the remains of the calcified cartilage, where they proceed to deposit a thin layer of bone between themselves and the cartilage (Fig. 126). As this increases in thickness some of the osteoblasts are enclosed within the newly formed bone to become *bone cells*, while the remains of the cartilage diminishes in amount and finally disappears. The *calcification centre* has now become the *ossification centre*, and

its anastomosing osseous trabeculæ, with their enclosed spaces containing osteogenetic tissue and marrow, constitute *primary spongy bone*.

At either end of the ossification centre the cartilage presents a special structure. Nearest the centre the cell spaces are enlarged, flattened, arranged in rows and contain shrunken cells. Some of the walls break down and irregular spaces are formed. The ground substance is calcified. Passing away from the ossification centre, the cell spaces become less flattened, still arranged in rows, the contained cells larger, and there is a lesser degree of calcification. This area passes over into an area of hyaline cartilage which blends without distinct demarcation with the ordinary embryonal cartilage of the rest of the shaft. The area of calcified cartilage at either end of the ossification centre is known as the *calcification zone* and everywhere precedes the formation of true bone (Fig. 123).

3. **Subperiosteal or subperichondrial development** (Fig. 123) has already been largely described in connection with intramembranous ossification, and

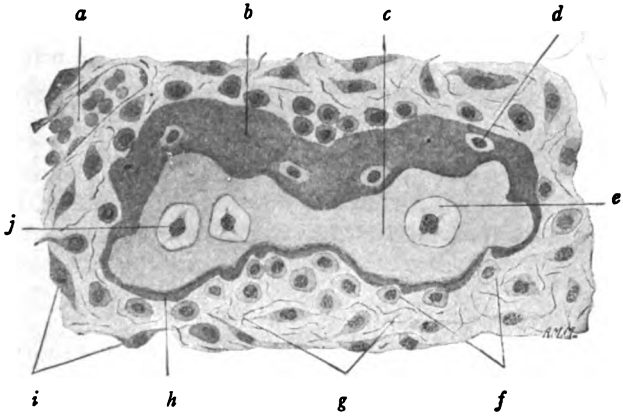

FIG. 126.—Intracartilaginous Bone Development. Same specimen as Fig. 123. (×350), showing bone being deposited around one of the trabeculæ of cartilage. *a*, Blood-vessel; *b*, bone; *c*, cartilage remains; *d*, bone cell; *e*, cartilage cell space; *f*, osteoblasts; *g*, osteogenetic tissue; *h*, lamella of bone; *i*, connective-tissue cells; *j*, cartilage cell.

differs in no important respect from the latter. It always accompanies one of the other forms of ossification. Bone appears beneath the perichondrium somewhat earlier than within the underlying cartilage. Beneath the perichondrium is a layer of richly cellular osteogenetic tissue. The cells of this tissue nearest the cartilage become osteoblasts and arrange themselves in a single layer along its surface. Under their influence bone is laid down on the surface of the cartilage in the same manner as in intramembranous ossification.

Intracartilaginous and subperiosteal bone can be easily differentiated by the presence of cartilaginous remains in the former and their absence in the latter.

All bone is at first of the spongy variety. When this is to be converted into compact bone, there is first absorption of bone by osteoclasts, with increase in size of the marrow spaces and reduction of their walls to thin plates. These spaces are now known as *Haversian spaces*.

Within these new bone is deposited. This is done by osteoblasts which lay

down layer within layer of bone until the Haversian space is reduced to a mere channel, the Haversian canal. In this way are formed the *Haversian canals* and the *Haversian systems of lamellæ*. Some of the interstitial lamellæ are the remains of the spongy bone which was not quite removed in the enlargement of the primary marrow spaces to form the Haversian spaces; other interstitial lamellæ appear to be early formed Haversian lamellæ which have been more or less replaced by Haversian lamellæ formed later.

While these varieties of ossification have been described, we would emphasize the *essential unity* of the process. The likeness between intramembranous and subperiosteal ossification has been already noted. The differences observed in intracartilaginous ossification are more apparent than real. In intracartilaginous ossification the bone is developed *in* cartilage but not *from* cartilage. As in intramembranous and in subperiosteal ossification, intracartilaginous bone is developed *from osteogenetic tissue*. This osteogenetic tissue is a differentiation of embryonal connective tissue, in this case *carried into* the cartilage from the periosteum in the *periosteal buds*. In intramembranous ossification the bone is developed *within* and *directly from* the embryonal connective tissue of which the membrane is composed. In intracartilaginous ossification there is the same embryonal connective-tissue membrane, but within this membrane the form of the bone is first laid down in embryonal cartilage. Surrounding the cartilage there remains the embryonal connective tissue of the membrane, now perichondrium. It is from tissue which *grows into the cartilage* from this membrane—*embryonal connective tissue*—that the bone, although developed *in* cartilage, is formed.

Marrow develops from the mesenchymal tissue which enters the cartilage anlage in the periosteal buds, at the beginning of ossification.

Growth of Bone

The growth of intramembranous bone by the formation of successive layers beneath the periosteum has been already described (page 204).

Intracartilaginous bones grow both in *diameter* and in *length*.

Growth in diameter is accomplished by the constant deposition of new layers of bone beneath the periosteum. During this process, absorption of bone from within by means of osteoclasts leads to the formation of the *marrow cavity*. The hard bone of the shaft of a long bone is *entirely* of *subperiosteal origin*, the intracartilaginous bone being completely absorbed.

Growth in length takes place in the following manner: Some time after the beginning of ossification in the shaft or diaphysis, independent ossification centres appear in the ends of the bone (epiphyses). So long as bone is growing, the epiphyses and diaphysis remain distinct. Between them lies a zone of growing cartilage, the *epiphyseal* or *intermediate cartilage*. Increase in length of the bone takes place by a constant extension of ossification into this cartilage from the ossification centres of the epiphyses and diaphysis. After the bone ceases to grow in length, the epiphyses and diaphysis become firmly united.

TECHNIC

(1) Developing Bone—Intramembranous.—Small pieces are removed from near the edge of the parietal bone of a new-born child or animal. These pieces

should include the entire thickness of bone with the attached scalp and dura mater. Treat as in technic 1, p. 202, except that the sections which are cut perpendicular to the surface of the bone should be stained with hæmatoxylin-picro-acid-fuchsin (technic 3, p. 24) and mounted in balsam.

(2) Developing Bone—Intracartilaginous and Subperiosteal.—Remove the forearms and legs of a human or animal embryo by cutting through the elbow, and knee-joints. (Fœtal pigs from five to six inches long are very satisfactory.) Treat as in technic (1). Block so that the two long bones will lie in such a plane that both will be cut at the same time. Cut thin longitudinal sections through the ossification centres, stain with hæmatoxylin-picro-acid-fuchsin, and mount in balsam. Cut away the ends of one or two of the embedded bones, leaving only the ossification centres. Block so as to cut transverse sections through the ossification centre. Stain and mount as the preceding.

In the picro-acid-fuchsin stained sections of developing bone the cartilage is stained blue; cells, including red blood cells, yellow; connective tissue from pale pink to red, according to density; bone a deep red.

The Cartilages

The *costal cartilages* are hyaline. They are covered by a closely adherent connective-tissue membrane, the perichondrium. Where cartilage joins bone there is a firm union between the two tissues and the perichondrium becomes continuous with the periosteum.

The *articular cartilages* are described below under articulations.

The *other skeletal cartilages*, such as those of the larynx, trachea, bronchi, and of the organs of special sense, are more conveniently considered with the organs in which they occur.

Articulations

Joints are *immovable* (synarthrosis) or *movable* (diarthrosis). In synarthrosis union may be cartilaginous (synchondrosis), or by means of fibrous connective tissue (syndesmosis).

SYNCHONDROSIS.—The cartilage is usually of the fibrous form except near the edge of the bone, where it is hyaline. The intervertebral discs consist of a ring of fibro-cartilage surrounding a central gelatinous substance, the nucleus pulposus, the latter representing the remains of the notochord.

SYNDESMOSIS.—Union is by means of ligaments. These may consist wholly of fibrous tissue, the fibres and cells being arranged much as in tendon, or mainly of coarse elastic fibres separated by loose fibrous tissue. In such syndesmoses as the sutures of the cranial bones, the union is by means of short fibrous ligaments between the adjacent serrated edges.

DIARTHROSIS.—In diarthrosis must be considered (*a*) the articular cartilages, (*b*) the glenoid ligaments and interarticular cartilages, (*c*) the joint capsule.

(*a*) *Articular cartilages* cover the ends of the bones. They are of the hyaline variety,[1] being the remains of the original cartilaginous matrix in which the bones are formed. Next to the bone is a narrow strip of cartilage in which the matrix is calcified. This is separated from the remaining uncalcified portion of the cartilage by a narrow so-called "striated" zone. The most superficial of the cartilage cells are arranged in rows parallel to the surface; in the mid-region the grouping of cells is largely in twos and fours as in ordinary hyaline cartilage (page 102); while in the deepest zone of the uncalcified cartilage the cells are arranged in rows perpendicular to the surface.

(*b*) The *glenoid ligaments* and interarticular cartilages conform more to the structure of dense fibrous tissue than to that of cartilage

(*c*) The *joint capsule* consists of two layers, an outer layer of dense fibrous tissue intimately blended with the ligamentous structures of the joint and known as the *stratum fibrosum*, and an inner layer, the *stratum synoviale* or *synovial membrane*, which forms the lining of the joint cavity. The outer part of the stratum synoviale consists of areolar tissue with its loosely arranged white and elastic fibres interlacing in all directions, and scattered connective-tissue cells and fat cells. Nearer the free surface of the membrane the fibres run parallel to the surface and the cellular elements are more abundant. The cells are scattered among the fibres and are stellate branching cells like those usually found in fibrous connective tissue. On the free surface, however, the cells lie close together, in places forming a single surface layer, in other places being disposed in three or four layers. Formerly described as endothelium, they are now generally considered connective-tissue cells or "mesenchymal epithelium."

From the free surfaces of synovial membranes, processes (*synovial villi—Haversian fringes*) project into the joint cavity. Some of these are non-vascular and consist mainly of stellate cells similar to those of the synovial membrane. Others have a distinct core of fibrous tissue containing blood-vessels and covered with stellate con-

[1] In the acromio-clavicular, sterno-clavicular, costo-vertebral, and maxillary articulations the cartilage is of the fibrous form. The same is true of the cartilage covering the head of the ulna, while the surface of the radius, which enters into the wrist-joint, is covered not by cartilage, but by dense fibrous tissue.

nective-tissue cells. From the primary villi small secondary non-vascular villi are frequently given off.

The larger blood-vessels of the joint capsule lie in the outer layer of the stratum synoviale whence smaller vessels and capillaries pass to the inner layer and to some of the villi. The inner layer is richly, the outer layer more poorly supplied with lymph capillaries. Non-medullated nerve fibres are found in the connective tissue, some of them ending in end-bulbs or Pacinian corpuscles (p. 444).

TECHNIC

(1) Joint Capsule and Articular Cartilage.—Remove one of the small joints —human or animal—cutting the bones through about one-half inch back from the joint. Treat as in technic 1, p. 202, making longitudinal sections through the entire joint.

(2) Synovial Villi.—Remove a piece of the capsular ligament from near the border of the patella and cut out a bit of the velvety tissue which lines its inner surface. Examine fresh in a drop of normal salt solution. Fix a second piece of the ligament in formalin-Müller's fluid (technic 6, p. 7), make sections perpendicular to the surface, stain with hæmatoxylin-eosin (technic 1, p. 23), and mount in balsam.

General References for Further Study

Braunca: Précis d'Histologie.

Kölliker: Handbuch der Gewebelehre, vol. i.

Stöhr: Text-book of Histology.

Schäfer: Histology and Microscopical Anatomy, in Quain's Elements of Anatomy.

CHAPTER XIV

THE MUSCULAR SYSTEM[1]

THE voluntary muscular system consists of a number of organs—*the muscles*—and of certain accessory structures—the *tendons*, *tendon sheaths*, and *bursæ*.

A VOLUNTARY MUSCLE consists of striated muscle fibres arranged in bundles or fascicles and supported by connective tissue.

The entire muscle is enclosed by a rather firm connective-tissue sheath or *capsule*—the *epimysium* (Fig. 127). This sends trabeculæ

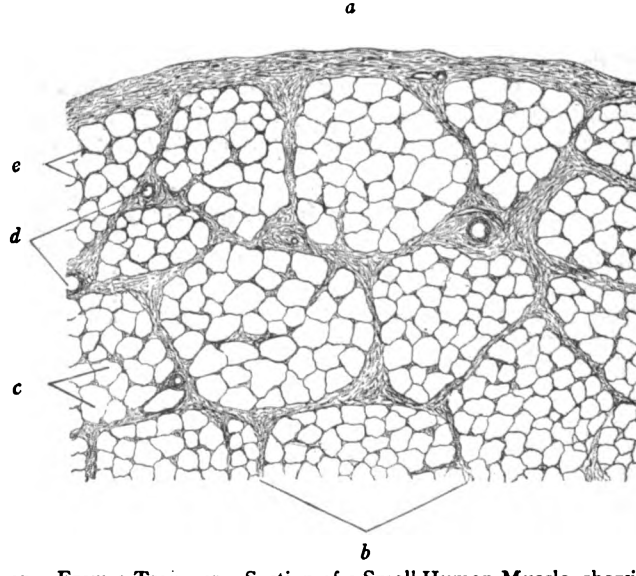

FIG. 127.—From a Transverse Section of a Small Human Muscle, showing relations of muscle fibres to connective tissue. *a*, Epimysium; *b*, perimysium; *c*, muscle fibres; *d*, arteries; *e*, endomysium.

of more loosely arranged connective tissue into the substance of the muscle. These divide the muscle fibres into bundles or *fascicles*. Around each fascicle the connective tissue forms a more or less definite

[1] Definite arrangements of smooth muscle, such as are found in the stomach and intestines, also the muscle of the heart, are properly a part of the muscular system. They are, however, best considered under tissues and in connection with the organs in which they occur.

envelope, the *perifascicular sheath* or *perimysium*. From the latter delicate strands of connective tissue pass into the fascicles between the individual muscle fibres. This constitutes the *intrafascicular connective tissue* or *endomysium*, which everywhere completely separates the fibres from one another so that the sarcolemma of one fibre never comes in contact with the sarcolemma of any other fibre. It should be noted that these terms indicate merely location; epi-, peri-, and endo-mysium, all being connective tissue grading from coarse to fine, as it passes from without inward. The structure of the muscle as an organ is thus seen to conform to the structure of other organs, in that it is surrounded by a connective-tissue capsule, which sends septa into the organ, dividing it into a number of compartments and serving for the support of the essential tissue of the organ, the muscle fibres or parenchyma.

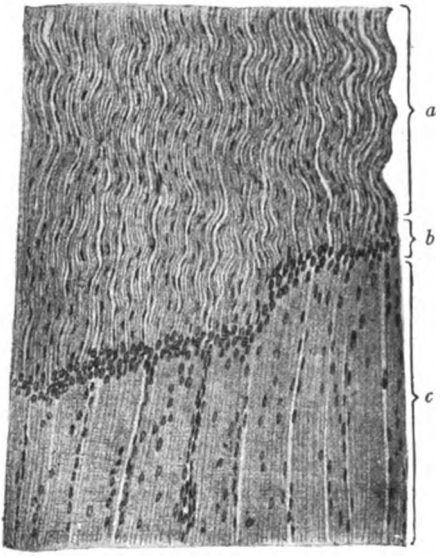

FIG. 128.—From a Longitudinal Section through Junction of Muscle and Tendon. ×150. (Böhm and Davidoff.) *a*, Tendon; *b*, line of union showing increase in number of muscle nuclei; *c*, muscle.

The structure of *tendon* has been described (see page 95).

Tendon sheaths and bursæ are similar in structure, consisting of mixed white and elastic fibres. Their free surfaces are usually lined by flattened connective tissue-cells.

At the junction of muscle and tendon, the muscle fibre with its sarcolemma ends in a rounded or blunt extremity (Fig. 65*A*, p. 123*a*). Here the fibrils of the tendon fibres are in part cemented to the sarcolemma, and in part are continuous with the fibres of the endo- and peri-mysium. This has been for a long time the accepted idea of the transition from muscle to tendon, and is perhaps more nearly correct where the insertion is oblique. It has been more recently proved, however, that for some muscles at least, and especially where muscle and tendon join end to end a much more intimate union of elements occurs. This is shown in Figs. 129 and 130 from Stöhr.

In Fig. 129 the individual muscle fibrillæ are seen passing over into tendon fibrillæ with no line of demarcation. In Fig. 130 a similar continuity is shown except that groups of muscle fibrillæ are seen to be continuous with groups of tendon fibrillæ. Both sarcoplasm, which appears somewhat augmented at this point, and sarcolemmæ, extend between the tendon bundles beyond the line of cross muscle striations. Along the line of union of muscle and tendon the muscle nuclei are more numerous than elsewhere (Fig. 128, *b*), and it has been suggested that there is here a zone of indifferent or formative

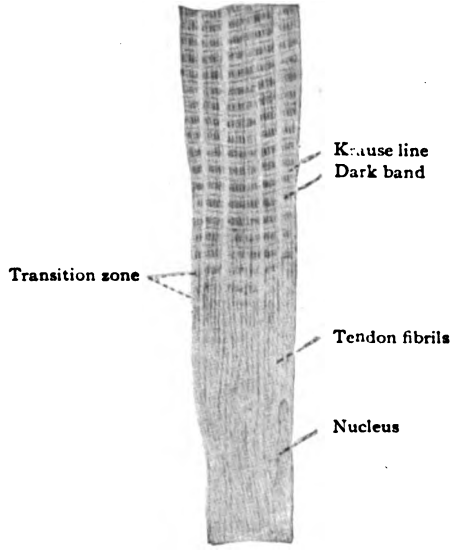

FIG. 129.—Longitudinal Section through Muscle-tendon Junction. Human Intercostal. ×750. Only part of a fibre is shown, without sarcolemma. (Stöhr.)

tissue which is capable of developing on the one hand into muscle, on the other into the connective tissue of tendon. (See also p. 123.)

GROWTH OF MUSCLE takes place mainly at the ends of the fibres where the nuclei are most numerous. In addition to the growth incident to increase in size of the individual or of the particular muscle, there is a constant wearing out of muscle fibres and their replacement by new fibres. This is accomplished as follows: The muscle fibre first breaks up into a number of segments (sarcostyles), some of which contain nuclei while others are non-nucleated. The sarcostyles next divide into smaller fragments, and finally completely disintegrate. This is followed by a process of absorption and complete disappearance of the fibre. From the free sarcoplasm new

muscle fibres are formed. In the early stages of their development these are known as myoblasts. The latter develop into muscle fibres in the same manner as described under the histogenesis of muscle (p. 126).

Blood-vessels.—The larger arteries of muscle run in the perimysium, their general direction being parallel to the muscle bundles. From these, small branches are given off at right angles. These in

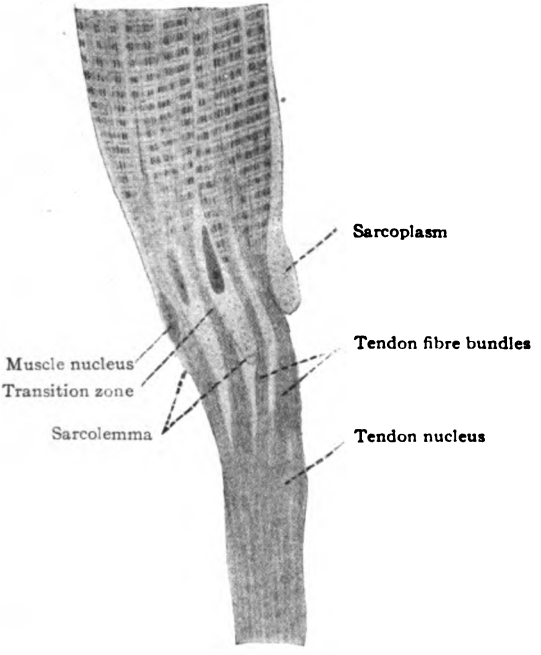

FIG. 130.—Junction of Muscle and Tendon showing Continuity of Fibrils and Extension of Sarcolemma beyond the Limits of Cross Striations. Rectus abdominis of frog. ×750. (Stöhr.)

turn give rise to an anastomosing capillary network with elongated meshes, which surrounds the individual muscle fibres on all sides. From these capillaries, veins arise which follow the arteries. Even the smallest branches of these veins are supplied with valves.

In tendons blood-vessels are few. They run mainly in the connective tissue which surrounds the fibre bundles. Tendon sheaths and bursæ, on the other hand, are well supplied with blood-vessels.

The **lymphatics** of muscle are not numerous. They accompany the blood-vessels. In tendon definite lymph vessels are found only on the surface.

Nerves.—The terminations of nerves in muscle and tendon are described under nerve endings (page 447).

TECHNIC

(1) A Muscle.—Select a small muscle, human or animal, and, attaching a weight to the lower end to keep it stretched, fix in formalin-Müller's fluid (technic 6, p. 7), and harden in alcohol. Stain transverse sections with hæmatoxylin-picro-acid-fuchsin (technic 3, p. 24) and mount in balsam.

(2) Junction of Muscle and Tendon.—Any muscle-tendon junction may be selected. Fix in formalin-Müller's fluid, keeping stretched by means of a weight attached to the lower end. Cut longitudinal sections through the muscle-tendon junction, stain with hæmatoxylin-picro-acid-fuchsin, and mount in balsam. The gastrocnemius of a frog is convenient on account of its small size, and because by bending the knee over and tying there, the muscle can be easily put on the stretch and kept in that condition during fixation. Place the entire preparation in the fixative removing the muscle-tendon from the bone after fixation.

CHAPTER XV

GLANDS

General Structure and Classification

ATTENTION was called in describing the functional activities of cells (page 52) to the fact that certain cells possess the power of not only carrying on the nutritive functions necessary to maintain their own existence, but also of elaborating certain products either necessary for the general body functions (secretions) or for the body to eliminate as waste (excretions). Such cells are known as *gland cells* or *glandular epithelium*, and an aggregation of these cells to form a definite structure for the purpose of carrying on secretion or excretion is known as a *gland*.

A gland may consist of a single cell, as, *e.g.*, the mucous or goblet cell on the free surface of a mucous membrane, or the unicellular glands of invertebrates. Such a cell undergoes certain changes which result in the production within itself of a substance which is to be used outside the cell. The appearance which this cell presents depends upon the stage of secretion. It is thus possible to differentiate between a "resting" and an "active" cell or between an "empty" and a "loaded" cell. The mucous secreting cell of the intestine is one of the simple columnar cells which constitute the epithelium of the mucous membrane. It is distinguishable as a mucous or goblet cell only after secretion begins. The resting cell is granular and takes a rather dark cytoplasmic stain. As the cell becomes active, part of the cytoplasm is transformed into, or is replaced by, a clear substance which does not stain like cytoplasm, but reacts to hæmatoxylin. The mucus collects first in the free end of the cell, and gradually increases in amount until the entire cell is filled, with the exception of a small area at the base, where a little unchanged protoplasm surrounds a flattened nucleus. The cell at this stage is much larger than in the resting state, and finally ruptures on the free surface and pours out its secretion. Opinions differ as to the further behavior of this cell. According to some, its life history is now ended, and its place is taken by other cells which pass through the same process. Others

believe that in most cases the cell is reconstructed from the nucleus and unchanged cytoplasm, and again passes through the process of secretion. In stratified epithelium secretion may begin while the cell is still deeply situated, but is completed only as the cell reaches the surface, where its mucus is to be discharged.

In describing the vital properties of cells (p. 51) attention was called to the fact that all cells take up from the surrounding blood and lymph substances required for their own nutrition, and give off waste products (excretions). In such sense all cells secrete and excrete. What distinguishes the gland cell is that in addition to carrying on its own metabolism (p. 51) it manufactures a specific substance not for its own use but to be extruded from the cell, and used elsewhere in the body (secretion, *e.g.*, gastric juice), or discarded (excretion, *e.g.*, urine). Such a cell takes up from blood or lymph the substances required, more or less completely assimilates them, and finally transforms them into its specific secretion.

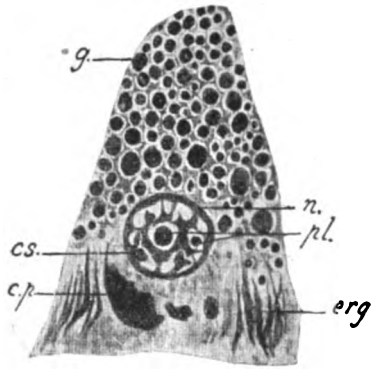

FIG. 131.—Gland Cell from Pancreas of Salamander; *n*, Nucleus; *cs*, caryosomes; *pl*, plasmosomes; *cp*, paranucleus; *erg*, ergastoplasm filaments; *g*, secretory granules. ×500. (Prenant.)

Certain changes, other than those described as seen in the mucous secreting cell, may occur in the protoplasm of actively secreting gland cells. In many cells there appears at the onset of secretion a modification of the cytoplasm which has been designated *ergastoplasm*[1] (Fig. 131). In some cells the ergastoplasm takes the form of slender threads near the base of the cell, *basal filaments*, in others of minute rods. Other forms have been described as mitochondria, cytosomes, pseudochromosomes, etc.

Many gland cells have intracellular secretory canals (see p. 47).

In some gland cells a body known as the *paranucleus* appears at the beginning of secretion. It is a rather large, usually irregular mass, differing in staining qualities from the nucleus and probably being of the same nature as, or closely allied to the ergastoplasm. Its relation to either of these structures, to the cytoplasm, or to the secretion is not known.

The function of the nucleus in secretion is apparently of great importance.

[1] A multiplicity of terms has arisen (ergastoplasm, basal filaments, kinoplasm, paraneucleus, protoplasma superieur, etc.) to designate substances which appear under varying conditions in many types of cells. These substances differ in appearance in different cells, which accounts for the various terms applied to them. They differ from the ordinary protoplasm of the cell both in appearance and in their reactions to stains. They are most in evidence when the activities of the cells are at their maximum. They are all specializations of the cytoplasm; products elaborated within the cell in the performance of its special functions. (See also Mitochondria, p. 47.)

Non-nucleated portions of cells are probably not able to elaborate any true secretion. When (see below) the entire cell enters the secretion as in the mammary gland, the entire nucleus of course becomes a part of the secretion. In any event, the onset of secretion is apt to be evidenced in the nucleus by enlargement and irregularity, in some cases by the giving off of nuclear material to the cytoplasm, in others by amitotic division. According to some observers, both ergastoplasm and paranucleus are of nuclear origin.

In connection with the mucous cell (p. 217) it was noted that according to some authorities the cell dies in secreting, while others believe that the cell reconstructs itself and can again secrete. In certain glands, *e.g.*, the mammary and sebaceous, the cast off cells themselves form the secretion. More commonly the cell merely gives off its secretion, the remainder of the cell recovering and again going through the same process.

Most glands are composed of more than one cell, usually of a large number of cells, and these cells, instead of lying directly upon the surface, line more or less extensive invaginations into which they pour their secretions.

In the simplest form of glandular invagination all the cells lining the lumen are secreting cells. In more highly developed glands only the deeper cells secrete, the remainder of the gland serving merely to carry the secretion to the surface. This latter part is then known as the *excretory duct*, in contradistinction to the deeper *secreting portion*. In both the duct portion and secreting portion of a gland the epithelium usually rests upon a more or less definite *basement membrane* or *membrana propria* (page 73). Beneath the basement membrane, separating and supporting the glandular elements, is the connective tissue of the gland. This varies greatly in structure and quantity in different glands.

When the secreting portion of the gland is a tubule, the lumen of which is of fairly uniform diameter, the gland is known as a *tubular gland*. When the lumen of the secreting portion is dilated in the form of a *sac* or *alveolus*, the gland is known as a *saccular* or *alveolar gland*. Intermediate forms have been described as tubulo-alveolar glands.

A gland may consist of a single tubule or saccule, or of a single system of ducts leading to terminal tubules or saccules—*simple gland*. A gland may consist of a number of more or less elaborate duct systems with their terminal tubules or saccules—*compound gland*. A few glands, *e.g.*, the thyreoid and thymus, have no ducts, and are known as *ductless glands*.

All compound glands are surrounded by connective tissue which

forms a more or less definite *capsule*. From the capsule connective-tissue *septa* or *trabeculæ* extend into the gland. The broadest septa usually divide the gland into a number of macroscopic compartments or *lobes*. Smaller septa from the capsule and from the interlobar septa divide the lobes into smaller compartments usually microscopic in size—the *lobules*. A lobule is not only a definite portion of the gland separated from the rest of the gland by connective tissue, but represents a definite grouping of tubules or alveoli with reference to one or more terminal ducts. The glandular (epithelial) tissue is known as the *parenchyma* of the gland, in contradistinction to the connective or *interstitial* tissue.

The relations of the glandular tissue proper to the connective tissue are best understood by reference to development. All glands, simple and compound, originate as simple evaginations from a surface lined with epithelium. The epithelial evagination grows down into the underlying connective tissue. In a compound gland this invagination tubule becomes the main excretory duct. As the tubule grows, it divides and subdivides to form the larger and smaller ducts and finally the secreting tubules or alveoli. During the development of the gland tubules, the connective tissue is also developing, but is being largely replaced by the more rapidly growing tubules. The gland tubules do not develop irregularly, but in definite groups, each group being dependent upon the tubule (duct) from which it originates. Thus the invagination tubule (main excretory duct) gives rise to a few large branches (lobar ducts), each one of which gives off the subdivisions which constitute a lobe. From each lobar duct there arise within the lobe a large number of smaller branches (lobular ducts) each one of which gives rise to the subdivisions included in a lobule. As the lobe groups and lobule groups of tubules develop, the largest strands of connective tissue are left between adjacent lobes (interlobar connective tissue), smaller strands between lobules (interlobular connective tissue), and the finest connective tissue between the tubules or alveoli within the lobule (intralobular connective tissue).

Glands may thus be classified as follows:

A. Duct glands or glands of external secretion.
   1. Tubular glands.
      (*a*) Simple tubular { straight. / coiled. / branched.
      (*b*) Compound tubular.
   2. Alveolar or saccular glands.
      (*a*) Simple alveolar.
      (*b*) Compound alveolar, saccular or racemose.

B. Ductless glands or glands of internal secretion.

Duct Glands

1. **Tubular Glands.**—(*a*) SIMPLE TUBULAR GLANDS are simple tubules which open on the surface, their lining epithelium being continuous with the surface epithelium. All the cells may be secreting cells or only the more deeply situated. In the latter case the upper portion of the tubule serves merely as a duct. In the more highly developed of the simple tubular glands we distinguish a ***mouth***, opening upon the surface, a ***neck***, usually somewhat constricted, and a ***fundus***, or deep secreting portion of the gland.

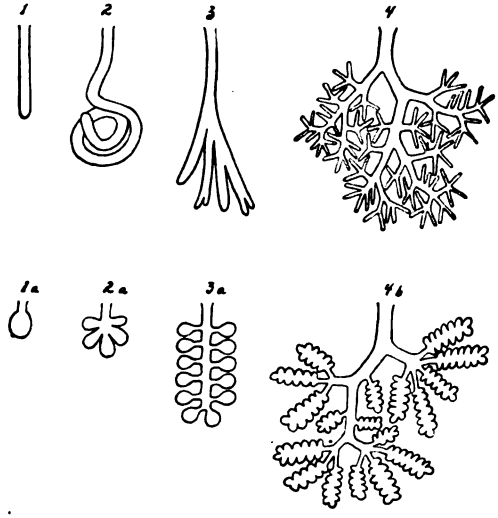

FIG. 132.—Diagram Illustrating Different Forms of Glands. 1, simple tubular gland; 2, coiled simple tubular gland; 3, branched simple tubular gland; 4, compound tubular gland; 1*a*, 2*a*, and 3*a*, simple alveolar glands; 4*a*, compound alveolar gland. For description of 1*a*, 2*a*, and 3*a*, see simple alveolar glands in text.

Simple tubular glands are divided according to the behavior of the fundus, into (1) straight, (2) coiled, and (3) branched.

(1) *A straight tubular gland* is one in which the entire tubule runs a straight unbranched course, *e.g.*, the glands of the large intestine (Fig. 132, 1).

(2) *A coiled tubular gland* is one in which the deeper portion of the tubule is coiled or convoluted, *e.g.*, the sudoriferous glands of the skin (Fig. 132, 2).

(3) *A forked or branched tubular gland* is a simple tubular gland in which the deeper portion of the tubule branches, the several

branches being lined with secreting cells and opening into a superficial portion, which serves as a duct. Examples of slightly forked glands are seen in the cardiac end of the stomach, and in the uterus. Other tubular glands show much more extensive branching, the main duct giving rise to a number of secondary ducts, from which are given off the terminal tubules. The mucous glands of the mouth, œsophagus, trachea, and bronchi are examples of these more elaborate simple tubular glands (Fig. 132, 3).

(*b*) COMPOUND TUBULAR GLANDS consist of a number, often of a large number, of distinct *duct systems*. These open into a common or *main excretory duct*. The smaller ducts end in terminal tubules. Many of the largest glands of the body are of this type, *e.g.*, the salivary glands, liver, kidney, and testis (Fig. 132, 4).

In certain compound tubular glands, as, *e.g.*, the liver, extensive anastomoses of the terminal tubules occur. These are sometimes called *reticular glands*.

2. **Alveolar Glands.**—(*a*) SIMPLE ALVEOLAR GLANDS.—The simplest form of alveolar gland consists of a *single sac* connected with the surface by a constricted portion, the *neck*, the whole being shaped like a flask (Fig. 132, 1 *a*). Such glands are found in the skin of certain amphibians; they do not occur in man. Simple alveolar glands, in which there are several saccules (Fig. 132, 2 *a*), are represented by the smaller sebaceous glands. *Simple branched alveolar glands*, in which a common duct gives rise to a number of saccules (Fig. 132, 3 *a*), are seen in the larger sebaceous glands, and in the Meibomian glands.

(*b*) COMPOUND ALVEOLAR GLANDS.—These resemble the compound tubular glands in general structure, consisting of a large number of *duct systems*, all emptying into a *common excretory duct*. The main duct of each system repeatedly branches, and the small terminal ducts, instead of ending in tubules of uniform lumen, as in a tubular gland, end in sac-like dilatations, the *alveoli* or *acini* (Fig. 132, 4 *a*). The best example of a compound alveolar gland is the mammary gland, although the lung is constructed on the principle of a compound alveolar gland.

Ductless Glands

Certain structures remain to be considered which are properly classified as glands, but in which during development the excretory duct has disappeared. Such glands are known as *ductless glands*.

The ovary is a ductless gland, the specific secretion of which, the ovum, is under normal conditions taken up by the oviduct and carried to the uterus. This is known as a *dehiscent gland.*

Other ductless glands, such as the thyreoid, hypophysis and adrenal, are known as glands of *internal secretion*, their specific secretions passing directly into the blood or lymph systems.

A few glands, *e.g.*, the liver and pancreas, have both an internal secretion, and an external secretion.

General Structure of Mucous Membranes

The alimentary tract, the respiratory tubules, parts of the genito-urinary system, and some of the organs of special sense are lined by *mucous membranes.* While differing as to details in different organs, the general structure of all mucous membranes is similar. The essential parts are (1) surface epithelium, (2) basement membrane, and (3) stroma or tunica propria. The *epithelium* may be simple columnar, as in the gastro-intestinal canal; ciliated, as in the bronchi; stratified squamous, as in the œsophagus, etc. The epithelium rests upon a *basement membrane* or *membrana propria* which, like the same membrane in glands, is described by some as a product of the epithelium, by others as a modification of the underlying connective tissue. Beneath the basement membrane is a connective-tissue *stroma*, or *tunica propria.* This usually consists of loosely arranged fibrous tissue with some elastic fibres. It may contain smooth muscle cells and lymphoid tissue.

In addition to the three layers above described there is frequently a fourth layer between the stroma and the underlying connective tissue. This consists of one or more layers of smooth muscle, and is known as the *muscularis mucosæ.*

A mucous membrane usually rests upon a layer of connective tissue rich in blood-vessels, lymphatics, and nerves—the *submucosa.*

CHAPTER XVI

THE DIGESTIVE SYSTEM

THE *digestive system* consists of the alimentary tract and certain associated structures such as glands, teeth, etc.

The *alimentary tract* is a tube extending from lips to anus. Different parts of the tube present modifications both as to calibre and as to structure of wall.

The embryological subdivision of the canal into headgut, foregut, midgut, and endgut admits of further subdivision upon an anatomical basis as follows:

I.	Headgut:	(*a*) Mouth, including the tongue and teeth.
		(*b*) Pharynx.
II.	Foregut:	(*a*) Œsophagus.
		(*b*) Stomach.
III.	Midgut:	Small intestine.
IV.	Endgut:	(*a*) Large intestine.
		(*b*) Rectum.

The entire canal is lined by *mucous membrane*, the modifications of which constitute the most essential difference in structure of its several subdivisions.

Beneath the mucosa is usually more or less connective tissue, which in a large portion of the canal forms a definite *submucosa*.

Muscular tissue is present beneath the submucosa throughout the greater part of the canal. In most regions it forms a definite, continuous, muscular tunic.

The upper and lower ends of the tube—mouth, pharynx, œsophagus, and rectum—are quite firmly attached by fibrous tisue to the surrounding structures. The remainder of the tube is less firmly attached, lying coiled in the abdominal cavity, its surface covered, except along its attached border, by a serous membrane, the visceral peritoneum.

I. THE HEADGUT

The Mouth

THE MUCOUS MEMBRANE OF THE MOUTH.—This consists of stratified squamous epithelium lying upon a connective-tissue stroma or tunica propria. The latter is thrown up into *papillæ*, which do not, however, appear upon the free surface of the epithelium. The submucosa is a firm connective-tissue layer with few elastic fibres. The thickness of the epithelium, the character of the stroma, and the height of the papillæ vary in different parts of the mouth. There is no muscularis mucosæ.

At the junction of the skin and mucous membrane (red margin of the lips) the epithelial layer is much thickened, the stroma is thinned, and the papillæ are very high. At this point the stratum corneum of the skin passes over into the softer nucleated epithelium of the mouth, while the stratum lucidum and stratum granulosum of the skin terminate (see skin, page 389).

The mucous membrane of the gums has prominent, long, slender papillæ, the summits of which are covered by a very thin layer of epithelium. This nearness of the vascular stroma to the surface accounts for the ease with which the gums bleed. That portion of the gums which extends over the teeth is devoid of papillæ. The submucosa of the gums is firmly attached to the underlying periosteum.

The mucous membrane lining the cheeks has low, small papillæ, and the submucosa is closely adherent to the muscular fibres of the buccinator.

Covering the hard palate, the mucous membrane is thin and the short papillæ are obliquely placed, their apices being directed anteriorly. The submucosa is firmly attached to the periosteum.

Over the soft palate the papillæ of the mucous membrane are low or even absent. They are somewhat higher on the uvula, the posterior surface of which shows a transitional condition of its epithelium, areas of stratified squamous alternating with areas of stratified columnar ciliated epithelium. Throughout the mucous membrane of the soft palate, uvula, and fauces, the stroma and submucosa contain diffuse lymphatic tissue. In some places the lymphoid cells are so closely placed as to form distinct nodules.

GLANDS OF THE ORAL MUCOSA.[1]—Distributed throughout the

[1] For description of the larger salivary glands see page 281.

oral mucosa are small branched tubular glands. Only in those parts of the mucous membrane which are closely attached to underlying bone, as on the gums and hard palate, are mucous glands few or entirely absent. While the deeper portions of the glands are in the submucosa, some of the tubules usually lie in the stroma of the mucous membrane.

The *ducts* open upon the surface and are lined with a continuation of the surface stratified squamous epithelium as far as the first bifurcation. Here the epithelium becomes stratified columnar, and this, as the smaller branches are approached, passes over into the simple columnar type. Not infrequently ducts of small secondary glands empty into the main duct during its passage through the mucosa.

According to the character of their secretions, the oral glands are divided into:

(*a*) Mucous glands, which secrete a mucin-containing fluid (mucus);

(*b*) Serous glands, which secrete a serous (albuminous) fluid;

(*c*) Mixed glands, the secretion of which is partly mucous and partly serous.

Morphologically, also, a similar distinction can be made in regard to the glandular epithelium which lines the terminal tubules, the tubules of mucous glands being lined with "mucous" cells, those of serous glands with "serous cells," while of the mixed glands the cells of some tubules are mucous, of others serous. In certain tubules both mucous and serous cells occur. The appearance which these cells present depends largely upon their secretory condition at the time of death.

Serous cells when resting have a slightly granular protoplasm, which in the fresh condition is highly refractive, giving the cells a transparent appearance. With the beginning of secretion the granules increase in number and the cells become darker. Stained with hæmatoxylin-eosin, serous tubules have a purple or red color. The nuclei are spherical or oval, and are situated between the centre and base of the cell (Fig. 185, p. 284).

Mucous cells are in the quiescent state rather small cuboidal or pyramidal cells, with cloudy cytoplasm and nuclei situated at the base of the cell. When active the mucous cells are much larger, with clear cytoplasm and with nuclei flattened against the basement membrane. The protoplasm of the fresh unstained mucous cell is less highly refractive than that of the serous cell. It consequently

appears darker and less transparent. Mucous tubules are larger and more irregular in shape than serous tubules, and when stained with hæmatoxylin-eosin either remain almost wholly unstained or take a pale blue hæmatoxylin stain (Fig. 185, p. 284). Many mucous tubules have, in addition to the mucous cells ,a peculiar, often crescentic-shaped group of cells on one side of the tubule, between the mucous cells and the basement membrane. These cells are granular and stain very much like serous cells with hæmatoxylin-eosin, thus resembling the latter in appearance. On account of the shape of the groups, they are known as the *crescents* of *Gianuzzi* or *demilunes* of *Heidenhain* (Fig. 185, p. 284). The cells of the crescents are connected with the lumen by means of *secretory canals*, which pass between the mucous cells and end in branches within the protoplasm of the crescent cells. It is quite possible that some of the crescents are not serous cells but mucous cells in the non-active condition which have been pushed away from the lumen by the more active cells. Such cell groups are not connected with the lumen of the gland by intercellular secretory canals.

Peculiar irregular branching cells have been described, extending from the basement membrane in between the mucous cells. They are known as "basket" cells and are supposed to be supportive in character.

The cells of both mucous and serous tubules rest upon a membrana propria, outside of which, separating the tubules, is a cellular connective-tissue stroma.

Of the small glands of the mouth, a group near the root of the tongue are of the mucous variety, some "lingual" glands in the region of the circumvallate papillæ are serous, while the remainder are of the mixed type.

Blood-vessels.—The larger vessels run mainly in the submucosa. The arteries of the submucosa give off one group of branches to the tunica propria, where they break up into a dense subepithelial capillary network, sending capillary loops into the papillæ. A second group of arterial branches passes to the submucosa, and gives rise to capillary networks among the tubules of the mucous glands. From the capillaries veins arise which accompany the arteries.

Lymphatics.—The larger lymph vessels lie in the submucosa. These send smaller branches into the tunica propria, where they open into small lymph capillaries and spaces.

Nerves.—Medullated nerve fibres form plexuses in the submucosa

and deeper parts of the mucosa. From these plexuses, branches are given off which lose their medullary sheaths and form a second plexus of non-medullated fibres just beneath the epithelium. From this subepithelial plexus, branches pass in between the epithelial cells to terminate in end brushes or in tactile corpuscles. The nerves belong to the cerebro-spinal system, and are dendrites of sensory ganglion cells. Axones of sympathetic neurones are also present in the oral mucosa, destined mainly for the muscle-tissue of the blood-vessels.

TECHNIC

(1) The superficial cells of the oral mucous membrane may be prepared for examination as in technic 1, page 63.

(2) For the study of the mucous membrane of different parts of the mouth, fix small pieces in formalin-Müller's fluid (technic 6, p. 7), cut sections perpendicular to the surface, stain with hæmatoxylin-eosin (technic 1, p. 23), and mount in balsam.

(3) Small mucous and serous glands of the mouth may be studied in the preceding sections.

THE TONGUE

The tongue is composed mainly of striated muscle fibres, supported by connective tissue and covered by a mucous membrane.

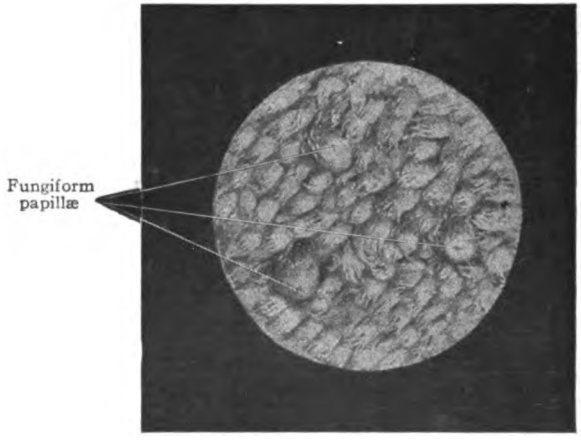

FIG. 133.—Surface View of Tongue showing filiform papillæ and three fungiform papillæ (Spalteholz).

While the bundles of fibres interlace in all directions, three fairly distinct planes can be differentiated.

(1) Vertical and somewhat radiating fibres—hyoglossus, genioglossus, and vertical fibres of the lingualis.

(2) Transverse fibres—transverse fibres of the lingualis.

(3) Longitudinal fibres—the styloglossus and longitudinal (superior and inferior) fibres of the lingualis.

The connective tissue which supports the muscle fibres and separates them into bundles contains mucous glands and fat. A strong band of connective tissue, the *septum linguæ*, extends lengthwise through the middle of the tongue, dividing it into right and left halves.

The *submucosa* of the tongue is not well developed, the stroma of the mucosa resting directly upon the underlying muscle.

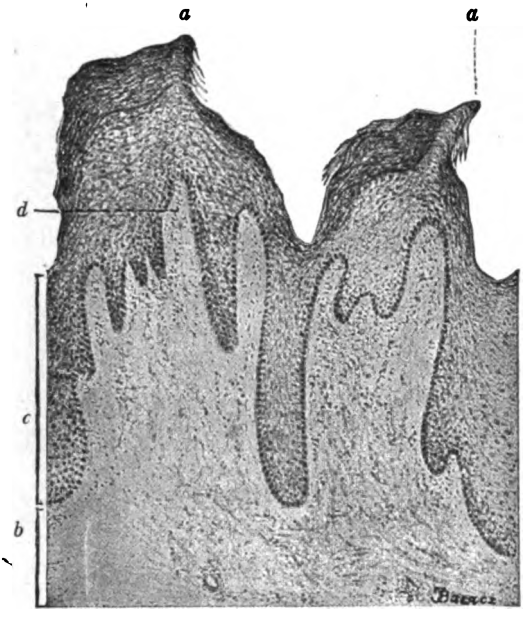

FIG. 134.—Vertical Section through Two Filiform Papillæ from Human Tongue. ×80. (Szymonowicz.) *a*, Horny epithelium; *b*, stroma; *c*, epithelium; *d*, secondary papilla.

The *mucous membrane* of the tongue resembles that of the mouth, but differs from the latter in that in addition to the low papillæ, such as are found in the oral mucosa, the upper surface of the tongue is studded with numerous and much larger papillæ or villi. These project from the surface and give to the tongue its characteristic roughness. Three forms of papillæ are distinguished:—Filiform, fungiform, and circumvallate.

(1) FILIFORM PAPILLÆ (Fig. 134).—These are the most numerous and are distributed over the entire dorsum of the organ. Each consists of a central core of connective tissue containing elastic fibres, which is long and slender, and is covered by stratified squamous epithelium. From the summit of each papilla are given off several *secondary papillæ*. The epithelium covering the papillæ is hornified and often extends from the surface as a long thread-like projection—hence the name, *filiform*.

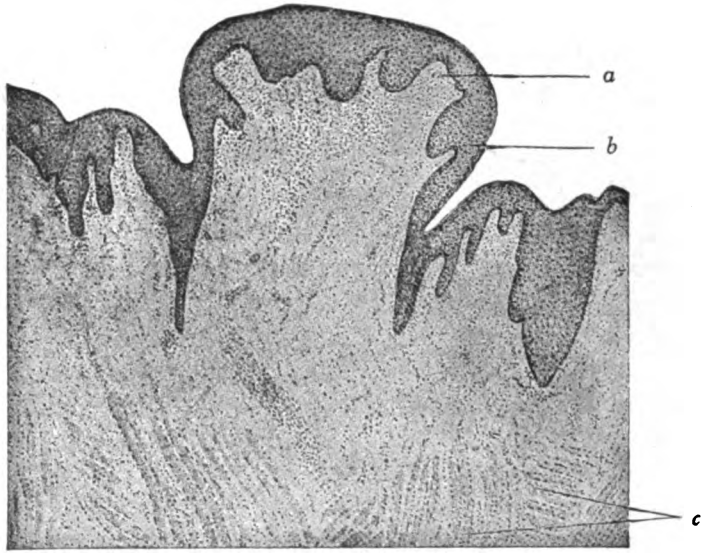

FIG. 135.—Vertical Section through Fungiform Papilla of Human Tongue. ×45. (Szymonowicz.) *a*, Secondary papilla; *b*, epithelium; *c*, muscle fibres.

(2) FUNGIFORM PAPILLÆ (Fig. 135).—Scattered irregularly over the entire dorsum among the filiform papillæ, but fewer in number, are larger papillæ of somewhat different structure known as fungiform papillæ. Their summits are rounded instead of pointed and their bases are narrowed. Secondary papillæ are given off not only from the summit, but from the sides of the papilla. The epithelial covering is comparatively thin and is not hornified. The connective-tissue cores of these papillæ contain but few elastic fibres.

(3) THE CIRCUMVALLATE PAPILLÆ (Fig. 136).—These are from nine to fifteen in number, and are grouped on the posterior surface of the dorsum of the tongue. They resemble the fungiform papillæ, but are much larger. Each lies rather deep in the mucous membrane,

surrounded by a groove or *trench* and *wall* (whence the name circumvallate). The wall is somewhat lower than the papilla, thus allowing the latter to project slightly above the surface. Secondary papillæ are confined to the upper surface of the papilla, the sides being free from secondary papillæ. The surface of the papilla and the borders of the groove and wall are covered by stratified squamous epithelium. Lying in the epithelium of the side wall and sometimes of the opposite trench wall are oval bodies, the so-called *taste buds*, which serve as

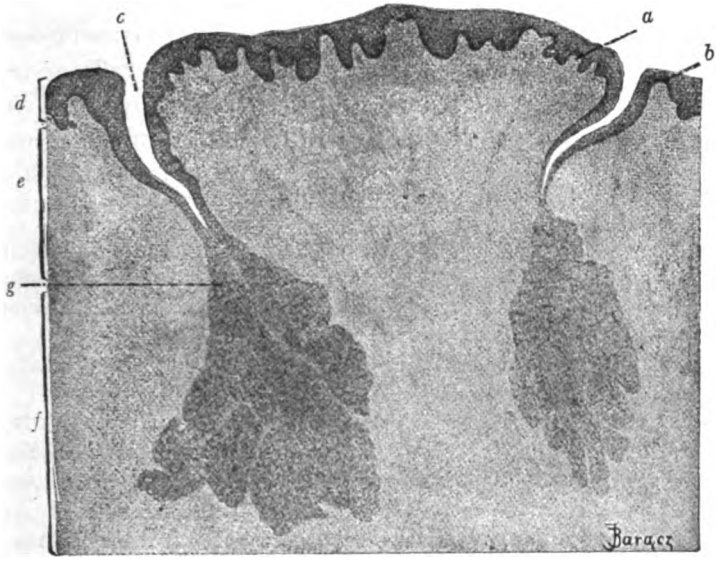

FIG. 136.—Vertical Section through a Circumvallate Papilla of Human Tongue. ×37. (Szymonowicz.) *a*, Secondary papilla; *b*, wall; *c*, trench; *d*, epithelium of tongue; *e*, stroma; *f*, submucosa; *g*, Ebner's glands.

organs for the nerves of taste (see nervous system). Into the trench surrounding the circumvallate papilla open the ducts of serous glands (Ebner's glands).

The *lymph follicles* of the tongue have been already described (page 184) under the head of the lingual tonsils.

For glands of the tongue see page 227.

The larger **blood-vessels** run in the connective-tissue septa. These give off smaller branches, which break up into capillary networks surrounding the muscle fibres and forming a plexus just beneath the epithelium. From the latter are given off capillaries to the papillæ. The capillaries converge to form veins, which in general follow the course of the arteries.

Fine **lymph spaces** occur in the papillæ and open into a plexus of small lymph capillaries just beneath the papillæ. These communicate with a deeper plexus of larger lymphatics, which increase in size and number as they pass backward and form an especially dense lymphatic network at the root of the tongue in the region of the lingual tonsils.

Nerves.—Sympathetic fibres pass mainly to the smooth muscle of the blood-vessels and to the glands. Medullated motor nerve fibres supply the lingual muscles. Medullated sensory nerves include those of the special sense of taste as well as those of ordinary sensation. They end freely among the epithelial cells or in connection with special end-organs—the *taste buds* mainly in the circumvallate papillæ, and the *end-bulbs of Krause* in the fungiform papillæ.

TECHNIC

Remove pieces of the dorsum of the tongue, selecting parts that will include the different forms of papillæ and cutting well into the underlying muscular tissue. Treat as in technic 2, p. 228, or sections may be stained with hæmatoxylin-picro-acid-fuchsin (technic 3, p. 24).

In sections from the back part of the tongue good examples of mucous and serous glands are usually found.

In small sections of the tongue the muscle fibres are seen arranged in bundles, surrounded by connective tissue and interlacing in all directions. For the study of the arrangement of the different planes of muscle, complete transverse sections should be made at intervals through the entire tongue. The muscle and connective-tissue relations are best brought out by the hæmatoxylin-picro-acid-fuchsin stain.

The Teeth

A tooth is a hard bone-like structure, part of which projects above the surface of the jaw as the *crown*, while the deeper portion, the *root*, consisting of from one to three *fangs*, is buried in a socket of the alveolar margin (Fig. 137). The junction of the root and crown is known as the *neck*.

A tooth consists of a soft central core, the *pulp cavity*, surrounded by *dentine* (Figs. 137 and 139). The latter constitutes the main bulk of the tooth. The exposed portion of the dentine is covered by a thin layer of extremely hard substance, the *enamel* (Fig. 137, 1), while the alveolar portion of the dentine is covered with *cementum* (Fig. 137, 3). Of these the dentine and cementum are of connective-tissue origin, the enamel of epithelial.

The *pulp cavity* occupies the central axis of the tooth (Figs. 137 and 139). In the root it is known as the *root canal*. At the apex of

the root or of each fang, it communicates with the underlying tissue by means of one or more minute *apical foramina*, through which blood-vessels and nerves enter the pulp cavity.

The *dental pulp* consists of loose connective tissue approaching the embryonal in type, composed of many fusiform and stellate cells and delicate white fibrils which do not form bundles but interlace in all directions. There are apparently no elastic fibres. A few smooth muscle cells have been described. The pulp is richly supplied with blood-vessels and nerves which are found only in this part of the tooth. Along the dentinal surface of the pulp the connective-tissue cells are arranged as a single layer of columnar cells, the *odontoblasts*. These cells are about 40μ long and lie with their long axes at right angles to the surface. They are closely allied to osteoblasts. Their nuclei lie toward their inner ends. Each cell sends out an inner process, which is usually single and passes into the dental pulp, several lateral processes which interlace with and probably anastomose with similar processes from other cells, and one or more outer fibre-like processes which enter the dentine, where they form the *dentinal fibres*. These frequently extend entirely through the dentine. Just beneath the layer of odontoblasts, the connective-tissue cells are much fewer in number than in the rest of the dental pulp. Appearing in sections as a clear band, it is known as the *layer of Weil*. Immediately internal to the layer of Weil, the cells are more closely arranged than elsewhere in the pulp.

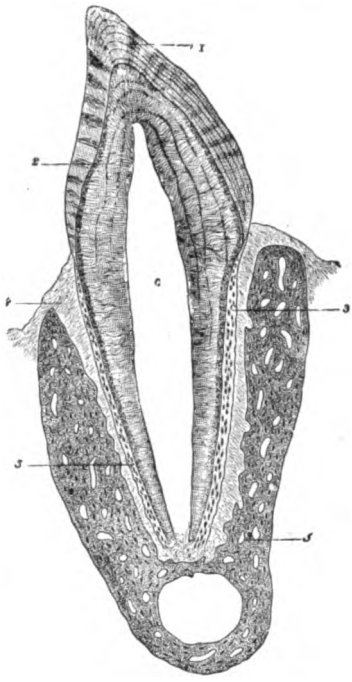

FIG. 137.—Vertical Section of Tooth *in situ*. ×15. (Waldeyer.) *c*, Pulp cavity, the letter being at about the junction of crown and root; 1, enamel showing radial and longitudinal markings; 2, dentine showing dental canals; 3, cementum (containing bone corpuscles); 4, peridental membrane; 5, bone of lower jaw.

DENTINE (Figs. 139 and 140, *D*) is somewhat harder than bone which it resembles in structure. According to von Bibra its chemical composition is:

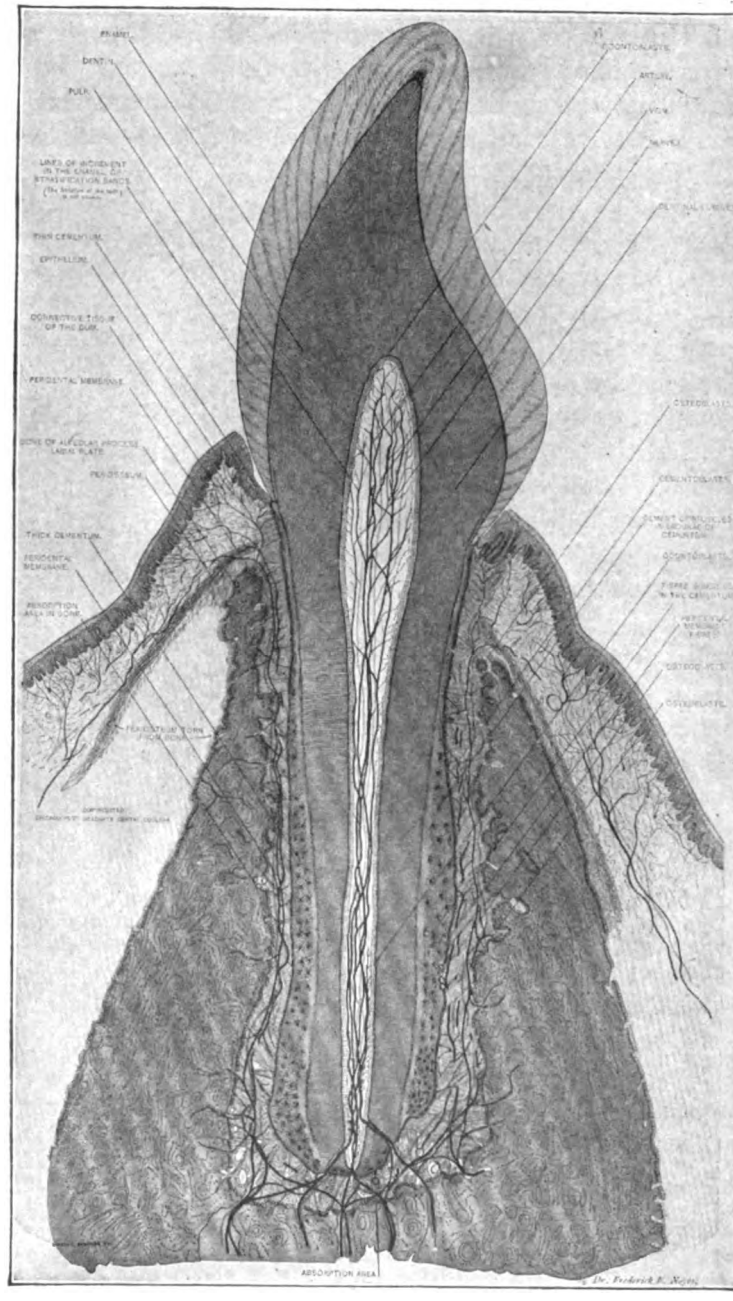

FIG. 138.—Diagram of Section through an Incisor, showing Blood-vessels and Peridental Membrane. (Noyes.)

Organic matter,	28.01
Calcium phosphate and fluorid,	66.72
Calcium carbonate,	3.36
Magnesium phosphate,	1.18
Other salts,	0.73

Dentine constitutes the bulk of the tooth and is peculiar in that it contains canaliculi, *dentinal canals* (Figs. 139 and 140, *Dk*), but no lacunæ or bone cells. The latter are represented by the odonto-

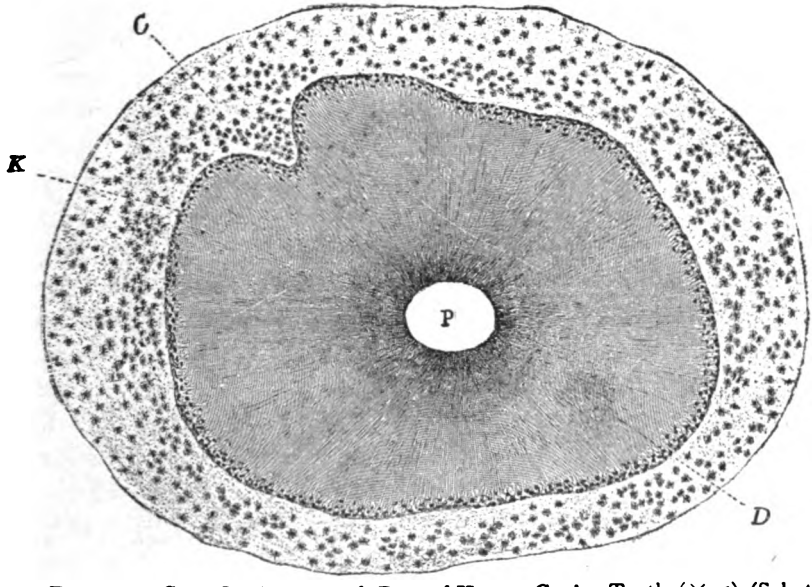

FIG. 139.—Cross Section through Root of Human Canine Tooth (×25) (Sobotta), showing relations of pulp cavity, dentine, and cementum. *P*, Pulp cavity; *D*, dentine; *C*, cementum; *K*, Tomes' granular layer.

blasts of the pulp, which, as already noted, lie at the inner side of the dentine, into the canaliculi of which they send the *dentinal fibres*. Dentine is non-vascular. The dentinal canals begin at the dental pulp, into which they open and where they have a calibre of 2 to 5μ. They pass outward radially, to the limit of the dentine, and, while taking different directions in different parts of the dentine, are essentially parallel. In their passage through the dentine the dentinal canals describe two series of curves, known as primary and secondary curves. The primary curves take the form of an elongated S from pulp to enamel or cementum, the secondary are twistings of the canals (drawn out corkscrew). These twistings are very fine as many as 200 turns having been described in the length of a canal. In their

passage through the dentine the main canals gradually grow smaller until their diameter is from 0.5 to 1μ. They give off minute side branches from 0.3 to 0.6μ in diameter, which leave the main tubules at almost right angles, but soon turn slightly outward. They anastomose with similar branches from other canals. This anastomosis takes place not only between branches of adjacent canals, but also between branches of canals some distance apart. The main canals terminate either in blind extremities, or form loops by anastomosing with neighboring tubules. Some of the tubules have quite extensive terminal

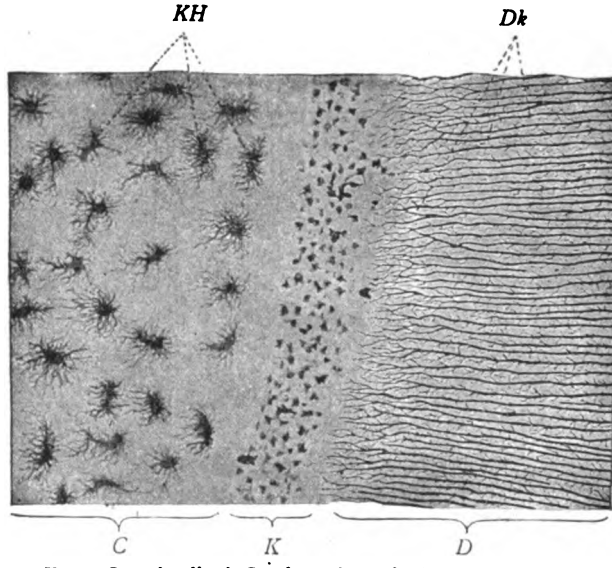

FIG. 140.—From Longitudinal Section through Root of Human Molar Tooth (×200) (Sobotta), showing junction of dentine and cementum. *C*, Cementum; *D*, dentine; *K*, Tomes' granular layer; *Dk*, dentinal canals; *KH*, lacunæ of cementum.

branchings, other tubules have only two or three end branches. A few tubules run slightly beyond the limits of the dentine into the enamel. The dentinal canals while essentially parallel differ somewhat in their arrangement in different parts of the tooth. In the crown there are few large branches and the main canals show distinct primary and secondary curves, most of them ending blindly in brush-like branchings just under the enamel, but some continuing over a short distance into the enamel where they lie in the cement between the prisms. In the root the canals have an almost straight direction (without primary curves). Large branches are more numerous and the main canals have a somewhat more irregular arrangement. They probably do not pass over into the cementum, but end at the granular

layer. The dentine immediately around a dentinal canal is harder and more dense than elsewhere and forms a sort of sheath for the canal—*Neumann's dental sheath.* Between the dentinal canals is a calcified ground substance, in which are connective-tissue fibres running in a direction parallel to the surface of the pulp, this corresponding, as in bone, to the deposition of the dentine in successive layers. The parallelism and the extreme regularity of both primary and secondary curves of the dentinal canals give rise, in longitudinal sections of dentine, to the appearance of lines running parallel to the surface of the pulp. These are known as the *incremental lines of Schreger.* In the same section may be seen other lines, the so-called *contour lines* of *Owen*, which cross the lines of Schreger at an angle in the root but run more nearly parallel to them in the crown. In a longitudinal section of the dentine of the crown, lines are seen running parallel to the surface of the pulp. They are probably due to irregularities in deposition of the dentine.

Spaces which probably represent incomplete calcification of the dentine occur in the peripheral portion of the dentine of the crown. These are known as *interglobular spaces* (Fig. 141, *Jg*). They are filled with a substance resembling uncalcified dentine. The interglobular spaces do not interrupt the dentinal canals which pass through them with no break in their continuity.

In the outer part of the dentine of the root are similar spaces which are smaller and more closely placed. These form the so-called *Tomes' granular layer* (Fig. 140, *K*). In the root of the tooth this layer is quite thick, separating the cementum from the dentine. Its spaces or lacunæ send off tiny canaliculi which run in all directions and anastomose with one another, with the dentinal tubules, and with the lacunæ of the cementum. This layer, with its small closely placed spaces and fine irregularly running canaliculi, contrasts sharply on the one side (Fig. 140) with the dentine and its straight parallel tubules, and on the other side, with the cementum and its large and more widely separated lacunæ. Over the crown of the tooth this layer is much thinner and as the apex is approached, becomes lost completely, the dentinal tubules extending to, and some of them entering slightly, (see above) the enamel.[1]

[1] Distinction is sometimes made between *primary* and *secondary* dentine. Primary dentine is that dentine normally formed during the development of a tooth and corresponds to the description given. Later under some stimulus, *e.g.*, excessive wear, formation of dentine again takes place, in which case the canals are often much more irregularly arranged; this is known as *secondary dentine.*

The ENAMEL covers the exposed part or crown of the tooth and is the hardest substance in the body. It is thickest over the crown and gradually decreases in thickness along the sides of the tooth until it reaches the neck where it stops. It contains little more than a trace of organic substance, its chemical composition being, according to von Bibra:

Organic matter,	3.59
Calcium phosphate and fluorid,	89.82
Calcium carbonate,	4.37
Magnesium phosphate,	1.34
Other salts,	0.88

It consists of long six-sided prisms 3 to 6μ in diameter—*enamel fibres* or *enamel prisms* (Fig. 141, *Sp*)—which take a slightly wavy course through the entire thickness of the enamel. The prisms are attached to one another by a small amount of cement substance, and are grouped into bundles, the prisms of each bundle being parallel, but the bundles themselves frequently crossing one another at acute angles. In the human adult the prisms are homogeneous; in the embryo they show a longitudinal fibrillation. Rather indistinct parallel lines (the *lines* of *Retzius*) cross the enamel prisms. They probably represent the deposition in layers of the lime salts, although they are considered by some as artefacts. The enamel is covered by a very thin apparently structureless membrane, the *cuticula dentis*.

The CEMENTUM (Fig. 140, *C*) covers the dentine of the root in a manner similar to that in which the enamel covers the dentine of the crown (Fig. 137, 1 and 3). It forms a thin layer at the neck, but increases in thickness as the deeper part of the root is reached. Cementum is *bone tissue*. It contains *lacunæ* and *bone cells*. These vary much more in size and shape than do those of bone, are very irregularly distributed and may be absent from considerable areas. From the lacunæ radiate canaliculi, but there is no distinct lamellation and no Haversian systems excepting in the large teeth of the larger mammalia, and in the teeth of the aged, where they may be present. Channels, similar to Volkmann's canals in bone, not surrounded by concentric lamellæ, but serving for the passage of blood-vessels, are quite frequent in the thicker portions of the cementum. The ground substance of the cementum is continuous with that of the dentine and many canaliculi of the former open into the interglobular spaces of the latter. Many uncalcified Sharpey's fibres penetrate the cementum.

The Peridental Membrane.—Surrounding the root of the tooth and filling in the space between it and the wall of the alveolus is a layer of connective tissue which is known as the peridental membrane (Fig. 145). It attaches the tooth to the alveolus, attaches the teeth to each other, supports the free margin of the gum and holds it to the tooth, and serves for the transmission of vessels and nerves. It consists of dense white fibrous tissue with few or no elastic fibres. In general it resembles periosteum and has been described as a reflection of the alveolar periosteum upon the root of the tooth. The fibres fall into two classes, long fibres which pass from the cementum to the coarser connective

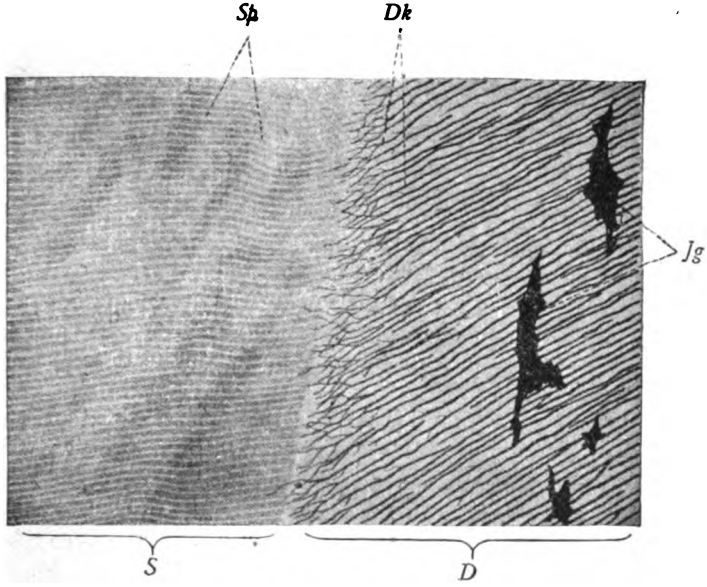

FIG. 141.—From Longitudinal Section of Crown of Human Premolar (×200) (Sobotta), showing junction of enamel and dentine. *S*, Enamel; *D*, dentine; *Sp*, enamel prisms; *Dk*, dental canals; *Jg*, interglobular spaces. A few dentinal fibres are seen passing beyond the limits of the dentine into the enamel. The oblique dark bands in the enamel are the lines of Retzius.

tissue of the gum, to the alveolar wall or to the cementum of an adjacent tooth, and short fibres which fill in the interstices between the long fibres. Many of the long fibres are continued as calcified fibres into the cementum on the one hand and into the bone of the alveolus on the other. They are analogous to Sharpey's fibres of bone (p. 197). As they enter the cementum or bone, the fibres are grouped in bundles but in the central portion of the membrane these bundles break up and their fibres interlace in all directions. The long fibres differ in direction in different parts of the membrane. Those which spring from the cementum near its junction with enamel, pass out at right angles and then turn sharply toward the free margin of the gum which they support. Passing toward the apex, the next fibres instead of bending toward the free margin of the gum pass out at right angles and blend with the gum connective tissue. All fibres

to the gums are more developed on the lingual than on the labial side. Between the teeth, fibres of this level pass from the cementum of one tooth to that of the next adjacent, here also supporting the free margin of the gum. Still further apically the fibres are grouped in coarser bundles to form the so-called dental ligament, and pass over or into the edge of the alveolus; between the teeth into the edge of the septum or into the cementum of the adjacent tooth. From the dental ligament for about one-third the depth of the root, rather coarse bundles of fibres pass from cementum almost straight to alveolar wall. For most of the remaining two-thirds, the direction of the fibres is away from the apex, the bundles tending to break up and to radiate to a more extended insertion into the alveolar bone. The apical fibres also radiate to their insertion into bone.

Among the connective-tissue fibres are found fixed connective-tissue cells, groups or cords of cells which are apparently epithelial, and, during development and sometimes sparingly later, osteoblasts, osteoclasts, and cementoblasts.

The fixed connective-tissue cells are described on p. 87.

The epithelioid cells are mostly arranged in cords which anastomose to form a network. The cells themselves are granular and have oval or round nuclei rich in chromatin. In some places their arrangement resembles tubules, but whether they have a glandular character is not known.

Osteoblasts and osteoclasts are the same as in developing bone (p. 203). The latter are present wherever absorption is taking place. They are especially numerous during the absorption of the roots of the milk teeth to make way for the permanent set.

Cementoblasts are cells which lie against the cementum and are analogous to the osteoblasts, from which however they differ morphologically. They are flattened and their protoplasm fills in the spaces between the ends of the fibres so that the cell bodies show the indentations of the fibres lying against them. From the cementoblasts processes extend into the cementum in much the same manner as processes of bone cells extend into their canaliculi.

Blood-vessels.—The arteries which supply the tooth and peridental membrane, enter the apical portion of the latter from the adjacent bone of the alveolus (Fig. 138). On entering the membrane the vessels divide into two main sets one of which passes through the foramina of the apex to supply the dental pulp, while the other passes along the outside of the tooth in the peridental membrane which it supplies (Fig. 138). The vessels in the membrane anastomose with vessels from the bone of the alveolar wall and at the margin of the alveolar cavity with vessels from the gums. From the capillary network veins follow the arteries back to the apical portion of the membrane and into the bone at the bottom of the alveolus. The arteries to the pulp run mainly through its centre giving off branches which form a capillary network which is especially rich at the periphery of the pulp (Fig. 142). From these capillaries arise veins which pass

back through the apical foramina into the peridental membrane where they unite with veins from the membrane and pass into the bone of the alveolus. Enamel, cementum, and dentine are non-vascular. A marked feature of the pulp vessels is the thinness of their walls, vessels of much greater calibre than are usually classed as capillaries having walls of capillary thinness.

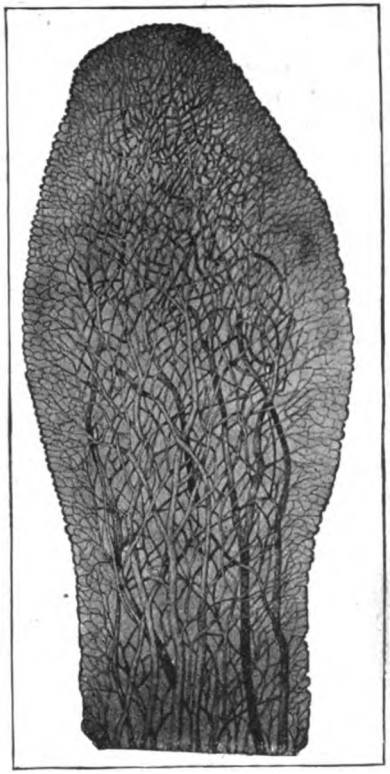

FIG. 142.—Diagram of Blood-vessels of Pulp. (Stowell).

Lymph Vessels.—Most authorities have denied the existence of definite lymph channels in the pulp. Schweitzer on the other hand describes an arborization of small lymph vessels in the pulp of the crown, converging to a few larger lymph vessels in the root pulp and accompanying the blood-vessels through the foramina of the apex.

Nerves.—The distribution of nerves to the tooth follows quite closely that of the blood-vessels. Bundles of medullated fibres from the bone at the bottom of the alveolus enter the peridental membrane just beneath the apex where they divide into two main sets, one of which follows the vessels of the membrane while the other passes with the vessels through the apical foramina to the dental pulp. The membrane surrounding the tooth also receives nerves from the bone of the side wall of the alveolus. The branches to the pulp pass up through its center, giving off branches which are mostly non-medullated and which radiate toward the periphery where they form a plexus in the layer of Weil just beneath the odontoblasts. From this plexus branches are given off which pass in between the odontoblasts, some terminating there while others end between the odontoblasts and the dentine.[1]

[1] Noyes calls attention to the extreme sensitiveness of dentine in spite of the fact that no nerve fibres have been demonstrated in its canals, and believes that sensation is carried to the nerve fibres through the processes (dentinal fibres) and cell bodies of the odontoblasts.

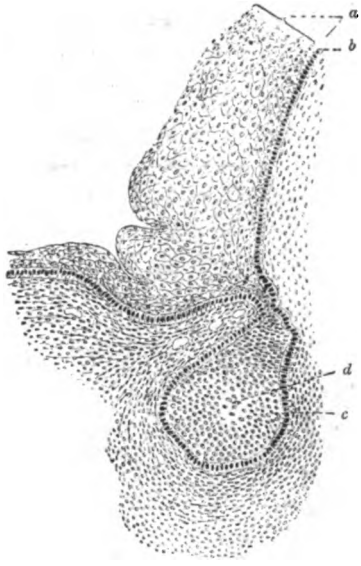

FIG. 143.

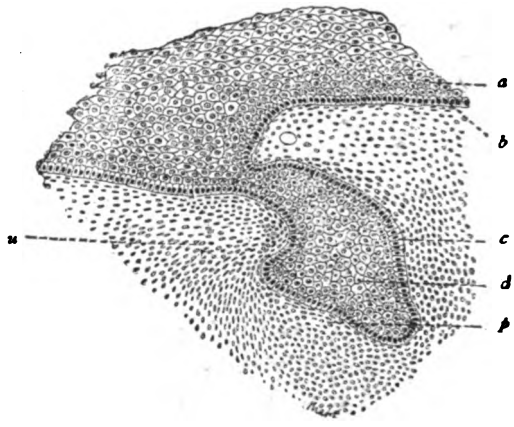

FIG. 144.

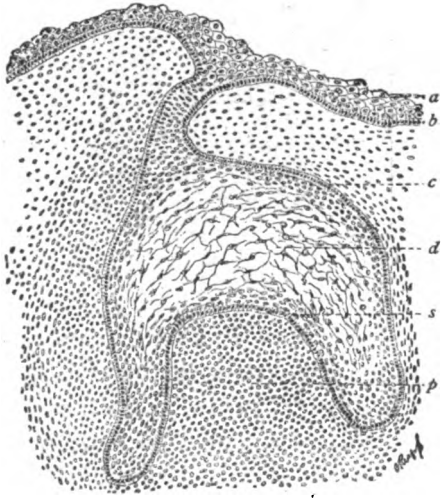

FIG. 145.

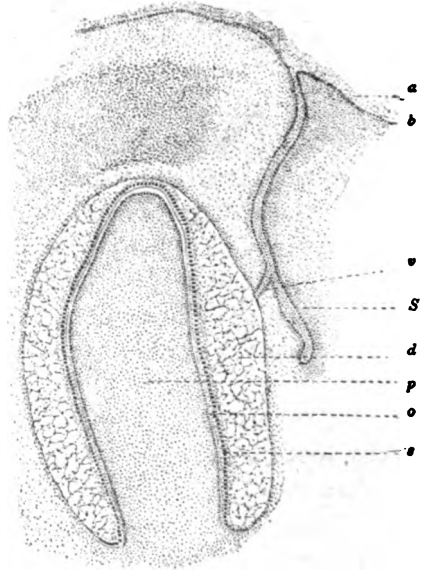

FIG. 146.

FIGS. 143, 144, 145, 146.—Four Stages in the Development of a Tooth (from lower jaw of sheep embryo). (Bohm-Davidoff.) Fig. 143, Beginning of enamel organ showing connection with epithelium of mouth; Fig. 144, Later stage showing same with first trace of papilla; Fig. 145, Later stage showing papilla well formed, the differentiation of the enamel pulp and of the inner and outer enamel cells can be seen; odontoblast appearing along periphery of the papilla; Fig. 146, shows also beginning enamel organ of permanent tooth; Figs. 143, 144, 145, ×110, Fig. 146, ×40. *a*, Epithelium of mouth; *b*, its basal layer; *c*, superficial cells of enamel organ; *d*, enamel pulp; *p*, dental papilla; *s*, enamel cells; *o*, odontoblasts; *S*, enamel organ of permanent tooth just beginning to differentiate; *v*, remains of enamel ledge of milk tooth; *u*, surrounding connective tissue.

DEVELOPMENT.—The *enamel* of the teeth is of ectodermic origin, the remainder of mesodermic. The earliest indication of tooth formation occurs about the seventh week of intra-uterine life (embryos 12 to 15 mm.). It consists in a dipping down of the epithelium covering the edge of the jaw into the underlying connective tissue (mesoderm) where it forms the *dental shelf*, or *common dental germ*. Soon after the formation of the dental shelf, a groove appears along the margin of the jaw where the ingrowth of epithelium occurred. This is known as the *dental groove*. The epithelium of the dental shelf is at first of uniform thickness. Soon, however, at intervals along the outer side of the dental shelf, the cells of the shelf undergo proliferation and form thickenings, ten in

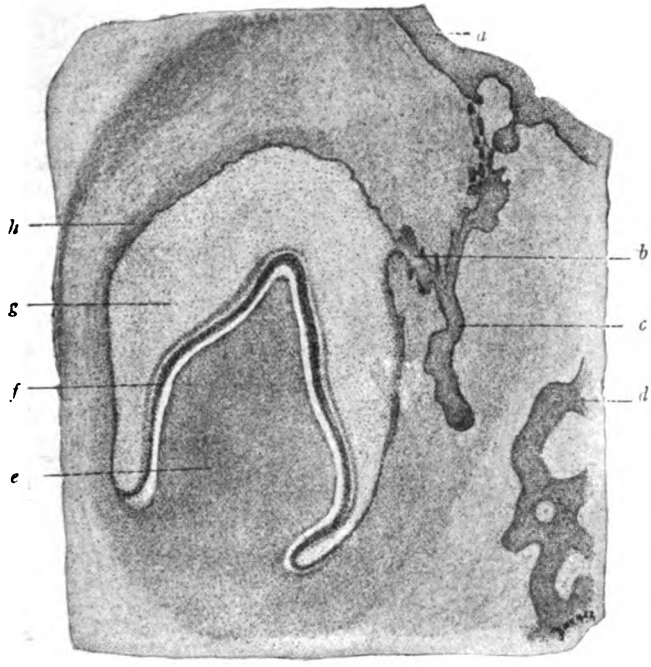

FIG. 147.—Developing Tooth from Three-and-one-half-months' Human Embryo. ×65. (Szymonowicz.) *a*, Epithelium of gums; *b*, neck of enamel organ; *c*, dental germ of permanent tooth; *d*, bone of lower jaw; *e*, dental papilla; *f*, inner enamel cells; *g*, enamel pulp; *h*, outer enamel cells.

the upper and ten in the lower jaw, each one corresponding to the position of a future milk tooth. These are known as *special dental germs*, and remain for some time connected with one another and with the surface epithelium by means of the rest of the dental ridge.

Into the side of each special dental germ there occurs about the end of the third month (embryos of about 40 mm.) an invagination of the underlying connective tissue. In the upper jaw the invagination takes place on the upper and inner side, in the lower jaw on the lower and inner side, of each dental germ. Each invagination forms a *dental papilla* (Fig. 145), over which the tissue of the

special dental germ forms a sort of cap, the latter being known from its subsequent function as the *enamel organ*, the papilla itself giving rise to the pulp and dentine. The dental germs are at this stage connected with each other by remaining portions of the dental shelf, and with the surface epithelium by remains of the original invagination. The next step is the almost complete separation of the special dental germs and ridge from the surface epithelium (Fig. 146), and the formation around each special dental germ of a vascular membrane, the *dental sac*. The attenuated strand of epithelial cells, which

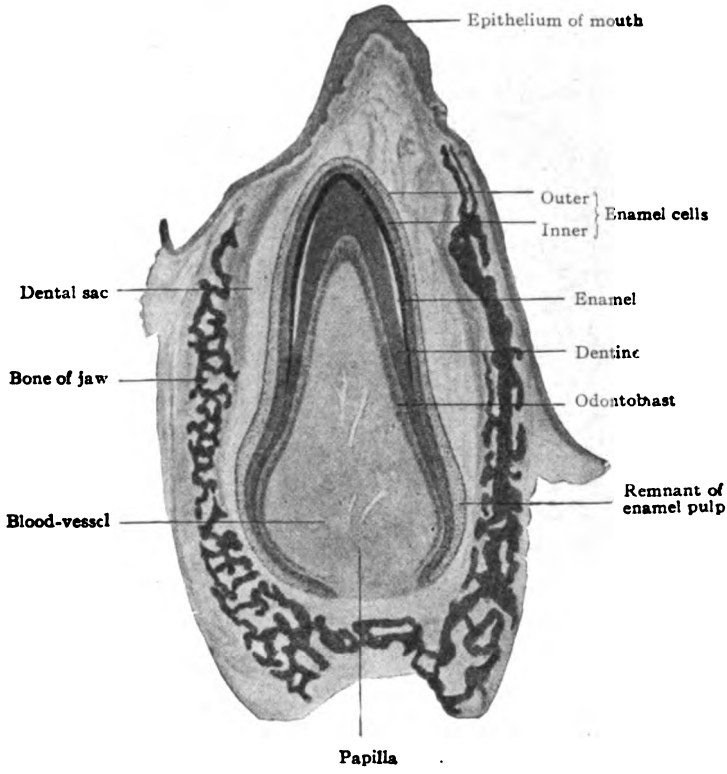

FIG. 148.—Longitudinal Section of a Developing Tooth of a New-born Puppy. (Bonnett.) Late Stage.

still maintains a connection between the dental germs and the epithelium of the gums, is known as the *neck* of the *emanel organ* and it is from this that an extension soon occurs to the inner side of the dental germs of the milk teeth, to form the *dental germs* of the *permanent teeth* (Fig. 147, *c*). Into the latter, connective-tissue papillæ extend as in the case of the milk teeth. There are thus present as early as the fifth month of fœtal existence the germs of all milk and of some permanent teeth.

The ENAMEL is formed by the *enamel organ*. At the stage represented in Fig. 149, it consists of three layers: (1) The *outer enamel cells*, somewhat flat-

tened; (2) the *inner enamel cells*, high columnar epithelium; (3) a layer of *enamel pulp*, situated between the other layers, and consisting of stellate anastomosing cells with considerable intercellular substance (Figs. 149 and 150). A membrane, the *cuticular membrane*, is first laid down between the inner enamel cells and the dentine. Each of the inner enamel cells now sends out a process, *Tomes' process*, from its inner end. The processes are separated by a considerable amount of cement, and are the beginnings of the *enamel prisms*. Calcification now takes place both in the prisms and in the cement substance, beginning in the ends nearest

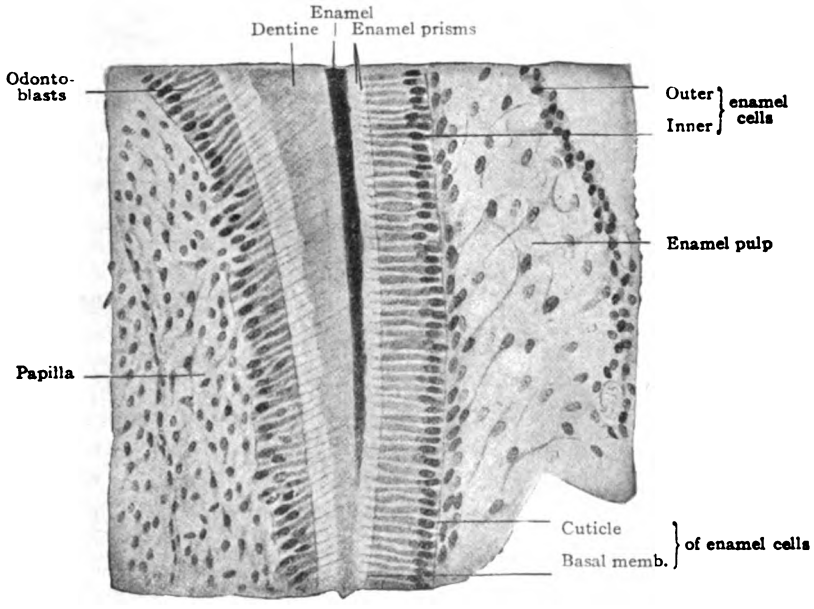

FIG. 149.—Section through Border of a Developing Tooth of a New-born Puppy. (Bonnett.)

the papilla. As this proceeds outward, the prisms become much elongated and the cement substance reduced in amount. Further growth in thickness of enamel occurs by lengthening of the enamel prisms. During the formation of the enamel, the enamel pulp and the external enamel cells disappear.

The formation of enamel in the milk teeth begins about the end of the fourth month and continues until the eruption of the teeth. The extent of the enamel organ is considerably greater than that of the enamel, the former covering the entire tooth, both root and crown, with the exception of the base of the papilla where the latter is connected with the underlying connective tissue. As the tooth develops, the enamel organ disappears over the root, remaining to form the enamel only over that part of the tooth which is to be subsequently exposed. The function of the enamel pulp is not known. It disappears as the tooth grows. It has been suggested that it may furnish nutrition or serve as an avenue through which nutrition reaches the non-vascular enamel organ. It may serve as an area of least resistance through which the tooth grows.

The DENTINE is the first of the dental tissues to become hard. Both dentine and pulp develop, as noted on p. 243, from the mesoderm of the dental papilla. When the latter is first formed it is of the same structure as the surrounding mesoderm with which it is continuous, except that it is somewhat more dense; later it assumes more the character of embryonal connective tissue, blood-vessels and nerves growing into it from the underlying connective tissue. The most peripheral cells of the pulp, those lying nearest the enamel organ, differentiate from the rest of the pulp to form a single layer of columnar or pyramidal cells—the *odontoblasts*. The outer end of each cell is broad, while the inner end which contains the nucleus narrows to a point from which a delicate process extends into the pulp and probably anastomoses with other cell processes. These cells are analogous to the osteoblasts of developing bone and like them appear to determine the deposition of lime salts. The lime salts are first laid down in a membrane-like structure—the *membrana preformativa*—which the odontoblasts apparently form between themselves and the enamel. From this membrane the transformation of the connective tissue into dentine progresses inward toward the pulp, additional dentine continuing to be laid down in layers, each new layer internal to the preceding. In this way the dental papilla is reduced in size to form the *pulp cavity*. In the outer part of the dentine spaces remain in which no lime salts are deposited. These are the *interglobular spaces*. As calcification proceeds the odontoblasts do not become enclosed within the dentine as do the osteoblasts within bone. They leave merely long slender processes, the *dentinal fibres*, lying in minute channels through the dentine, *dentinal canals*, while the bodies of the cells form a single layer along the inner margin of the dentine. There are thus no lacunæ and no cells within the dentine. This relation of odontoblasts to dentine, and probably the original odontoblasts, persist, not only throughout embryonic but through adult life.

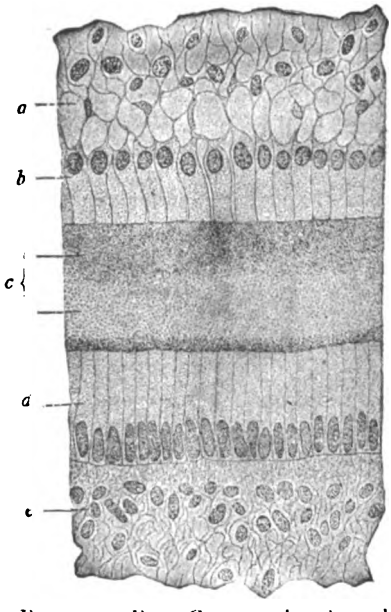

FIG. 150.—From Cross-section through a Developing Tooth. ×720. (Böhm and von Davidoff.) Note close relationship between odontoblasts and tissue of dental pulp. *a*, Dental pulp; *b*, odontoblasts; *c*, dentine; *d*, inner enamel cells; *e*, enamel pulp.

While the tooth lies within the gum, the somewhat condensed connective tissue which surrounds it constitutes the *dental sac*.

As the germs of the milk teeth develop, the dental shelf broadens by extending inward toward the tongue. Along this inner margin appear the germs of the permanent teeth, the development of the various teeth structures from the germs being identical with the process described in the case of the milk teeth.

Twenty of the permanent teeth correspond in position to the twenty milk teeth, while twelve new molar germs, six in the upper and six in the lower jaw, represent the *true molars* of the adult. The first permanent tooth germ to appear is that of the first molar, about the beginning of the fifth month (embryos of about 180 mm.). It lies just behind the second molar of the milk dentition. The germs of the incisors and canines appear about the end of the sixth month, those of the premolars, which replace the milk molars, in the beginning of the eighth month. The germs of the second and third (wisdom teeth) molars do not appear until after birth, those of the former at about six months, of the latter during the fifth year.

The CEMENTUM is developed by ossification of that part of the dental sac which covers the root, its development being similar to subperiosteal bone formation (p. 207), without the formation of Haversian systems.

TECHNIC

(1) Teeth are extremely difficult organs from which to obtain satisfactory material for study. Sections of hard (undecalcified) and of decalcified teeth may be prepared in the same manner as sections of bone—technics 1, and 2 p. 202. The decalcified tooth should include if possible the alveolar margin of the jaw, so that in longitudinal sections the mode of implantation and the relation of the tooth to the surrounding structures can be seen.

(2) For the study of developing teeth, embryo pigs, sheep, cats, dogs, etc., are suitable. For the early stages fœtal pigs should be five to six inches long; for the intermediate, ten to twelve inches. The later stages are best obtained from a small new-born animal, *e.g.*, kitten or small pup. The jaw—preferably the lower—or pieces of the jaw are fixed in formalin-Müller's fluid (technic 6, p. 7), hardened in alcohol, and decalcified (page 9). Subsequent treatment is the same as for developing bone (technic 1, p. 208).

The Pharynx

The wall of the pharynx consists of three coats—mucous, muscular, and fibrous.

1. **The mucous membrane** has a surface epithelium and an underlying stroma.

The EPITHELIUM is stratified squamous except in the region of the posterior nares, where it is stratified columnar ciliated, continuous with the similar epithelium of the nasal mucosa.

The STROMA, or tunica propria, consists of mixed fibrous and elastic tissue infiltrated with lymphoid cells. In certain regions these cells form distinct *lymph nodules* (see pharyngeal tonsils, page 184). Beneath the stratified squamous epithelium the stroma is thrown up into numerous low *papillæ*. These are absent in regions

covered by ciliated cells. Bounding the stroma externally is a strongly developed layer of longitudinal elastic fibres, the *elastic limiting layer*, which separates the stroma from the muscular coat and sends stout bands in between the muscle bundles of the latter.

2. **The muscular coat** lies beneath the elastic layer and is formed of very irregularly arranged muscle fibres belonging to the constrictor muscles of the pharynx.

3. **The fibrous coat** consists of a dense network of mixed fibrous and elastic tissue. It has no distinct external limit, and binds the pharynx to the surrounding structures.

The distribution of **blood-vessels, lymphatics,** and **nerves** is similar to that in the oral mucosa.

Small, branched, tubular, *mucous glands* are present in the stroma, and extend down into the intermuscular connective tissue. They are most numerous near the opening of the Eustachian tube.

TECHNIC

For the study of the structure of the walls of the pharynx, material should be prepared as in technic 2, p. 228.

II. THE FOREGUT

The Œsophagus

The walls of the œsophagus are continuous with those of the pharynx and closely resemble the latter in structure. They consist of four layers, which from within outward are mucous, submucous, muscular, and fibrous (Figs. 151 and 153).

1. **The mucous membrane** resembles that of the pharynx except that beneath the stroma is a well-developed *muscularis mucosæ* composed of smooth muscle cells arranged longitudinally. The muscularis mucosæ forms a complete coat only in the lower part of the œsophagus. The epithelium is stratified squamous and rests upon a papillated stroma.

2. **The submucosa** is composed of loosely arranged fibrous and elastic tissue. It contains mucous glands, the larger blood-vessels, lymphatics, and nerves.

3. **The Muscular Coat.**—In the upper portion of the œsophagus this coat is composed of striated muscle fibres; in the middle portion, of mixed striated and smooth muscle. In the lower portion there are

two distinct layers of smooth muscle, an inner circular and an outer longitudinal. The latter is not continuous.

4. **The fibrous coat** consists of bundles of white fibrous tissue with many elastic fibres. It serves to connect the œsophagus with the surrounding structures.

Two kinds of *glands* occur in the œsophagus.

FIG. 151.—Transverse Section through Wall of Dog's Œsophagus. ×18. (Böhm and von Davidoff.) *a*, Epithelium; *b*, stroma; *c*, muscularis mucosæ; *d*, submucosa; *e*, circular muscle layer; *f*, longitudinal muscle layer; *g*, fibrous layer.

(1) MUCOUS GLANDS.—These are of the same structure as those of the tongue, but much smaller. They lie in the submucosa and are distributed throughout the entire œsophagus, though most numerous in its upper third. The ducts pass obliquely downward on their way to the surface. Just before entering the muscularis mucosæ the duct widens out to form a sort of *ampulla*. Beyond this it again becomes narrow and enters the epithelium in the depression between two adjacent papillæ. A small lymph nodule is usually attached to the duct as it passes through the tunica propria.

(2) SIMPLE BRANCHED TUBULAR GLANDS.—These resemble the glands of the cardiac end of the stomach, but branch much more

profusely. Some contain both chief and acid cells, others only chief cells (see stomach, page 254). They lie in the tunica propria, and are for the most part confined to a narrow zone at the lower end of the œsophagus and to the level of the fifth tracheal ring. Scattered groups also occur in other regions.

The distribution of blood-vessels, lymphatics, and nerves in the œsophagus is similar to their distribution in the mouth (p. 227). Between the two muscular coats the nerve fibres form plexuses in which are many sympathetic nerve cells. These plexuses are analogous to the plexuses of Meissner in the stomach and intestine.

TECHNIC

Remove a portion of the wall of the œsophagus, wash carefully in normal salt solution, and pin out, mucous-membrane side up, on a piece of cork. Fix in formalin-Müller's fluid and harden in alcohol (technic 6, p. 7). Transverse or longitudinal sections should be cut through the entire thickness of the wall. If the details of the muscular coat are to be studied, sections from at least three different levels should be taken: one near the upper end, one at about the middle, and the other in the lower third. Stain with hæmatoxylin-eosin or hæmatoxylin-picro-acid-fuchsin (technic 1, p. 23; 3, p. 24) and mount in balsam.

General Structure of the Walls of the Gastro-intestinal Canal

The walls of the stomach and intestines are made up of four coats (Fig. 152). These from the lumen outward are mucous, submucous, muscular, and serous.

1. **The mucous membrane** (Fig. 152) consists of surface epithelium, glands, stroma, and muscularis mucosæ. The *surface epithelium* is simple columnar and rests upon a distinct *basement membrane.* The arrangement of the glands and the nature of the gland cells differ in different parts of the tract. The *stroma* is a loosely arranged, richly cellular connective tissue, which in many places is so infiltrated with lymphoid cells as to constitute diffuse lymphatic tissue. In other places it contains circumscribed masses of lymphatic tissue, lymph nodules. The amount of stroma depends upon the closeness with which the glands are packed. The *muscularis mucosæ* consists of smooth muscle cells, which have a generally longitudinal arrangement. Where, however, the muscularis mucosæ is thick there are usually two distinct layers—an inner circular and an outer longitudi-

nal. Folds of considerable extent occur in the mucous membrane. Those of the stomach are known as *rugæ*, and are not constant, depending upon the degree of distention of the organ. Those of the small intestine are much more definite, and are known as *valvulæ conniventes*.

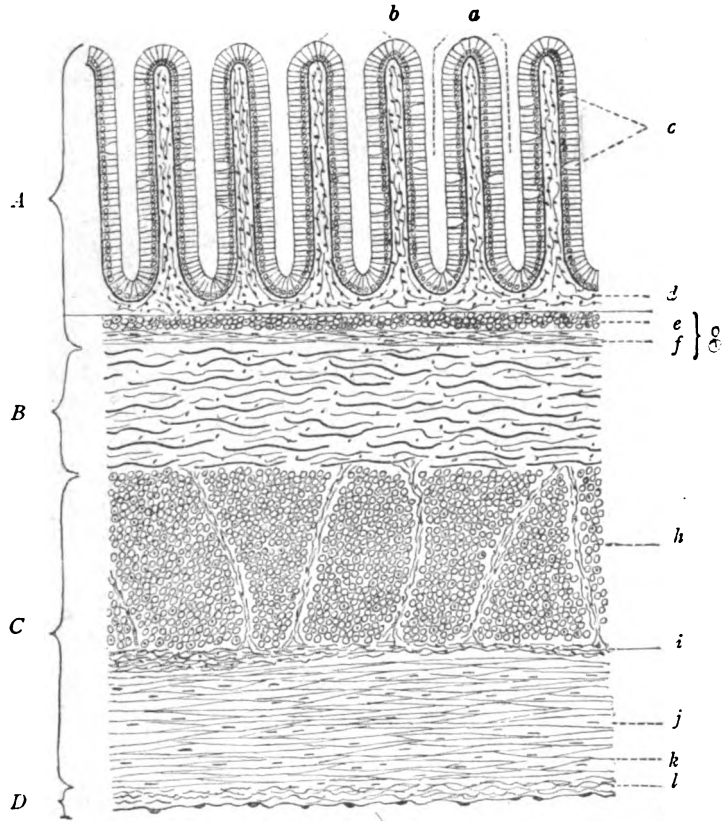

FIG. 152.—Diagram of Structure of Wall of Gastro-intestinal Canal (longitudinal section). *A*, Mucous membrane; *a*, glands; *b*, surface epithelium; *c*, goblet cells; *d*, stroma; *e*, inner circular, *f*, outer longitudinal layers of *g*, muscularis mucosæ. *B*, Submucosa. *C*, Muscular coat; *h*, its inner circular layer; *j*, its outer longitudinal layer; *i*, intermuscular connective-tissue septum. *D*, serous coat; *k*, its connective-tissue layer; *l*, its endothelial layer.

2. **The submucosa** (Fig. 152) is a loose connective-tissue structure. It contains the larger blood-vessels, lymphatics, and nerves.

3. **The muscular coat** (Fig. 152) consists of two layers of smooth muscle, which in the intestine are sharply differentiated into an *inner circular* and an *outer longitudinal*. In the stomach the direction of the layers of the muscular coat is less definite. A thin layer of

connective tissue separates the two layers of muscle. From this septa extend into the muscle tissue, separating it into bundles.

4. **The serous coat** (Fig. 152) is the visceral layer of the peritoneum. It consists of a thin layer of connective tissue covered by a single layer of mesothelium. Along the attachment of the mesentery the serous coat is wanting.

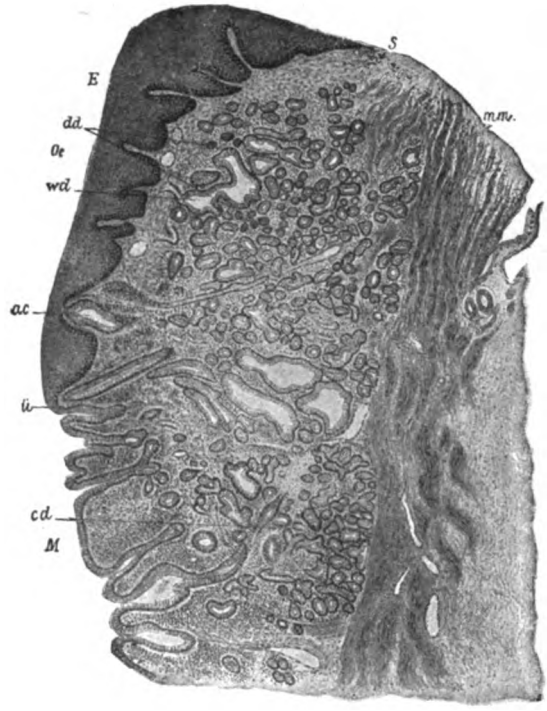

FIG. 153.—Section through Junction of Œsophagus and Stomach of Man. ×121. (Schäfer.) *Oe*, Œsophagus; *M*, stomach; *cd*, cardiac glands; *wd*, dilated ducts of cardiac glands; *S*, stroma; *E*, stratified squamous epithelium of œsophagus; *mm*, muscularis mucosæ; *cd*, irregularly cut tubules of cardiac glands; *dd*, cardiac glands in lower end of the œsophagus; *ü*, limit of stratified œsophageal epithelium.

The subdivisions of the gastro-intestinal canal differ from one another mainly in regard to the structure of their mucous membranes, and especially in regard to the structure of the glands of the mucous membrane and submucosa.

The Stomach

At the junction of œsophagus and stomach there is an abrupt transition from the stratified squamous epithelium of the former with its smooth surface to the simple columnar epithelium of the latter

with its elevations and depressions. In the deeper structures the line of demarcation is not so abrupt, the muscularis mucosæ of the œsophagus being continuous with that of the stomach, and glands of the stomach type extending up under the stratified epithelium of the œsophagus (Fig. 153).

1. **The mucous membrane** of the stomach is folded into ridges or *rugæ*, the height and number of which depend, as already noted, upon the degree of distention of the organ. The rugæ are most prominent

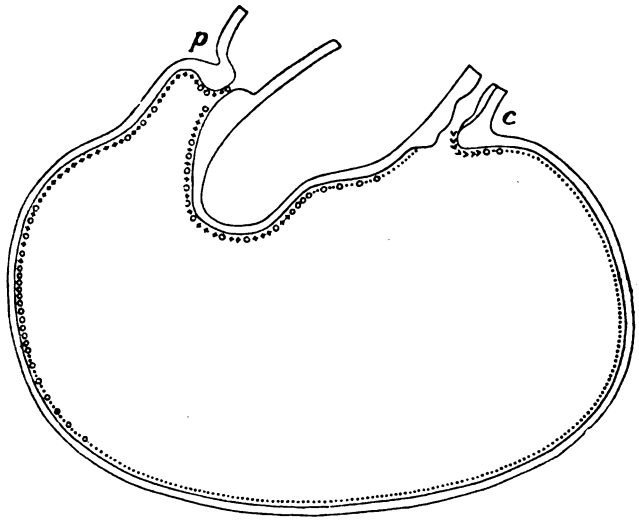

FIG. 154.—Outline Diagram of Stomach to show Location of Different Kinds of Glands. *c*, cardia; *p*, pylorus; vvvvvv, cardiac glands; ....., fundus glands; ++++++, pyloric glands; oooooo, intestinal type glands (of Lieberkuhn). (Jouvenal.)

in the collapsed organ, almost absent when the organ is fully distended. In addition to the rugæ the entire mucous membrane is studded with minute depressions barely visible to the naked eye, the so-called *gastric pits* (Fig. 156, *Mg*). These mark the openings of the *gastric glands*. In the fundus they are comparatively shallow, extending through about one-fifth the thickness of the mucosa; in the pylorus the pits are much deeper, extending through half or more of the thickness of the mucous membrane (compare Figs. 156 and 160).

The Epithelium.—This is of the simple columnar type, covers the entire surface of the gastric mucosa and extends down into the pits (Fig. 156). The cells are of the high, clear, mucous type (Fig. 157, *M* and *M'*). The end of the cell toward the lumen is clear, usually consists mostly of mucus, and consequently stains lightly. There

is no such distinct cuticle as in the intestine. The basal end of the cell contains the spheroidal, oval, or sometimes flattened nucleus, is granular, and takes a darker stain. The amount of mucus in the cell depends upon its functional condition. The cells rest upon a distinct basement membrane.

THE GASTRIC GLANDS.—Extending from the bottoms of the pits, their epithelium continuous with that of the pits themselves, are the gastric glands. These are of two main kinds, *fundus* or *peptic glands*, distributed through the greater part of the gastric mucosa, and *pyloric glands*, confined to the immediate region of the pylorus.

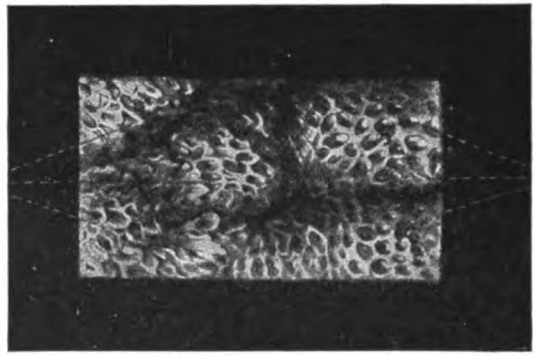

FIG. 155.—Surface View of Mucous Membrane of Stomach showing gastric pits (Spalteholz).

The *fundus glands* (Fig. 156) are simple, sometimes branched, tubular glands, of which from three to seven open into each gastric pit. They extend through the entire thickness of the stroma, to the muscularis mucosæ.

Each gland consists of (1) a *mouth* opening into the pit; (2) a constricted portion, the neck; (3) the *body* or main portion of the tubule; and (4) a slightly dilated and bent blind extremity, the *fundus* (Fig. 156). The mouth marks the transition from the higher epithelium of the pit to the low cuboidal of the neck (Fig. 157, *h*). In the body and fundus of the gland two types of cells are found: (*a*) *chief cells* (central, peptic, or adelomorphous), and (*b*) *parietal cells* (acid, oxyntic, or delomorphous).

The *chief cells* (Figs. 157, 158) are the more numerous. They are of the low columnar type, often pyramidal with apices directed toward the lumen. Their bases rest either on the basement membrane or against the parietal cells. The appearance which these cells present

depends upon their functional condition (p. 277). They usually appear clear and granular and take a light stain.

The *parietal cells* (Fig. 157), are oval or polygonal in shape, and lie here and there against the basement membrane. The nucleus is spherical, somewhat larger than that of the chief cell, and is usually situated at the center of the cell. There may be two nuclei. The protoplasm is finely granular and in the fresh unstained condition appears clearer than that of the chief cells. The parietal cells stain intensely with the aniline dyes with the result that in

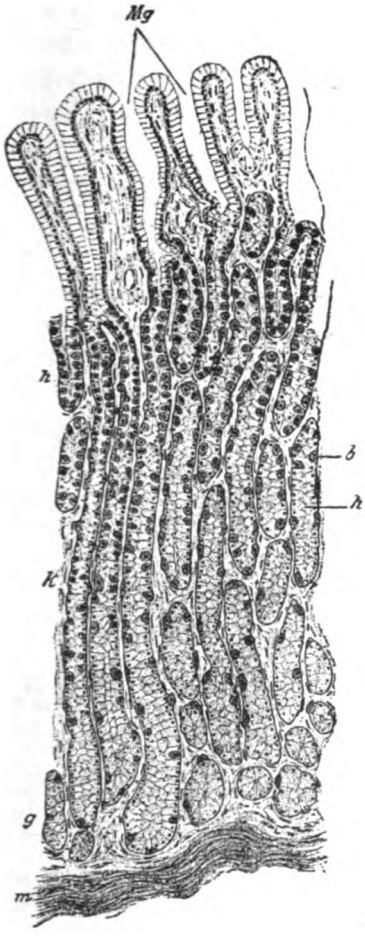

FIG. 156.

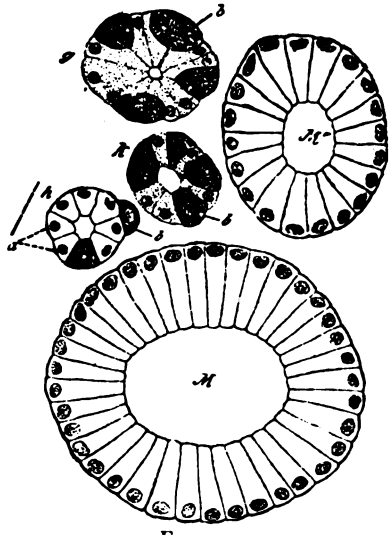

FIG. 157.

FIG. 156.—Vertical Section through the Mucous Membrane of the Fundus of the Stomach. ×85. (Kölliker.) *Mg*, Gastric pits; *h*, neck; *k*, body; *g*, fundus of peptic glands; *h*, chief cells; *b*, parietal cells; *m*, muscularis mucosæ.

FIG. 157.—Cross-sections at Various Levels of Peptic Glands of Stomach. ×400. (Kölliker.) *M*, Section through gastric pit near surface; *M'*, section through gastric pit near bottom; *h*, mouth of gland; *k*, neck; *g*, body near fundus; *a*, chief cells; *b*, parietal cells.

stained specimens the two kinds of cells are in marked contrast, the parietal cells being much darker than the chief cells. Although lying against the basement membrane and frequently pushing it out so as to form little protuberances beyond the even line of the gland tubule,

the parietal cells always maintain a connection with the lumen. This is accomplished by means of little clefts between the chief cells, *intercellular secretory tubules*, which extend down to the parietal cells. By means of the method of Golgi may be demonstrated not only the intercellular secretory tubules, but also the fact that upon reaching the cells these are continuous with a network of minute spaces within the cell—the *intracellular secretory tubules* (Figs. 158 and 159). Parietal

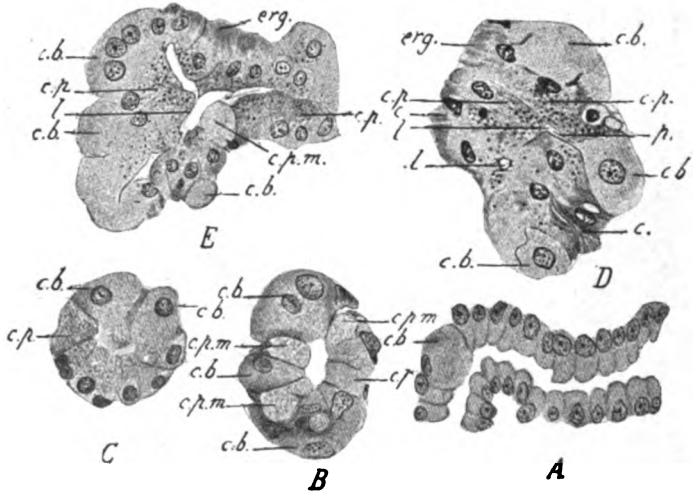

FIG. 158.—Sections through Different Parts of a Fundus Gland of Human Stomach.

A, mouth of gland; cells resemble surface cells except that they are shorter.

B, neck of gland; *cp*, principal cells; *cpm*, mucous cells; *cb*, parietal cells, one containing two nuclei.

C, middle portion of gland; *cp*, chief cells; *cb*, parietal cells.

D, deeper part of gland; *cp*, chief cells containing secretory granules, and at their bases ergastoplasm filaments (*erg*): at *c* are shown intracellular secretory canals penetrating base of cell; *cb*, parietal cells, one of which shows canaliculus leading to lumen of gland (1), the latter being cut twice in section owing to its irregular course.

E, blind end of gland; *cp*, chief cells with secretion granules and ergastoplasm filaments (*erg*); *cb*, parietal cells, one containing three nuclei; *cpm*, mucous cells; *l*, lumen of gland. ×250. (Prenant.)

cells are not distributed uniformly throughout the gland, but are most numerous in the body, where they frequently almost obscure the chief cells. In the fundus of the gland parietal cells are less numerous. For this reason and because of the wider lumen of the fundus, transverse and longitudinal sections of this part of the tubule are most satisfactory for the study of the relations of the two kinds of cells (Figs. 156 and 157). Mitosis is most active at the junction of the neck and body of the tubule which has consequently been designated the "growing point" of the tubule.

Lying near the basement membrane among the bases of the columnar epithelial cells are small spherical or irregular cells with dark nuclei. These are young epithelial cells which from their function are known as "replacing cells" (see page 75).

The PYLORIC GLANDS (Figs. 160 and 161) are simple branched tubular glands, several of which open into each of the *deep pyloric pits*. These pits occupy a much greater proportion of the thickness of the mucous membrane than do the pits of the fundus glands (compare Figs. 156 and 160) and the proportionate depth occupied by the glands themselves is correspondingly less. The pyloric glands, though short, are quite tortuous, so that in sections the tubules are seen cut mainly transversely or obliquely. In most of the pyloric glands but one type of cell is found. These resemble the chief cells of the fundus, but present a more uniform appearance, probably due to the absence of parietal cells. As in the fundus, "replacing cells" lie between the bases of the columnar epithelial cells. Parietal cells are not always entirely absent, but occur here and there in the pyloric tubules, especially near the fundus.

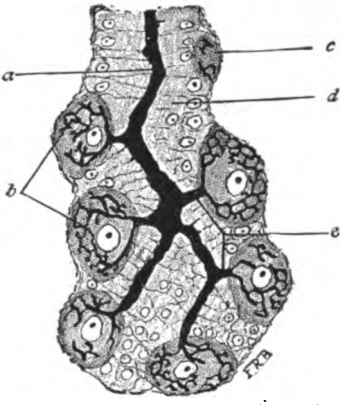

FIG. 159.—Longitudinal Section of Fundus of Gland from Pyloric End of Dog's Stomach. (Golgi method. See 5, p. 29.) *a*, Lumen of gland; *b*, intracellular canals in parietal cells; *c*, cut-off portion of parietal cell; *d*, chief cells; *e*, intercellular canals leading from lumen of gland to canals in parietal cells.

The transition from fundus to pylorus is not abrupt, but is marked by a "transitional border zone," in which fundus and pyloric glands are intermingled, and in which are also found single glands which resemble in structure both fundus and pyloric.

In the transition zone between œsophagus and stomach are found glands which resemble those found in the lower end of the œsophagus (p. 249). Their cells are clear resembling those of the pyloric glands. On account of their location they have been designated *cardiac glands*. Those nearest the œsophagus are lined with clear cells and resemble closely the pyloric glands. As one passes further from the œsophageal junction, cells with coarse granules begin to make their appearance among the clear cells and, assuming the character of parietal cells, become more and more numerous, the glands thus passing over by gradual transition into typical fundus glands. There

are also found in the stomach glands which are apparently identical in structure with those of the intestine (p. 265). Most of these resemble the glands of Lieberkühn and are distributed in small groups mainly in the pylorus and lesser curvature. Glands resembling Brunner's glands have also been described.

The STROMA (Figs. 156 and 160) or TUNICA PROPRIA, in which the glands are embedded, consists of mixed fibrillar and reticular connective

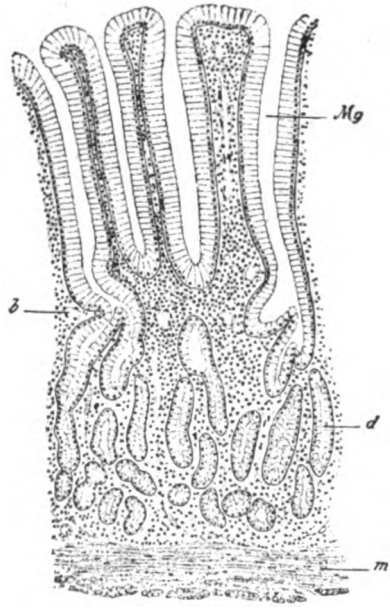

FIG. 160.

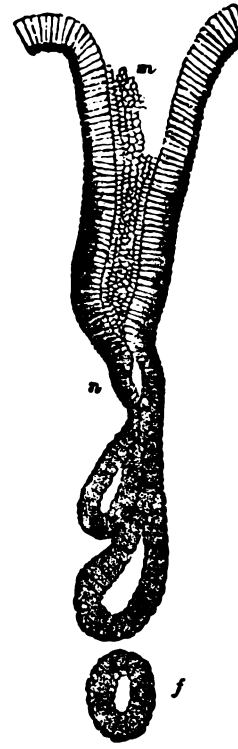

FIG. 161.

FIG. 160.—Vertical Section through Mucous Membrane of Pyloric End of Stomach. ×85. (Kölliker.) *Mg*, Gastric pit; *b*, blood-vessel in stroma; *d*, longitudinal section of body of gland; *m*, muscularis mucosæ.

FIG. 161.—Pyloric Gland from Vertical Section through Wall of Dog's Stomach. (Ebstein.) *m*, Gastric pit in which are seen some transversely cut cells; *n*, neck of gland; *f*, fundus cut transversely.

tissue infiltrated with lymphoid cells. In the fundus of the stomach the glands are so closely packed that the stroma is reduced to thin strands, which pass up between the glands and also separate them from the muscularis mucosæ. In the pylorus the glands are more widely separated and the stroma is correspondingly greater in amount.

In both fundus and pylorus thicker strands of stroma surround a number of gland tubules, thus separating them into more or less well-defined groups. In addition to the diffuse lymphatic tissue of the stroma, closely packed aggregations of lymphoid cells are found in the shape of distinct nodules, known as "*solitary follicles*." These occur throughout the entire gastric mucosa, but are most numerous in the pylorus. The nodules are usually egg-shaped, their apices lying just beneath the epithelium, their bases resting upon the muscularis mucosæ. Less commonly they lie partly in the submucosa. Over the nodules the epithelium is more or less infiltrated with migratory leucocytes. Most of the nodules contain germinal centres around which the lymphoid cells are more closely packed than elsewhere (see page 173).

The MUSCULARIS MUCOSÆ (Figs. 156 and 160, *m*) may consist of a single *layer* of *smooth muscle* with cells arranged longitudinally or obliquely, or there may be two distinct layers, an *inner circular* and an *outer longitudinal*. From the muscularis mucosæ single cells and groups of cells extend into the stroma between the gland tubules.

2. **The submucosa** consists of connective tissue, loosely arranged, many elastic fibres, and some fat. It contains the larger blood-vessels and nerves, including the plexus of Meissner (p. 276).

3. **The muscular coat** is usually described as consisting of three layers, an *inner oblique*, a *middle circular*, and an *outer longitudinal*.

In the fundus the muscle bundles run in various directions, so that the division of the muscular coat into layers having definite directions can be made out only in the pylorus. Here the inner and middle layers are thickened to form the sphincter pylori. In the connective tissue which separates the groups of muscle cells are collections of sympathetic nerve cells and fibres, which while much less distinct, are analogous to Auerbach's plexus of the intestine.

4. **The serous coat** consists of a layer of loosely arranged connective tissue covered by a single layer of mesothelium.

TECHNIC

(1) Remove a human stomach (not more than two or three hours after death) or that of a recently killed dog. Open along the lesser curvature, and carefully remove the excess of mucus by washing with normal saline. Cut pieces through the entire thickness of the wall, one from the fundus and one from the pylorus; pin out, mucous membrane side up, on pieces of cork, fix in formalin-Müller's fluid (technic 6, p. 7) or in Zenker's fluid (technic 10, p. 8), and harden in alcohol. Sections are cut as thin as possible, care being taken that the plane is such that

the glands are cut longitudinally, stained with hæmatoxylin-eosin (technic 1, p. 23), and mounted in balsam.

(2) Instead of removing pieces of stomach and pinning them out on cork, as suggested in the preceding technic, the entire stomach may be filled with the fixative, the ends being tied, and then placed in a large quantity of the fixing fluid. After fixation, pieces are removed and hardened in graded alcohols. If this method is used, great care must be taken not to overdistend the organ, only very moderate distention being desirable. Further treatment is the same as in the preceding technic (1).

(3) For comparison of resting with active gastric cells, preparations should be made from the stomach of an animal that has been for from twenty-four to forty-eight hours without food, and from a stomach during active digestion. Fix in Zenker's fluid as in technic 1, p. 259. Examine unstained sections and sections stained with hæmatoxylin-eosin.

(4) Sections through the junction of œsophagus and stomach and through the junction of stomach and duodenum furnish instructive pictures. They should be prepared as in technic 1, p. 259.

(5) For the study of the distribution of the blood-vessels sections of an injected stomach should be made. This is best accomplished by selecting a small animal, such as a rat or guinea-pig, and injecting *in toto* through the ascending aorta, or by injecting only the hind part of the animal through the abdominal aorta. Technic, p. 12.

III. THE MIDGUT

The Small Intestine

On passing from stomach to small intestine the rugæ of the former disappear, but are replaced by much more definite foldings of the mucosa, the *valvulæ conniventes* (Fig. 163). These folds involve the entire thickness of the mucous membrane and part of the submucosa. They are in general parallel to one another, and pass in a circular or oblique manner, partly around the lumen of the gut. The entire surface of the intestine, including the valvulæ, is studded with minute projections just visible to the naked eye, and known as *villi* (Figs. 164 and 165). These involve only the epithelium and stroma, although they also contain some muscular elements derived from the muscularis mucosæ. The villi differ in shape in the different parts of the small intestine, being leaf-shaped in the duodenum, rounded in the jejunum, club-shaped in the ileum. The valvulæ conniventes and the villi are characteristic of the small intestine. It is important to note that while the pits of the stomach are *depressions in* the mucous membrane, the intestinal villi are definite *projections above* its general surface (Fig. 162).

The wall of the intestine consists of the same four coats described

as constituting the wall of the stomach, *mucosa*, *submucosa*, *muscularis*, and *serosa*.

1. **The mucosa,** as in the stomach, is composed of a lining *epithelium*, *stroma*, *glands*, and *muscularis mucosæ*. Of these, the epithelium, the stroma, and cells from the muscularis mucosæ, are concerned in the formation of the villi.

The VILLUS consists of a *central core*—a fold of the stroma—of mixed fibrous and reticular tissue infiltrated with lymphoid cells, and of a covering *epithelium*.

The *epithelium* is disposed in a single layer, separated from the underlying connective tissue by a basement membrane. It consists of

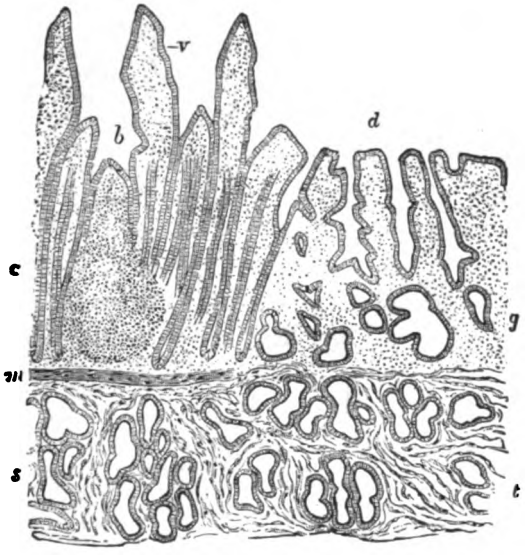

FIG. 162.—Section through Junction of Pylorus and Duodenum. (Klein.) *V*, Villi of duodenum; *d*, stomach, showing gastric pits; *b*, apex of a solitary lymph nodule; *c*, crypt of Lieberkühn; *s*, secreting tubules of Brunner's glands; *g*, pyloric glands; *t*, tubules of Brunner's glands in submucosa of stomach; *m*, muscularis mucosæ.

two apparently quite different kinds of cells, *columnar cells* and *goblet* or *mucous cells*. The former are the more numerous and are peculiar to the intestine, while the mucous cells are identical with those found in other mucous membranes. The columnar cells are quite elastic and while generally long and narrow, vary as to length and breadth as they adapt themselves to movements of the intestine. Their protoplasm is finely granular, its appearance depending somewhat on the activity of secretion and absorption. It frequently contains fat droplets. The nucleus is void and is usually situated in the basal third

of the cell. A peculiarity of these cells is the *striated free border*, contiguous free borders uniting to form the so-called *cuticular membrane* (Fig. 167, *c*). By means of special technic these striations can be resolved into delicate parallel lying rods or fibrils. They have been interpreted by some as marking channels through the cuticle, by others as a fibrillar arrangement of the protoplasm. Scattered among the columnar cells are *mucous* or *goblet cells* (Figs. 166 and 167, *b*). These vary in appearance according to the amount of secretion which they contain. A cell at the beginning of secretion contains only a small amount of mucus near its free border. As secretion increases the

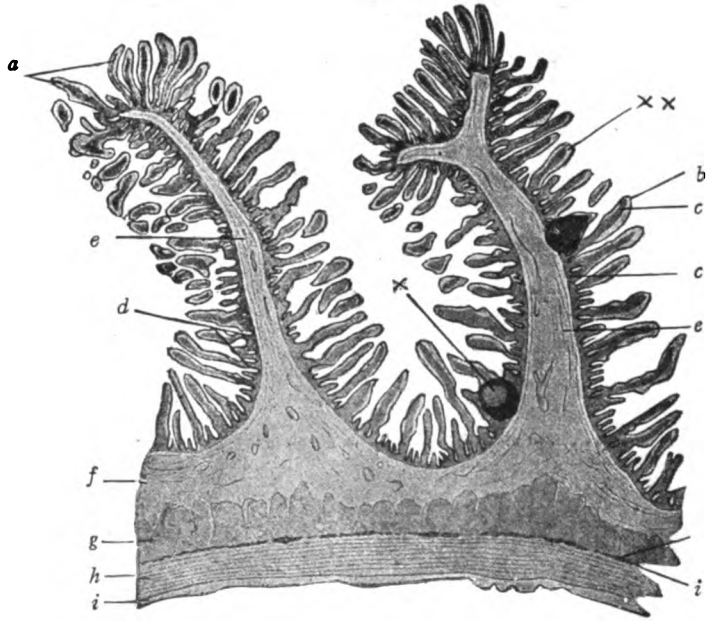

FIG. 163.—Vertical Longitudinal Section of Human Jejunum (×16) (Stöhr), including two valvulæ conniventes. *a*, Villi, in many of which the stroma has shrunken away from the epithelium leaving a clear space, ××. Lying free in the lumen of the gut are seen sections of villi cut in various directions. *b*, Epithelium; *c*, stroma; *d*, crypts of Lieberkühn; ×, solitary lymph nodule with germinal centre; *e*, tissue of submucosa forming centre of one of the valvulæ conniventes; *f*, submucosa; *g*, inner circular layer of muscle; *h*, outer longitudinal layer of muscle; *i*, Auerbach's plexus; *j*, serous coat.

mucus gradually replaces the cytoplasm until the latter is represented only by a crescentic mass containing a flattened nucleus and pressed against the basement membrane. The cell now discharges its mucus upon the free surface. The goblet cells possess no thickened border, appearing, when seen from the surface, as openings surrounded on all sides by the cuticulæ of the adjacent columnar cells. Opinions

differ as to the relation of the mucous to the columnar cell. Some authorities consider them two different and independent cells. The majority, however, look upon the mucous cell as a specialization of the

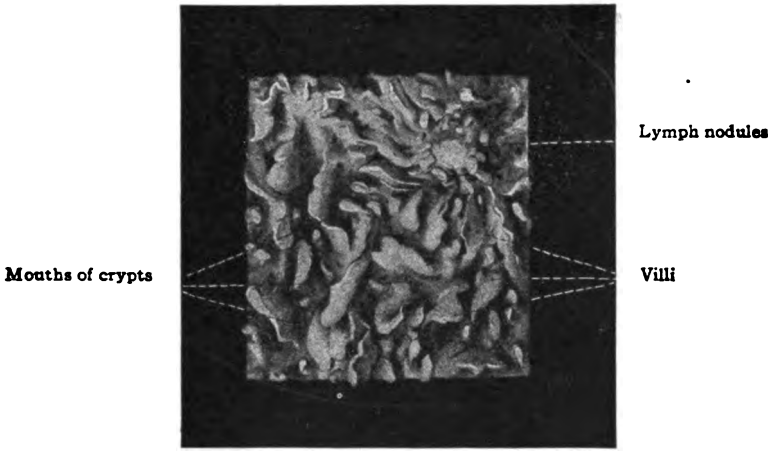

FIG. 164.—Surface View of Small Intestine near upper end, showing villi and one solitary lymph nodule. ×12. (Spalteholz.)

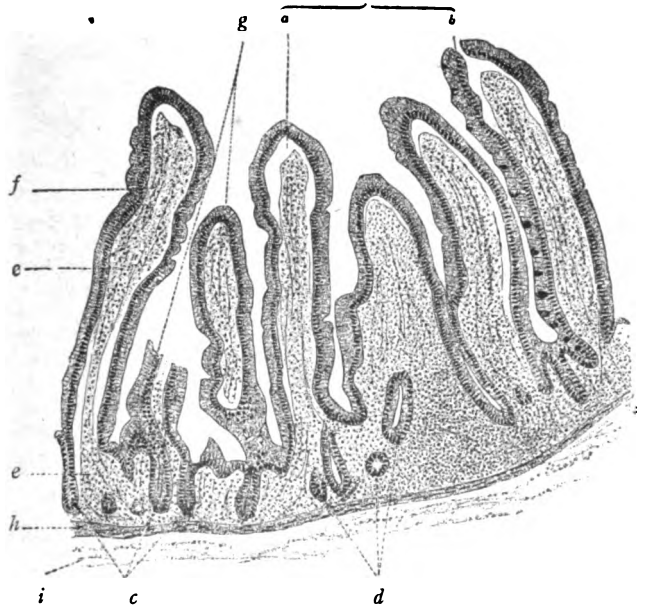

FIG. 165.—Vertical Section through Mucous Membrane of Human Jejunum. ×80. (Stöhr.) *a* and *b*, Artifacts due to shrinkage; *c*, intestinal crypts (Lieberkühn); *d*, obique and transverse sections of crypts; *e*, stroma; *f*, epithelium; *g*, tangentially cut villi; *h*, muscularis mucosæ; *i*, submucosa.

columnar cell, the younger cells being indifferent as it were and able to become columnar cells or goblet cells as conditions may require. Again opinions differ as to whether the mucous cell, having discharged its secretion, dies or re-secretes, or returns to the condition of the columnar cell. Small spherical cells with deeply staining nuclei are found in varying numbers among and sometimes within the epithelial cells.[1] These are so-called *wandering cells*, *migratory*

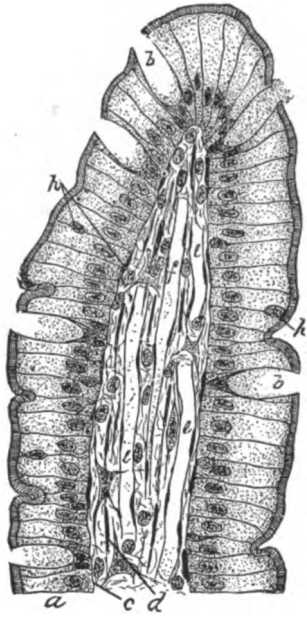

FIG. 166.

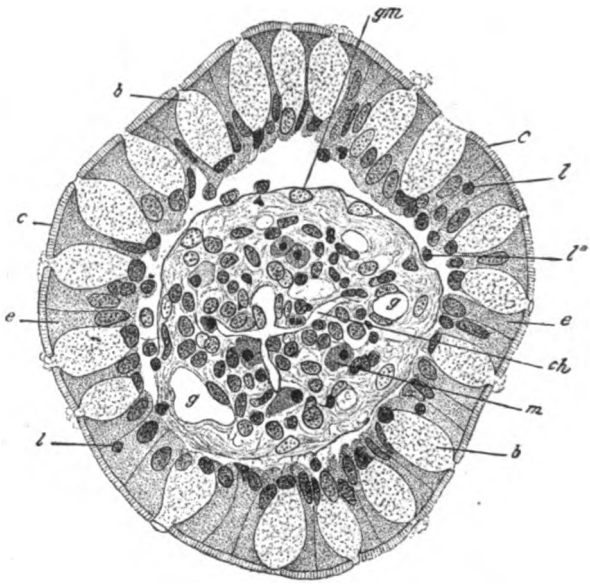

FIG. 167.

FIG. 166.—Longitudinal Section of Villus from Small Intestine of Dog. (Piersol.) *a*, Columnar epithelium; *b*, goblet cells; *h*, leucocytes; *c*, basement membrane; *d*, core of villus; *e*, blood-vessels; *f*, lacteal.

FIG. 167.—Cross-section of a Villus of Human Small Intestine. ×530. (Kölliker.) The stroma of the villus has shrunken away from the epithelium. *b*, Goblet cell; *c*, cuticula showing striations; *e*, columnar epithelial cell; *gm*, basement membrane with nuclei; *l*, leucocyte in epithelium; *l'*, leucocyte just beneath epithelium; *m*, large leucocyte in stroma; *ch*, central chyle vessel; *g*, blood-vessel.

leucocytes, from the underlying stroma (Figs. 166, *h*, and 167, *l*). Other cells with dark-staining nuclei, "*replacing cells*," are found between the bases of the columnar cells (pages 75 and 257).

In addition to the connective-tissue and lymphoid cells, which constitute the main bulk of the villus core (Figs. 166 and 167), isolated smooth muscle cells derived from the muscularis mucosæ occur,

[1] Davidoff considers these cells leucocytes in process of formation. He describes some of the columnar cells as having two nuclei, one of which remains within the cell, while the other is extruded with a little cytoplasm as a leucocyte.

running in the long axis of the villus. A single lymph or chyle vessel (Figs. 166, *f*; 167, *ch*) with distinct endothelial walls traverses the centre of each villus, ending at its tip in a slightly dilated blind extremity. As it is usually seen collapsed, it appears as two closely approximated rows of flat cells with bulging nuclei. The capillaries of the villus lie for the most part away from the chyle vessel, just beneath the basement membrane (Figs. 166, *e*; 167, *g*).

From the depths of the depressions between the villi, simple tubular glands —glands or crypts of Lieberkühn (Figs. 165 and 168)—extend down through the stroma as far as the muscularis mucosæ. These crypts are lined with an epithelium similar to and continuous with that covering the villi. The cells are, however, lower, have no striated borders, and there are fewer goblet cells. In addition to these cells there are also found in the depths of the crypts of Lieberkühn peculiar coarsely granular cells, the cells of Paneth (Fig. 168, *k*). They are found in man and in rodents, but do not occur in the carnivora. They probably produce a specific secretion, the nature of which is unknown. Two other types of cells have been recently described as occurring among the cells covering the villi and lining the crypts, (*a*) chromafin cells containing yellowish granules and (*b*) finely granular acidophile cells. Their origin and function are unknown. In contrast with the stomach, where most active mitosis is at the junction of the neck and body of the gland (page 256), the most active cell proliferation in the intestinal epithelium is at the bottoms of the crypts whence the cells are gradually pushed toward the surface. the oldest cells thus being found at the crests of the villi.

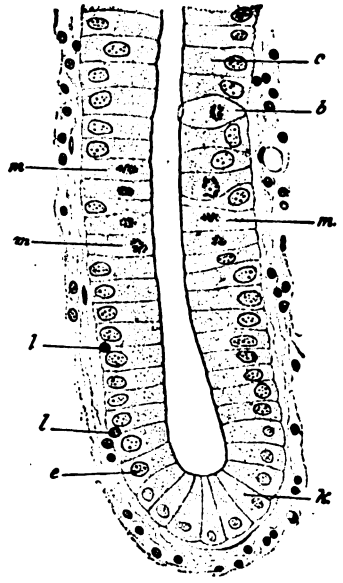

FIG. 168.—Longitudinal Section of Fundus of Crypt of Lieberkühn. ×530. (Kölliker.) *b*, Goblet cell showing mitosis; *e*, epithelial cell; *k*, cell of Paneth; *l*, leucocyte in epithelium; *m*, mitosis in epithelial cell. Surrounding the crypt is seen the stroma of the mucous membrane.

The *stroma*, besides forming the centres of the villi, fills in the spaces between the crypts of Lieberkühn and between the latter and

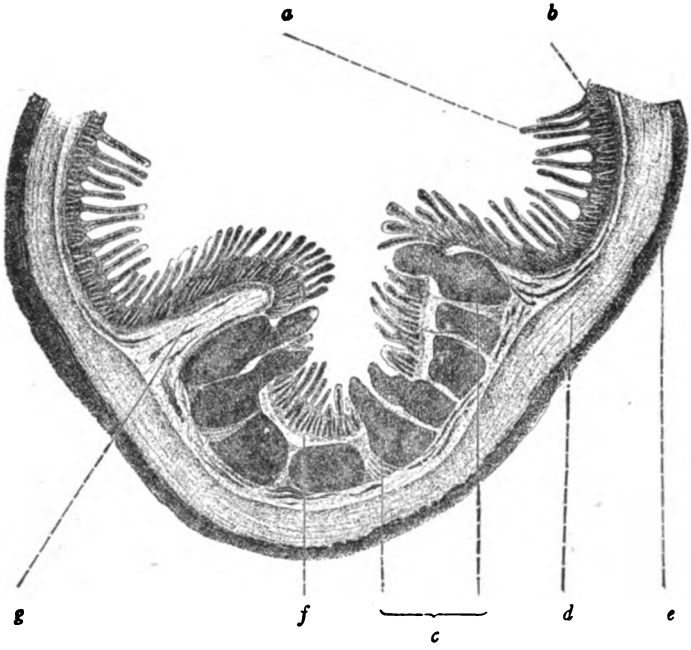

FIG. 169.—Transverse Section of Cat's Small Intestine through a Peyer's Patch. (Stöhr.) *a*, Villi; *b*, crypts; *c*, lymph nodules; *d*, circular muscle layer; *e*, longitudinal muscle layer; *f*, muscularis mucosæ; *g*, submucosa.



FIG. 170.—Surface View of Mucous Membrane of Small Intestine (Ileum), showing Peyer's patch (Spalteholz).

the muscularis mucosæ. It is composed of reticular tissue and delicate fibrillar connective tissue with a considerable number of elastic fibrils. Everywhere lymphocytes are abundant and in many places so numerous as to give the appearance of diffuse lymphoid tissue. Here and there the lymphoid cells are more closely packed together to form distinct lymph nodules. These are known as solitary follicles to distinguish them from groups of lymph nodules which occur in this part of the intestine and are known as Peyer's patches (see below). Solitary follicles are much more numerous in the small intestine than in the stomach. They are identical with the stomach follicles in structure (p. 259). Most of the follicles are ovoid, their long diameter corresponding to that of the intestine. They appear first in the stroma and for a time lie wholly within this layer of the intestinal wall. As a follicle however, increases in size it grows downward through the muscularis mucosæ into the submucosa. In the loose tissue of this layer the follicle expands freely and usually evenly in all directions. The result is that portion of the follicle within the submucosa is usually spherical in shape and ultimately becomes larger than the portion in the stroma. This gives to the whole follicle a somewhat pear shape, the smaller end lying against the surface epithelium.

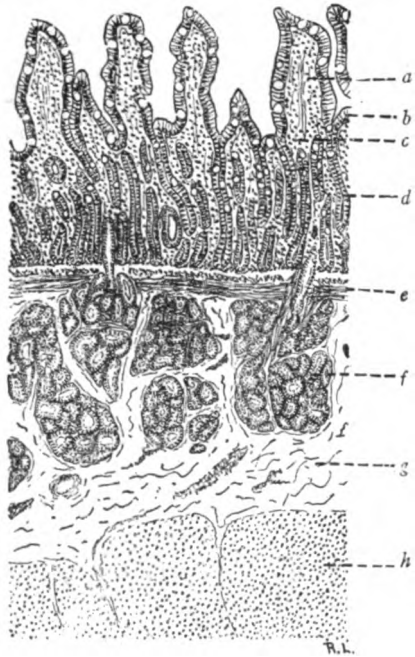

FIG. 171.—From Vertical Longitudinal Section of Cat's Duodenum to show Brunner's Glands. (Larrabee.) *a*, Villus; *b*, epithelium; *c*, stroma; *d*, glands; *e*, muscularis mucosæ; *f*, Brunner's glands; *g*, submucosa; *h*, circular muscle layer.

PEYER'S PATCHES (agminated follicles) (Fig. 176).—These are aggregations of solitary follicles or groups of lymph nodules found mainly in the ileum, especially near its junction with the jejunum. They always occur on the side of the gut opposite the attachment of the mesentery. Each patch consists of from ten to seventy nodules,

so arranged that the entire patch has a generally oval shape, its long diameter lying lengthwise of the intestine. The nodules of which a patch is composed lie side by side, never one over another. Their apices are directed toward the lumen and project almost through the mucosa, being uncovered by villi, a single layer of columnar epithelium alone separating their surfaces from the lumen

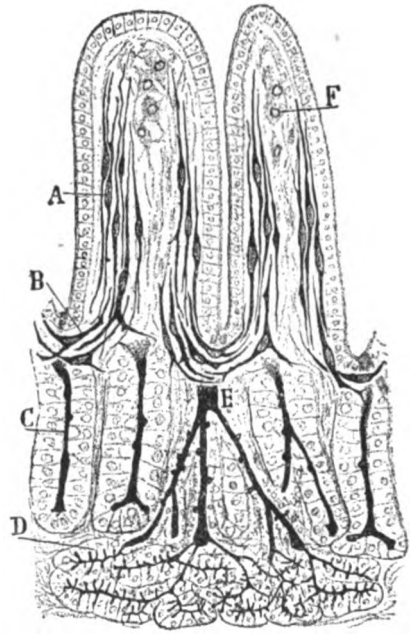

FIG. 171a.—Section through mucous and submucous layers of wall of small intestine of young guinea pig (Cajal). Chrome-silver impregnation. Gland ducts filled with black silver precipitate. A and B, smooth muscle cells of body and base of villus. C, lumen of crypt of Lieberkuhn; D, terminal tubules of Brunner's gland; E, ducts of Brunner's gland; F, sympathetic nerve cells of apex of villus.

of the gut. The bases of the nodules are not confined to the stroma, but usually spread out in the submucosa. The relation of the patch to the stroma and submucosa can be best appreciated by following the course of the muscularis mucosæ. This is seen to stop abruptly at the circumference of the patch, appearing throughout the patch as isolated groups of smooth muscle cells. Sometimes the individual nodules which make up a Peyer's patch are quite

discreet and well outlined. More frequently however the nodules tend to coalesce except at their apices, so that the individual nodules can rarely be definitely outlined except at their apices and to some extent by their germinal centers. It should be noted that both solitary nodules and Peyer's patches are structures of the mucosa, and that their presence in the submucosa is secondary.

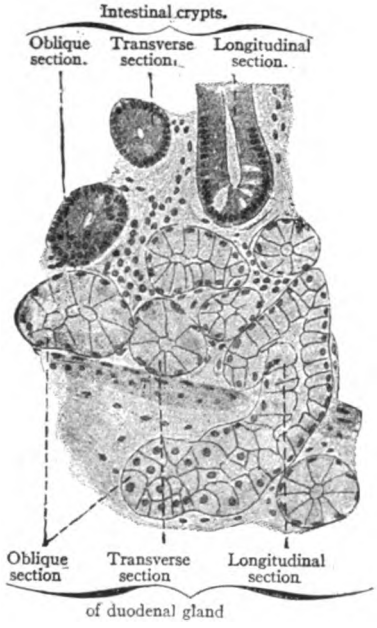

FIG. 171*b*.—Section from human duodenum × 240. (Stöhr.) Only lower portion of mucosa and adjacent portion of submucosa are shown.

THE MUSCULARIS MUCOSÆ (Figs. 165 and 171) consists of an inner circular and an outer longitudinal layer of smooth muscle.

2. **The submucosa** (Figs. 163, 165, 171) consists, as in the stomach, of loosely arranged connective tissue and contains the larger blood-vessels. It is free from glands except in the duodenum, where it contains the *glands* of *Brunner* (Fig. 171). These are branched tubular glands lined with a granular columnar epithelium similar to that of the pyloric glands. The ducts are also lined with simple columnar epithelium. They pass through the

muscularis mucosæ and empty either into a crypt of Lieberkühn or on the surface between the villi. Brunner's glands frequently occur in the pylorus, and it is not uncommon for the pyloric glands to extend downward somewhat into the duodenum. *Meissner's plexus* of nerve fibres, mingled with groups of sympathetic ganglion cells, lies in the sub-mucosa (see page 276).

3. **The muscular coat** (Figs. 163 and 171) consists of two well-defined layers of smooth muscle, an inner circular and an outer longitudinal. Connective-tissue septa divide the muscle cells into groups or bundles, while between the two layers of muscle is a connective-tissue septum which varies greatly in thickness at different places and contains a plexus of nerve fibres and sympathetic ganglion cells known as the plexus of Auerbach (see page 276).

4. **The serous coat** consists as in the stomach of loose connective tissue covered by a single layer of mesothelium.

IV. THE ENDGUT

The Large Intestine

The wall of the large intestine consists of the same four coats which have been described as constituting the walls of the stomach and small intestine, *mucous*, *submucous*, *muscular*, and *serous*.

1. **The mucous membrane** has a comparatively smooth surface, there being neither pits as in the stomach nor villi as in the small intestine (Fig. 172). The glands are of the simple tubular variety, are considerably longer than those of the small intestine, are almost straight, and extend through the entire thickness of the stroma. Owing to the closeness with which the gland tubules are packed, the amount of stroma is usually small. The surface cells (Fig. 172, *a*) are very high and narrow, with small, deeply placed nuclei, and are not usually intermingled with goblet cells. Passing from the surface down into the glands, the cells become somewhat lower and goblet cells become numerous (Fig. 173, *a* and *d*). Both superficial and deep cells rest upon a *basement membrane* similar to that in the small intestine. The *stroma* also, though less in amount, is similar in structure to the stroma of the small intestine.

The MUSCULARIS MUCOSÆ (Fig. 173, *c*) consists of an inner circular and an outer longitudinal layer of smooth muscle.

2. **The submucosa** (Fig. 172, *e*) consists of loosely arranged connective tissue. It contains large blood-vessels and the nerve plexus

of Meissner (see page 276). Solitary lymph follicles occur throughout the mucous membrane of the large intestine. While properly considered as structures of the stroma from which they originate, the follicles lie mainly in the submucosa. (For details of structure see page 171.)

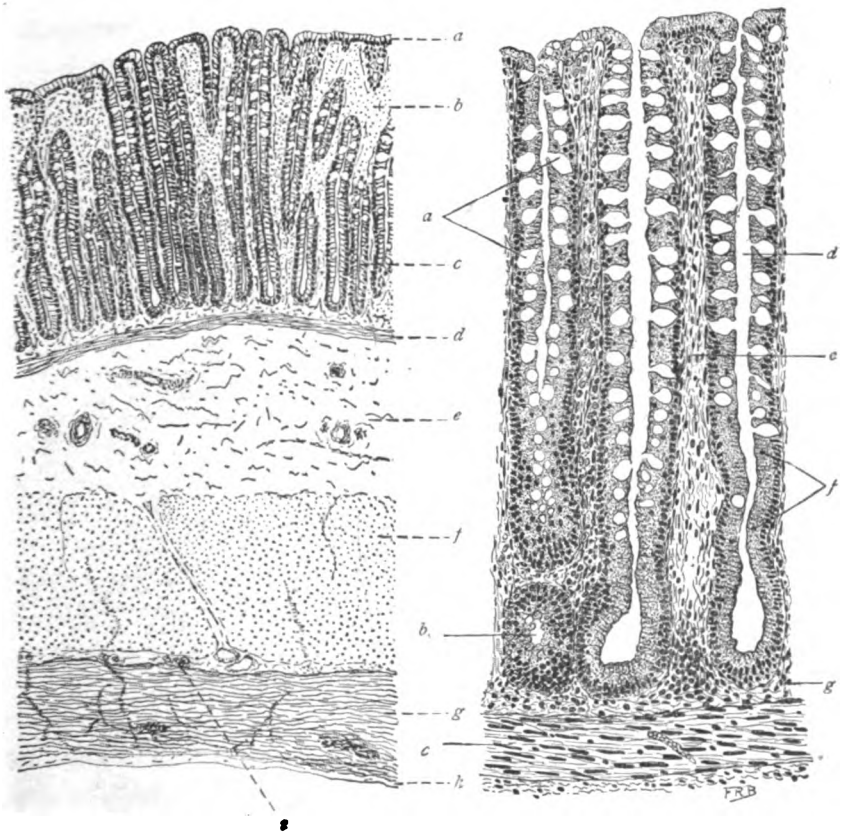

Fig. 172. Fig. 173.

FIG. 172.—From Vertical Longitudinal Section of Cat's Large Intestine. (Larrabee.) *a*, Epithelium; *b*, stroma; *c*, fundus of gland; *d*, muscularis mucosæ; *e*, submucosa; *f*, circular muscle layer; *g*, longitudinal muscle layer; *h*, serous coat; *i*, Auerbach's plexus.

FIG. 173.—From Vertical Longitudinal Section of the Mucous Membrane of the Human Large Intestine. (Technic 1, p. 280.) *a*, Mucous (goblet) cells; *b*, fundus of a gland cut obliquely; *c*, muscularis mucosæ; *d*, lumen of a gland cut longitudinally; *e*, stroma between the glands; *f*, leucocytes in the epithelium; *g*, stroma between fundi of glands and muscularis mucosæ.

3. **Of the muscularis** (Fig. 172) the inner circular layer only is complete, the muscle tissue of the external longitudinal coat being arranged mainly as three strong, flat, longitudinal bands, the lineæ coli. Between these bands the longitudinal muscular coat is either

very thin or entirely absent. In the connective tissue, lying to the outer side of the circular muscle coat, is the nerve plexus of Auerbach. (For details see page 276.)

4. **The serous coat** consists, as in the stomach and small intestine, of loose connective tissue covered by a single layer of mesothelium.

The Vermiform Appendix

The vermiform appendix is a diverticulum from the large intestine. Its walls are continuous with those of the latter, and closely

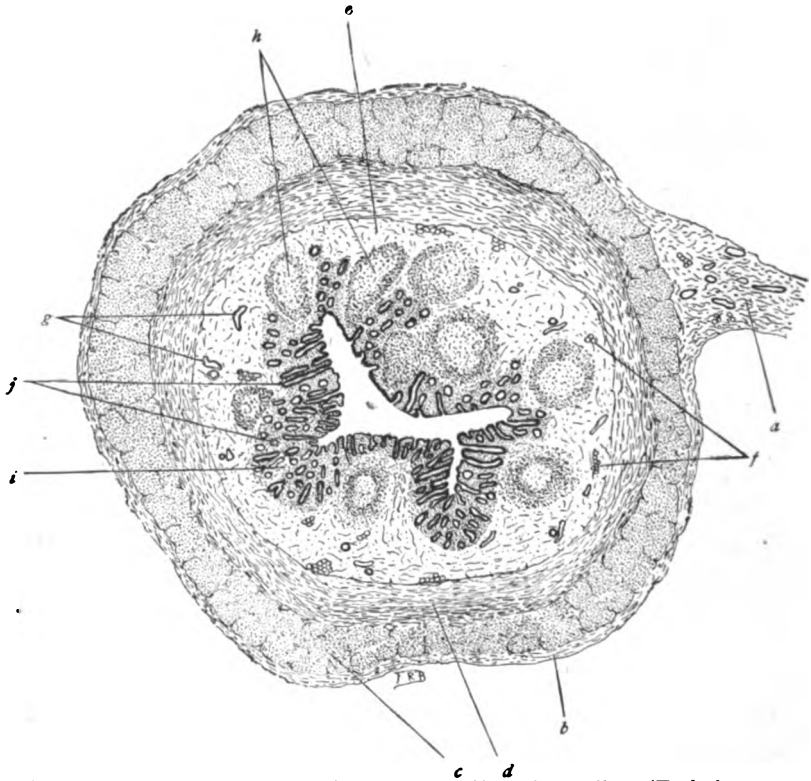

FIG. 174.—Transverse Section of Human Vermiform Appendix. (Technic 2, p. 280.) *a*, Mesoappendix; *b*, serous membrane (serosa); *c*, outer longitudinal muscle layer; *d*, inner circular muscle layer; *e*, submucosa; *f*, groups of fat cells in submucosa; *g*, blood-vessels in submucosa; *h*, lymph nodules; *i*, stroma; *j*, glands opening into lumen and cut in various planes; muscularis mucosæ not present.

resemble them in general structure. There are the same four coats, ***mucous***, ***submucous***, ***muscular***, and ***serous***.

1. **The mucous membrane** (Fig. 174) consists of epithelium, glands, stroma, and muscularis mucosæ. The ***epithelium*** resembles

that of the large intestine. The glands vary in number, but are usually much less closely packed than in the large intestine. They are most numerous in the appendices of infants and children. The *gland tubules* (Fig. 174, *j*) are usually rudimentary, but in most cases have the same structure as the intestinal glands, and are evidently functional as they contain mucous cells in all stages of secretion. In consequence of the wider separation of the tubules the *stroma* is more abundant than in the large intestine, but has the same structure. The *muscularis mucosæ* is usually fairly distinct as a thin circularly disposed band of smooth muscle cells just beneath the stroma. It is not always present. In some cases the mucosa as such is practically absent, being replaced by fibrous tissue. This condition is especially common after middle age, and may or may not be associated with obliteration of the lumen.

2. **The submucosa** (Fig. 174, *e*) is similar to that of the intestine.

3. **The muscular coat** varies greatly, both as to thickness and as to the amount of admixture of fibrous tissue. The inner circular layer (Fig. 174, *d*) is usually thick and well developed. The outer longitudinal layer (Fig. 174, *c*) differs from that of the large intestine in having no arrangement into lineæ, the muscle tissue forming a continuous layer. Less commonly a more or less marked tendency to an arrangement of the cells of the longitudinal coat into bundles, between which the outer coat is thin or wanting, is observed.

4. **The serosa** has the usual structure of peritoneum.

The lymph nodules (Fig. 174, *h*) constitute the most conspicuous feature of the appendix. They lie mainly in the submucosa. In children and young adults the nodules are oval or spherical; in later life somewhat flattened. The nodules may be entirely distinct, or may be arranged as in a Peyer's patch with distinct apices and bases, but with their central portions confluent. The muscularis mucosæ either passes through the superficial portions of the nodules, or, where they are separated from the lumen, passes over them.

The distribution of **blood-vessels, lymphatics,** and **nerves** is similar to that in the large intestine.

The Rectum

1. **The mucous membrane** of the rectum has a structure similar to that of the large intestine (Fig. 175). The glands are longer and the mucosa is consequently somewhat thicker. In the lower part of the rectum definite longitudinal foldings of the mucosa occur, the

so-called *columnæ rectales*. A change in the character of the mucous membrane begins at the upper end of the columnæ rectales. Here the simple columnar epithelium of the gut passes over into a stratified squamous epithelium, beneath which is a papillated stroma. The glands continue for a short distance beyond the change in the epithelium, but soon completely disappear. At the anus there is a transition from mucous membrane to skin similar to that described as occurring at the margin of the lips (page 225).

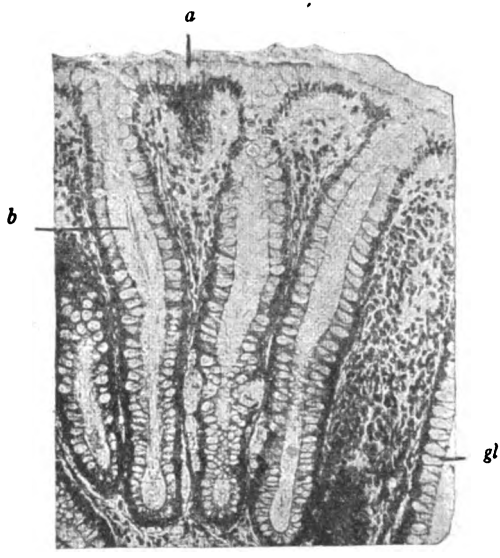

FIG. 175.—Mucous Membrane of Human Rectum. *a*, Superficial epithelium, composed almost wholly of mucous cells, the columnar cells lying between them being so compressed as to appear as thin dark lines; *gl*, lumen of gland of Lieberkühn. ×60. (Prenant.)

2. **The submucosa** is similar in structure to that of the large intestine.

The muscularis of the rectum differs from that of the large intestine in that the longitudinal layer is continuous and thick.

The serous coat is absent in the lower part of the rectum, being replaced by a fibrous connective-tissue layer, which connects the rectum with the surrounding structures.

The Peritoneum, Mesentery, and Omentum

The *peritoneum* (see also p. 169) is a serous membrane which lines the walls of the abdomen (parietal peritoneum) and is reflected over the contained viscera (visceral peritoneum). It consists of two

layers, a connective-tissue stroma and mesothelium. The stroma consists of loosely arranged connective-tissue bundles, which interlace in a plane parallel to the surface. There are numerous elastic fibres, especially in the deeper layer of the parietal peritoneum. There are comparatively few connective-tissue cells. The mesothelium consists of a single layer of flat polygonal cells with bulging nuclei. The cells have irregular wavy outlines, which are easily demonstrated with silver nitrate (Fig. 28). The shape of the cells varies considerably according to the direction in which the tissues are stretched. Over some parts, *e.g.*, the liver and intestine, the peritoneum or serosa is thin and very closely attached. In places where the peritoneum is freely movable, a considerable amount of loose connective tissue, rich in elastic fibres and containing varying numbers of fat cells, connects the peritoneum with the underlying tissue. This is known as the "*subserous tissue.*" The peritoneum is well supplied with blood-vessels and lymphatics. The former give rise to a rich capillary network.

The *mesentery* is a sheet of loosely arranged connective tissue covered with peritoneum. It is reflected from the post-abdominal wall to the viscera, and serves to carry to these organs their blood-vessels, lymphatics, and nerves. In the case of the stomach, duodenum, and large intestine, the mesentery is comparatively short, and the organs are therefore quite firmly fixed to the abdominal wall. In the case of the small intestine the mesentery is long and the intestine, therefore, freely movable. The mesentery is richly supplied with lymph nodes and there is usually a considerable amount of fat. From the mesentery, the peritoneum passes over to and envelops the viscera.

The *omentum* (Fig. 28) is a sheet of tissue which passes from the liver to the lesser curvature of the stomach (gastro-hepatic omentum) to which it is attached, and from the greater curvature of the stomach to the transverse colon (greater omentum). It is similar in structure to the mesentery, and contains usually much fat and many lymph nodes. Its connective-tissue bundles are arranged in networks, the strands and meshes of which vary greatly in size and shape. The strands are covered by a single layer of mesothelium.

Blood-Vessels of the Stomach and Intestines

The arteries reach the gastro-intestinal canal through the mesentery, give off small branches to the serosa, and pass through the muscular coats to the submucosa, where they form an extensive

plexus of large vessels (Heller's plexus) (Fig. 176, *c*). Within the muscular coats the main arteries give off small branches to the muscle tissue. From the plexus of the submucosa two main sets of vessels arise, one passing outward to supply the muscular coats, the other inward to supply the mucous membrane (Fig. 176). Of the former, the larger vessels pass directly to the intermuscular septum, where they form a plexus from which branches are given off to the

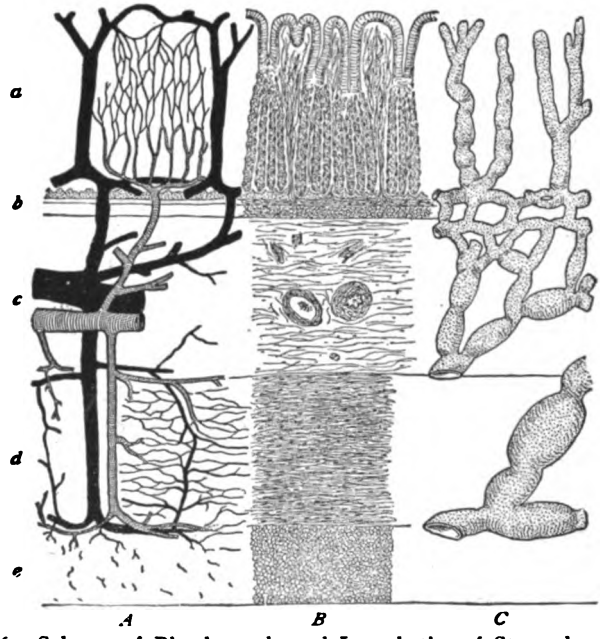

FIG. 176.—Scheme of Blood-vessels and Lymphatics of Stomach. ×70. (Szymonowicz, after Mall.) *a*, Mucous membrane; *b*, muscularis mucosæ; *c*, submucosa; *d*, inner circular muscle layer; *e*, outer longitudinal muscle layer; *A*, blood-vessels; *B*, structure of coats; *C*, lymphatics.

two muscular tunics. A few small branches from the larger recurrent vessels also supply the inner muscular layer. Of the branches of the submucosa plexus which pass to the mucous membrane, the shorter supply the muscularis mucosæ, while the longer branches* pierce the latter to form a capillary plexus among the glands of the stroma. These capillaries have a comparatively small diameter and are most numerous around the bodies and necks of the glands.

* Stöhr describes these small arterial branches to the stroma of the gastric mucosa as terminal or end-arteries each supplying a segment of mucosa from 1 to 2.5 m.m. in diameter. As the capillaries of one end-artery, do not anastomose with those of other end-arteries, any obstruction or destruction of one of these arteries results in death of the dependent area of mucosa.

They pass over into much larger capillaries which form a dense network just beneath the surface epithelium. From the capillaries small veins take origin which pierce the muscularis mucosæ and form a close-meshed venous plexus in the submucosa (Fig. 176). These in turn give rise to larger veins, which accompany the arteries into the mesentery.

In the small intestine the distribution of the blood-vessels is modified by the presence of the villi (Fig. 178). Each villus receives one small artery, or, in the case of the larger villi, two or three small arteries. The artery passes through the long axis of the villus close under the epithelium to its summit, giving off a network of fine capillaries, which for the most part lie just beneath the epithelium. From these, one or two small veins arise which lie on the opposite side of the villus from the artery.

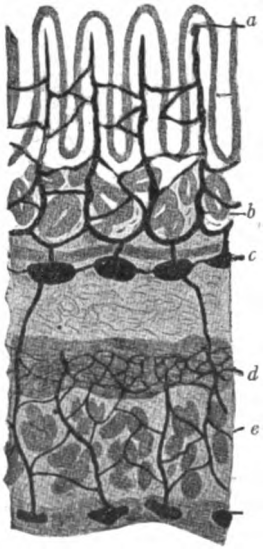

FIG. 177.—Diagram of wall of Stomach to show General Disposition of Lymphatics *a*, Terminal lymph channel in tissues separating glands; *b*, superficial lymphatic plexus in connective tissue surrounding bases of glands; *c*, submucous lymphatic plexus; *d*, intermuscular lymphatic plexus; *e*, subperitoneal lymphatic plexus. (Cuneo.)

LYMPHATICS OF THE STOMACH AND INTESTINE

Small lymph or chyle capillaries begin as blind canals in the stroma of the mucous membrane among the tubular glands (Fig. 176). In the small intestine a lymph (chyle) capillary occupies the centre of the long axis of each villus, ending in a blind extremity beneath the epithelium of its summit (Fig. 178). These vessels unite to form a narrow-meshed plexus of lymph capillaries in the deeper part of the stroma, lying parallel to the muscularis mucosæ. Vessels from this plexus pass through the muscularis mucosæ and form a wider meshed plexus of larger lymph vessels in the submucosa. A third lymphatic plexus lies in the connective tissue which separates the two layers of muscle. From the plexus in the submucosa, branches pass through the inner muscular layer, receive vessels from the intermuscular plexus, and then pierce the outer muscular layer to pass into the mesentery in company with the arteries and veins.

Nerves of the Stomach and Intestines

The nerves which supply the stomach and intestines are mainly non-medullated sympathetic fibres. They reach the intestinal walls through the mesentery. In the connective tissue between the two layers of muscle, these fibres are associated with groups of sympathetic ganglion cells to form the *plexus myentericus* or *plexus of Auerbach*. The dendrites of the ganglion cells interlace, forming a large part of the plexus. The axones are grouped together in small

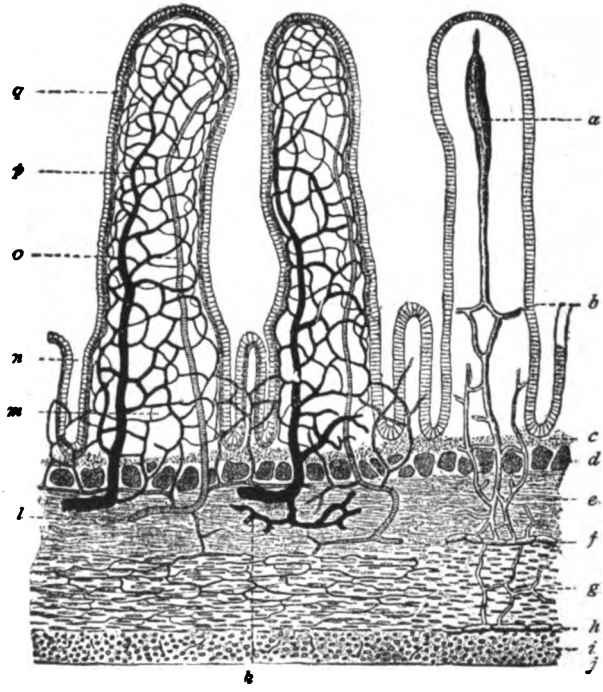

Fig. 178.—Scheme of Blood-vessels and Lymphatics of Human Small Intestine. (From Böhm and von Davidoff, after Mall.) *a*, Central lacteal of villus; *b*, lacteal; *c*, stroma; *d*, muscularis mucosæ; *e*, submucosa; *f*, plexus of lymph vessels; *g*, circular muscle layer; *h*, plexus of lymph vessels; *i*, longitudinal muscle layer; *j*, serous coat; *k*, vein; *l*, artery; *m*, base of villus; *n*, crypt; *o*, artery of villus; *p*, vein of villus; *q*, epithelium.

bundles of non-medullated fibres, which pass into the muscular coats, where they form intricate plexuses, from which are given off club-shaped terminals to the smooth muscle cells. From Auerbach's plexus fibres pass to the submucosa, where they form a similar but finer-meshed, more delicate plexus, also associated with groups of sympathetic ganglion cells, the *plexus of Meissner*. Both fibres and cells are smaller than those of Auerbach's plexus. From Meissner's

plexus delicate fibrils pass to their terminations in submucosa, muscularis mucosæ, and mucous membrane.

Secretion and Absorption

The secretory activities of epithelial cells have already been mentioned (page 217). The epithelium of the gastro-intestinal tract must be considered as having two main functions: (1) The *secretion* of substances necessary to digestion; and (2) the *absorption* of the products of digestion.

(1) Secretion.—The production of mucus takes place in the mucous or goblet cell, which is present throughout the gastro-enteric mucosa and, as already mentioned, probably represents a differentiation of the ordinary columnar epithelial cell. The chief cells, "peptic cells," of the stomach glands are comparatively clear during fasting, with development of ergastoplasm in their basal ends. With the onset of digestion these cells increase in size and become generally cloudy from development of granules with reduction of the ergastoplasm. These granules represent a pre-ferment or pepsinogen and with their discharge into the lumen of the gland, the cells again become smaller, clearer, and assume the resting condition. Bensley and Theohara have recently very clearly demonstrated the secretory chain in the chief cells from ergastoplasm or basal filaments through pepsinogen granules to pepsin. While some authorities still contend that a minor pepsin-forming rôle is played by the pyloric glands, the above facts together with the fact that activity of the chief cells (Fig. 180) is coincident with an increase in the pepsin found in the stomach, and that the amount of pepsinogen in the gastric mucosa is proportionate to the number of granules in the chief cells (Langley and Sewell), may be accepted as proving these cells the main if not the sole producers of pepsin, and the granules as some stage in the elaboration of the ferment. As their name of "acid cells"



Fig. 179.—Section through Glands of Fundus of Human Stomach in Condition of Hunger. ×500. (Böhm and von Davidoff.) *a*, Stroma; *b*, parietal cell; *c*, lumen; *d*, chief cell.

would indicate, the parietal cells have been considered the source of the hydrochloric acid of the stomach. While doubt still exists as to the function of these cells, recent investigations make it probable that they secrete substances which as chlorides are transformed into hydrochloric acid by the action of the carbonic acid of the blood. According to some authorities other cells assist in the production of the stomach acid. The cells of Brunner's glands undergo changes during digestion, which are somewhat similar to those described as occurring in the chief cells of the stomach glands. By some they are believed to be concerned in the production of pepsin, by others to play a special rôle in the secretion of one or more of the intestinal

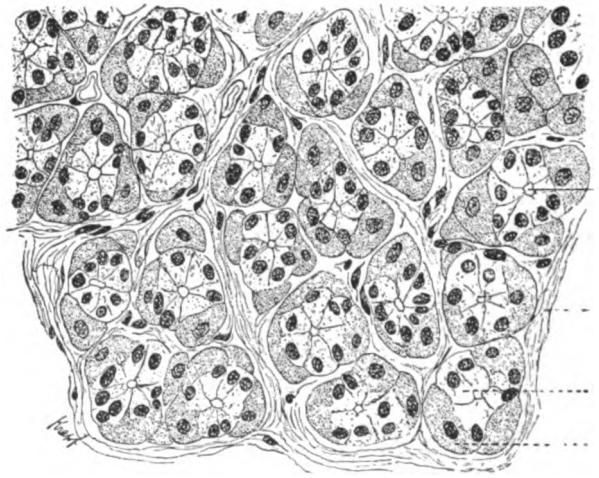

FIG. 180.—Section through Glands of Fundus of Human Stomach during Digestion. ×500. (Böhm and von Davidoff.) *a*, Lumen; *b*, stroma; *c*, chief cell; *d*, parietal cell.

ferments. The only function of the surface epithelium and of that of the intestinal crypts which has yet been determined is the secretion of mucus. The cells of Paneth are typical gland cells containing secretion granules and probably produce a specific secretion. (See also page 265.) Whether this secretion is the so-called "inverse ferment" or "*invertin*" which changes cane sugar into glucose and levulose or one of the other intestinal ferments has not been determined. It has been known that pancreatic fluid is inactive toward albuminoids unless mixed with intestinal secretions. This is due according to Pavlow to a special ferment "*enterokinase*." According to some this is a secretion of the epithelium, to others it is elaborated

by eosinophile leucocytes which pass through the intestinal wall, and become a part of the intestinal secretion.

(2) Absorption of Fat.—While various other products of digestion are absorbed by the intestine, the absorption of fat is the one most easily observed and the one of most interest from the histological

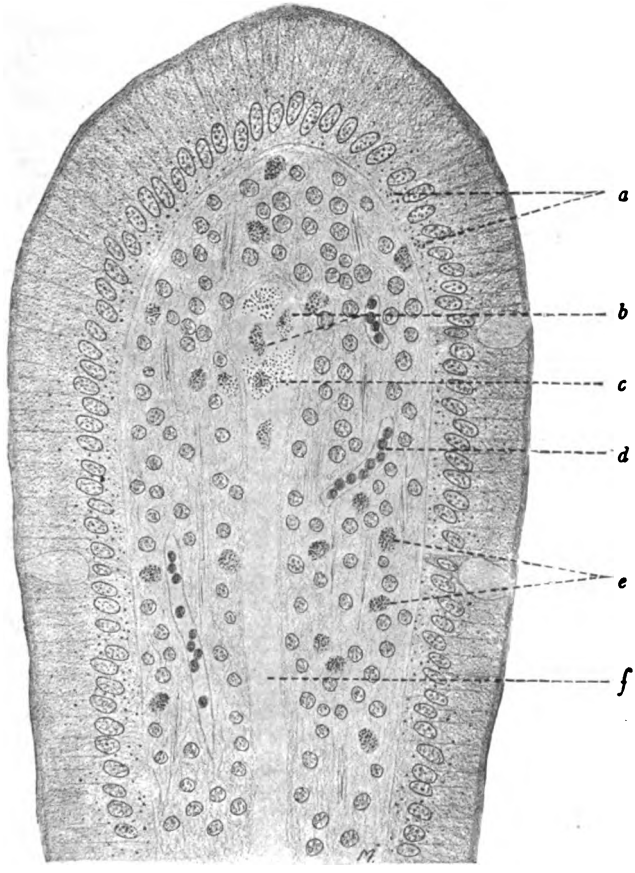

Fig. 181.—Fat Absorption. Longitudinal section of villus of cat's small intestine, three hours after feeding. ×350. Osmic acid. *a*, Fat droplets in epithelial cells; *b*, fat droplets in leucocytes in stroma; *c*, fat droplets in leucocytes within lacteal; *d*, fat droplets free in lacteal; *e*, capillary containing blood cells; *f*, central lacteal of villus.

standpoint because the passage of the droplets can be seen under the microscope. After feeding fat, fatty acids, or soaps, fat globules are found to have penetrated the intestinal mucosa, and may be seen in (*a*) the epithelial cells, (*b*) the leucocytes, and (*c*) the lacteals of the villi (Fig. 181). Fat globules are never seen in the thickened free borders of the cells. Hence it seems probable that the fat before

passing through this part of the cell becomes split up into glycerin and fatty acids which are united again to form fat within the protoplasm of the cell. Leucocytes containing fat globules are seen throughout the stroma. Within the lacteals are found fat-containing leucocytes and free fat droplets of various size. It would thus seem probable that the process of fat absorption consists in: (1) The passage of glycerin and fatty acids through the cell borders; (2) their reunion in the cell to form fat; (3) the transference of these fat globules to leucocytes; which (4) carry them to the lacteals. In the lacteals the fat is probably set free by disintegration of the leucocytes. Other fat droplets—perhaps the majority—pass from the epithelial cells into the lacteal without the aid of leucocytes, possibly assisted by contractions of the smooth muscle fibres.

TECHNIC

(1) The technic for the small and large intestines and rectum is the same as for the stomach. Accurate fixation of the villi is difficult, there being usually some shrinkage of the connective tissue of the core away from the epithelium.

A longitudinal section should be made through the junction of small and large intestine, showing the transition from the villus-covered surface of the former to the comparatively smooth surface of the latter.

To show Brunner's glands a section of the duodenum is required.

To show the varying shapes of the villi in the different regions, sections should also be made of the jejunum and ileum.

Solitary follicles may usually be seen in any of the above sections.

A small Peyer's patch, together with the entire thickness of the intestinal wall, should be removed, treated as above, stained with hæmatoxylin-eosin (technic 1, p. 23), or with hæmatoxylin-picro-acid-fuchsin (technic 3, p. 24), and mounted in balsam.

(2) A vermiform appendix, as fresh as possible, should be cut transversely into small pieces, fixed in formalin-Müller's fluid (technic 6, p. 7), and hardened in alcohol. Thin transverse sections are made through the entire wall, stained with hæmatoxylin-eosin or hæmatoxylin-picro-acid-fuchsin, and mounted in balsam.

(3) Fat Absorption.—For the purpose of studying the process by which fat passes from the lumen of the gut into the chyle vessels, an animal should be killed at the height of fat absorption. A frog fed with fat bacon and killed two days later, a dog fed with fat meat, or a cat with cream and killed after from four to eight hours, furnishes good material. Usually if the preparation is to be successful, the lumen of the intestine will be found to contain emulsified fat and the lacteals of the mesentery are seen distended with chyle. Extremely thin slices of the mucous membrane of the small intestine are fixed in 1-per-cent. osmic acid or in osmium bichromate solution (5-per-cent. aqueous solution potassium bichromate and 2-per-cent. aqueous solution osmic acid—equal parts) for twelve to twenty-four hours, after which they are passed rather quickly through graded

alcohols. Sections should be thin and mounted, either unstained or after a slight eosin stain, in glycerin.

(4) The blood-vessels of the stomach are best studied in injected specimens. (See page 10.)

The Larger Glands of the Digestive System

The smaller tubular glands which form a part of the mucous membrane and submucosa of the alimentary tract have been already described. Certain larger glandular structures, the development of which is similar to that of the smaller tubules but which come to lie wholly without the alimentary tract, connected with it only by their main excretory ducts, and which are yet functionally an important part of the digestive system, remain to be considered.

These are:

1. The salivary glands { (*a*) The parotid. (*b*) The sublingual. (*c*) The submaxillary.
2. The pancreas.
3. The liver.

The Salivary Glands

The salivary glands are all compound tubular glands. In man the parotid is serous; the sublingual and submaxillary, mixed serous

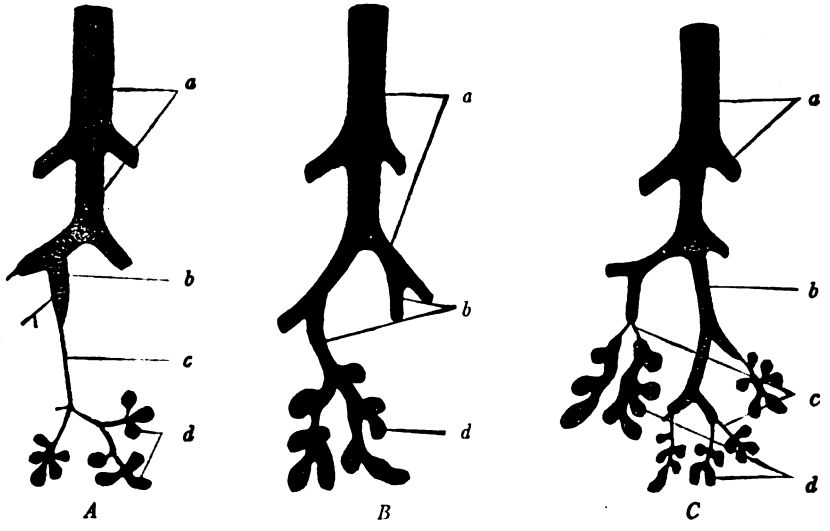

FIG. 182.—Diagrams to illustrate the Structure of the Salivary Glands. (Stöhr.) *A*, Parotid; *B*, sublingual; *C*, submaxillary. *a*, Excretory duct; *b*, secreting tubule; *c*, intermediate tubule; *d*, terminal tubule.

and mucous (page 226). Only the general structure of these glands is here described, the minute structure of mucous and serous glands having been described on page 226.

Each gland consists of gland tissue proper and of a supporting connective-tissue framework. The framework consists of a connective-tissue *capsule* which encloses the gland, but blends externally with and attaches the gland to the surrounding structures. From the capsule *trabeculæ* pass into the gland, subdividing it into *lobes* and *lobules*. The gland tissue proper consists of systems of *excretory ducts* opening into *secretory tubules*, all being lined with one or more layers of epithelial cells. Each gland has one *main excretory duct*. This divides into branches—*interlobar ducts*—which run to the lobes in the connective tissue which separates them. The interlobar ducts give rise to branches which, as they pass to the lobules in the interlobular connective tissue, are known as *interlobular ducts*. From the latter, branches enter the lobules—*intralobular ducts*—and split up into *terminal secreting tubules* which constitute the bulk of the lobule. As the smaller intralobular ducts are lined with cells of a secretory type, and probably take part in the elaboration of the secretion of the gland, they have been called *salivary* or *secreting* tubules. These, in the submaxillary and parotid glands, open into tubules which have a narrow lumen and are lined with low or flat epithelium; lying between the secreting tubules and the terminal tubules, they are known as *intercalated* or *intermediate tubules*. From the interlobular connective tissue delicate extensions pass into the lobules, separating the gland tubules. The glandular tissue is known as the *parenchyma* of the gland in contradistinction to the connective or *interstitial tissue*.

FIG. 183.—Reconstructed Model of Small Muco-serous Gland. Dotted parts corresponding to the "crescents". (Maziarski).

The parotid gland in man, dog, cat, and rabbit is a purely serous gland. Its duct system is complex. The main excretory duct (Stenoni) is lined with two layers of columnar epithelium resting upon a distinct basement membrane. The main duct divides into numerous branches, which in turn give rise to the *secreting* or *salivary* tubules.

These are continuous with the long narrow *intermediate tubules*, from each of which are given off a number of short *terminal tubules* (Figs. 182 *A*, and 184). The two-layered epithelium of the main duct becomes reduced in the smaller ducts to a single layer of columnar cells. The salivary tubules are lined with high columnar epithelium, the bases of the cells showing distinct longitudinal striations. In the intermediate tubule the epithelium is flat, sometimes spindle-shaped. The terminal tubules are lined with serous cells (page 226). The connective tissue usually contains a considerable number of fat cells.

The sublingual gland is a mixed gland in man, dog, cat, and rabbit. The duct system is less complex than in the parotid. The

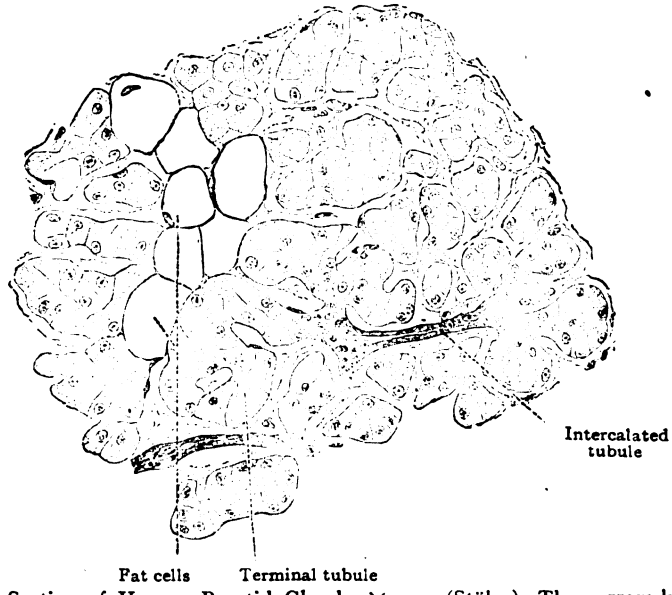

FIG. 184.—Section of Human Parotid Gland. ×252. (Stöhr.) The narrow lumina of the terminal tubules do not show in this figure.

main duct (Bartholini) sends off branches which are continuous with tubules, showing a few secretory mucous cells. These open directly into the *terminal tubules* which are convoluted and vary greatly in diameter (Fig. 182, *B*). The excretory duct is like that of the parotid gland, lined with a two-layered columnar epithelium resting upon a basement membrane. In the smaller ducts the epithelium is reduced to a single layer of columnar cells. There are no intermediate tubules. The terminal tubules are lined with both serous and mucous cells (page 226). The crescents of Gianuzzi (page 227) are numerous

and large. The connective tissue of the gland contains many lymphoid cells (Fig. 185).

Near the sublingual gland is a group of some 5 to 20 simple tubular glands. Their terminal tubules are lined almost wholly with mucous cells. This group of tubules has been designated the "sublingualis minor."

The submaxillary gland is also a mixed gland in man, dog, cat, and rabbit. In complexity of its duct system it stands between the parotid and the sublingual (Fig. 182). The main duct (Wharton's) has not only a two-layered epithelial lining resting upon a basement

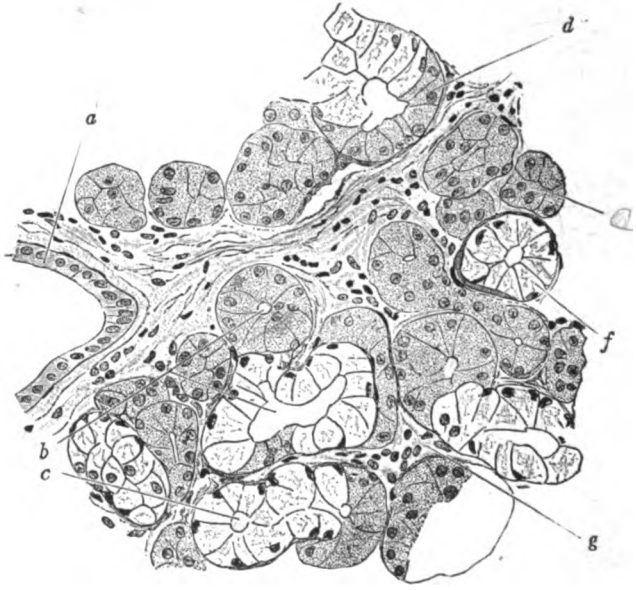

FIG. 185.—Section of Human Sublingual Gland. ×252. (Stöhr.) *a*, Excretory duct; *b*, lumina of serous and mucous tubules; *c*, mucous tubule; *d*, demilune; *e*, serous tubule; *f*, cross section mucous tubule; *g*, interstitial connective tissue.

membrane, but is distinguished by a richly cellular stroma and a thin layer of longitudinally disposed smooth muscle. Branches of the main duct open into long *secreting tubules* which communicate with the *terminal tubules* by means of short narrow *intermediate tubules* (Fig. 182 *C*). The secretory tubules are lined as in the parotid with columnar cells whose bases are longitudinally striated. These cells usually contain more or less yellow pigment. The intermediate tubules have a low cuboidal or flat epithelium. Most of the end tubules contain serous cells only (page 226). The crescents of the mucous tubules (page 227) are less numerous and smaller than those in the sublingual, consisting as a rule of only from one to three cells (Fig. 186). They

are connected with the lumen by intercellular secretory canals (page 47). The interstitial tissue of the submaxillary contains numerous elastic fibres.

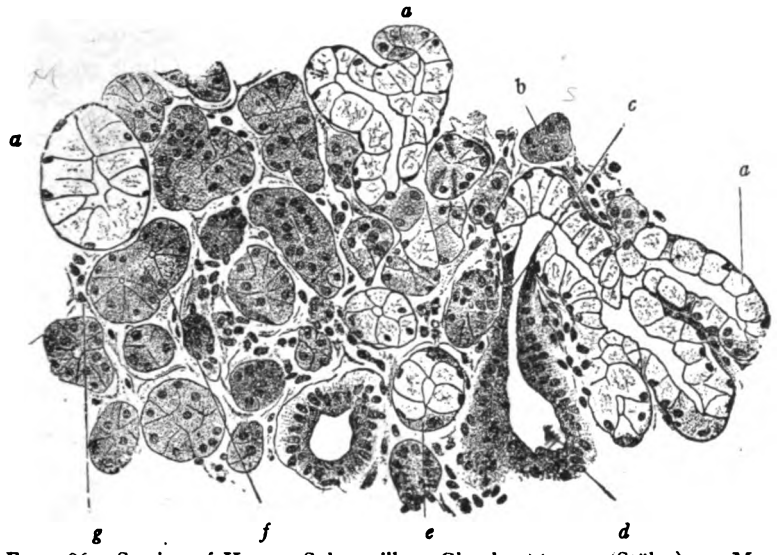

FIG. 186.—Section of Human Submaxillary Gland. ×252. (Stöhr.) *a*, Mucous tubule; *b*, serous tubule; *c*, intermediate tubule; *d*, "secretory" tubule; *e*, demilune; *f*, lumen; *g*, interstitial connective tissue.

Blood-vessels.—The larger arteries run in the connective-tissue septa with the ducts, giving off branches which accompany the divisions of the ducts to the lobules, where they break up into capillary networks among the tubules. These give rise to veins which accompany the arteries.

The **lymphatics** begin as minute capillaries in the connective tissue separating the terminal tubules. These empty into larger lymph vessels which accompany the arteries in the septa.

The **nerves** of the salivary glands are derived from both cerebro-spinal and sympathetic systems, and consist of both medullated and non-medullated fibres. The medullated fibres are afferent, probably the dendrites of cells located in the geniculate ganglion. Small bundles of these fibres accompany the ducts. Single fibres leave the bundles, lose their medullary sheaths, and form a non-medullated subepithelial plexus, from which delicate fibrils pass to end freely among the epithelial cells. Efferent impulses reach the gland through the sympathetic. The fibres are axones of cells situated in small peripheral ganglia; the cells sending axones to the submaxillary

lying upon the main excretory duct and some of its larger branches; those sending axones to the sublingual being situated in a small ganglion—the sublingual—lying in the triangular area bounded by the chorda tympani, the lingual nerve, and Wharton's duct; those supplying the parotid probably being in the otic ganglion. Axones from these cells enter the glands with the excretory duct and follow its branchings to the terminal tubules, where they form plexuses beneath the epithelium. From these, terminals pass to the secreting cells. It is probable that the salivary glands also receive sympathetic fibres from cells of the superior cervical ganglia.

TECHNIC

(1) The salivary glands should be fixed in Flemming's fluid (technic 8, p. 8), or in formalin-Müller's fluid (technic 6, p. 7). Sections are cut as thin as possible, stained with hæmatoxylin-eosin (technic 1, p. 23), and mounted in balsam.

(2) For the study of the secretory activities of the gland cells, glands from a fasting animal should first be examined and then compared with those of a gland the secretion of which has been stimulated by the subcutaneous injection of pilocarpine. Fix in Flemming's or in Zenker's fluid (technic 10, p. 8). Examine some sections unstained and mounted in glycerin, others stained with hæmatoxylin-eosin and mounted in balsam.

(3) The finer intercellular and intracellular secretory tubules are demonstrated by Golgi's method. Small pieces of absolutely fresh gland are placed for three days in osmium-bichromate solution (3-per-cent. potassium bichromate solution, 4 volumes; 1-per-cent. osmic acid, 1 volume), and then transferred without washing to a 0.75-per-cent. aqueous solution of silver nitrate. Here they remain for from two to four days, the solution being frequently changed. The processes of dehydrating and embedding should be rapidly done, and sections mounted in glycerin, or, after clearing in xylol, in hard balsam.

Pancreas

The pancreas is a compound tubular gland. While in general similar to the salivary glands, it has a somewhat more complicated structure. A connective-tissue capsule surrounds the gland and gives off trabeculæ which pass into the organ and divide it into *lobules*.

In some of the lower animals, as for example the cat, these lobules are well defined, being completely separated from one another by connective tissue. In this respect they resemble the lobules of the pig's liver. A number of these *primary lobules* are grouped together and surrounded by connective tissue, which is considerably broader and looser in structure than that separating the primary lobules. These constitute a *lobule group* or *secondary lobule*.

In the human pancreas the division into lobules and lobule groups

is much less distinct, although it can usually be made out. This is due to the incompleteness of the connective-tissue septa, the human pancreas in this respect resembling the human liver. Rarely the human pancreas is distinctly lobulated.

The gland has a main excretory duct, the pancreatic duct or *duct of Wirsung*. In many cases there is also a *secondary excretory duct*, the accessory pancreatic duct or *duct of Santorini*. Both open into the duodenum. The main duct extends almost the entire length of the gland, giving off short lateral branches, one of which enters the centre of each lobule group. Here it splits up into branches which pass to the primary lobules. From these *intralobular ducts*, are given off long, narrow, *intermediate tubules*, which in turn give rise to the *terminal secreting tubules* (Fig. 187).



FIG. 187.—Diagram to illustrate Structure of Pancreas. (Stöhr.) *a*, Excretory duct; *b*, intermediate tubule; *c*, *c*, terminal tubules.

The *excretory ducts* are lined with a simple high columnar epithelium which rests upon a basement membrane. Outside of this is a connective-tissue coat, the thickness of which is directly proportionate to the size of the duct. In the pancreatic duct goblet cells are present, and the accompanying connective tissue of the main duct and of its larger branches contains small *mucous glands*. As the ducts decrease in size, the epithelium becomes lower until the intermediate tubule is reached where it becomes flat.

The *terminal tubules* themselves are most of them very short, frequently almost spherical. This and the fact that several terminal tubules are given off from the end of each intermediate tubule have led to the description of these tubules as *alveoli*, and of the pancreas as a *tubulo-alveolar gland*, although there is no dilatation of the lumen. The terminal tubules are lined with an irregularly conical epithelium resting upon a basement membrane (Figs. 188 and 189). The appearance of these cells depends upon their functional condition. Each cell consists of a central zone bordering the lumen, which contains numerous granules known as *zymogen granules*, and of a peripheral zone next to the basement membrane, which is homogeneous and contains the nucleus (Fig.

189). The zymogen granules are quite large granules and as they are highly refractive stand out distinctly even in the fresh, unstained condition and under low magnification. The relative

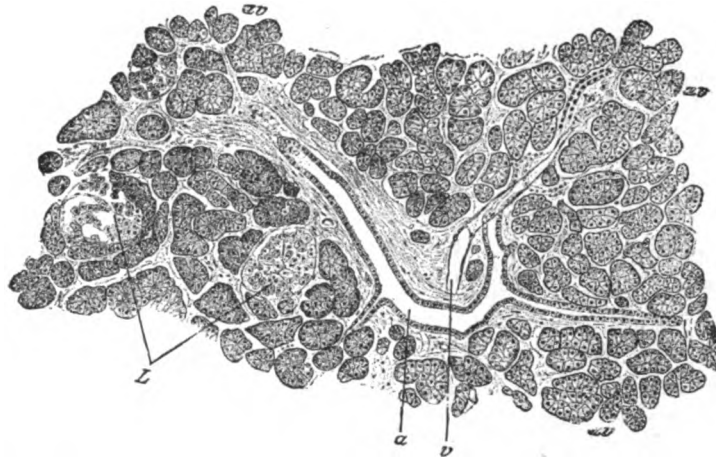

FIG. 188.—Section of Human Pancreas. ×112. (Kölliker.) *av*, Alveoli; *a*, interlobular duct surrounded by interlobular connective tissue; *L*, islands of Langerhans; *v*, small vein.

size of these zones depends upon whether the cell is in the active or resting state (compare Fig. 190, *A* and *B*). During ***rest*** (fasting) there is a gradual increase in number of the zymogen granules beginning at the lumen end of the cell and extending outward until, after a prolonged rest, the entire cytoplasm is crowded with granules. During the early stages of *activity* (intestinal digestion) the granules begin to disappear, until, after prolonged activity (later stages of intestinal digestion) they are almost wholly absent and the clear zone occupies practically the entire cell. The cell now returns to the resting state. The increase and disappearance of the granules are marked by the appearance of the fluid secretion of the gland in the lumen. It would thus seem probable that the zymogen granules are the intracellular representatives of the secretion of the gland.

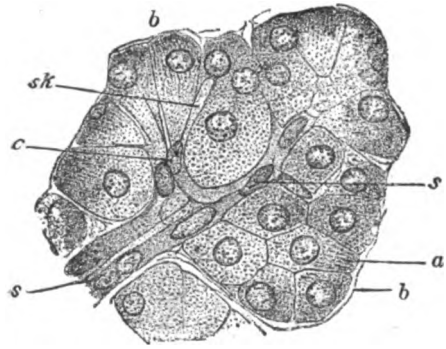

FIG. 189.—From Section of Human Pancreas. ×700. (Kölliker.) *a*, Gland cell; *b*, basement membrane; *s*, intermediate tubule; *c*, centro-acinar cells; *sk*, intracellular secretory tubule.

In sections of the gland there are seen within the lumina of many of the secreting tubules one or more small cells of which little but the nucleus can usually be made out. These cells lie in contact with the secreting cells, and resemble the flat cells which line the intermediate

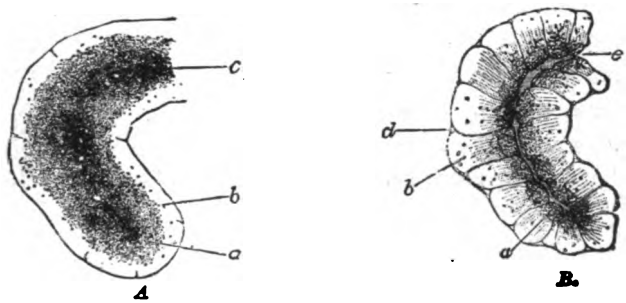

FIG. 190.—Sections of Alveoli from Rabbit's Pancreas. (Foster, after Kühne and Lea.) *A*, Resting alveolus, the inner zone (*a*), containing zymogen granules, occupying a little more of the cell than the outer clear zone (*b*); *c*, indistinct lumen. *B*, Active alveolus, granules coarser, fewer, and confined to inner ends of the cell (*a*), the outer clear zone (*b*) being much larger; outlines of cells and of lumen much more distinct.

tubule. They are known as the *centro-acinar* (*centro-tubular*) *cells of Langerhans* (Fig. 189, *c*). Their significance is not definitely known. Langerhans believed that they were derived from the intermediate tubule, the epithelium of which, instead of directly joining that of

FIG. 191.—Sections through Alveoli of Human Pancreas—Golgi Method—(Dogiel), to show intracellular secretory tubules. *a*, Intermediate tubule giving off several terminal tubules, from which pass off minute intracellular secretory tubules; *b*, gland cells lining terminal tubules.

the terminal tubule as in the submaxillary gland, was continued over into the lumen of the terminal tubule (Fig. 189). This interpretation has been quite generally accepted.

Cells which differ from the secreting cells are frequently found

wedged in between the latter. They extend from the lumen to the basement membrane and are probably *sustentacular*.

Passing from the lumen of the terminal tubule, sometimes between the centro-tubular cells, directly into the cytoplasm of the secreting cells are minute *intracellular secretory tubules*. These are demonstrable only by special methods (Golgi) (Fig. 191).

The pancreas also contains peculiar groups of cells, the *cell-islands of Langerhans*, having a diameter from 200 to 300μ (Figs. 188, 192, and 193). The "island" cells differ quite markedly both in arrangement and structure from those which line the terminal tubules (Fig.

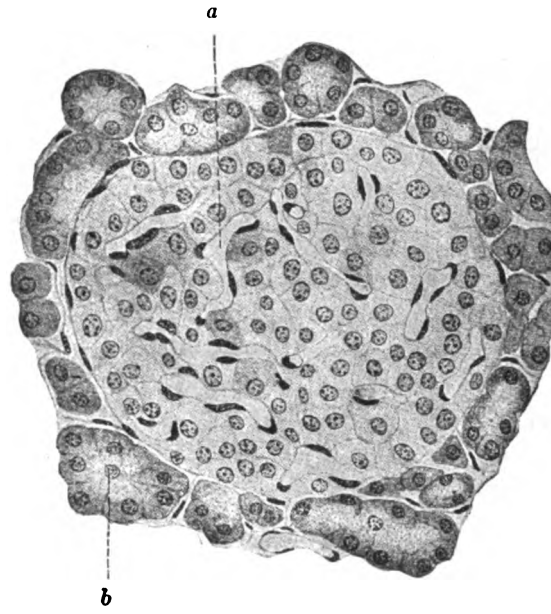

FIG. 192.—Island of Langerhans and few surrounding Pancreatic Tubules. (Böhm and von Davidoff.) *a*, Capillary; *b*, tubule.

192). They contain no zymogen granules. They are arranged in anastomosing cords or strands which are separated from one another by capillaries. There are no ducts and the method of Golgi shows no inter- or intra-cellular secretory tubules. Their protoplasm is unstained by basic dyes, but stains homogeneously with acid dyes. Their nuclei vary greatly in size, some, especially where the cells are closely packed, being small, others being large and vesicular. Some of the islands are quite sharply outlined by delicate fibrils of connective tissue containing a few elastic fibres (Fig. 192). Others blend with the surrounding tissues.

The origin, structure, and function of these islands have been subjects of much controversy. For some time they were considered of lymphoid origin. They are now believed to be epithelial cells having a developmental history similar to the cells lining the secreting tubules. Each cell-island consists of, in addition to the cells, a tuft or glomerulus of broad tortuous anastomosing capillaries, which arise from the network of capillaries surrounding the secreting tubules. The close relation of cells and capillaries and the absence of any ducts have led to the hypothesis that these cells furnish a secretion—*internal secretion*—which passes directly into the blood-vessels.

Opie after reviewing previous work upon the histology of the pancreas and adding the results of his own careful researches, concludes that the cell-islands of Langerhans are definite structures "formed in embryological life," that

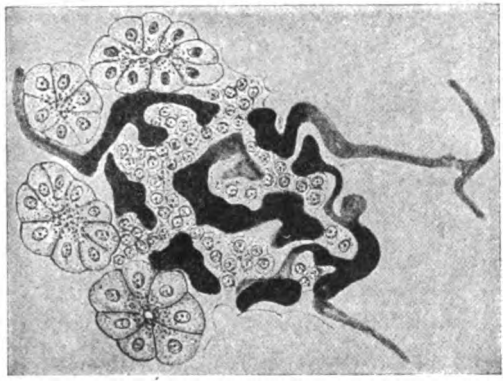

FIG. 193.—From Section of Pancreas, the blood-vessels of which had been injected (Kühne and Lea), showing island of Langerhans with injected blood-vessels, surrounded by sections of tubules. Zymogen granules are distinct in inner ends of cells.

"they possess an anatomical identity as definite as the glomeruli of the kidney or the Malpighian body of the spleen, and that they subserve some special function." He calls attention to the similarity which Schäfer noted between these cell-islands and such small ductless structures as the carotid and coccygeal glands and the parathyreoid bodies. From his study of the pancreas in diabetes, Opie believes that the islands of Langerhans are concerned in carbohydrate metabolism.

Blood-vessels.—The arteries enter the pancreas with the main duct and break up into smaller arteries which accompany the smaller ducts. These end in a capillary network among the secreting tubules. From this, venous radicles arise which converge to form larger veins. These pass out of the gland in company with the arteries.

Lymphatics.—Of the lymphatics little is known.

Nerves.—The nerves are almost wholly from the sympathetic system, and are non-medullated. Some of them are axones of cells in sympathetic ganglia, outside the pancreas; others, of cells situated

in small ganglia within the substance of the gland. They pass to plexuses among the secreting tubules, to which and to the walls of the vessels they send delicate terminal fibrils.

TECHNIC

(1) The general technic for the pancreas is the same as for the salivary glands (page 286).

(2) Zymogen granules may be demonstrated by fixation in formalin-Müller's fluid (technic 6, p. 7), and staining with picro-acid-fuchsin (technic 2, p. 24), or with Heidenhain's iron hæmatoxylin (technic 3, p. 21).

(3) The arrangement of the blood-vessels in the islands of Langerhans may be studied in specimens in which the vascular system has been injected (page 10).

The Liver

The liver is a compound tubular gland, the secreting tubules of which anastomose. There are thus, strictly speaking, no "terminal

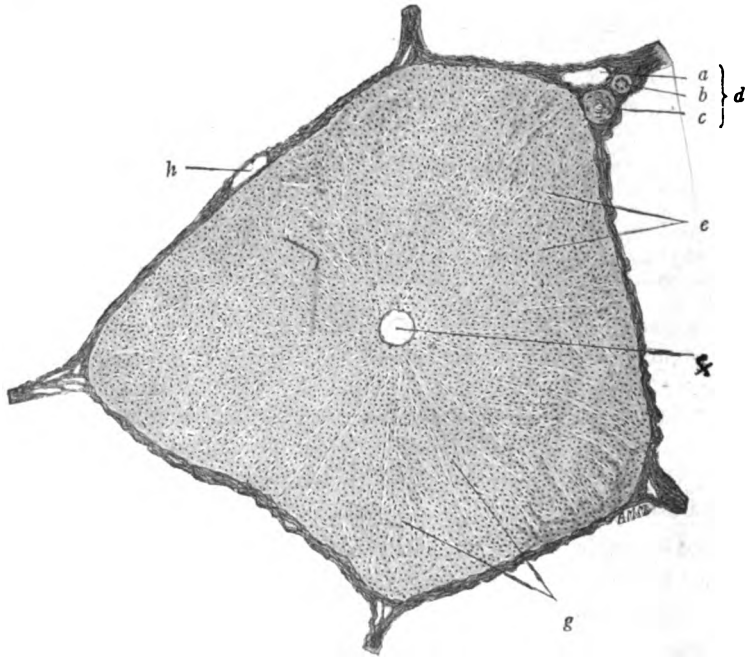

FIG. 194.—Section of Lobule of Pig's Liver ×60 (technic 1, p. 301), showing lobule completely surrounded by connective tissue. *a*, Portal vein; *b*, bile duct; *c*, hepatic artery; *d*, portal canal; *e*, capillaries; *f*, central vein; *g*, cords of liver cells; *h*, hepatic vein.

tubules" in the liver, the lumina and walls of neighboring tubules anastomosing without any distinct line of demarcation.

The liver is surrounded by a connective-tissue *capsule*, the *capsule of Glisson*. At the *hilum* this capsule extends deep into the substance of the liver, giving off broad connective-tissue *septa*, which divide the organ into *lobes*. From the capsule and from these interlobar septa, trabeculæ pass into the lobes, subdividing them into *lobules*. In some animals, as for example the pig, each lobule is completely invested by connective tissue (Fig. 194). In man, only islands of connective

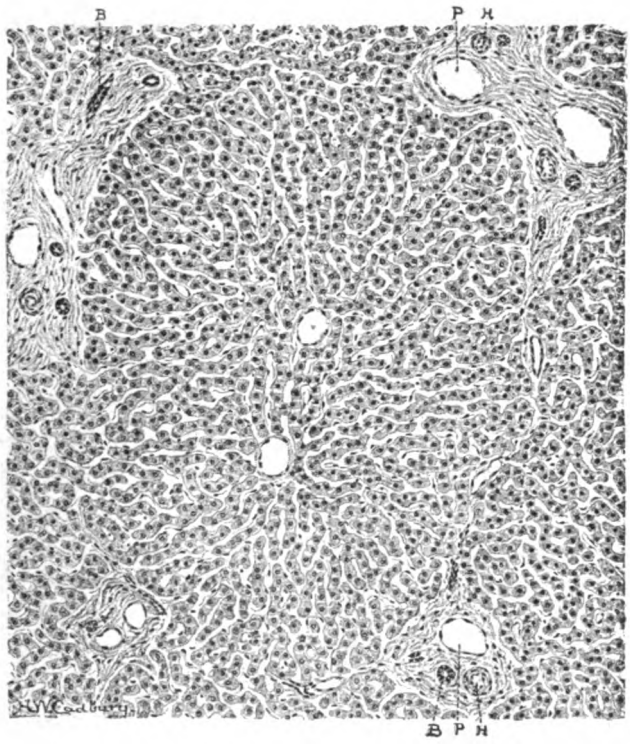

FIG. 195.—Section of Human Liver. ×80. (Hendrickson.) *P*, Portal vein; *H*, hepatic artery; *B*, bile duct. *P*, *H*, *B* constitute the portal canal and lie in the connective tissue between the lobules.

tissue are found, usually at points where three or more lobules meet (Fig. 195). The lobules are cylindrical or irregularly polyhedral in shape, about 1 mm. in breadth and 2 mm. in length. Excepting just beneath the capsule, where they are frequently arranged with their apices toward the surface, the liver lobules have an irregular arrangement.

The lobule (Fig. 194) which may be considered the anatomic unit of structure of the liver, consists of secreting tubules arranged in a

definite manner relatively to the blood-vessels. The blood-vessels of the liver must therefore be first considered.

The BLOOD SUPPLY of the liver is peculiar in that in addition to the ordinary arterial supply and venous return, which all organs possess, the liver receives venous blood in large quantities through the portal vein. There are thus *two afferent vessels*, the *hepatic artery* and the *portal vein*, the former carrying arterial blood, the latter venous blood from the intestine. Both vessels enter the liver at the hilum and divide into large *interlobar branches*, which follow the connective-tissue septa between the lobes. From these are given off *interlobular branches*, which run in the smaller connective-tissue septa between the lobules. From the interlobular branches of the portal vein arise veins which are still interlobular and encircle the lobules. These send off short branches which pass to the surface of the lobule, where they break up into a rich *intralobular capillary network*. These intralobular capillaries all converge toward the center of the lobule, where they empty into the *central vein* (Fig. 194). The central veins are the smallest radicles of the hepatic veins, which are the efferent vessels of the liver. Each central vein begins at the apex of the lobule as a small vessel little larger than a capillary. As it passes through the centre of the long axis of the lobule the central vein constantly receives capillaries from all sides, and, increasing in size, leaves the lobule at its base. Here it unites with the central veins of other lobules to form the *sublobular vein* which is a branch of the hepatic (Fig. 205).

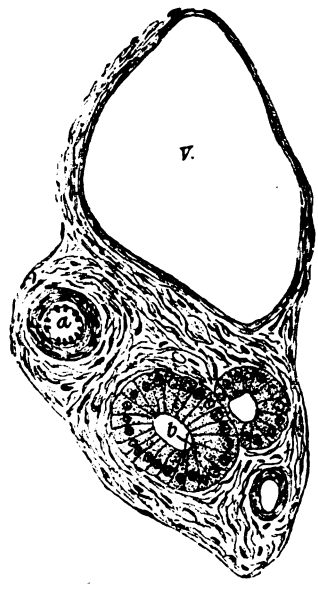

FIG. 196.—Portal Canal. ×315 (Klein and Smith.) *a*, Hepatic artery; *V*, portal vein; *b*, bile duct.

The hepatic artery accompanies the portal vein, following the branchings of the latter through the interlobar and interlobular connective tissue, where its finer twigs break up into *capillary networks*. Some of these capillaries empty into the smaller branches of the portal vein; others enter the lobules and anastomose with the intralobular portal capillaries.

The MAIN EXCRETORY DUCT—*hepatic duct*—leaves the liver at the

hilum near the entrance of the portal vein and hepatic artery. Within the liver the duct divides and subdivides, giving off *interlobar*, and these in turn *interlobular branches*. These ramify in the connective tissue, where they always accompany the branches of the portal vein and hepatic artery. These three structures—the hepatic artery, the portal vein, and the bile duct, which always occur together in the connective tissue which marks the point of separation of three or more lobules—together constitute the *portal canal* (Fig. 196). From the interlobular ducts short branches pass to the surfaces of the lobules

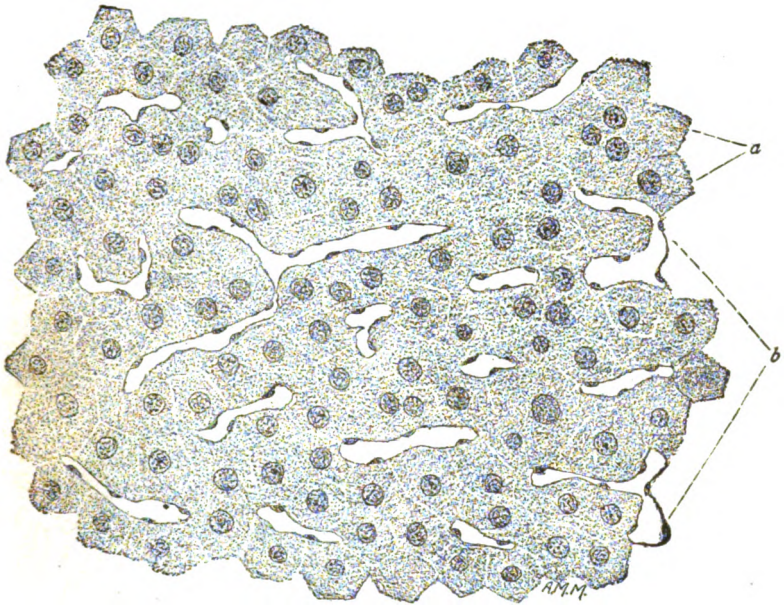

FIG. 197.—Part of Lobule of Human Liver, showing capillaries and anastomosing cords of liver cells. ×350. *a*, Liver cells; *b*, capillaries.

From these are given off extremely narrow tubules, which enter the lobule as *intralobular secreting tubules*.

The walls of the ducts consist of a single layer of epithelial cells resting upon a basement membrane and surrounded by connective tissue (Fig. 196). The height of the epithelium and the amount of connective tissue are directly proportionate to the size of the duct. In the largest ducts there are usually a few scattered smooth muscle cells. The walls of the secreting tubules are formed by the liver cells.

The LIVER CELLS (Fig. 197) are irregularly polyhedral in shape. They have a granular protoplasm which frequently contains gly-

cogen, pigment granules, and droplets of fat and bile. Each cell contains *one* or *more spherical nuclei*. Like other gland cells, the granularity of the protoplasm depends upon its functional condition. Within the cells are minute irregular canals, some of which can be

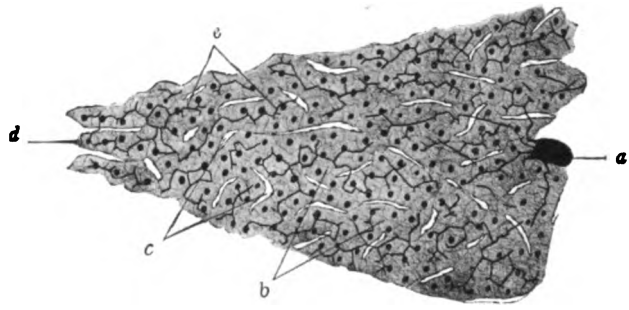

FIG. 198.—Part of Lobule of Human Liver, Golgi Method (technic 3, p. 301), to show relations of bile duct to intralobular secretory tubules and of the latter to the liver cells. *a*, Bile duct; *b*, cords of liver cells; *c*, blood capillaries; *d*, central vein; *e*, secretory tubules.

injected through the blood-vessels, while others are apparently continuous with the secreting tubules (Fig. 199, *A* and *B*).

The capillaries of the portal vein, as they anastomose and converge from the periphery to the centre of the lobule, form long-meshed

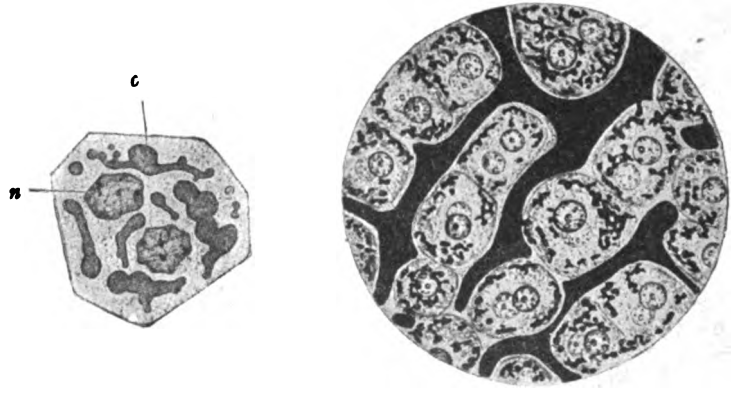

FIG. 199.—*A*, Cell from human liver showing intracellular canals (Browicz); *c*, intracellular canal; *n*, nucleus. *B*, From section of rabbit's liver injected through portal vein, showing intracellular canals (continuous with intercellular blood capillaries). (Schäfer.)

capillary networks. In the meshes of this network lie the anastomosing secreting tubules. On account of the shape of the capillary network, the liver cells, which form the walls of these tubules, are

arranged in anastomosing rows or cords, known as *hepatic cords* or *cords of liver cells* (Fig. 197).

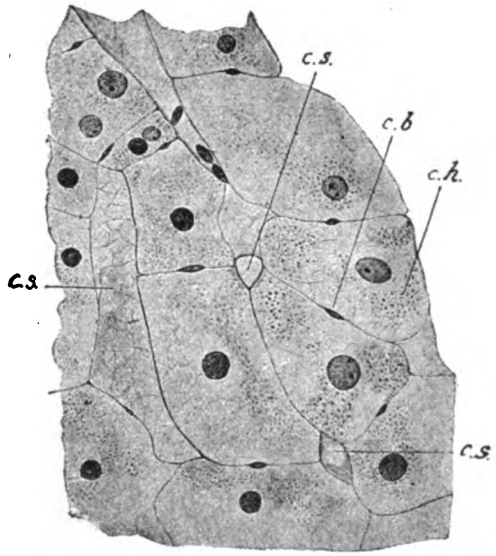

FIG. 200.—Section of rabbit's liver (Prenant) to show relation of bile capillaries and blood capillaries to liver cells; *ch*, liver cells; *cb*, bile capillary; *cs*, blood capillary cut obliquely.

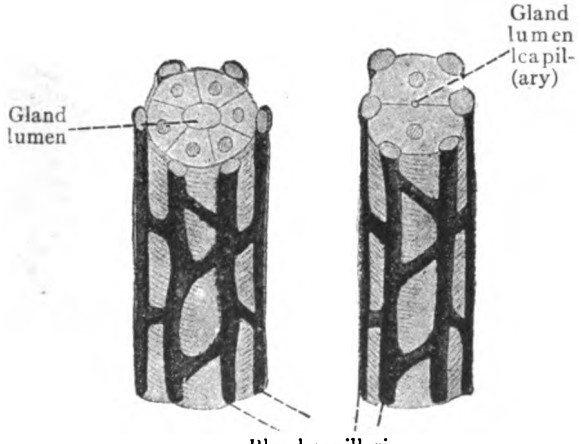

FIG. 201. FIG. 202.

FIG. 201.—Diagram illustrating relation of cells to lumen and to blood capillaries in an ordinary tubular gland. (Stöhr.)

FIG. 202.—Diagram illustrating relation of cells to lumen (bile capillary) and to blood capillaries in liver. (Stöhr.)

The secreting tubules (Fig. 198) are extremely minute channels, the walls of which are the liver cells. A secretory *tubule* always runs

between two contiguous liver cells, in each of which a groove is formed (Figs. 200, 202.) The *blood capillaries*, on the other hand, are found at the corners where three or more liver cells come in contact (Fig. 200). It thus results that bile tubules and blood capillaries rarely lie in contact, but are regularly separated by part of a liver cell. Exceptions to this rule sometimes occur. While most of the secretory tubules anastomose, some of them end blindly either between the liver cells or, in some instances, after extending a short distance within the cell protoplasm (Fig. 199, *A*). At the surface of the lobule there is a modification of some of the liver cells to a low cuboidal type, and these become continuous with the lining cells of the smallest bile ducts, the secretory tubule being continuous with the duct lumen.

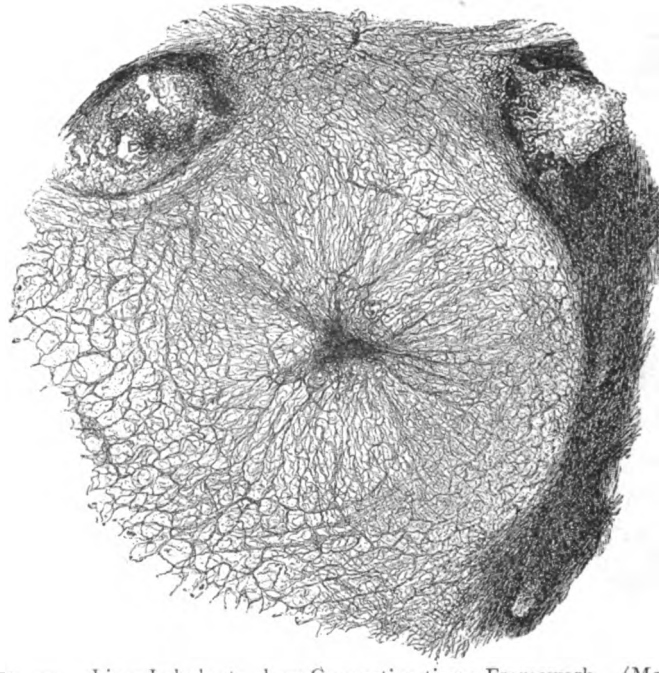

FIG. 203.—Liver Lobule, to show Connective-tissue Framework. (Mall.)

Special methods of technic have demonstrated a connective-tissue framework within the lobule. This consists of a *reticulum* of extremely delicate fibrils which envelop the capillary blood-vessels, and of a smaller number of coarser fibres which radiate from the region of the central vein—*radiate fibres* (Fig. 203).

Special technical methods also show the presence of stellate

cells—*cells of Kupffer*—within the lobule. These are interpreted by Kupffer as belonging to the endothelium of the intralobular capillaries.

Comparing the liver with other compound tubular glands, it is seen to present certain marked peculiarities which distinguish it and which make its structure as a compound tubular gland difficult to understand. The most important of these are the following:

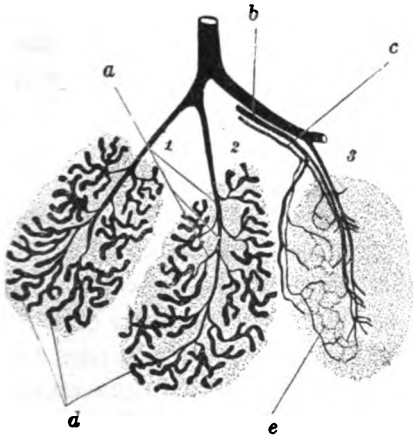

FIG. 204.

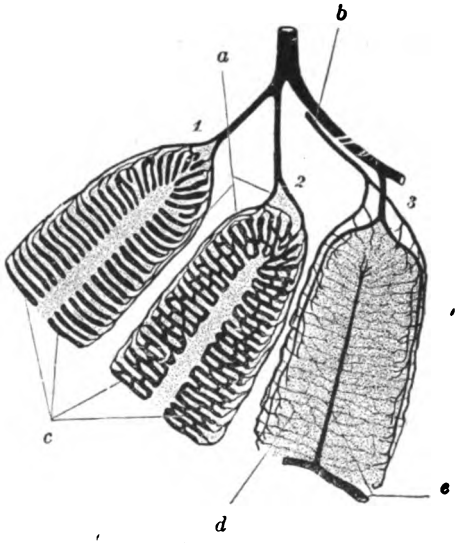

FIG. 205.

FIG. 204.—Scheme of an Ordinary Compound Tubular Gland. In lobule 3 only the ramifications of the excretory duct, without endpieces, are shown. (Stöhr.) *a*, Branches of excretory duct; *b*, artery; *c*, vein; *d*, terminal tubules; *e*, capillaries.

FIG. 205.—Scheme of Liver. In lobule 1, only the direction of the endpieces is shown; in lobule 2 only their branching; in 3 only the excretory ducts. (Stöhr.) *a*, Branches of excretory duct; *b*, portal vein; *c*, terminal tubules (hepatic cords); *d*, capillaries; *e*, vein (central and sublobular).

The extremely small amount of connective tissue. In the human liver there is not enough interlobular connective tissue to outline the lobules, while intralobular connective tissue demonstrable by ordinary staining methods is wholly absent. There is thus no connective tissue seen separating the cells of one tubule from those of another as, for example, in such a gland as the submaxillary. (Compare Figs. 186 and 197.) The result is that cells of neighboring tubules lie side by side, and back to back as it were, with no intervening connective tissue.

The fact that unlike the tubules of other glands, the liver tubule con-

sists of only two rows of cells (Figs. 201 and 202), between which lies the lumen. The latter is thus never in touch with more than two cells.

The end-to-end anastomosis of the secreting tubules, there being no true terminal tubules; anastomosis of neighboring tubules by means of side branches; the arrangement of the bile capillaries in such a manner that a single liver cell abuts upon more than one capillary.

The more intimate relation of the liver cell to the blood capillaries. Thus most gland cells have one side on the lumen, one side only in contact with a capillary blood-vessel, the remaining sides being in contact with other cells of the same tubule. A liver cell, on the other hand, may and usually does come in contact with several blood capillaries (Fig. 202).

The arrangement of both blood-vessels and tubules within the lobule. In the submaxillary, for example, the terminal tubules are convoluted and run in all directions. In the liver the terminal tubules are straight and run in a definite direction from the periphery of the lobule toward the centre. Again, while in other glands both intralobular arteries and ducts are distributed outward from the centre of the lobule, and the blood is returned through veins which pass to the periphery of the lobule, in the liver the interlobular ducts pass to the periphery of the lobule and give off secreting tubules which pass in toward the centre of the lobule. The afferent vessels also (portal veins) take the blood to the periphery of the lobule and distribute it to a capillary network which converges to an efferent vessel (hepatic vein) at the centre of the lobule. The veins are also peculiar in that they do not follow the arteries in leaving the liver but pursue an entirely independent course (compare Figs. 204 and 205).

Blood-vessels.—These have been already described.

Lymph vessels form a network in the liver capsule. These communicate with deep lymphatics in the substance of the organ. The latter accompany the portal vein and follow the ramifications of its capillaries within the lobule as far as the central vein.

The nerves of the liver are mainly non-medullated axones of sympathetic neurones. The nerves accompany the blood-vessels and bile ducts, around which they form plexuses. These plexuses give off fibrils which end on the blood-vessels, bile ducts, and liver cells.

Three main ducts, all parts of a single excretory duct system, are concerned in the transportation of the bile to the intestine, the *hepatic*, the *cystic*, and the *common*. Their walls consist of a *mucous membrane*,

a *submucosa*, and a layer of *smooth muscle*. The *mucosa* is composed of a simple columnar epithelium resting upon a basement membrane and a stroma which contains smooth muscle cells and small mucous glands. The *submucosa* is a thin layer of connective tissue. Hendrickson describes the *muscular coat* as consisting of three layers, an inner circular, a middle longitudinal, and an external oblique. At the entrance of the common bile duct into the intestine, and at the junction of the duct of Wirsung with the common duct, there are thickenings of the circular fibres to form sphincters. In the cystic duct occur folds of the mucosa—the *Heisterian valve*—into which the muscularis extends.

The Gall-Bladder

The wall of the gall-bladder consists of three coats—mucous, muscular, and serous.

The mucous membrane is thrown up into small folds or *rugæ*, which anastomose and give the mucous surface a reticular appearance. The epithelium is of the simple columnar variety with nuclei situated at the basal ends of the cells. A few mucous glands are usually found in the stroma.

The muscular coat consists of bundles of smooth muscle cells which are disposed in a very irregular manner, and are separated by considerable fibrous tissue. A richly vascular layer just beneath the stroma is almost free from muscle and corresponds to a submucosa. It frequently contains small lymph nodules.

The serous coat is a reflection of the peritoneum.

TECHNIC

(1) Before taking up the study of the human liver, the liver from one of the lower animals in which each lobule is completely surrounded by connective tissue should be studied. Fix small pieces of pig's liver in formalin-Müller's fluid (technic 6, p. 7). Cut sections near and parallel to the surface. Stain with hæmatoxylin-picro-acid-fuchsin (technic 3, p. 24) and mount in balsam. In the pig's liver the lobules are completely outlined by connective tissue and the yellow picric-acid-stained lobules are in sharp contrast with the red fuchsin-stained connective tissue.

(2) For the study of the human liver treat small pieces of perfectly fresh tissue in the same manner as the preceding, but stain with hæmatoxylin-eosin (technic 1, p. 23).

(3) The secretory tubules and smaller bile ducts may be demonstrated by technic, 5, p. 29. A light eosin stain brings out the liver cells.

(4) For the study of the blood-vessels of the liver, inject the vessels through

the inferior vena cava or portal vein. If the vena cava is used, it is convenient to inject from the heart directly through the right auricle into the vena cava. Sections should be rather thick and may be stained with eosin, or even lightly with hæmatoxylin-eosin (technic 1, p. 23), and mounted in balsam.

(5) For demonstrating the intralobular connective tissue, Oppel recommends fixing fresh tissue in alcohol, placing for twenty-four hours in a 0.5-per-cent. aqueous solution of yellow chromate of potassium, washing in very dilute silver nitrate solution (a few drops of 0.75-per-cent. solution to 50 c.c. of water) and then transferring to 0.75-per-cent. silver nitrate solution, where it remains for twenty-four hours. Embed quickly in celloidin. The best tissue is usually found near the surfaces of the blocks. A similar result is obtained by fixing fresh tissue in 0.5-per-cent. chromic-acid solution for three days, then transferring to 0.5-per-cent. silver nitrate solution for two days.

Development of the Digestive System

In the development of the digestive system all the layers of the blastoderm are involved. Mesoderm and entoderm are, however, the layers most concerned, as the ectoderm is used only in the formation of the oral and anal orifices. The *primitive alimentary canal* is formed by two folds which grow out from the ventral surface of the embryo and unite to form a canal, in a manner that is quite similar to the formation of the neural canal. In this way the primitive gut is lined with cells which previously formed the ventral surface of the embryo, *i.e.*, entoderm. A portion of the mesoderm accompanies the entoderm in the formation of the folds. This is known as the *visceral layer* of the mesoderm. The primary gut is thus a *closed sac* or *tube*. It is connected with the umbilical vesicle, but has no connection with the exterior. These connections are formed later by oral and anal invaginations of ectoderm which extend inward and open up into the ends of the hitherto imperforate gut. The ends of the alimentary tract, including the oral cavity and all of the glands and other structures connected with it, are of ectodermic origin. The epithelial lining of the gut and the parenchyma of all glands connected with it are derived from entoderm. The muscle, the connective tissue, and the mesothelium of the serosa are developed from mesoderm.

The mesodermic elements show little variation throughout the gut, the peculiarities of the several anatomical divisions of the latter being dependent mainly on special differentiation of the entoderm (epithelium). Beneath the entodermic cells is a narrow layer of loosely arranged tissue which later separates into stroma, muscularis mucosæ, and submucosa. Outside of this a broader mesodermic band of firmer structure represents the future muscularis.

The *stomach* first appears as a spindle-shaped dilatation about the end of the first month. Its entodermic cells, which had consisted of a single layer, increase in number and arrange themselves in short cylindrical groups. These are the first traces of tubular glands. They increase in length and extend downward into the mesodermic tissue. For a time the cells lining the peptic glands are all apparently alike, but at about the fourth month the differentiation into chief cells and parietal cells takes place.

In the *intestines* a proliferation of the epithelium and of the underlying stroma results in the formation of *villi*. These appear about the tenth week, in both small and large intestines. In the former they increase in size, while in the latter they atrophy and ultimately disappear. The simple tubular glands of the intestines develop in a manner similar to those of the stomach.

The mesothelium of the serosa is derived from the mesodermic cells of the primitive body cavity.

The *development of the larger glands*, connected with the digestive tract, takes place in a manner similar to the formation of the simple tubular glands. All originate in extensions downward of entodermic cords into the underlying mesodermic tissue. From the lower ends of these cords, branches extend in all directions to form the complex systems of tubules found in the compound glands.

The *salivary glands* being developed from the oral cavity, originate in similar invaginations of ectodermic tissue.

The *pancreas* originates as three separate evaginations from the entoderm of the future duodenum. Of these, one atrophies, while the other two unite to develop the adult pancreas. The two evaginations account for the two pancreatic ducts. The evaginations take place into the underlying mesenchyme, which develops the connective-tissue framework of the organ. The growths are at first solid cords of cells which later become hollowed out to form tubules and differentiate chief and centro-acinar cells, the former early showing zymogen granules. Increase in size of the gland is accomplished by continuous budding and extension of tubules. In some of the tubules the epithelial cells become darker and arranged as a wall around a mass of developing blood cells. These structures are known as *primary islands*. Neither their function nor subsequent history is known. Later in development some of the gland tubules lose their lumina, the zymogen granules disappear from their cells and the whole becomes transformed into a *secondary island* or island of Langerhans of the adult pancreas. According to Lageusse a transformation of islands into tubules also occurs, and this process of transformation of tubules into islands and islands into tubules persists throughout life. Claude on the other hand derives both primitive islands and islands of Langerhans from the mesenchyme. Recent observations tend to support the former of these views.

The *liver* originates as a downgrowth of the entoderm of the ventral wall of the future duodenum into the mesoderm of the transverse septum. At its cephalic end the downgrowth is solid and gives rise to the liver; at the caudal end it is hollow and gives rise to the gall-bladder. As the evagination increases in size it becomes almost completely separated from the intestine, the slender connection which does remain becoming the ductus choledochus. Between the latter and the liver anlage a slender connection also remains, the cystic duct. The mesenchyme surrounding these structures develops their connective-tissue framework. As the liver outgrowths develop they come into relation with the omphalomesenteric veins in such a manner that the vessels are broken up into an anastomosing network of smaller vessels, while the liver cells develop into anastomosing hepatic cylinders. These resemble the tubules of other glands in that the walls are formed by many cells. The manner in which these are trans-

formed into the slender hepatic cords of the adult liver is not known. The change begins to take place about the time of birth in man. The breaking up of the larger vessels into smaller by ingrowth of the cords of liver cells gives rise to the so-called sinusoidal circulation.

General References for Further Study

Oppel: Lehrbuch der vergleichenden mikroskopischen Anatomie.
Kölliker: Handbuch der Gewebelehre des Menschen.
Opie: The Pancreas.
Stöhr: Salivary Glands, in Text-book of Histology.

CHAPTER XVII

THE RESPIRATORY SYSTEM

THE respiratory apparatus consists of a system of passages—nares, larynx, trachea, and bronchi, which serve for the transmission of air to and from the essential organ of respiration, the lungs.

The Nares

The nares, or nasal passages, are divided into vestibular, respiratory, and olfactory regions, the differentiation depending mainly upon the structure of their mucous membranes.

The VESTIBULAR REGION marks the transition between skin and mucous membrane (page 225). Its epithelium is of the stratified squamous variety and rests upon a basement membrane, which is thrown into folds by papillæ of the underlying stroma. The latter is richly cellular, and contains sebaceous glands (page 397) and the follicles of the nasal hairs.

THE RESPIRATORY REGION, the mucous membrane of which is known as the *Schneiderian membrane*, is much larger than both the vestibular and olfactory regions. Its epithelium is of the stratified columnar variety and rests upon a distinct basement membrane. The cells of the surface layer are ciliated and are interspersed with goblet cells. The stroma is distinguished by its thickness (3 to 5 mm. over the inferior turbinates) and by the presence of considerable smooth muscle and of networks of such large veins that the tissue closely resembles erectile tissue. It contains considerable diffuse lymphoid tissue and here and there small lymph nodules. In the stroma are many simple tubular glands. Some are serous, some mucous, while some of the largest contain both serous and mucous cells. There is no submucosa, the stroma being connected directly with the periosteum and perichondrium of the nasal bones and cartilages.

The mucous membrane of the *accessory nasal sinuses* is similar in structure to that of the respiratory region of the nares, but is thinner and contains fewer glands.

The OLFACTORY REGION can be distinguished with the naked eye by its brownish-yellow color, in contrast with the reddish tint of the surrounding respiratory mucosa. The epithelium is of the stratified

columnar type, and is considerably thicker than that of the respiratory region. The surface cells are of two kinds: (1) sustentacular cells, and (2) olfactory cells.

(1) The *sustentacular cells* are the more numerous. Each cell consists of three parts: (*a*) A superficial portion, which is broad and cylindrical, and contains pigment, and granules arranged in longitudinal rows. The cells have well-marked, striated, thickened free borders, which unite to form the so-called *membrana limitans olfactoria*. (*b*) A middle portion which contains an oval nucleus. As the nuclei of these cells all lie in the same plane, they form a distinct narrow band, which is known as the *zone of oval nuclei*. (*c*) A thin filamentous process which extends from the nuclear portion down between the cells of the deeper layers. This process is irregular and pitted by pressure of surrounding cells. It usually forks and apparently anastomoses with processes of other cells to form a sort of protoplasmic reticulum.

(2) The *olfactory cells* lie between the sustentacular cells. Their nuclei are spherical, lie at different levels, and are most of them more deeply placed than those of the sustentacular cells. They thus form a broad band, the *zone of round nuclei*. From the nuclear portion of the cell a delicate process extends to the surface, where it ends in several minute hair-like processes. From the opposite pole of the cell a longer process extends centrally as a centripetal nerve fibre. The olfactory cell is thus seen to be of the nature of a ganglion cell or neurone, the short peripherally directed process its dendrite, the long centrally directed process its axone (see also page 438).

Between the nuclear parts of the olfactory cells and the basement membrane are the *basal cells*. These are small nucleated elements, the irregular branching protoplasm of which anastomoses with that of neighboring basal cells and of the sustentacular cells to form the peculiar protoplasmic reticulum already mentioned.

The *basement membrane* is not well developed.

The *stroma* consists of loosely arranged white fibres, delicate elastic fibres, and connective-tissue cells. Embedded in the stroma are large numbers of simple branched tubular glands, the glands of Bowman. Each tubule consists of a duct, a body, and a fundus. The secreting cells are large and irregular and contain a yellowish pigment, which with that of the sustentacular cells is responsible for the peculiar color of the olfactory mucosa. These glands were long described as serous, but are now believed to be mucous in character. They frequently extend beyond the limits of the olfactory region.

The Larynx

The larynx consists essentially of a group of cartilages united by strong fibrous bands and lined with mucous membrane.

The *epithelium* covering the true vocal cords, the laryngeal surface of the epiglottis, and the anterior surface of the arytenoid cartilages is of the stratified squamous variety with underlying papillæ, similar to that of the pharynx. With these exceptions the mucous membrane of the larynx is lined with stratified columnar ciliated epithelium similar to that of the respiratory portion of the nares. Numerous goblet cells are usually present, and the epithelium rests upon a broad basement membrane. On the posterior surface of the epiglottis many taste buds (see page 666) are embedded in the epithelium.

The *stroma* is especially rich in elastic fibres. The true vocal cords consist almost wholly of longitudinal elastic fibres covered by stratified squamous epithelium. Lymphoid cells are present in varying numbers. In some places they are so numerous that the tissue assumes the character of diffuse lymphoid tissue. Distinct nodules sometimes occur.

Owing to the absence of a muscularis mucosæ the stroma passes over with no distinct line of demarcation into the submucosa. This is a more loosely arranged, less cellular connective tissue, and contains simple tubular glands lined with both serous and mucous cells.

Externally the submucosa merges into a layer of more dense fibrous tissue which connects it with the laryngeal cartilages and with the surrounding structures. Immediately surrounding the cartilages the connective tissue forms an extremely dense layer, the perichondrium.

Of the *cartilages* of the larynx, the epiglottis, the middle part of the thyreoid, the apex and vocal process of the arytenoid, the cartilages of Santorini and of Wrisburg are of the yellow elastic variety. The main body of the arytenoid, the rest of the thyreoid and the cricoid cartilages are hyaline. After the twentieth year, more or less ossification is usually found in the cricoid and thyreoid cartilages.

The Trachea

The walls of the trachea consist of three layers—mucosa, submucosa, and fibrosa (Fig. 206).

The mucosa is continuous with that of the larynx, which it closely resembles in structure. It consists of a stratified columnar ciliated

epithelium, with numerous goblet cells, resting upon a broad basement membrane, and of a stroma of mixed fibrous and elastic tissue containing many lymphoid cells.

The submucosa is not distinctly marked off from the stroma on account of the absence of a muscularis mucosæ. It is distinguished from the stroma by its looser, less cellular structure, by its numerous large blood-vessels, and by the presence of glands. These are of the simple branched tubular variety and are lined with both serous and

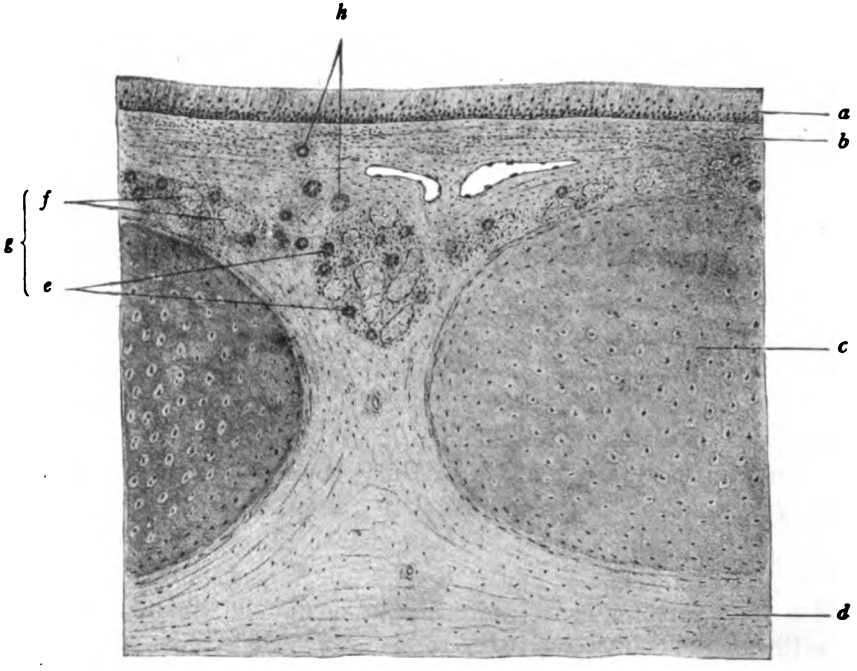

FIG. 206.—From Longitudinal Section of Human Trachea. ×40. (Technic 3, p 310.) *a*, Epithelium; *b*, stroma; *c*, cartilage; *d*, fibrous coat; *e*, serous tubules; *f*, mucous tubules; *g*, glands in submucosa; *h*, ducts.

mucous cells. Some of the mucous tubules have well-marked crescents of Gianuzzi. The glands are most numerous between the ends of the cartilaginous rings, where they frequently penetrate the muscle and extend into the fibrosa.

The fibrosa is composed of coarse, rather loosely woven connective-tissue fibres embedded in which are the ***tracheal cartilages***. These are incomplete rings of hyaline cartilage shaped like the letter C (Fig. 207). They are from sixteen to twenty in number and encircle about four-fifths of the tube, being open posteriorly. The openings

between the ends of the cartilaginous rings are bridged over by a thickened continuation of the fibrous coat, strengthened by a layer of smooth muscle (Fig. 207, *m*). The bundles of muscle cells run mainly in a transverse direction, and extend across the intervals between adjacent rings as well as between their open ends. There

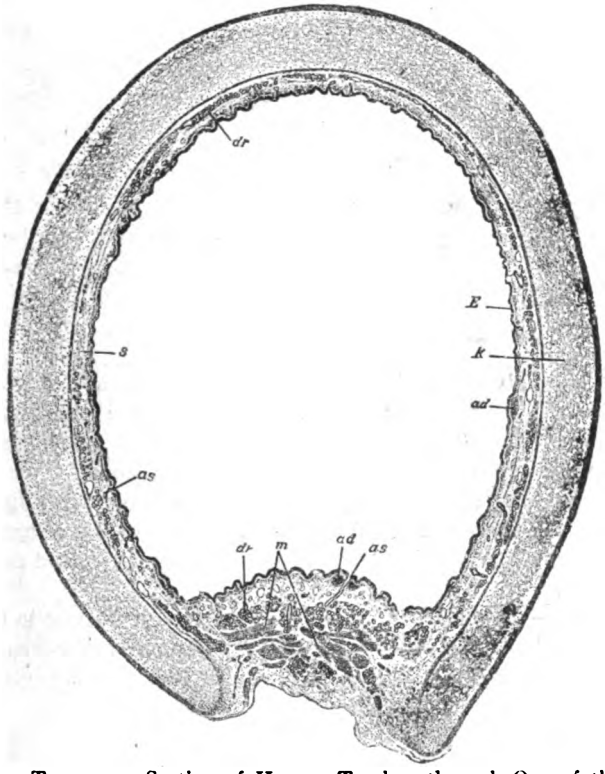

FIG. 207.—Transverse Section of Human Trachea through One of the Cartilage Rings. ×8. (Kölliker.) *E*, Epithelium of (*s*) mucous membrane; *dr*, glands; *as*, gland duct; *ad*, adenoid tissue; *K*, cartilage; *m*, smooth muscle cut longitudinally, extending across between ends of cartilage ring.

are frequently a few bundles of obliquely disposed cells and, most external, some few that run longitudinally.

Outside the fibrous coat proper is a looser, more irregular connective tissue, which serves to attach the trachea to the surrounding structures.

Blood-vessels, lymphatics, and nerves have a similar distribution in larynx and trachea. The larger vessels pass directly to the submucosa. From these, smaller branches pass to the different coats, where they break up into capillary networks.

Lymphatics form plexuses in the submucosa and mucosa, the most superficial lying just beneath the subepithelial capillary plexus.

The nerves of the larynx and trachea are derived from both cerebro-spinal and sympathetic systems. The cerebro-spinal nerves are afferent, the dendrites of spinal ganglion cells. They form a subepithelial plexus from which are given off fibrils which pass into the epithelium and terminate freely among the epithelial cells. Other afferent fibres of cerebro-spinal nerves pass to the muscular coat of the trachea. Sympathetic nerve fibres form plexuses which are interspersed with minute groups of ganglion cells. Axones from these ganglion cells have been traced to the smooth muscle cells of the trachea. Sympathetic axones also pass to the glands of the trachea and larynx. On the under surface of the epiglottis small taste buds are found.

TECHNIC

(1) For the study of the details of structure of the walls of the nares and larynx, fix small pieces of perfectly fresh material from different regions in formalin-Müller's fluid (technic 6, p. 7), harden in alcohol, stain sections with hæmatoxylin-eosin (technic 1, p. 23), and mount in balsam.

(2) The general relations of the parts can be studied by removing the larynx, upper part of the trachea, and corresponding portion of the œsophagus of an animal or of a new-born child, fixing and hardening as above, and cutting longitudinal sections through the entire specimen.

(3) Trachea.—Remove a portion of the trachea and treat as in technic (1). Both longitudinal and transverse sections should be made; the longitudinal including at least two of the cartilaginous rings; the transverse being through one of the rings.

The Bronchi

The primary bronchi and their largest branches have essentially the same structure as the trachea except that the cartilaginous rings are not as complete. Bronchi branch at acute angles and also give off small side branches.

As they decrease in calibre, the following changes take place in their walls (Figs. 208 to 211).

(1) The epithelium gradually becomes thinner. In a bronchus of medium size (Fig. 208) it has become reduced to three layers of cells, which Kölliker describes as an outer "basal" layer, a middle "replacing" layer, and a surface layer of ciliated and goblet cells. In the smaller bronchi (Figs. 210, 211) the epithelium is reduced to a

single layer of ciliated cells. These are at first high, but become gradually lower as the bronchi become smaller, until in the terminal branches the epithelium is simple cuboidal and non-ciliated. Among the ciliated cells are varying numbers of mucous or goblet cells.

(2) The stroma decreases in thickness as the bronchi become smaller. It consists of loosely arranged white and elastic fibres. This layer with the epithelium is folded longitudinally (Fig. 211). There is considerable diffuse lymphatic tissue, and in some places small nodules occur, over which there may be lymphoid infiltration

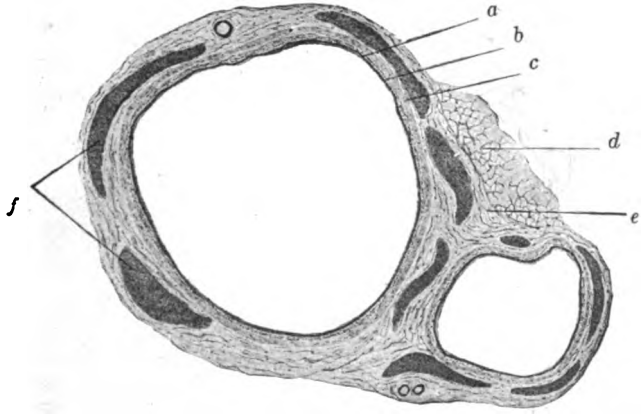

FIG. 208.—Transverse Section through two Medium-size Bronchi of the Human Lung. ×15. (Technic 2, p. 323) In the fibrous coat are seen the bronchial arteries and veins. *a*, Epithelium; *b*, stroma; *c*, muscularis mucosæ; *d*, lung tissue; *e*, fibrous coat; *f*, plates of cartilage.

of the epithelium (see Tonsil, page 183). Near the root of the lung many small lymph nodules are found, which show different degrees of pigmentation.

(3) With decrease in thickness of the epithelium and of the stroma, the thickness of the mucosa is maintained by the appearance of a layer of smooth muscle. In the larger bronchi this is a continuous layer of circularly disposed smooth muscle, and lies just external to the stroma, forming a muscularis mucosæ (Fig. 209). It reaches its greatest thickness relative to the size of the bronchus in the bronchi of medium size. As the bronchi become smaller it becomes thinner, then discontinuous, and in the smallest bronchi consists of only a few scattered muscle cells. These continue into the walls of the alveolar ducts, but are absent beyond this point.

(4) The submucosa decreases in thickness with decrease in the

calibre of the bronchi. It consists of loosely arranged connective tissue. Mixed glands (Fig. 209) are present until a diameter of about 1 mm. is reached, when they disappear. They lie in the submucosa and frequently extend through between the cartilage plates into the fibrous coat. The ducts pass through the muscular coat and open into pit-like depressions lined with a continuation of the surface ciliated epithelium.

(5) The cartilages, which in the trachea and primary bronchi form nearly complete rings, become gradually smaller, and finally break up into short disconnected plates (Figs. 208 and 209). They

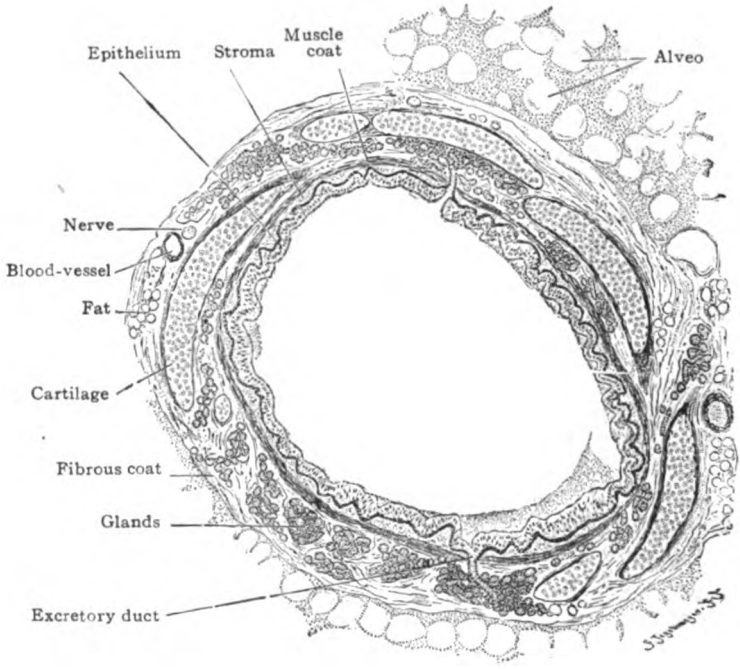

FIG. 209.—Cross Section of Human Bronchus (of a child) of 2 mm. diameter. ×30. (Stöhr.)

are frequently fibrocartilage rather than hyaline. These plates decrease in size and number, and are absent after a diameter of 1 mm. is reached. Cartilage and mucous glands thus disappear at about the same time, although it is common for glands to extend over into smaller bronchi than do the cartilage plates.

The bronchi down to a diameter of from 1.5 to 1 mm. are interlobular, and belong to the duct system down to a diameter of about

0.5 mm. From the small interlobular bronchi are given off the terminal bronchi. These are respiratory in character and are described with the lungs.

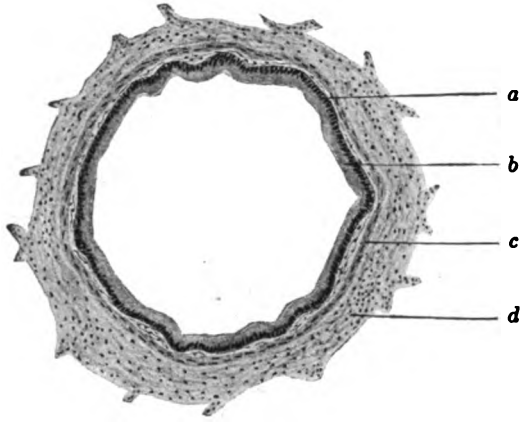

FIG. 210.—Transverse Section of Small Bronchus from Human Lung. ×115. (Technic 2, p. 323.) *a*, Stroma; *b*, epithelium; *c*, muscularis mucosæ; *d*, fibrous coat.

FIG. 211.—Transverse Section through small Bronchus of Human Lung. (Sobotta.) Simple columnar ciliated epithelium; no cartilage; no glands; mucosa folded longitudinally; elastic tissue stained with Weigert's elastic tissue stain.

In studying the bronchi it is convenient to arbitrarily divide them into large, medium-sized, and small bronchi.

Large bronchi have essentially the same structure as the trachea except for somewhat thinner walls.

Medium-sized bronchi (Fig. 2c8) have an epithelium about three layers deep, disconnected plates of cartilage, a continuous layer of smooth muscle disposed circularly as a muscularis mucosæ, and tubular glands

Small bronchi have a single layer of ciliated epithelium, a thinner muscular coat, no glands, and no cartilage. (Figs. 210, 211.)

The Lungs

The lung is built upon the plan of a compound alveolar gland, the trachea and bronchial ramifications corresponding to duct systems, the air vesicles to gland alveoli.

The surface of the lung is covered by a serous membrane—the *pulmonary pleura*—which forms its *capsule*, and which at the root of the lung, or hilum, is reflected upon the inner surface of the chest

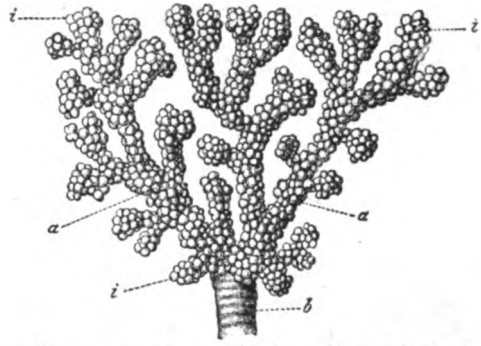

FIG. 212.—From Lung of an Ape. The bronchi and their dependent ducts and alveoli have been filled with quicksilver. ×15. (Kölliker, after Schulze.) *b*, Terminal bronchus; *a*, alveolar duct; *i*, alveoli.

wall as the *parietal pleura*. It consists of fibrillar connective tissue containing fine elastic fibres which are more numerous in the visceral than in the parietal layer. From the capsule broad connective-tissue *septa* pass into the organ, dividing it into *lobes*. From the capsule and interlobar septa are given off smaller septa, which subdivide the lobes into *lobules*.

The *human pulmonary lobule* (Figs. 213 and 215) is the anatomic unit of lung structure. Each lobule is complete in itself, having its own bronchial system, its own vascular system, and being more or less completely separated from its neighbors by connective tissue. In the young and in some lower animals the lobule is quite plainly outlined by connective tissue, but in the human adult the amount of connective tissue is extremely small, and the lobules, especially the more central, difficult of definition. The lobules are best observed at the surface of the lung where their bases which lie against the pleura can be seen with the naked eye. This is especially true in the aged

where carbon deposits in the interlobular connective tissue assist in outlining the lobules. The base of the peripheral lobule is four- to eight-sided and from 1 to 1.5 cm. in diameter. It is pyramidal in shape, narrowing to an apex about 1 to 1.5 cm. from the base. In the interior of the lung the lobules are not pyramidal but irregularly polyhedral, the apex being, however, distinguishable by the entrance of the lobular bronchus.

The apex of each lobule is the point of entrance of the lobular bronchus (branch of inter- or sublobular) (Figs. 212, 213 and 215, *bl*) which is about 0.5 mm. in diameter, and of the lobular branch of the

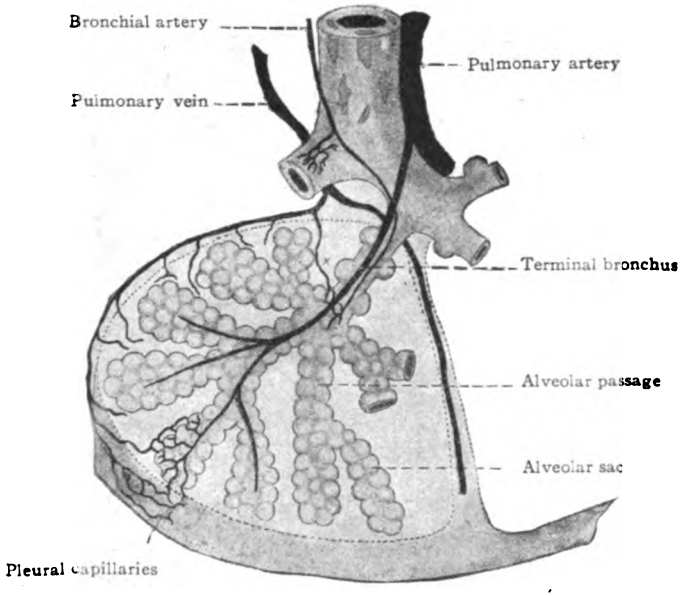

FIG. 213.—Scheme of a Pulmonary Lobule and its Blood Supply. (Stöhr.) The two main branches of the pulmonary vein are seen lying in the interlobular connective tissue.

pulmonary artery. Accompanied by the artery (Fig. 213) the bronchus passes through the central axis of the lobule, giving off collateral branches (Fig. 212, *a*, *b*), to about the middle of the lobule, where it divides into two branches (Fig. 213). These branches and also the collaterals branch dichotomously giving rise to from 50 to 100 terminal or alveolar bronchi ("terminal", as being the last subdivision of the bronchial tree which preserves its identity as a bronchus; "alveolar", as it gives off, especially toward its distal end, some alveoli). From each terminal bronchus (Fig. 215, *ba*) open from three

to six narrow passages—alveolar passages or alveolar ducts (Fig. 215, *ca*)—from which are given off the alveoli—air vesicles or air cells* (Figs. 214 and 215, *d*). The somewhat dilated distal end of the alveolar passage is sometimes designated the alveolar sac or infundibulum (Fig. 215, *i*). Laguesse divides the lobule schematically into three parts a proximal part containing the intralobular bronchus and

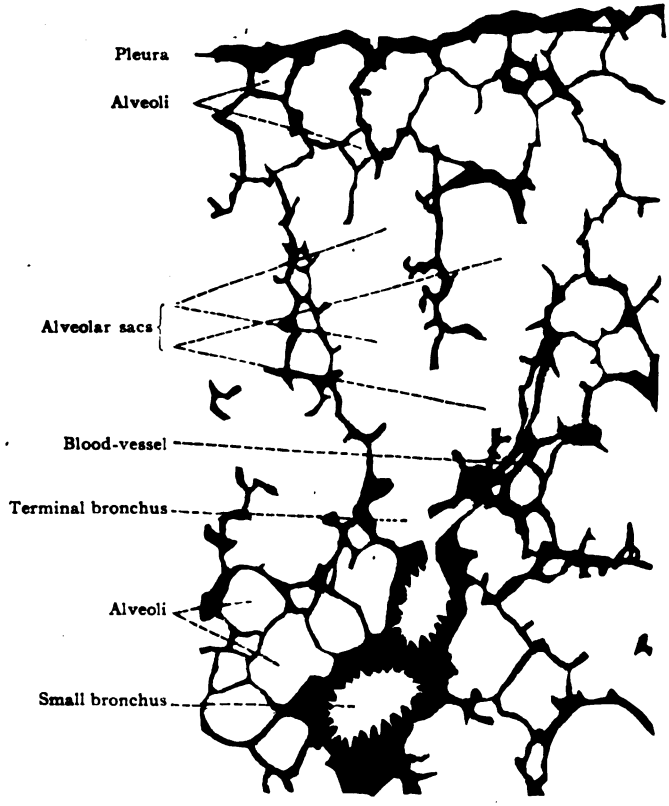

FIG. 214.—Section of Cat's Lung (Szymonowicz), surface lobule; terminal bronchus opening into alveolar duct from which are given off two alveolar sacs.

collaterals, a middle part in which the main division of the lobular bronchus occurs, and a third part containing the alveolar bronchi and alveoli.

The *terminal bronchus* (Figs. 213, 214, 215, *ba*). The proximal portion of the terminal bronchus is lined by a simple columnar

* The dilatation of the terminal bronchus from which are given off the alveolar passages is sometimes called the *vestibule* (Fig. 215, *v*).

ciliated epithelium, resting upon a basement membrane. Beneath this is a richly elastic stroma containing bundles of circularly disposed smooth muscle cells. The epithelium becomes gradually lower and non-ciliated, and near the distal end of the terminal bronchus there appear small groups or islands of flat, non-nucleated epithelial cells—*respiratory epithelium*.

FIG. 215.—Section of Lung of Rat to show Arrangement of Bronchial Ramifications and of Alveoli within a Single Lobule. *bl*, Lobular or sublobular bronchus; *bil*, intralobular bronchus; *ba*, terminal bronchus; *v*, dilatation sometimes called vestibule; *ca*, alveolar passage; *i*, portion sometimes called infundibulum; *d*, alveoli, some of which are so cut as to show their openings into the infundibulum and alveolar canals, etc., while others appear closed. ×60. (Prenant.)

The *alveolar passage* (Fig. 215, *ca*). Here the cuboidal epithelium is almost completely replaced by the respiratory. Beneath the epithelium the walls have a structure similar to those of the distal end of the terminal bronchus, consisting of delicate fibro-elastic tissue with scattered smooth muscle cells. The basement membrane is extremely thin.

The *alveolus* (Figs. 215, *d*, 216). The epithelium of the alveolus consists of two kinds of cells, respiratory cells and so-called "*fœtal*" cells (see Development, page 321).

The *respiratory cells* (Fig. 216) are some of them large, flat, non-nucleated plates, while others are much smaller, non-nucleated elements. The absence of nuclei and the extremely small amount of intercellular substance render these cells quite invisible in sections stained by the more common methods. The cell boundaries are best demonstrated by means of silver nitrate (technic 1, p. 82).

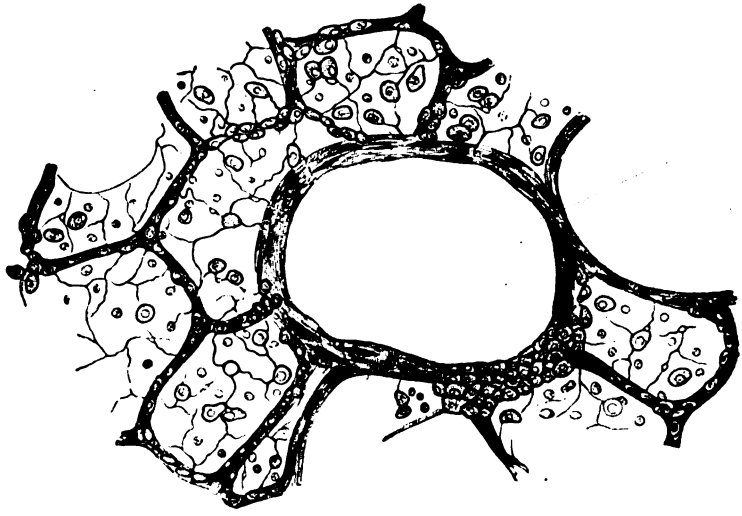

FIG. 216.—From Section of Cat's Lung Stained with Silver Nitrate. (Klein.) (Technic 1, p. 82.) Small bronchus surrounded by alveoli, in which are seen both flat cells (respiratory epithelium) and cuboidal cells (fœtal cells).

The "*fœtal*" *cells* are granular, nucleated cells which are scattered among the respiratory cells (Fig. 216). Their position appears to be less superficial than that of the respiratory cells, the fœtal cells lying in the meshes of the capillary network, the respiratory cells covering the capillaries. In the embryonic lung and in the lungs of a still-born child the air passages and alveoli contain only this type of cells, the small flat plates apparently resulting from a flattening out of the cuboidal cells due to pressure from inspiration, and the large flat plates to union of a number of small plates. Delicate elastic fibrils support the respiratory and fœtal cells. Around the opening of the alveolus the elastic fibres are more numerous, forming a more or less definite ring. The disposition of elastic tissue in the wall of the

alveoli is undoubtedly of importance in determining the contraction and expansion of the alveoli under varying conditions of pressure. It has been estimated that on forced inspiration an alveolus can expand to three times its resting capacity. Each alveolus communicates not only with its alveolar passage, or alveolar bronchus, by means of a broad opening, but alveoli are connected with one another by minute openings in their walls.

The *interalveolar connective tissue*, while extremely small in amount, serves to separate the alveoli from one another. Somewhat thicker connective tissue separates the alveoli of one alveolar passage from

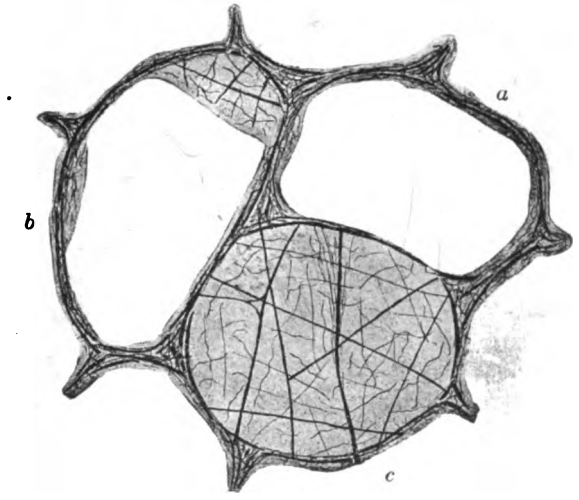

FIG. 217.—Section Through Three Alveoli of Human Lung. ×235. Weigert's elastic-tissue stain (technic 3, p. 28) to show arrangement of elastic tissue. *a*, Alveolus cut through side walls only; *b*, alveolus cut through side walls and portion of bottom or top; *c*, alveolus in which either the bottom or top is included in section.

those of another. Still stronger connective-tissue bands as already noted separate adjacent lobules.

Blood-vessels.—Two systems of vessels distribute blood to the lungs. One, the *bronchial system*, carries blood for the nutrition of the lung tissue. The other, the much larger *pulmonary system*, carries blood for the respiratory function (Fig. 213).

The *bronchial artery* and the *pulmonary artery* enter the lung at its hilum. Within the lung the vessels branch, following the branchings of the bronchi, which they accompany (Fig. 213). The pulmonary vessels are much the larger and run in the connective tissue *outside* the bronchial walls. The bronchial vessels lie *within* the fibrous coat of the bronchus. A section of a bronchus thus usually shows

the large pulmonary vessels, one on either side of the bronchus, and two or more small bronchial vessels in the walls of the bronchus (Fig. 208).

The *pulmonary lobule* forms a distinct "blood-vascular unit." A branch of the pulmonary artery enters the apex of each lobule close to the lobular bronchus, and almost immediately breaks up into branches, one of which passes to each alveolar passage (Fig. 213). From these are given off minute terminal arterioles which pass to the



FIG. 218.—Parts of Four Alveoli from Section of Injected Human Lung. ×200. (Technic 5, p. 323.) *a*, Wall of alveolus seen on flat; *c*, same, but only small part of alveolar wall in plane of section; *b*, alveoli in which plane of section includes only side walls; alveolar wall seen on edge.

central sides of the alveolar passages and alveoli, where they give rise to a rich capillary network. This capillary network is extremely close-meshed, and invests the alveoli on all sides (Fig. 218). Similar networks invest the walls of the respiratory bronchi, the alveolar ducts, and their alveoli. All of these capillary networks freely anastomose.

There are thus interposed between the blood in the capilaries and the air in the alveoli only three extremely thin layers: (1) The thin endothelium of the capillary wall; (2) the single layer of flat

respiratory epithelial plates; and (3) the delicate basement membrane upon which the respiratory epithelium rests together with an extremely small amount of fibrous and elastic tissues (see diagram, Fig. 219.)

The *veins* begin as small radicles, one from the base of each alveolus (Fig. 213). These empty into small veins at the periphery of the lobule. These veins at first run in the interlobular connective tissue away from the artery and bronchus. Later they empty into the large pulmonary trunks which accompany the bronchi.

The *bronchial arteries* break up into capillary networks in the walls of the bronchi, supplying them as far as their respiratory divisions, beyond which point the capillaries belong to the pulmonary system. The bronchial arteries supply the walls of the bronchi, the bronchial lymph nodes, the walls of the pulmonary vessels, and the pulmonary pleura. Of the bronchial capillaries some empty into the bronchial veins, others into the pulmonary veins.

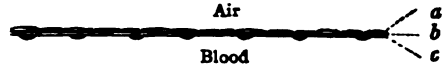

FIG. 219.—Diagram of Tissues Interposed Between Blood and Air in Alveolus. *a*, Respiratory epithelium; *b*, fibro-elastic tissue; *c*, endothelium of capillary. As *b* does not form a continuous membrane, the capillary wall is in many places in direct apposition with the respiratory epithelium, so that only two layers, *a* and *b*, are interposed between blood and air.

Lymphatics.—The lymphatics of the lung begin as small lymph spaces in the interalveolar connective tissue. These communicate with larger lymph channels in the interlobular septa. Some of these empty into the deep pulmonary lymphatics, which follow the pulmonary vessels to the lymph glands at the root of the lung. Others empty into the superficial pulmonary lymphatics, which form an extensive subpleural plexus connected with small subpleural lymph nodes, whence by means of several larger vessels the lymph is carried to the lymph nodes at the hilum.

Nerves.—Bundles of medullated and non-medullated fibres accompany the bronchial arteries and veins. Small sympathetic ganglia are distributed along these nerves. The fibres form plexuses in the fibrous layer of the bronchi, from which terminals pass to the muscle of the bronchi and of the vessel walls and to the mucosa. Free endings upon the epithelium of bronchi, air passages, and alveoli have been described.

DEVELOPMENT OF THE RESPIRATORY SYSTEM

The epithelium of the respiratory system develops from entoderm, the connective-tissue elements from mesoderm. The first differentiation of respiratory

system appears as a dipping down of the entoderm of the floor of the primitive pharynx (some investigators describe two original evaginations, one for each lung). The tubule thus formed divides into a larger and longer right branch, which subdivides into three branches corresponding to the three lobes of the future right lung, (Fig. 220, b, b, b) and a smaller and shorter left branch, which subdivides into two branches corresponding to the two lobes of the future left lung. By repeated subdivisions of these tubules the entire bronchial system is formed. Up to this point (about six months in human fœtus) the development

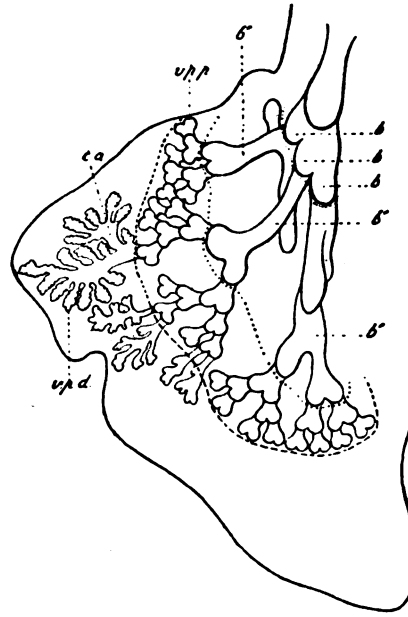

FIG. 220.—Scheme of Development of Lung (Right). *b*, *b*, *b*, the three primary bronchial buds; *b'*, *b'*, *b'*, collateral branches and secondary buds, terminating in *vpp*, the primary vesicles; *vpd*, pulmonary vesicles proper or alveoli; *oa*, alveolar canals. The broken line ----- limits the stage of the three primary lung buds; between this line and the line ..... only the three primary buds, their collaterals and secondary buds; between the line ..... and line ———, the stage of dichotomous division and of termination in primary vesicles. Up to this point the development is that of a compound alveolar gland. From this line to the surface represents the final period of development, which is peculiar to the lung and results in the formation of the pulmonary alveoli. (Prenant.)

is that of a compound alveolar gland, (Fig. 220). The last to develop are the respiratory divisions of the bronchi with their alveolar passages and alveoli. The appearance of the alveoli is wholly characteristic of lung (Fig. 220, *vpd*.) The epithelium of the alveoli is at first entirely of the fœtal-cell type, the large flat respiratory plates appearing only late in fœtal life. Just how and when the flattening of the epithelial cells takes place is not definitely known. The accepted theory has been that the cells become flattened rather suddenly at birth as a result of the first inspiration. Some authors describe a gradual thinning of the cells from the sixth fœtal month on. Bikfalir describes a gradual thinning

which is completed rather rapidly on inspiration. The fœtal and respiratory cells of the adult lung have the same embryonic origin. During the early stages of lung development the mesodermic tissue predominates, but with the rapid growth of the tubules the proportion of the two changes until in the adult lung the mesodermic tissue becomes restricted to the inconspicuous pulmonary framework and the blood-vessels.

TECHNIC

(1) The technic for the largest bronchi is the same as for the trachea (technic 3, p. 310). The medium size and small bronchi are studied in sections of the lung.

(2) Lung and Bronchi.—Carefully remove the lungs and trachea (human, dog, or cat) and tie into the trachea a cannula to which a funnel is attached. Distend the lungs moderately (pressure of two to four inches) by pouring in formalin-Müller's fluid (technic 5, p. 7), and then immerse the whole in the same fixative for twenty-four hours. Cut into small blocks, using a very sharp razor so as not to squeeze the tissue, harden in alcohol, stain thin sections with hæmatoxylin-eosin (technic 1, p. 23), and mount in balsam or in eosin-glycerin. The larger bronchi are found in sections near the root of the lung. The arrangement of the pulmonary lobules is best seen in sections near and horizontal to the surface. Sections perpendicular to and including the surface show the pulmonary pleura.

(3) Respiratory Epithelium (technic 1, p. 82).

(4) Elastic Tissue of the Lung (technic 3, p. 28).

(5) Blood-vessels.—For the study of the blood-vessels, especially of the capillary networks of the alveoli, sections of injected lung should be made. A fresh lung is injected (page 12) with blue gelatin, through the pulmonary artery. It is then hardened in alcohol, embedded in celloidin, and thick sections are stained with eosin and mounted in balsam.

General References for Further Study

Miller, W. S.: Das Lungenläppchen, seine Blut- und Lymphgefässe.
Councilman: The Lobule of the Lung and its Relations to the Lymphatics.
Kölliker: Handbuch der Gewebelehre des Menschen.

CHAPTER XVIII

THE URINARY SYSTEM

The Kidney

THE kidney is a compound tubular gland. It is enclosed by a firm connective-tissue capsule, the inner layer of which contains smooth muscle cells. In many of the lower animals and in the human fœtus, septa extend from the capsule into the gland, dividing it into a number of lobes or *renculi*. In some animals, *e.g.*, the guinea-pig and rabbit, the entire kidney consists of a single *lobe* (Fig. 221). In the adult human kidney the division into lobes is not complete, the peripheral parts of the different lobes blending. Rarely the fœtal division into lobes persists in adult life, such a kidney being known as a "lobulated kidney."

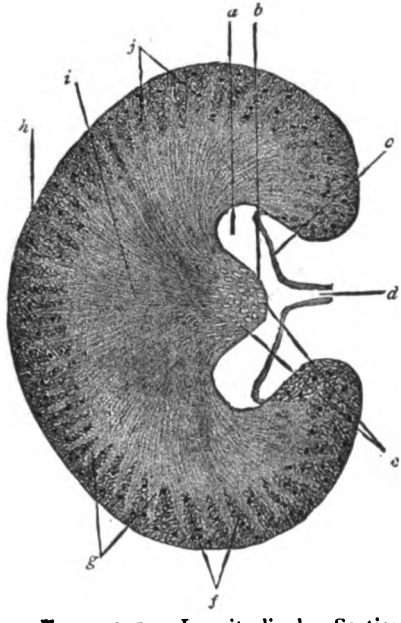

FIG. 221. — Longitudinal Section Through Kidney of Guinea-pig, including hilum and beginning of ureter. ×5. (Technic 1, p. 338.) *a*, Pelvis; *b*, papilla; *c*, wall of pelvis; *d*, ureter; *e*, ducts of Bellini; *f*, cortical pyramids; *g*, medullary rays; *h*, cortex; *i*, medulla; *j*, renal corpuscles.

On the mesially directed side of the kidney is a depression known as the *hilum* (Fig. 221). This serves as the point of entrance for the *renal artery* and of exit for the *renal vein* and *ureter*.

On section, a division of the organ into two zones is apparent to the naked eye (Figs. 221 and 222). The outer zone or *cortex* has a granular appearance, while the inner zone or *medulla* shows radial striations. This difference in appearance between cortex and medulla is mainly due, as will be seen subsequently, to the fact that in the cortex the kidney tubules are convoluted, while in the medulla they run in parallel radial lines alternating with straight blood-vessels. The medullary portion of

the kidney projects into the *pelvis*, or upper expanded beginning of the ureter (Figs. 221, *a* and 222, *g*) in the form of *papillæ* (Figs. 221, *b* and 222, *o*). The number of papillæ varies from ten to fifteen,

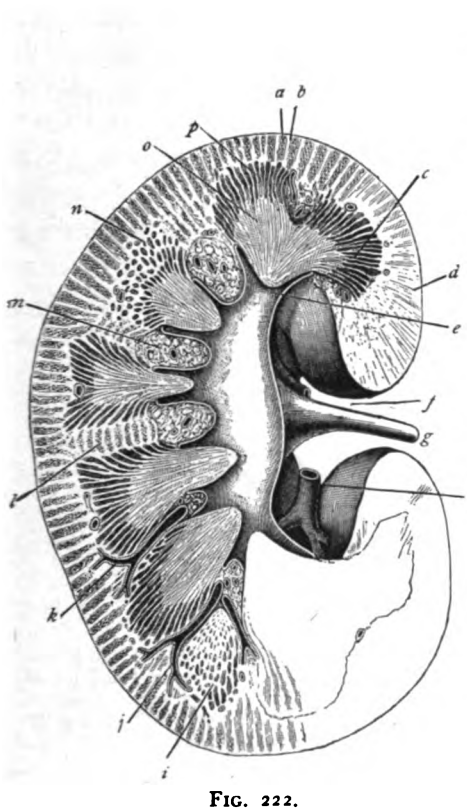

FIG. 222.

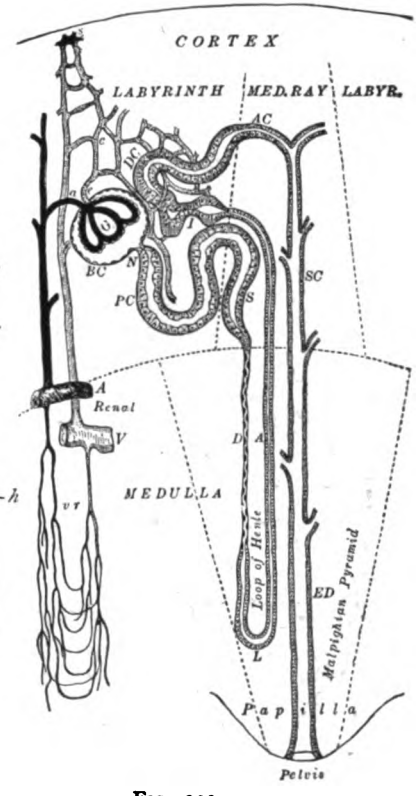

FIG. 223.

FIG. 222.—Longitudinal Section of Kidney Through Hilum. *a*, Cortical pyramid; *b*, medullary ray; *c*, medulla; *d*, cortex; *e*, renal calyx; *f*, hilum; *g*, ureter; *h*, renal artery; *i*, obliquely cut tubules of medulla; *j* and *k*, renal arches; *l*, column of Bertini; *m*, connective tissue and fat surrounding renal vessels; *n*, medulla cut obliquely; *o*, papilla; *p*, medullary pyramid. (Merkel-Henle.)

FIG. 223.—Scheme of Uriniferous Tubule and of the Blood-vessels of the Kidney showing their relation to each other and to the different parts of the kidney. *G*, Glomerulus; *BC*, Bowman's capsule; *N*, neck; *PC*, proximal convoluted tubule; *S*, spiral tubule; *D*, descending arm of Henle's loop; *L*, Henle's loop; *A*, ascending arm of Henle's loop; *I*, *DC*, distal convoluted tubule; *AC*, arched tubule; *SC*, straight collecting tubule; *ED*, duct of Bellini; *A*, arcuate artery, and *V*, arcuate vein, giving off interlobular vessels to cortex and vasa recta to medulla; *a*, afferent vessel of glomerulus; *e*, efferent vessel of glomerulus; *c*, capillary network in cortical labyrinth; *s*, stellate veins; *vr*, vasa recta and capillary network of medulla. (Pearsol.)

corresponding to the number of lobes in the fœtal kidney. The pyramidal segment of medulla, the apex of which is a papilla—in other words, the medullary portion of a fœtal lobe—is known as a

medullary or *Malpighian pyramid* (Fig. 223). The extensions downward of cortical substance between the Malpighian pyramids constitute the *columns* of *Bertini* or *septa renis* (Fig. 222, *l*). Radiating lines—*medullary rays* or *pyramids of Ferrein*—extend outward from the base of each Malpighian pyramid into the cortex (Fig. 222.) As the rays extend outward in groups they outline pyramidal cortical areas. These are known as the *cortical pyramids* or *cortical labyrinths* (Fig. 223).

The secreting portion of the kidney is composed of a large number of long tortuous tubules, the *uriniferous tubules.*

Each URINIFEROUS TUBULE begins in an expansion known as *Bowman's capsule* (Figs. 223, *BC*, and 224, 3, 4, 5). This encloses a

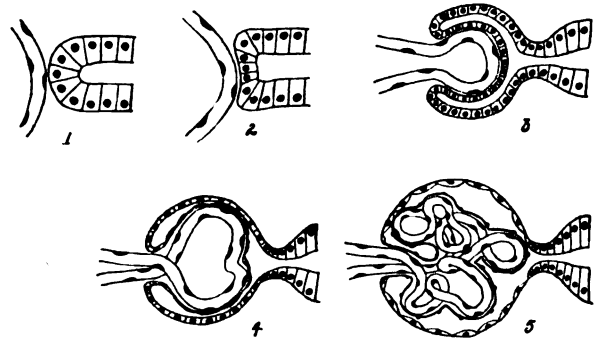

FIG. 224.—Diagrams Illustrating Successive Stages in Development of the Renal Corpuscle, 1 and 2, Approach of blood-vessel and blind end of tubule; 3, invagination of tubule by blood-vessels; 4 and 5, later stages, showing development of glomerulus and of the two-layered capsule of the renal corpuscle, the outer layer being the capsule of Bowman continuous with the epithelium of the first convoluted tubule.

tuft of blood capillaries, the *glomerulus*. Bowman's capsule and the glomerulus together constitute the *Malpighian body* or *renal corpuscle* (Fig. 225). As it leaves the Malpighian body the uriniferous tubule becomes constricted to form the neck (Figs. 223, *N*, 224, and 225, *b*). It next broadens out into a greatly convoluted portion, the *first convoluted tubule* (Fig. 223, *PC*, and Fig. 226). The Malpighian body, the neck, and the first convoluted tubule are situated in the cortical pyramid (Fig. 223). The tubule next takes a quite straight course downward into the medulla—*descending arm of Henle's loop* (Fig. 223, *D*)—turns sharply upon itself—*Henle's loop* (Fig. 223, *L*)—and passes again toward the surface—*ascending arm of Henle's loop* (Fig. 223, *A*)—through the medulla and medullary ray. Leaving the medullary ray, it enters the same cortical pyramid from which it took origin to become the *second convoluted tubule* (Fig. 223, *DC*). This tubule is in

close proximity to the Malpighian body from which it started, lying, however, on the side of the afferent and efferent blood-vessels, *i.e.*, on the side opposite its point of origin. The second convoluted tubule passes into the *arched tubule* (*AC*) which enters a medullary ray and continues straight down through the medullary ray and medulla as the *straight* or *collecting tubule* (*SC*). During its course the collecting tubule receives other arched tubules. As it descends it becomes broader, enters the papilla, where it is known as the *duct of Bellini* (*ED*) and opens on the surface of the papilla into the kidney pelvis. About twenty ducts of

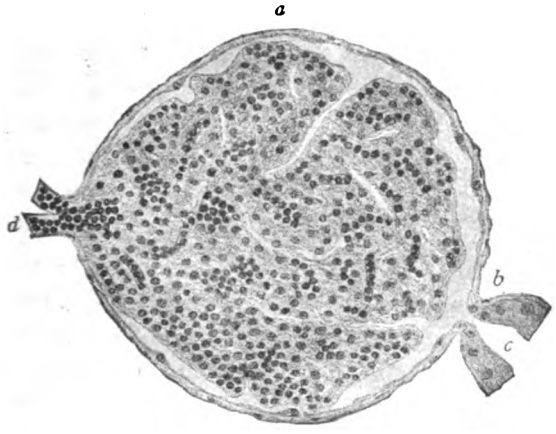

FIG. 225.

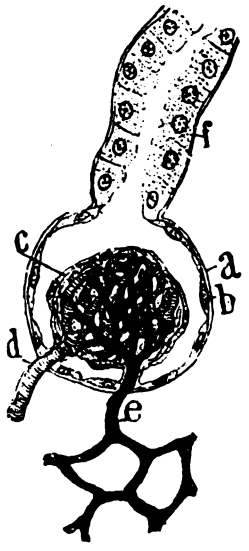

FIG. 225A.

FIG. 225.—Malpighian Body from Human Kidney. × 280. (Technic 2, p. 338.) *a*, Bowman's capsule; *b*, neck; *c*, first convoluted tubule; *d*, afferent and efferent vessels.

FIG. 225*A*.—Malpighian Body of Kidney, showing relations of Glomerulu to Blood Vessels and to Uriniferous Tubule. (Cajal.) *a*, outer layer, and *b*, inner layer of modified epithelium constituting together Bowman's capsule; *c*, Glomerulus, showing *d*, afferent vessel, breaking up into capillary network of glomerulus, the latter converging to form the efferent vessel of the glomerulus, *e*, which gives rise to a capillary network among the kidney tubules.

Bellini open upon the surface of each papilla, their openings being known as the *foramina papillaria*.

Each tubule consists of a delicate homogeneous *membrana propria* upon which rests a *single layer* of *epithelial cells*. The shape and structure of the epithelium differ in different portions of the tubule.

1. The *Malpighian body* is spheroidal, and has a diameter of from 120 to 200μ. The structure of the Malpighian body can be best understood by reference to its development (Fig. 224). During the development of the uriniferous tubules and of the blood-vessels of the kidney, the growing end of a vessel meets the growing end of a tubule

in such a way that there is an invagination of the tubule by the blood-vessel (see Fig. 224). The result is that the end of the vessel which develops a tuft-like network of capillaries—the *glomerulus*—comes to lie within the expanded end of the tubule, which thus forms a two-layered capsule for the glomerulus. One layer of the capsule closely invests the tuft of capillaries, dipping down into it and separating the groups of capillaries (see p. 333). This layer by modification of the original epithelium of the tubule is finally composed of a single layer of flat epithelial cells with projecting nuclei. The outer layer of the capsule lies against the delicate connective tissue which surrounds the Malpighian body. This layer consists of a similar though slightly higher epithelium and is known as *Bowman's capsule*. Between the glomerular layer of the capsule and Bowman's capsule proper is a space which represents the beginning of the lumen of the uriniferous tubule (Fig. 225), the epithelium of Bowman's capsule being directly continuous with that of the neck of the tubule.

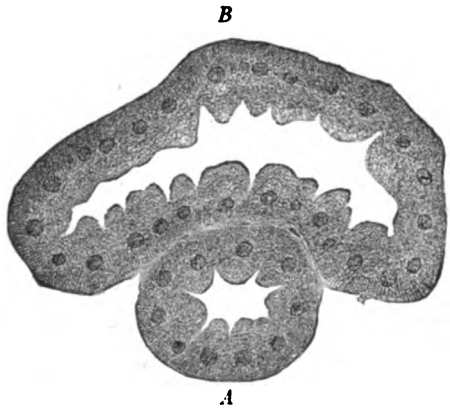

FIG. 226.—Proximal Convoluted Tubules of Human Kidney. × 350. (Technic 2, p. 338.) *A*, Cross-section; *B*, oblique section.

2. *The Neck.*—This is short and narrow, and is lined by a few cuboidal epithelial cells. Toward its glomerular end the epithelium is transitional between the flat epithelium of Bowman's capsule and the cuboidal epithelium of the neck proper. At its other end the epithelium of the neck becomes larger and more irregular as it passes over into that lining the next division of the tubule (Fig. 225, *c*).

3. The *first convoluted tubule* (Fig. 226) measures from 40 to 70μ in diameter. It is lined by irregularly cuboidal or pyramidal epithelium, with very indistinct demarcation between the cells. The cytoplasm is granular, and the granules are arranged in rows, giving the cell a striated appearance. This is especially marked at the basal end of the cell where the nucleus is situated. A zone of fine striations along the free surface frequently presents somewhat the appearance of cilia.

4. The *descending arm of Henle's loop* is narrow (Fig. 227, 1), 10 to 15μ in diameter. It is lined by a simple flat epithelium. The

part of the cell which contains the nucleus bulges into the lumen, and as the nuclei of opposite sides of the tubule usually alternate, the lumen is apt to present a wavy appearance in longitudinal sections.

5. *Henle's Loop.*—The epithelium here changes from the flat of the descending arm to the cuboidal of the ascending arm. The exact point where the transition occurs varies. It may take place during the turn of the loop, or in either the ascending or descending arm.



FIG. 227.—Tubules of Human Kidney. ×560. From longitudinal section. (Technic 2, p. 338.) 1, Descending arm of Henle's loop; 2, ascending arm of Henle's loop; 3, collecting tubule; 4, duct of Bellini. Beneath the longitudinal sections are seen cross sections of the same tubules.

6. The *ascending arm of Henle's loop* (Fig. 227, 2) is broader than the descending, measuring from 20 to 30μ in diameter. Its epithelium is cuboidal with granular striated protoplasm. The cells thus resemble those of the convoluted tubule, but are smaller, more regular, and less granular.

7. The *second convoluted tubule* has a diameter of 40 to 50μ. It is much less tortuous than the first convoluted tubule. Its epithelium is similar to that lining the first convoluted tubule except that it is slightly lower and less distinctly striated.

8. The *arched tubule* has a somewhat narrower lumen (about 25μ) than the second convoluted. It is lined with a low cuboidal epithelium with only slightly granular cytoplasm.

9. The *straight* or *collecting tubule* (Fig. 227, 3) has at its commencement at the apex of a medullary ray a diameter of from 40 to 50μ. As it descends it receives other arched tubules, and increases in diameter until in the *ducts of Bellini* (Fig. 227, 4) of the papilla it has a diameter of from 200 to 300μ and a widely open lumen. The epithelium is at first low and gradually increases in height. In the

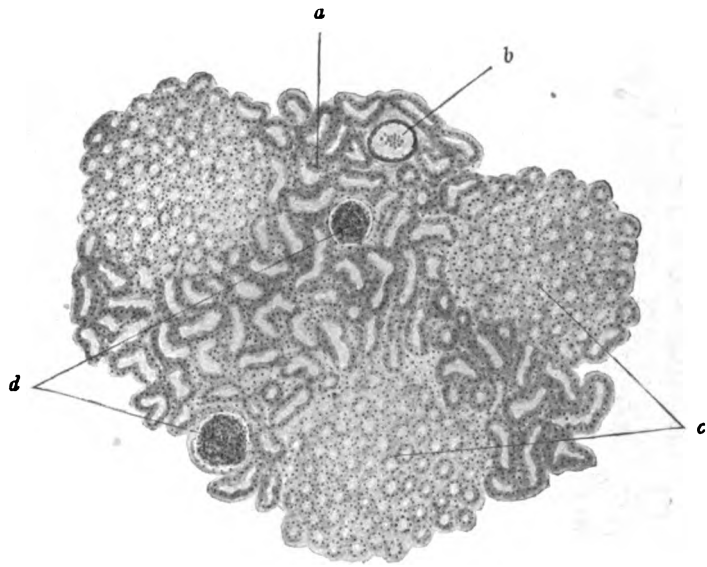

FIG. 228.—Cross Section Through Cortex of Human Kidney. ×60. (Technic 2, p. 338.) *a*, Convoluted tubules of cortical pyramid; *b*, interlobular artery; *c*, medullary rays; *d*, Malpighian bodies.

ducts of Bellini it is of the high columnar type. The cytoplasm of these cells contains comparatively few granules, thus appearing transparent in contrast with the granular cytoplasm of the ascending arms of Henle's loops and of the convoluted tubules.

Location in kidney	*Portion of tubule*	*Epithelium*
Cortical labyrinth	Bowman's capsule..	Flat with bulging nuclei.
	Neck.....	Cuboidal, granular.
	First convoluted....	Pyramidal, granular; large cells with granules in rows, giving striated appearance; striated free border; indistinct cell outline.
	Second convoluted..	Similar to preceding, but cells not so distinctly striated and more regular in shape.

Location in kidney	*Portion of tubule*	*Epithelium*
Medullary ray in cortex	Arched (passing from labyrinth to ray)	Rather clear cuboidal cells.
	Part of ascending arm of Henle's loop	Cuboidal, granular, regular.
	Collecting tubule...	Cuboidal or columnar, clear; varying in height with diameter of tubule.
Medulla.....	Descending arm of Henle's loop	Clear flat cells with bulging nuclei.
	Henle's loop.....	Usually like descending, rarely like ascending arm.
	Part of ascending arm of Henle's loop	Cuboidal, granular.
	Collecting tubule...	Cuboidal or columnar, clear; varying in height with diameter of tubule.
Papilla.....	Ducts of Bellini.....	Clear, cuboidal or columnar cells according to diameter of tubule.

The epithelium of the uriniferous tubule rests upon an apparently structureless basement membrane. Rühle describes the basement membrane as consisting of delicate longitudinal and circular connective-tissue fibrils. He regards the fibrils as merely a more regular arrangement of the interstitial connective tissue. According to Rühle the epithelium simply *rests upon* the basement membrane, being in no way connected with it. In the cortex the tubules are closely packed and the amount of interstitial connective tissue is extremely small. In the medulla the connective tissue is more abundant.

Of the function of the different parts of the uriniferous tubule our knowledge is extremely limited. The water of the urine is secreted in the Malpighian body, some specific action of the cells covering the glomerulus, allowing the water, normally free from albumen, to pass from the capillaries into the lumen of the tubule. The urinary solids are secreted mainly or wholly by the cells of the convoluted tubules and of the ascending arm of Henle's loop.

Blood-vessels (diagram, Fig. 230).—The blood supply to the kidney is rich and the blood-vessels come into intimate relations with the tubules. The *renal artery* enters the kidney at the hilum, and

immediately splits up into a number of branches—the *interlobar arteries* (Fig. 230, *g*). These give off twigs to the calyces and to the capsule, then without further branching pass between the papillæ through the medulla to the junction of medulla and cortex. Here they bend sharply at right angles and following the boundary line between cortex and medulla, form a series of arches, the *arteriæ arciformes* or *arcuate arteries* (Fig. 230, *d*). From the arcuate arteries two sets of vessels arise, one supplying the cortex, the other the medulla (Figs. 223 and 230).

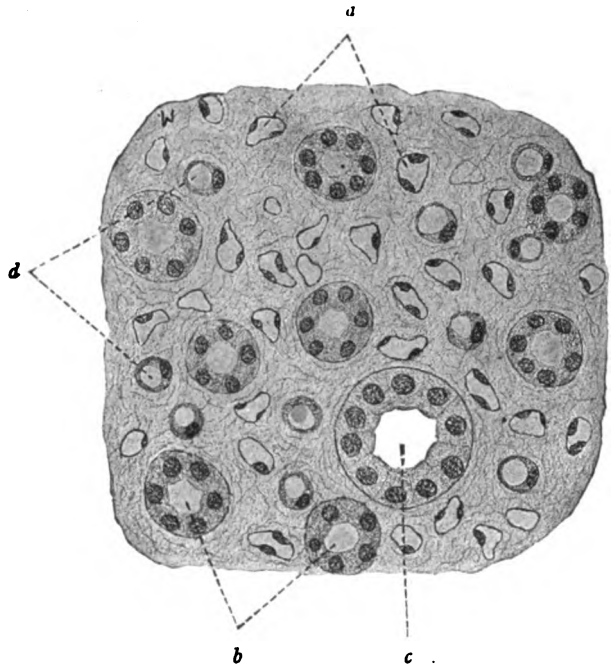

FIG. 229.—Cross Section through Medulla of Human Kidney. ×465. (Technic 2, p. 338.) *a*, Capillaries; *b*, collecting tubule; *c*, ascending arms of Henle's loops; *d*, descending arms of Henle's loops.

The *arteries to the cortex* spring from the outer (Fig. 230, *b*) sides of the arterial arches, and as *interlobular arteries* pursue a quite straight course through the cortical pyramids toward the surface, about midway between adjacent medullary rays. From each interlobular artery are given off numerous short lateral branches, each one of which passes to a Malpighian body. Entering a Malpighian body as its afferent vessel, the artery breaks up into a number of small arterioles, which in turn give rise to the groups of capillaries which form the

glomerulus. Each group of glomerular capillaries arising from a single arteriole is separated from its neighbors by a rather larger amount of connective tissue than that which separates the individual capillaries. This gives to the glomerulus its lobular appearance. From the smaller glomerular capillaries the blood passes into some-

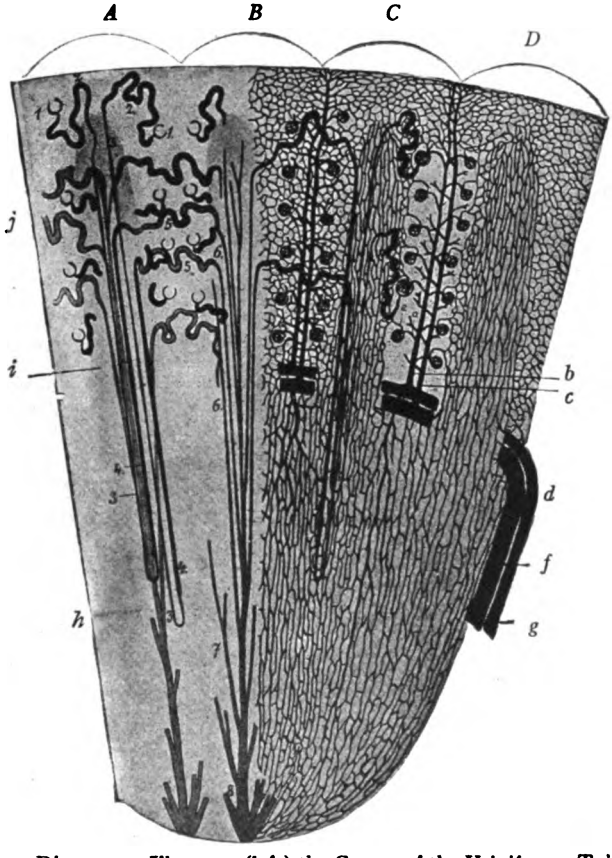

FIG. 230.—Diagram to Illustrate (left) the Course of the Uriniferous Tubule; (right) the Course of the Renal Vessels. (Szymonowicz.) *A*, *B*, *C*, *D*, each represents a kidney lobule limited laterally by the interlobular vessels; *a*, afferent vessel; *e*, efferent vessel of glomerulus; 1, Bowman's capsule; 2, first convoluted tubule; 3, descending arm of Henle's loop; 4, ascending arm of Henle's loop; 5, second convoluted tubule; 6 and 7, collecting tubules; 8, duct of Bellini; *b*, interlobular artery; *c*, interlobular vein; *d*, renal arch (arcuate artery above and arcuate vein below); in their transverse course these vessels lie along the boundary line between cortex and medulla; *f*, interlobar vein; *g*, interlobar artery; *h*, medulla; *i*, medullary ray; *j*, cortex.

what larger capillaries, which unite to form the efferent vessel of the glomerulus. As afferent and efferent vessels lie side by side, the glomerulus has the appearance of being suspended from this point (Figs. 223, 225). *The entire vascular system of the glomerulus is arterial.*

After leaving the glomerulus, the efferent vessel breaks up into a *second system of capillaries*, which form a dense network among the tubules of the cortical pyramids and of the medullary rays. The mesh corresponds to the shape of the tubules, being irregular in the pyramids, long and narrow in the rays. In these capillaries the blood gradually *becomes venous* and passes into the *interlobular veins* (Fig. 230, *c*). These accompany the interlobular arteries to the boundary between cortex and medulla, where they enter the *arcuate veins*, which accompany the arcuate arteries (Fig. 230, *d*).

The main *arteries to the medulla* arise from the inner concave sides of the arterial arches. They pass straight down among the tubules of the medulla and are known as *arteriæ rectæ*. Branching, they give rise to a long-meshed capillary network which surrounds the tubules. This capillary network is also supplied by (1) efferent vessels from the more deeply situated glomeruli (false arteriæ rectæ) and (2) by medullary branches from the interlobular arteries. The veins of the medulla arise from the capillary network and follow the arteries back to the junction of medulla and cortex, where they empty into the arcuate veins (Fig. 230, *d*).

In addition to the distribution just described, some of the interlobular arteries extend to the surface of the kidney, where they enter the capsule and form a network of capillaries which anastomose with capillaries of the suprarenal, recurrent, and phrenic arteries. A further collateral circulation is established by branches of the above-named arteries penetrating the kidney and forming capillary networks within the cortex, even supplying some of the more superficial glomeruli. The most superficial of the small veins which enter the interlobular are arranged in radial groups, having the interlobular veins as their centres. These lie just beneath the capsule, and are known as the *stellate veins of Verheyn*. In addition to capillary anastomoses, direct communication between arteries and veins of both cortex and medulla, by means of trunks of considerable size, has been described.

The **lymph vessels** of the kidney are arranged in two systems, a superficial system which ramifies in the capsule, and a deep system which accompanies the arteries to the parenchyma of the organ. Little is known of the relation of the lymphatics to the kidney tubules.

Nerves.—These are derived from both cerebro-spinal and sympathetic systems. The medullated fibres appear to pass mainly to the walls of the blood-vessels which supply the kidney capsule.

Plexuses of fine non-medullated fibres (sympathetic) accompany the arteries to the glomeruli. Delicate terminals have been described as passing from these plexuses, piercing the basement membrane and ending freely between the epithelial cells of the tubules.

The Kidney-Pelvis and Ureter

The kidney-pelvis, with its subdivisions the calyces, and the ureter constitute the *main excretory duct* of the kidney. Their walls consist of three coats: an inner mucous, a middle muscular, and an outer fibrous.

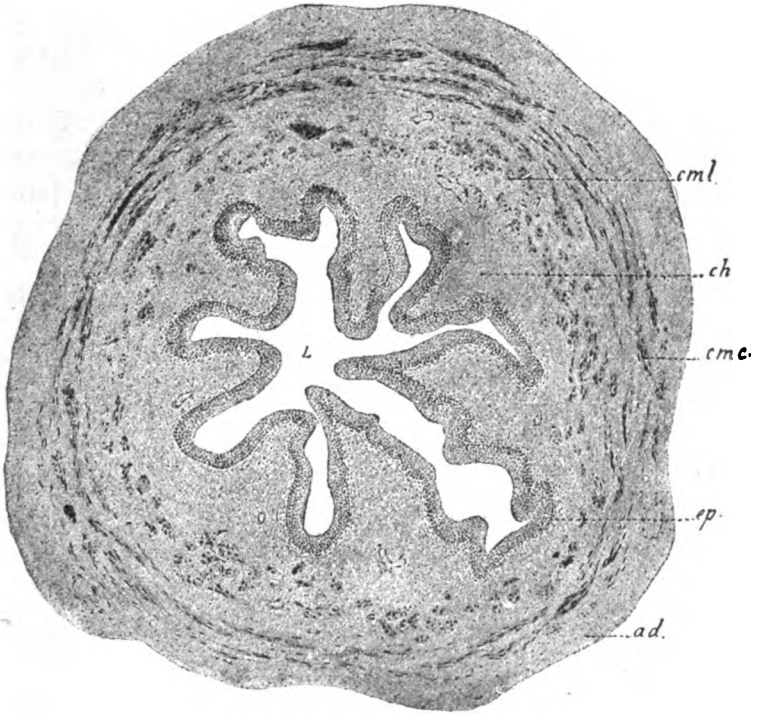

FIG. 231.—Transverse Section of Human Ureter. (Prenant.) *L*, lumen; *ep*, epithelium; *ch*, stroma; *cml*, inner longitudinal muscular layer; *cmc*, outer circular muscular layer; *ad*, fibrosa. ×25.

The mucosa is lined by epithelium of the transitional type (Fig. 231, *ep*). There are from four to eight layers of cells, the cell outlines are usually well defined, and the surface cells instead of being distinctly squamous are only slightly flattened. Less commonly large flat plate-like cells, each containing several nuclei, are present. The cells rest upon a basement membrane, beneath which is a stroma of

delicate fibrous tissue containing few elastic fibrils and rich in cells (Fig. 231, *ch*). Diffuse lymphatic tissue frequently occurs in the stroma, especially of the pelvis. Occasionally the lymphatic tissue takes the form of small nodules. Mucous glands in small numbers are found in the stroma of the pelvis and upper part of the ureter. There is no distinct submucosa, although the outer part of the stroma is sometimes referred to as such.

The muscularis consists of an inner longitudinal and an outer circular layer (Fig. 231, *cml* and *cmc*). In the lower part of the ureter a discontinuous outer longitudinal layer is added.

The fibrosa consists of loosely arranged connective tissue and contains many large blood-vessels. It is not sharply limited externally, but blends with the connective tissue of surrounding structures, and serves to attach the ureter to the latter (Fig. 231, *ad*).

The larger **blood-vessels** run in the fibrous coat. From these, branches pierce the muscular layer, give rise to a capillary network among the muscle cells, and then pass to the mucosa, in the stroma of which they break up into a rich network of capillaries. The veins follow the arteries.

The **lymphatics** follow the blood-vessels, being especially numerous in the stroma of the mucosa.

Nerves.—Plexuses of both medullated and non-medullated fibres occur in the walls of the ureter and pelvis. The non-medullated fibres pass mainly to the cells of the muscularis. Medullated fibres enter the mucosa where they lose their medullary sheaths. Terminals of these fibres have been traced to the lining epithelium.

The Urinary Bladder

The walls of the bladder are similar in structure to those of the ureter.

The mucous membrane is thrown up into folds or is comparatively smooth, according to the degree of distention of the organ. The epithelium is of the same general type—transitional epithelium (see page 77)—as that of the ureter. The number of layers of cells and the shapes of the cells depend largely upon whether the bladder is full or empty. In the collapsed organ the superficial cells are cuboidal or even columnar, their under surfaces being marked by pit-like depressions caused by pressure of underlying cells. Beneath the superficial cells are several layers of polygonal cells, while upon

the basement membrane is the usual single layer of small cuboidal cells. In the moderately distended bladder the superficial cells become flatter and the entire epithelium thinner (Fig. 232). In the distended organ there is still further flattening of the superficial cells and thinning of the entire epithelium. The stroma consists of fine loosely arranged connective tissue containing many lymphoid cells and sometimes small lymph nodules. It merges without distinct demarcation into the less cellular *submucosa* (Fig. 232, *c*).

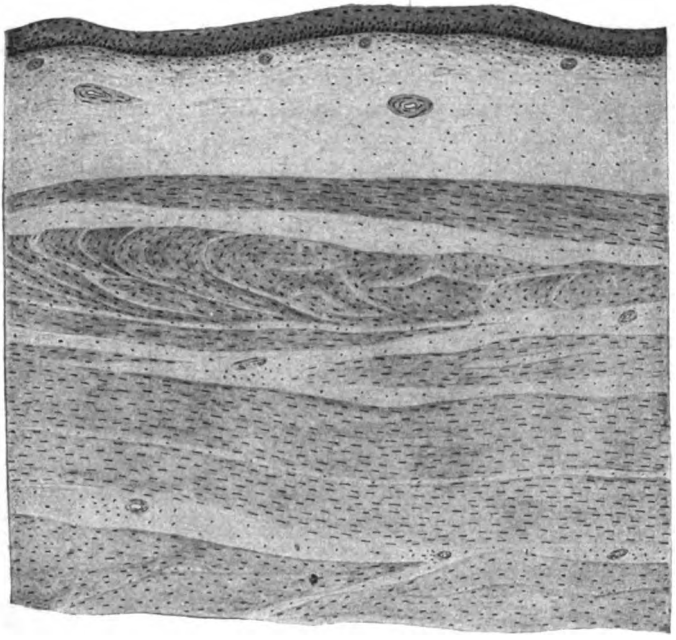

FIG. 232.—Vertical Section through Wall of moderately distended Human Bladder. ×60. (Technic 5, p. 338.) *a*, Epithelium, *b*, stroma, of mucous membrane; *c*, submucosa; *d*, inner muscle layer; *e*, middle muscle layer; *f*, outer muscle layer.

The three **muscular layers** of the lower part of the ureter are continued on to the bladder, where the muscle bundles of the different layers interlace and anastomose, but can be still indistinctly differentiated into an inner longitudinal, a middle circular, and an outer longitudinal layer (Fig. 232, *d*, *e*, *f*).

The fibrous layer is similar to that of the ureter, and attaches the organ to the surrounding structures.

The blood- and lymph-vessels have a distribution similar to those of the ureter.

Nerves.—Sensory medullated fibres pierce the muscularis, branch repeatedly in the stroma, lose their medullary sheaths, and terminate among the cells of the lining epithelium. Sympathetic fibres form plexuses in the fibrous coat, where they are interspersed with numerous small groups of ganglion cells. Axones of these sympathetic neurones penetrate the muscularis. Here they form plexuses, from which are given off terminals to the individual muscle cells.

For development of urinary system see page 382.

TECHNIC

(1) Fix the simple kidney of a rabbit or guinea-pig in formalin-Müller's fluid (technic 6, p. 7). Make sections through the entire organ including the papilla and pelvis, stain with hæmatoxylin-eosin (technic 1, p. 23), and mount in balsam. This section is for the study of the general topography of the kidney.

(2) Fix small pieces from the different parts of a human kidney in formalin-Müller's fluid or in Zenker's fluid. Thin sections should be made, some cutting the tubules longitudinally, others transversely, stained with hæmatoxylin-eosin and mounted in balsam.

(3) Blood-vessels.—For the purpose of demonstrating blood-vessels of the kidney the method of double injection is useful (page 10).

(4) Ureter.—Cut transversely into short segments, fix in formalin-Müller's fluid (technic 6, p. 7), and stain transverse sections with hæmatoxylin-eosin (technic 1, p. 23), or with hæmatoxylin-picro-acid-fuchsin (technic 3, p. 24). Mount in balsam.

(5) Bladder (technic 1, p. 259, or technic 2, p. 260). By the latter method any desired degree of distention may be obtained.

General References for Further Study

Kölliker: Handbuch der Gewebelehre, vol. iii.

Gegenbauer: Lehrbuch der Anatomie des Menschen, vol. ii.

Henle: Handbuch der Anatomie des Menschen, vol. ii.

Johnston: A Reconstruction of a Glomerulus of the Human Kidney. Johns Hopkins Hosp. Bul., vol. xi., 1900.

Müller: Ueber die Ausscheidung des Methylenblau durch die Nieren. Deutsches Archiv f. klin. Med., Bd. 63, 1899.

CHAPTER XIX

THE REPRODUCTIVE SYSTEM

I. MALE ORGANS

The Testis

THE testes are compound tubular glands of both external and internal secretions. Each testis is enclosed in a dense connective-tissue capsule, the *tunica albuginea* (Fig. 233, *a*). Outside the latter is a closed serous sac, the *tunica vaginalis*, the visceral layer of which is attached to the tunica albuginea, while the parietal layer lines the inner surface of the scrotum. Posteriorly the serous sac is wanting, the testis lying behind and outside of the tunica vaginalis. As the latter is derived from the peritoneum, being brought down with and invaginated by the testes in their descent to the scrotum, it is lined by mesothelial cells. To the inner side of the tunica albuginea is a layer of loose connective tissue rich in blood-vessels, the *tunica vasculosa*. Posteriorly the tunica albuginea is greatly thickened to form the *corpus Highmori*, or *mediastinum testis*, from which strong connective-tissue septa radiate (Figs. 233, *m* and 234, *b*). These septa pass completely through the organ and blend with the tunica albuginea at various points. In this way the interior of the testis is subdivided into a number of pyramidal chambers or *lobules*, with bases directed toward the periphery and apices at the mediastinum (Figs. 233 and 234).

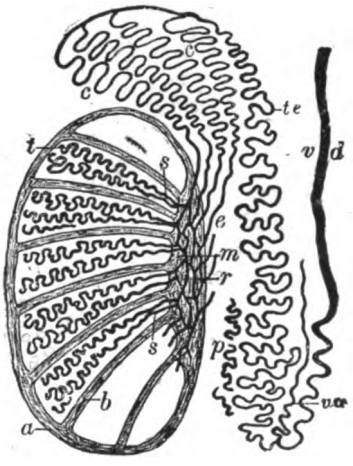

FIG. 233.—Diagram illustrating the Course and Relations of the Seminiferous Tubules and their Excretory Ducts. (Piersol.) *a*, Tunica albuginea; *b*, connective-tissue septum between lobules; *m*, mediastinum; *t*, convoluted portion of seminiferous tubule; *s*, straight tubule; *r*, rete testis; *e*, vasa efferentia; *c*, tubules of head of epididymis; *te*, vas epididymis; *vd*, vas deferens; *va*, vas aberrans; *p*, paradidymis.

Behind the testis and outside of its tunica albuginea is an elongated body—the *epididymis* (Figs. 233, *c* and 234, *c*), consisting of convoluted tubules continuous with those of the mediastinum. The epididymis is divided into three parts: an expanded upper extremity,

the *head* or *globus major* (Figs. 233 and 234, *c*); a *middle piece*, the *body* (Fig. 234, *d*); and a slightly expanded *lower extremity*, the *tail* or *globus minor*. From the last named passes off the main excretory duct of the testis, the *vas deferens* (Fig. 233, *vd*). All of the tubules of the epididymis are continuous on the one hand with the tubules of the testicle, and on the other with the vas deferens. They thus constitute a portion of the complex system of excretory ducts of the testicle.

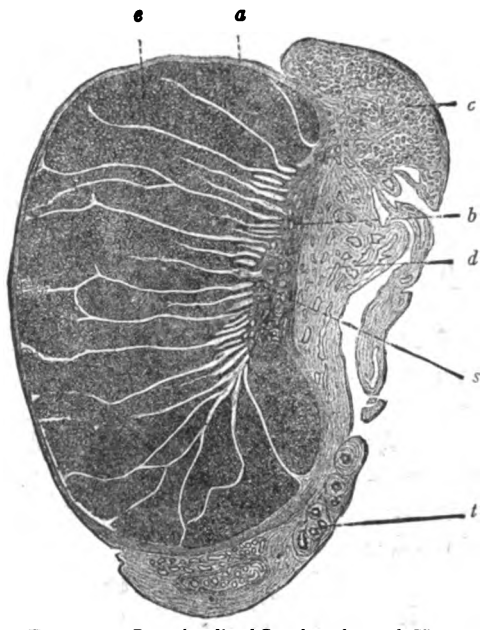

FIG. 234.—Longitudinal Section through Human Testis and Epididymis. ×2. (Böhm and von Davidoff.) The light strands are connective-tissue septa. *a*, Tunica albuginea; *b*, mediastinum and rete testis; *c*, head of epididymis; *d*, body of epididymis; *e*, lobule; *s*, straight tubules; *t*, vas epididymis.

The seminiferous tubule may be divided with reference to structure and location into three parts. (1) A much convoluted part, the ***convoluted tubule***, which begins at the base and occupies the greater portion of a lobule of the testis (Fig. 237, *a*). As they approach the apex of a lobule several of these convoluted tubules unite to form (2) the ***straight tubule*** (Figs. 233, *s*, 237). This passes through the apex of the lobule to the mediastinum, where it unites with other straight tubules to form (3) the irregular network of tubules of the mediastinum, the ***rete testis*** (Fig. 237, *c*).

1. THE CONVOLUTED TUBULE.—This, which may be considered the most important secreting portion of the tubule, since it is here that the spermatozoa are formed, has a diameter of from 150 to 250μ. The tubules begin, some blindly, others by anastomoses with neighboring tubules, near the periphery of the lobule, and pursue a tortuous course toward its apex (Fig. 237, *a*).

The wall of the convoluted tubule (Fig. 235) consists of three layers: (*a*) An outer layer composed of fibro-elastic tissue and flattened connective-tissue cells which closely invests the tubule; (*b*) a thin basement membrane; and (*c*) a lining stratified epithelium. The

epithelium consists of two kinds of cells, the so-called *supporting* or *sustentacular cells* and the *glandular cells proper*, or *spermatogenic cells*.

The *sustentacular cells*, or *columns of Sertoli*, are high, irregularly pyramidal epithelial cells. Their bases rest upon the basement membrane while their tapering cytoplasm extends through or nearly through the entire epithelium to the lumen (Fig. 236, *s*). Their sides are markedly irregular, showing pits or depressions into which

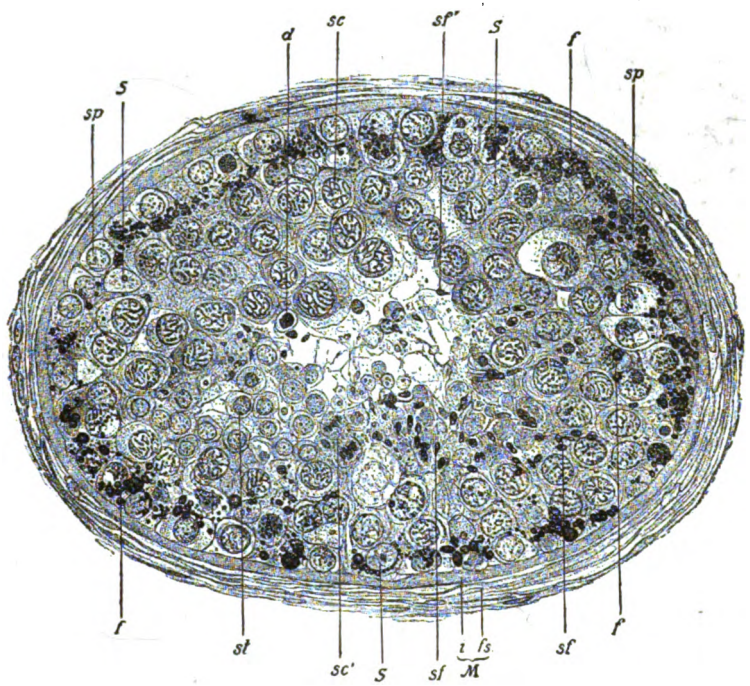

FIG. 235.—Cross Section of Convoluted Portion of Human Seminiferous Tubule ×480. (Kölliker.) *M*, Basement membrane; *i*, its inner homogeneous layer; *fs*, its outer fibrous layer; *s*, nucleus of Sertoli cell; *sp*, spermatogone; *sc*, spermatocyte; *sc'*, spermatocyte showing mitosis; *sf*, nearly mature spermatozoön; *sf'*, spermatozoön free in lumen of tubule; *d*, degenerating nucleus in lumen; *f*, fat droplets stained by osmic acid.

fit the adjoining sperm cells. Of the latter, those nearest the lumen, the spermatozoa, lie with heads embedded in the cytoplasm of the Sertoli cell, their tails directed toward or into the lumen of the tubule (Figs. 236, 238). The nuclei of the sustentacular cells lie in their broadened out bases and are easily distinguishable from those of the more numerous sperm cells by their paleness, being poor in chromatin. Their protoplasm frequently contains lipoid granules and bodies known as crystalloids. The Sertoli cells are probably sustentacular and possibly also nutritive in function. According to some they have origin in common with the sperm cells. Others

believe them derived from some entirely different source; possibly from cells of the Wolffian body.

The *spermatogenic cells* in various stages of development lie between the Sertoli columns, and, from four to six layers deep occupy the space between the basement membrane and the lumen. The appearance which the spermatogenic cells present depends upon the

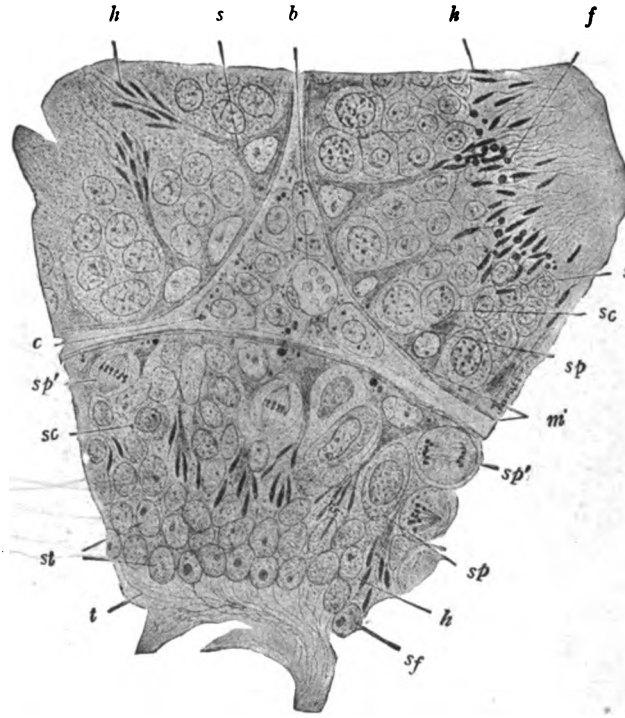

FIG. 236.—Parts of Transverse Section of three Seminiferous Tubules from Testis to White Mouse. ×600. (Szymonowicz.) *s*, Sertoli cell with nucleus; *sp*, spermatogonium, resting state; *sp'*, spermatogonium in mitosis; *sc*, spermatocyte; *st*, spermatid; *sf*, spermatid developing into spermatozoön; *h*, head of spermatozoön; *t*, tails of developing spermatozoa; *b*, blood-vessel; *c*, interstitial cell; *m*, basal membrane; *f*, fat droplets.

functional condition of the tubule. In the resting state the epithelium consists of several indistinct layers of spherical cells containing nuclei which stain with varying degrees of intensity. In the active state several more distinct but still not sharply marked off layers can be differentiated. These from without inward are as follows:

(1) *Spermatogonia* (Figs. 235 and 236, *sp*).—These are irregularly cuboidal cells which lie near the basement membrane. Their nuclei are spherical and rich in chromatin. By mitotic division of the spermatogonia are formed the later generations of spermatogonia and finally the cells of the second layer, or *spermatocytes*.

(2) *Spermatocytes* (Figs. 235 and 236, *sc*).—These may be distinguished as *spermatocytes of the first order* or *primary spermatocytes* and *spermatocytes of the second order* or *secondary spermatocytes*. The former are the direct descendants of the last generation of spermatogonia. They are large spherical cells with abundant cytoplasm and large vesicular nuclei showing various stages of mitosis, and give rise to the much smaller secondary spermatocyte. By mitotic division of the innermost spermatocytes are formed the spermatids.

(3) The *spermatids* (Figs. 235 and 236, *st*) are small round cells which line the lumen of the seminiferous tubule. They

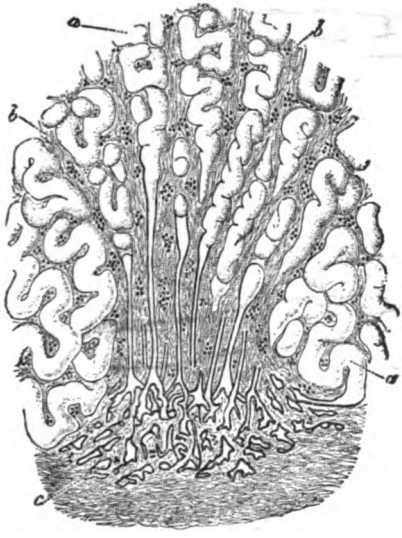

FIG. 237.

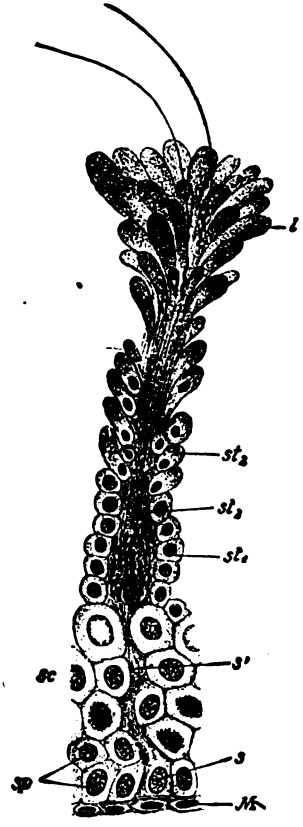

FIG. 238.

FIG. 237.—Passage of Convoluted Part of Seminiferous Tubules into Straight Tubules and of these into the Rete Testis (Milhalkowicz.) *a*, Convoluted part of tubule; *b*, fibrous stroma continued from the mediastinum testis; *c*, rete testis.

FIG. 238.—Spermatoblast with some Adjacent Sperm Cells, from Testis of Sparrow. (From Kölliker, after Etzold.) *M*, Basement membrane; *s*, nucleus of Sertoli cell; *sp*, spermatogonia; *sc*, spermatocyte; st_1 and st_2, spermatids lying along the surface of the Sertoli cell, *s'* and st_3; at st_3 are seen the nearly mature spermatozoa; *l*, tuft-like arrangement of bodies of spermatids around free end of Sertoli cell, with two mature spermatozoa.

are the direct progenitors of the spermatozoa. (For details of spermatogenesis see page 350.)

In the actively secreting testicle *spermatozoa* are frequently found either free in the lumen of the tubule or with their heads among the superficial cells and their tails extending out into the lumen (Figs. 235, sf^1 and 238). There are also found in the lumen many small

cells with dark nuclei. These are spermatids which have become free and which degenerate without forming spermatozoa.*

Separating and supporting the convoluted tubules is a small amount of interstitial connective tissue in which are the blood-vessels

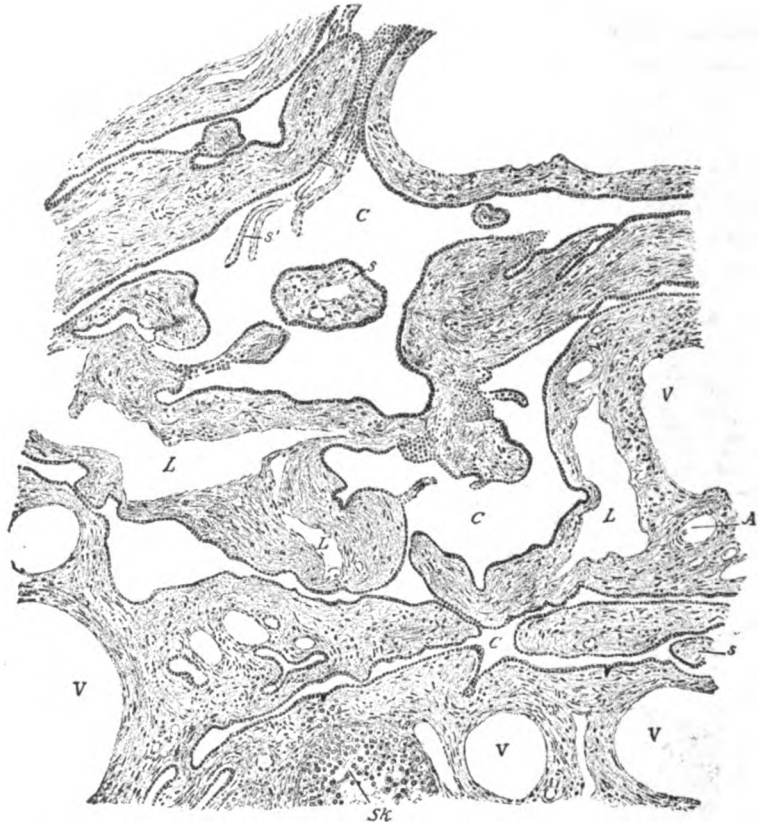

FIG. 239.—From Section through Human Mediastinum and Rete Testis. ×96. (Kölliker.) *A*, Artery; *V*, vein; *L*, lymph space; *C*, canals of rete testis; *s*, cords of tissue projecting into the lumina of the tubules and so cut transversely or obliquely; *Sk*, section of convoluted portion of seminiferous tubule.

and nerves. Among the usual connective-tissue elements are found groups of rather large spherical cells with large nuclei—***interstitial***

* In contrast with the actively functionating seminiferous tubules described above, are the tubules of non-active testes. Typical examples of non-active tubules can be studied in animals having definite breeding seasons with long intermissions. Here between seasons one finds no spermatozoa in the tubules, no spermatogenesis, only cells of the spermatogonium type and Sertoli cells. A similar condition is sometimes found in the human testis in senility or after prolonged sickness. In senility there is a general increase in fibrous tissue at the expense of elastic fibres and cells, while in the tubules sperm cells may entirely disappear, the Sertoli cells alone remaining.

cells (Fig. 236,.*c*). They are believed to represent remains of the Wolffian body.

2. THE STRAIGHT TUBULE.—With the termination of the convoluted portion, the spermatogenic tissue of the gland ends, the remainder of the tubule constituting a complex system of excretory ducts. The straight tubule is much narrower than the convoluted, having a diameter of from 20 to 40μ. It is lined with a single layer of cuboidal cells resting upon a thin basement membrane. At the apex of the lobule the straight tubules become continuous with the tubules of the rete testis.

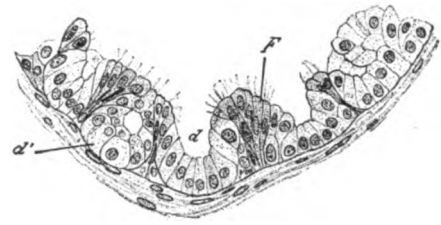

FIG. 240.—Part of a Cross Section through a Vas Efferens of the Human Epididymis. ×140. (Kölliker.) *F*, High columnar ciliated epithelium; *d*, lower non-ciliated epithelium, presenting appearance of a gland; *d'*, the same cut obliquely.

3. THE TUBULES OF THE RETE TESTIS.—These are irregular canals which vary greatly in shape and size. They are lined with a single layer of low cuboidal or flat epithelial cells (Fig. 239, *C*).

FIG. 241.—From Cross Section through Head of Epididymis. ×35. (Kölliker.) *b*, Interstitial connective tissue; *c*, sections through tubules of epididymis, showing two-layered columnar epithelium; *g*, blood-vessel.

The Seminal Ducts.—While the already described straight tubules and the tubules of the rete testis must be regarded as part of the complex excretory duct system of the testis, there are certain structures which are wholly outside the testis proper, which serve to

transmit the secretion of the testis, and are known as the seminal ducts. On leaving the testis these ducts form the epididymis, after which they converge to form the main excretory duct of the testis, the vas deferens.

THE EPIDIDYMIS.—From the tubules of the rete testis arise from eight to fifteen tubules, the *vasa efferentia*, or efferent ducts of the testis (Fig. 233, *e*). Each vas efferens pursues a tortuous course, is separated from its fellows by connective tissue, and forms one of the lobules of the head of the epididymis. The epithelium of the vasa efferentia consists of two kinds of cells, high columnar ciliated cells (Fig. 240, *F*), and, interspersed among these, low cuboidal non-ciliated cells (Fig. 240, *d*). Occasionally some of the high cells are free from cilia and some of the cuboidal cells may bear cilia. The cuboidal cells lie in groups between groups of the higher cells, often giving the appearance of crypt-like depressions. These have been referred to as intraepithelial glands. They do not, however, invaginate the underlying tissues. The epithelium rests upon a basement membrane, beneath which are several layers of circularly disposed smooth muscle cells.

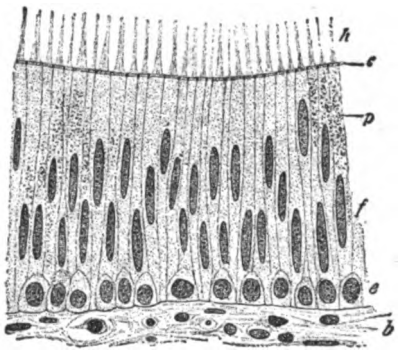

FIG. 242.—Vertical Section through Wall of Tubule of Epididymis. ×700. (Kölliker.) (Fig. 241 more highly magnified.) *b*, Connective-tissue and smooth muscle cells; *e*, basal layer of epithelial cells; *f*, high columnar epithelial cells; *p*, pigment granules in columnar cells; *c*, cuticula; *h*, cilia.

The vasa efferentia converge to form the *vas epididymis* (Fig. 241). Here the epithelium is of the stratified variety, there being two or three rows of cells. The surface cells are narrow, high, and ciliated, and their nuclei are placed at different levels (Fig. 242). The cilia are long and each cell has only a few cilia. The deeper cells are irregular in shape. The basement membrane and muscular layers are the same as in the vasa efferentia. As the vas deferens is approached the muscular coat becomes thickened, and is sometimes strengthened by the addition of scattered bundles of longitudinally disposed cells.

THE VAS DEFERENS.—The walls of the vas deferens consist of four coats—mucosa, submucosa, muscularis, and fibrosa (Fig. 243).

The *mucosa* is folded longitudinally, and is composed of a stroma

and a lining epithelium. The epithelium is of the stratified columnar type with two or three rows of cells, being similar to that lining the vas epididymis. The extent to which the epithelium is ciliated varies greatly. In some cases the entire vas is ciliated, in others only the upper portion, in still others no cilia are present beyond the epididymis. The epithelium rests upon a basement membrane beneath which is a fibro-elastic cellular stroma. The stroma merges without distinct demarcation into the more vascular *submucosa.*

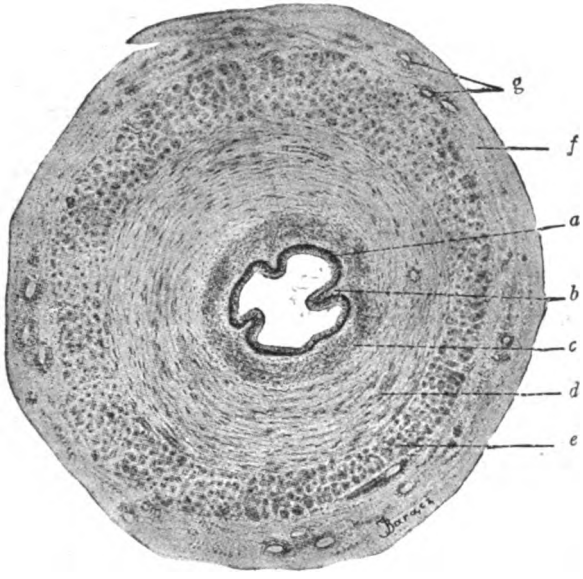

FIG. 243.—Cross Section of Human Vas Deferens. ×37. (Szymonowicz.) *a*, Epithelium; *b*, stroma; *c*, submucosa; *d*, inner circular muscle layer; *e*, outer longitudinal muscle layer; *f*, fibrous layer; *g*, blood-vessels.

The *muscularis* consists of two strongly developed layers of smooth muscle, an inner circular and an outer longitudinal (Fig. 243), which together constitute about seven-eighths of the wall of the vas. At the beginning of the vas deferens a third layer of muscle is added composed of longitudinal bundles, and situated between the inner circular layer and the submucosa.

The *fibrosa* consists of fibrous tissue containing many elastic fibres.

Near its termination the vas dilates to form the *ampulla,* the walls of which present essentially the same structure as those of the vas. The lining epithelium is, however, frequently markedly pigmented and the mucosa contains branched tubular glands.

The Seminal Vesicles and Ejaculatory Ducts.—The *seminal vesicles.* The walls of the seminal vesicles are similar in structure to those of the ampulla. The epithelium is pseudo-stratified with two or three rows of nuclei and contains a yellow pigment. When the vesicles are distended the epithelium flattens out and the nuclei lie more in one plane, thus giving the appearance of an ordinary simple columnar epithelium. Beneath the epithelium is a thin stroma, outside of which is an inner circular and an outer longitudinal layer of smooth muscle, both layers being much less developed than in the vas. The seminal vesicles are to be regarded as accessory genital glands.

The *ejaculatory ducts* are lined with a single layer of columnar cells. The muscularis is the same as in the ampulla except that the inner circular layer is thinner. In the prostatic portion of the duct the muscularis is indistinct, merging with the muscle tissue of the gland. The ducts empty either directly into the urethra or into the urethra through the vesicula prostatica.

Rudimentary Structures Connected with the Development of the Genital System.—Connected with the testicle and its ducts are remains of certain fœtal structures. These are:

(1) The *paradidymis*, or *organ of Giraldes*, situated between the vessels of the spermatic cord near the testis. It consists of several blind tubules lined with simple columnar ciliated epithelium.

(2) The *ductus aberrans Halleri*, found in the epididymis. It is lined with simple columnar ciliated epithelium and opens into the vas epididymis. Instead of a single ductus aberrans, several ducts may be present.

(3) The *appendix testis* (stalked hydatid or hydatid of Morgagni), in the upper part of the globus major. It consists of a vascular connective tissue surrounding a cavity lined with simple columnar ciliated epithelium.

(4) The *appendix epididymidis*, a vascular structure, not always present, lying near the appendix testis. It resembles the latter in structure.

The paradidymis and ductus aberrans Halleri probably represent remains of the embryonal mesonephros. The appendix testis and the appendix epididymidis are believed by some to be derived from the primitive kidney, by others from the embryonal duct of Müller.

Blood-vessels.—Branches of the spermatic artery ramify in the mediastinum and in the tunica vasculosa. These send branches into the septa of the testicle, which give rise to a capillary network among the convoluted tubules. From the capillaries arise veins which accompany the arteries.

Lymph capillaries begin as clefts in the tunica albuginea and in the connective tissue surrounding the seminiferous tubules. These

connect with the more definite lymph vessels of the mediastinum and of the spermatic cord.

Nerves.—Non-medullated nerve fibres form plexuses around the blood-vessels. From these, fibres pass to plexuses among the seminiferous tubules. Their exact method of termination in connection with the epithelium has not been determined. In the epididymis are found small sympathetic ganglia. The walls of the vasa efferentia, vas epididymis, and vas deferens contain plexuses of non-medullated nerve fibres, which give off terminals to the smooth muscle cells and to the mucosa.

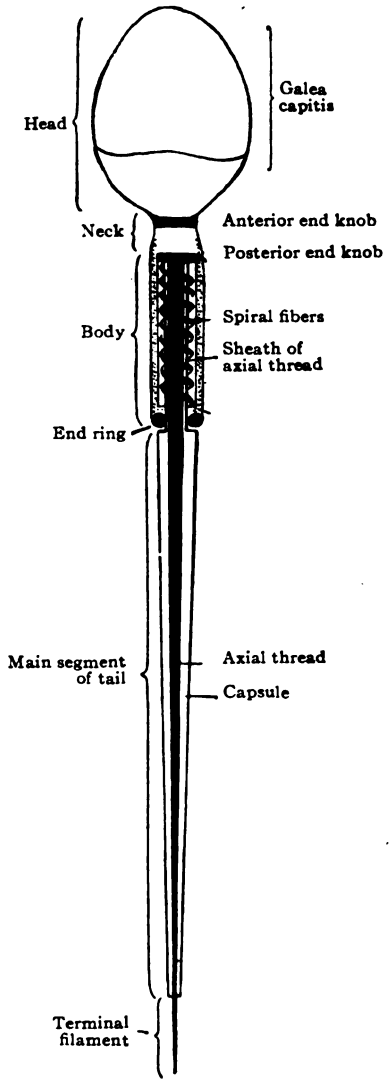

FIG. 244.—Diagram of a Human Spermatozoön. (Meves, Bonnet.)

The Spermatozoa.—The spermatozoa are the specific secretion of the testicle. Human spermatozoa are long, slender flagellate bodies, from 50 to 70μ in length, and are suspended in the semen, which is a secretion of the accessory sexual glands. The general shape is that of a tadpole; and by means of an undulatory motion of the tail, the spermatozoön is capable of swimming about freely in a suitable medium. It has been estimated that the human spermatozoa average about sixty thousand per cubic millimetre of semen.

The human spermatozoön consists of (1) a head, (2) a middle piece or body, and (3) a tail or flagellum (Fig. 244).

The *head*, from 3 to 5μ long and about half that in breadth, is oval in shape when seen on flat, pearshaped when seen on edge. It consists mainly of chromatin drived from the nucleus of the parent cell.

Enveloping the nuclear material of the head is a thin layer or delicate membrane of cytoplasm, the *galea capitis*. The front of the head ends in a sharp edge, the *apical body* or *acrosome*. In some lower forms the acrosome is much more highly developed than in man and extends forward as a pointed or barbed spear, the *perforatorium*. The acrosome is differentiated from the nuclear portion of the head by taking an acid dye, the chromatin, of course, taking a basic stain.

The *body* is cylindrical, about the same length as the head, and consists of a fibrillated central core, the *axial thread*, surrounded by a protoplasmic *capsule*. A short clear portion, the *neck*, unites the head and body. Just behind the head the axial thread presents a bulbous thickening, the *anterior end knob*, which fits into a depression in the head. At the junction of neck and body are one or several *posterior end knobs* to which the axial thread is attached. The latter leaves the body through a perforated ring, the *end ring* or *end disc*. Delicate fibrils—*spiral fibres*—run spirally around the body portion of the axial thread.

The *tail* consists of a *main segment*, from 40 to 60μ in length, and a *terminal segment* having a length of from 5 to 10μ. The main segment has a central fibrillated *axial thread* which is continuous with the axial thread of the body. This is enclosed in a thin cytoplasmic membrane or *capsule* continuous with the capsule of the body. This membrane, inconspicuous and apparently structureless in man, is remarkably developed in some lower forms, *e.g.*, the membrana undulata of birds. The terminal segment consists of the axial thread alone. The motility of the spermatozoön depends entirely upon the flagellate movements of the tail. In many of the lower animals the spermatozoön has a much more complicated structure.

Of the above-described parts of the spermatozoön only the head and tail can usually be differentiated, except by the use of special methods and very high-power objectives.

Spermatogenesis.—As already noted in describing the testicle, the spermatozoa are developed from the epithelial cells of the seminiferous tubules. It is convenient to divide the series of changes through which the sperm cells pass in their progress toward mature spermatozoa into periods or stages, although these stages merge into one another without distinct demarkation. These may be called the periods of (1) proliferation, (2) growth, (3) maturation, (4) transformation.

1. Period of proliferation (Fig. 244*B*, *b*). In an active seminiferous tubule, the primary germ cells or primary spermatogonia (Fig. 236, *sp.*, Fig. 238, *sp.*, Fig. 244*A*, A) are large clear cells with distinctly chromatic nuclei, lying near the basement membrane between the cells of Sertoli. Each cell contains the somatic number of chromosomes, one half of paternal the other half of maternal origin. These cells are in active mitosis which is of the usual somatic type described on p. 54 and known as homeotypic. The results of this proliferation of the primary spermatogonia is the production of several generations of smaller cells known as secondary spermatogonia, each cell containing the

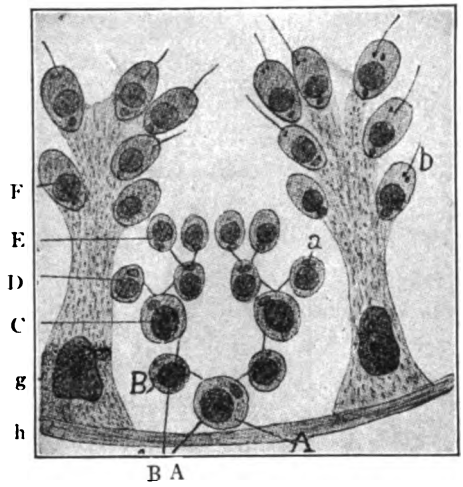

FIG. 244*A*.—Scheme of the geneological tree of the Spermatozoa. (Cajal.) The two large cells with bases against the basement membrane are Sertoli Cells. *A*, primary spermatogone; *B*, secondary spermatogone; *C*, primary spermatocyte; *D*, secondary spermatocyte; *E*, spermatid; *F*, spermatozoön; *a*, idiosome; *b*, spermatozoön showing two centrosomes and beginning tailpiece. *g*, Sertoli cell, *h*, basement membrane.

somatic or diploid number of chromosomes. These cells become progressively pushed nearer the lumen and come to occupy a position internal to the primary spermatogonia.

2. *Period of growth* (Fig. 244*A*, B, Fig. 244*B*, *b*).—Just how many are the generations of small secondary spermatogonia is indeterminate, but the final generation, ceasing to proliferate, enters upon a resting period with growth in size (Figs. 244*A*, and 244*B*, *b*). The resultant large cell is known as a primary spermatocyte or spermatocyte of the I order (Fig. 244*A*, Fig. 244*B*).

3. *Period of maturation.*—As the resting nucleus of the now fully grown primary spermatocyte prepares for division, instead of behaving in the usual manner as in the ordinary of homeotypic mitosis, it goes through a quite different process known as synapsis of the chromosomes. This consists in a fusion of the chromosomes into which the spireme has segmented, into pairs. The result is one half the number (haploid number) of pairs of chromosomes that there was of original single chromosomes (Fig. 244*C*). The fused chromosomes next split longitudinally (Fig. 244*C*, B.C.), then divide transversely, with the result that each

fused chromosome-pair breaks up into four parts, thus forming the characteristic figure known as the tetrad (Fig. 244*C*, D.E). As each tetrad is derived from one fused chromosome (of which there are one half the somatic number) the number of tetrads is the same as the number of fused chromosomes (*i.e.*, one half the somatic number). The tetrads now pass to the equator of the spindle (Fig. 244*C*, F.). As division of the cell body takes place each tetrad separates into two dyads and one dyad from each tetrad passes to each daughter cell, secondary spermatocyte or spermatocyte of the II order (Fig. 244*C*, F.G.H. and Figs. 244*A* and 244*B*, *b*). The number of dyads in each secondary spermatocyte thus equals the number of tetrads, *i.e.*, the somatic number. Without return to the resting condition, a new mitotic figure is formed (Fig. 244*C*,

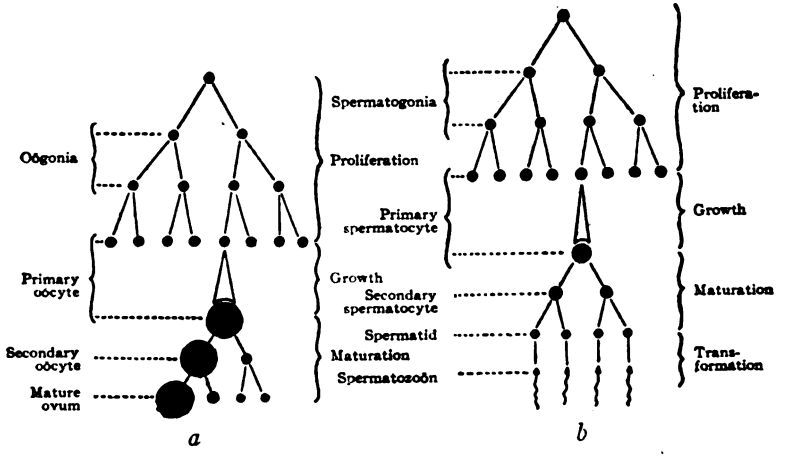

FIG. 244*B*.—Diagrams representing the comparative histogenesis of (*a*) the female sex cells and (*b*) the male sex cells. Modified from *Boveri*.

I.J.K.), with the dyads at its equator. Each dyad now separates into two monads and one monad passes to each daughter cell of spermatid (Fig. 244*C*, L). The number of monads thus received by each spermatid equals the number of tetrads. As the number of tetrads was one half the somatic number and as each primary spermatocyte—the tetrad spermatocyte—gives rise to four spermatids, each receiving one member from each tetrad, each spermatid contains the haploid number or one half the somatic number of chromosomes (Fig. 244*C*, L.). Quantitatively it contains one quarter of the chromatic content of the tetrad spermatocyte.

Accessory or *sex chromosomes:* In many lower and in some higher animal forms the somatic number of chromosomes has been found to differ in the two sexes. For example in the grasshopper (Stenobothrus viridulus) illustrated in Fig. 244*D*, the somatic number for the male is 17, for the female 18. In general it may be said that the larger number occurs in the female. This is due to the presence in the male of an odd chromosome which can often be distinguished from its fellow chromosomes by its more or less characteristic

appearance (Fig. 244*D*, 1, 2, 3). When synapsis occurs and the chromosomes fuse in pairs, the odd accessory chromosome remains unpaired and passes to the pole of the spindle. Thus when division of the cell (primary spermatocyte) occurs, only one of the two secondary spermatocytes will receive the accessory chromosome (Fig. 244,*D* 4, 5, 6, x). This results in one secondary

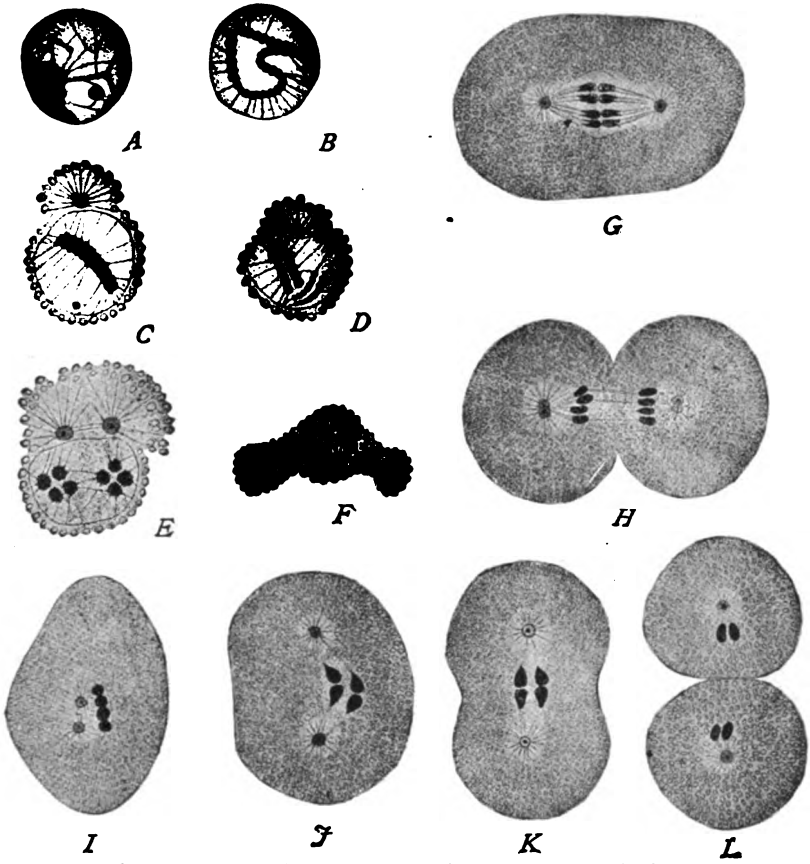

FIG. 244*C*.—Reduction of chromosomes in spermatogenesis in Ascaris megalocephala (bivalens). *Brauer, Wilson*, A–G, Successive stages in the division of the primary spermatocyte. The original reticulum undergoes a very early division of the chromatin granules which then form a doubly split spireme (B). This becomes shorter (C), and then breaks in two to form the 2 tetrads (D, in profile, E, on end). F, G, H, First division to form 2 secondary spermatocytes, each receiving 2 dyads. I, Secondary spermatocyte. J. K, The same dividing. L, Two resulting spermatids, each containing 2 single chromosomes.

spermatocyte receiving 8 chromosomes, the other 9 (8 plus the accessory). In the next division however, the accessory chromosome divides like the others; one half going to each daughter cell or spermatid. There thus result from one primary spermatocyte four spermatids; which differ in that two contain 8 chromosomes each, while the other two contain nine each. As the accessory

chromosome is absent in the female and as all mature ova contain an equal number of chromosomes—one half the female somatic number, *i.e.*, 9, the significance of the accessory chromosome in the determination of sex becomes immediately apparent. For if an ovum is fertilized by an eight chromosome spermatozoön, the result is a new individual whose somatic chromosome number is 17,

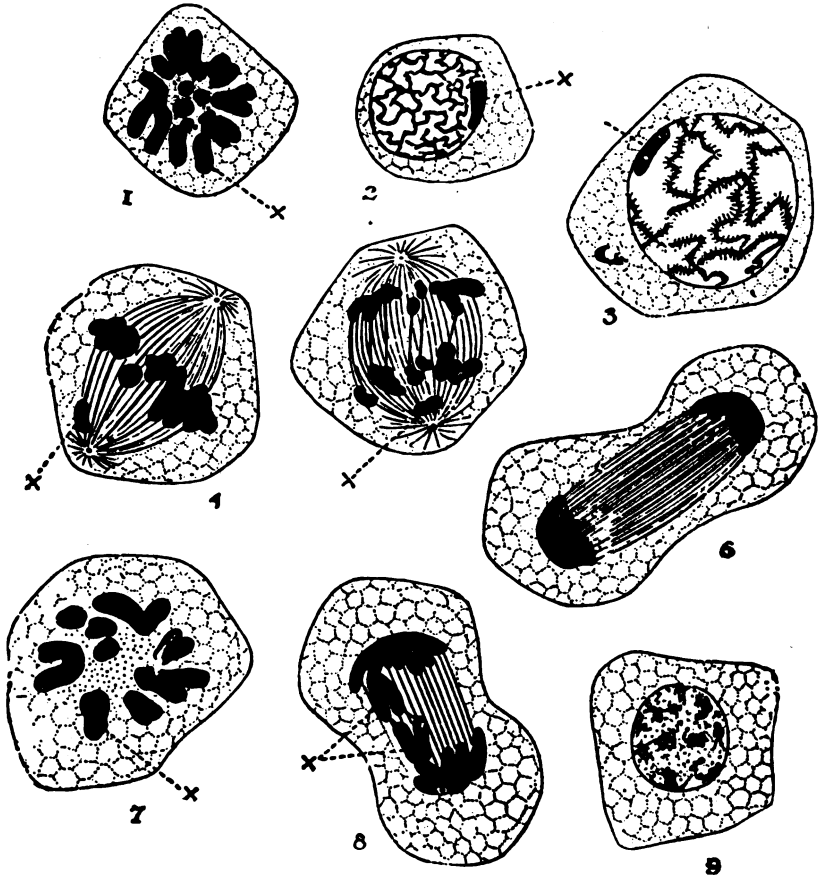

FIG. 244*D*.—Stages in the spermatogenesis of a grasshopper (Stenobothrus viridulus). *Meek*. 1, Spermatogonium in process of division, having 17 chromosomes (8 pairs and one odd). 2, Repreenting growth period of spermatogonium. 3–9, Division of the primary spermatocytes—sixteen of the chromosomes are paired while the "accessory" has no mate and passes as a whole to one of the two secondary spermatocytes. 7–8, Division of the secondary spermatocyte with the odd chromosome, the latter splitting and giving one half to each resulting spermatid. x, "Accessory" chromosome.

in other words a male, while if the ovum is fertilized by a 9-chromosome spermatozoön, one containing the accessory, the resulting new individual will have 9 + 9 = 18 as its somatic chromosome number, and will be a female.

Without going into a discussion of the complex problems of heredity, it may be stated that there is a quite general concensus of opinion that the chromosomes

are probably the main carriers of those generic and individual qualities which are transmitted from parent to offspring.

4. The *transformation* of the spermatid into the spermatozoön differs somewhat in different animals and the details of the process must be regarded as not yet definitely determined. In general the nucleus of the spermatid first becomes oval in shape, and its chromosomes become condensed into a small homogeneous mass, which forms the head of the spermatozoön. During their transformation into the heads of the spermatozoa, the nuclei of the sper-

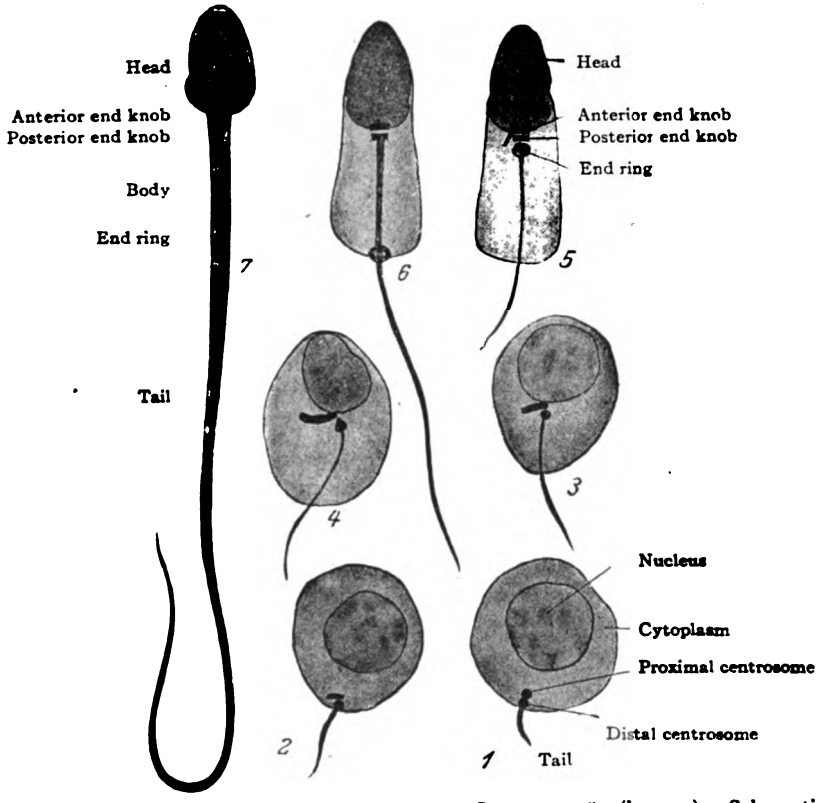

FIG. 245.—Transformation of a Spermatid into a Spermatozoön (human). Schematic. (Meves Bonnet.)

matids arrange themselves in tufts against the inner ends of the cells of Sertoli. This compound structure, consisting of a Sertoli cell and of a group of developing spermatozoa attached to its central end, is known as a *spermatoblast* (Fig. 238). The body or middle piece of the spermatozoön is described by most investigators as derived from the centrosome, while the tail is a derivative of the cytoplasm.

The details of the transformation of the spermatid into the spermatozoön are illustrated in Fig. 245. The centrosome either divides completely, forming two

centrosomes, or incompletely, forming a dumb-bell-shaped body. The nuclear material becomes very compact and passes to one end of the cell, forming the bulk of the head. Both centrosomes help to form the body. They first become disc-shaped. The one lying nearer the centre of the cell becomes attached to the posterior end of the head as the anterior end-knob, the other takes a position a little more posteriorly as the posterior end-knob and from it grows out the axial filament. Some of this centrosome passes to the posterior limits of the body and there becomes the end ring. As the two parts of this centrosome separate the delicate cytoplasm between them forms the *spiral filament* which wraps around the aerial filament of the body. During these changes the axial filament has been growing and projects beyond the limits of the cell. Most of the cytoplasm of the spermatid is not used in the formation of the spermatozoön, but is cast off and degenerates. A small amount is used for the sheath of the body, and for the galea capitis. The sheath of the main part of the filament appears to develop from the filament itself. Atypical spermatozoa are not infrequent. Thus are found very large, or very small types, or spermatozoa with several tails attached to a single head or less commonly several heads with only one tail.

The significance of the different parts of the spermatozoön has been brought out in describing its development. From this it is seen that the spermatozoön, like the mature ovum, is a true sexual element with one-half the somatic number of chromosomes. The head and body, containing the chromatin and the centrosomes, are the parts of the spermatozoön essential to fertilization. The acrosome is an accessory which in some forms at least aids the spermatozoön in attaching itself to and in entering the ovum. The tail is an accessory structure upon which depends the motility of the spermatozoön. In the lumen of the seminiferous tubules very little motion is observable, only after they have become a part of the semen (p. 349) does their motion become active. This activity is retained in the fluids of the female generative tract. Considering their minuteness, their speed is considerable, having been estimated at from 1.5 to 3.5 mm. per minute; enough to allow them to ascend through uterus and oviduct against the adverse action of the cilia. When in a favorable environment, such as the fluids of the female generative tract, the spermatozoön is capable of living for some time after leaving the testicle. Living spermatozoa have been found in the uterus or tubes three and a half weeks after coitus.

TECHNIC

(1) For the study of the general topography of the testis, remove the testis of a new-born child, make a deep incision through the tunica albuginea in order to allow the fixative to penetrate quickly, and fix in formalin-Müller's fluid (technic 6, p. 7). Antero-posterior longitudinal sections through the entire organ and including the epididymis should be stained with hæmatoxylin-picro-acid-fuchsin (technic 3, p. 24) or with hæmatoxylin-eosin (technic 1, p. 23) and mounted in balsam.

(2) The testis of a young adult is removed as soon after death as possible, is cut into thin transverse slices, which include the epididymis, and is fixed in formalin-Müller's or in Zenker's fluid (technic 10, p. 8). Select a slice which includes the head of the epididymis, cut away the anterior half or two-thirds of the testis

proper in order to reduce the size of the block, and, after the usual hardening and embedding, cut thin sections through the remaining posterior portion of the testis, the mediastinum, and epididymis. Stain with hæmatoxylin-eosin (technic 1, p. 23) and mount in balsam.

(3) For the study of spermatogenesis fix active testes of grasshoppers in chrome-acetic-osmic mixture (technic 8, p. 8). Harden in alcohol and mount thin unstained sections in balsam or in glycerin.

(4) Spermatozoa.—Human spermatozoa may be examined fresh in warm normal saline solution or fixed in saturated aqueous solution of picric acid and mounted in glycerin. Mammalian spermatozoa may be obtained from the vagina after intercourse, or by incision into the head of the epididymis. Technic same as for human.

(5) A portion of the vas deferens is usually removed with the testis and may be subjected to technic (2) above. Transverse sections are stained with hæmatoxylin-eosin and mounted in balsam.

The Prostate Gland

The prostate is described by some as a compound tubular, by others as a compound alveolar gland. It is perhaps best regarded

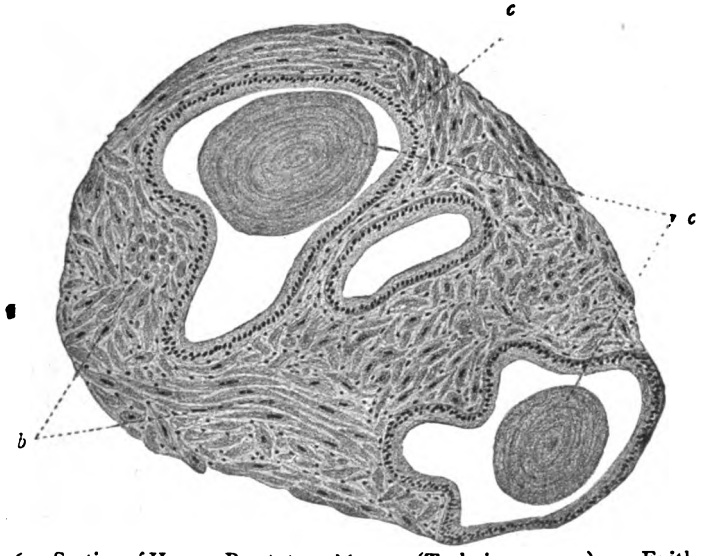

FIG. 246.—Section of Human Prostate. ×150. (Technic 1, p. 355.) *a*, Epithelium of tubule; *b*, interstitial connective tissue; *c*, corpora amylacea.

as a collection of simple branched tubular glands with dilated terminal tubules. These number from forty to fifty, and their ducts converge to form about twenty main ducts, which open into the urethra. The gland is surrounded by a *capsule* of fibro-elastic tissue and smooth

muscle cells, the muscle cells predominating. From the capsule broad *trabeculæ* of the same structure as the capsule pass into the gland. The amount of connective tissue is large. It is less in the prostate of the young than of the old. The hypertrophied prostate of age is due mainly to an increase in the connective-tissue elements. The tubules have wide lumina and are lined with simple cuboidal epithelium of the serous type, resting upon a delicate basement membrane (Fig. 246). Less commonly the epithelium is pseudo-stratified. The ducts are lined with simple columnar epithelium until near their terminations where they are lined with transitional epithelium similar to that lining the urethra. Peculiar concentrically laminated bodies, *crescentic corpuscles*, or *corpora amylacea*, are frequently present in the terminal tubules (Fig. 246, *c*). They are more numerous after middle life. Through the prostate runs the prostatic portion of the urethra.

Within the prostate is found the *vesicula prostatica* (*utriculus prostaticus—uterus masculinus*). It represents the remains of a fœtal structure, the *Müllerian duct* and consists of a blind sac with folded mucous membrane lined with a two-rowed ciliated epithelium which dips down to form short tubular glands. The prostatic secretion is serous.

The **blood-vessels** of the prostate ramify in the capsule and trabeculæ. The small arteries give rise to a capillary network which surrounds the gland tubules. From these arise small veins, which accompany the arteries in the septa and unite to form venous plexuses in the capsule.

The **lymphatics** begin as blind clefts in the trabeculæ and follow the general course of the blood-vessels.

Nerves.—Small groups of sympathetic ganglion cells are found in the larger trabeculæ and beneath the capsule. Axones of these cells pass to the smooth muscle of the trabeculæ and of the walls of the blood-vessels. Their mode of termination is not known. Timofeew describes afferent medullated fibres ending within capsular structures of flat nucleated cells. Two kinds of fibres pass to each capsule: one a large medullated fibre which loses its sheath and gives rise within the capsule to several flat fibres with serrated edges, the other small medullated fibres which lose their sheaths and split up into small varicose fibrils which form a network around the terminals of the large fibre.

Cowper's Glands

The bulbo-urethral glands, or glands of Cowper, are small, compound tubular glands. Both tubules and ducts are irregular in diameter so that some of them have more the character of alveoli than of tubules. They are lined with mucous cells. The smaller ducts are lined with simple cuboidal epithelium. They unite to form two main excretory ducts which open into the urethra and are lined with stratified columnar epithelium consisting of two or three layers of cells. In the main duct, as well as in its branches, smooth muscle occurs.

TECHNIC

(1) Fix small pieces of the prostate of a young man in formalin-Müller's fluid (technic 6, p. 7). Stain sections with hæmatoxylin-eosin (technic 1, p. 23) and mount in balsam.

(2) The prostate of an old man should be treated with the same technic and compared with the above.

(3) Cowper's glands. Same technic as prostate (1).

The Penis

The penis consists largely of three long cylindrical bodies, the *corpus spongiosum* and the two *corpora cavernosa*. The latter lie side by side, dorsally, while the corpus spongiosum occupies a medial ventral position (Fig. 247). All three are enclosed in a common connective-tissue capsule which is loosely attached to the overlying skin. In addition each corpus has its own special capsule or *tunica albuginea*, about a millimetre in thickness, and composed of dense connective tissue containing many elastic fibres.

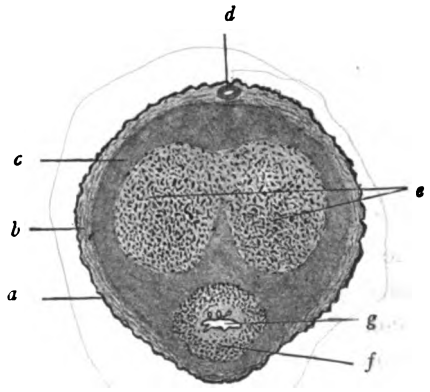

FIG. 247.—Transverse Section through Human Penis. *a*, Skin; *b*, subcutaneous tissue; *c*, fibrous tunic; *d*, dorsal vein; *e*, corpora cavernosa; *f*, corpus spongiosum; *g*, urethra.

The *corpus spongiosum* and *corpora cavernosa* have essentially the same structure, being composed of so-called *erectile tissue* (Fig. 248). This consists of thick trabeculæ of intermingled fibro-elastic tissue and bundles of smooth

muscle cells, which anastomose to form a coarse meshed network, the spaces of which are lined with endothelium. The spaces are known as *cavernous sinuses*, and communicate with one another, and with the blood-vessels of the penis. In the flaccid condition of the organ these sinuses are empty and their sides are in apposition. In erection these sinuses become filled with venous blood.

The **arteries** have thick muscular walls and run in the septa. A few of them open directly into the venous sinuses. Most of them give rise to a superficial capillary network beneath the tunica albuginea. From this capillary plexus the blood passes into a plexus of broader venous channels in the periphery of the erectile tissue, and

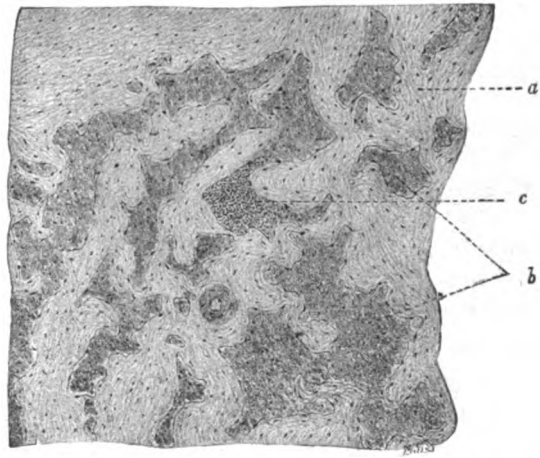

FIG. 248.—Erectile Tissue of Corpus Spongiosum of Human Penis. ×60. *a*, Trabeculæ of connective tissue and smooth muscle; *b*, cavernous sinuses; *c*, groups of leucocytes in sinus.

these in turn communicate with the cavernous sinuses. The usual direct anastomosis between arterial and venous capillaries also occurs. The blood may therefore pass either through the usual course—arteries, capillaries, veins—or, under certain conditions, may pass through the cavernous sinuses. This determines the flaccid or the erect condition of the organ. The veins arise partly from the capillaries and partly from the cavernous sinuses. They pass through the tunica albuginea and empty into the dorsal vein of the penis (Fig. 247). In the corpus spongiosum there is probably no direct opening of arteries into sinuses. Both trabeculæ and sinuses are also smaller.

Of the **lymphatics** of the penis little definite is known.

The **nerve endings**, according to Dogiel, consist of: (*a*) free sensory endings, (*b*) deeply situated genital corpuscles, (*c*) Pacinian corpus-

cles and Krause's end-bulbs in the more superficial connective tissue, and (*d*) Meissner's corpuscles in the papillæ. (For details see pages 444 and 445.)

The *glans penis* consists of erectile tissue similar in structure to that of the corpus cavernosum, except that the venous spaces are smaller and more regular. The mucous membrane is very closely attached to the fibrous sheath of the underlying erectile tissue. A few small sebaceous glands, unconnected with hairs—the glands of Tyson—are found in the mucous membrane of the base of the glans penis.

The *prepuce* is a fold of skin which overlies the glans penis. Its inner surface is lined with mucous membrane.

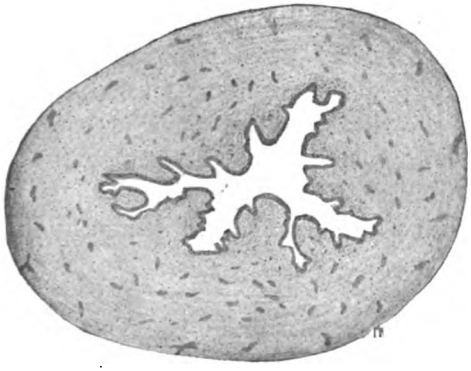

FIG. 249.

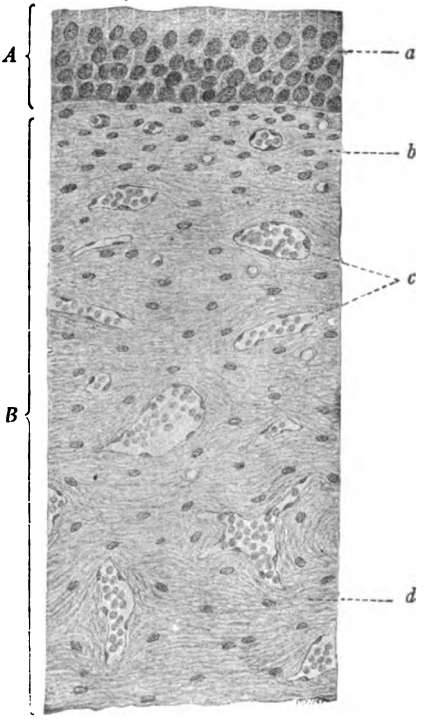

FIG. 250.

FIG. 249.—From Transverse Section of Urethra and Corpus Spongiosum, including Mucous Membrane and part of Submucosa. ×15. The dark spots represent the cavernous veins.

FIG. 250.—Vertical Section through Portion of Wall of Human Male Urethra. ×350. *A*, Mucous membrane; *B*, submucosa; *a*, epithelium; *b*, stroma; *c*, cavernous veins; *d*, connective tissue of submucosa.

The Urethra[1]

The MALE URETHRA is divided into three parts—*prostatic*, *membranous*, and *penile*. The wall of the urethra consists of three coats—

[1] The female urethra, while not so distinctly divisible into sections, presents essentially the same structure as the male urethra. The epithelium begins at the bladder as stratified squamous of the transitional type, changes to a two-layered stratified or pseudostratified, and finally passes over into stratified squamous near the urethral opening. Glands of Littré are present, but are fewer than in the male.

mucous, submucous, and muscular. The structure of the wall differs in the different parts of the urethra.

The *mucous membrane* (Fig. 250) consists of epithelium and stroma. The epithelium of the prostatic part is stratified squamous (transitional), resembling that of the bladder. In the membranous part it is stratified columnar or pseudostratified. In the penile portion it is pseudostratified up to the fossa navicularis, where it changes to stratified squamous. The epithelium rests upon a basement membrane, beneath which is a thin stroma rich in elastic fibres and having papillæ which are especially prominent in the terminal dilated portion of the urethra, the *fossa navicularis*. The stroma merges without distinct demarcation into the submucosa.

The *submucosa* consists of connective tissue and, in the penile portion, of more or less longitudinally disposed smooth muscle. It contains a dense network of veins—cavernous veins—which give it the character of erectile tissue (Fig. 250).

The *muscular coat* is thickest in the prostatic and membranous portions. Here it consists of a thin inner longitudinal and a thicker outer circular layer. A definite muscular wall ceases at the beginning of the penile portion, although circularly disposed smooth muscle cells are found in the outer part of the submucosa of the penile urethra.

Throughout the mucosa of the entire urethra, but most numerous in the penile portion, are simple branched tubular mucous glands, the glands of Littré. They are lined with columnar epithelium and the longer extend into the submucosa.

TECHNIC

(1) For the study of the general topography of the penis, remove the skin from the organ and cut into transverse slices about 0.5 cm. in thickness. Fix in formalin-Müller's fluid (technic 6, p. 7), cut rather thick sections across the entire penis, stain with hæmatoxylin-picro-acid-fuchsin (technic 3, p. 24) or with hæmatoxylin-eosin (technic 1, p. 23) and mount in balsam.

(2) For the study of the structure of the penile portion of the urethra and of the erectile tissue of the corpus spongiosum, cut away the corpora cavernosa, leaving only the corpus spongiosum and contained urethra, and treat as above. Sections should be thin and stained with hæmatoxylin-eosin.

(3) The same technic is to be used for the membranous and prostatic portions of the urethra.

II. FEMALE ORGANS

The Ovary

The ovary is a highly specialized gland of both external and internal secretion. Its specific external secretion is the ovum, and

while the ovary has no duct system which is directly continuous with its structure it has in place of this a highly specialized disconnected excretory duct—the *oviduct* or *Fallopian tube*—which serves for the transmission of the ovum to the uterus.

On one side the ovary is attached by a broad base, the *hilum*, to the broad ligament. Elsewhere the surface of the ovary is covered by a modified peritoneum. At the hilum the tissues of the broad ligament pass into the ovary and spread out there to form the *ovarian*

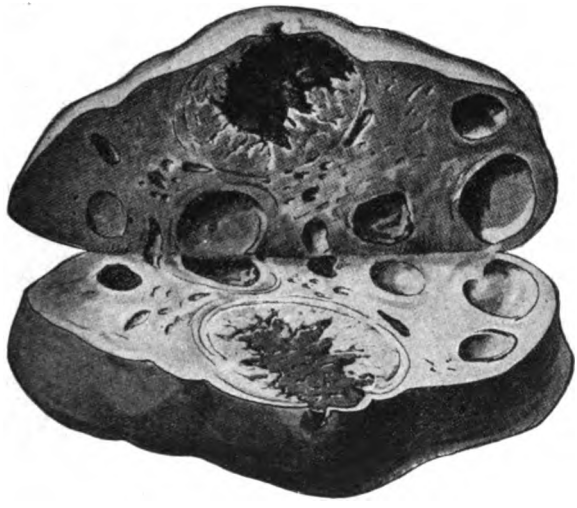

FIG. 251.—Ovary opened by Longitudinal Incision. Ovum has Escaped through Tear in Surface. Cavity of follicle filled with blood clot (corpus hæmorrhagicum) and irregular projections composed of lutein cells. (Kollmann's Atlas.)

stroma. This consists of fibrous connective tissue rich in elastic fibres and containing many smooth muscle cells. In the deeper central portion of the organ, stroma alone is found. Here it contains many large blood-vessels, and constitutes the *medulla* or *zona vasculosa* of the ovary (Fig. 252, 2). From the medulla the stroma radiates toward the surface of the ovary and becomes interspersed with glandular elements forming the *ovarian cortex* (Fig. 252, 3, 3′). At the surface of the ovary, just beneath the peritoneum, the stroma forms a rather dense layer of fibrous tissue, the *tunica albuginea*. At the margin of the peritoneal surface of the ovary the connective tissue of the peritoneum becomes continuous with the stroma of the ovary, while the flat mesothelium of the general peritoneum is replaced by a single layer of cuboidal cells, which covers the surface of the

ovary and is known from its function as the *germinal epithelium* (Fig. 253, *he*). The parenchyma or secreting portion of the ovary consists of peculiar glandular elements, the *Graafian follicles*.

The structure of the Graafian follicle can be best appreciated by studying its development. The follicles originate from the germinal epithelium during fœtal life. At this time the germinal epithelium is proliferating, and certain of its cells differentiate into larger

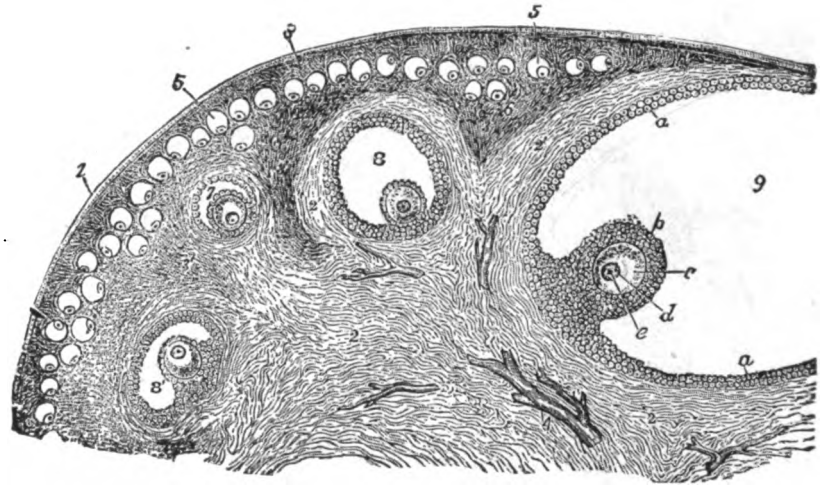

FIG. 252.—Semidiagrammatic Drawing of Part of Cortex and Medulla of Cat's Ovary. (From Schrön, in Quain's "Anatomy.") 1, Germinal epithelium, beneath which is 3, the tunica albuginea; 2, medulla, containing large blood-vessels, 4; 2,2', fibrous stroma, arranged around mature Graafian follicle as its theca folliculi; 3', stroma of cortex; 5, small (primitive) Graafian follicles near surface; 6, same deeper in cortex; 7, later stage of Graafian follicle, beginning of cavity; 8 and 8', still later stages in development of follicle; 9, mature follicle; *a*, stratum granulosum; *b*, germ hill; *c*, ovum; *d*, nucleus (germinal vesicle); *e*, nucleolus (germinal spot).

spherical cells—*primitive ova* (Fig. 253, *op*). The primitive ova pass down into the stroma accompanied by a considerable number of the undifferentiated cells of the germinal epithelium. A cord-like mass of cells is thus formed, extending from the surface into the stroma. This is known as *Pflüger's egg cord* (Fig. 253). Each cord usually contains several ova. In some cases the differentiation of the ova cells does not occur upon the surface but in the cords after they have extended down from the surface. The connection of the cord with the surface epithelium is next broken so that each cord becomes completely surrounded by stroma. It is now known as an *egg nest* (Fig. 253). During this process, proliferation of the epithelial cells of the cords and nests has been going on, and each ovum surrounded

by a layer of epithelial cells becomes separated from its neighbors (Fig. 253, *fp*). This central ovum surrounded by a single layer of epithelial cells (follicular cells) is the *primitive Graafian follicle* (Fig. 253, *fp*, Fig. 254, and Fig. 255, *a*). Rarely a follicle may contain more than one ovum, of which, however, only one goes on to maturity, the others degenerating. The follicle increases in size, mainly on account of proliferation of the follicular cells, which soon form several layers instead of a single layer, but also partly on account of growth of

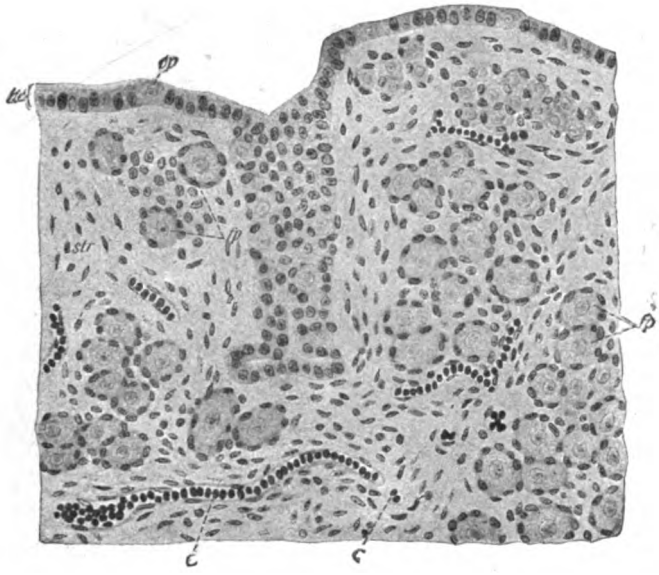

FIG. 253.—From Transverse Section of Ovary of New-born Child. ×280 (Sobotta). Shows primitive ova in germinal epithelium; Pflüger's egg cords and nests of cells; *c*, capillaries; *he*, germinal epithelium; *str*, stroma; *fp*, primitive follicles; *op*, primitive ova.

the ovum itself (Fig. 255). The latter now leaves the centre of the follicle and takes up an eccentric position. At the same time a cavity (or several small cavities which later unite) appears near the centre of the follicle (Fig. 255, *e* and Fig. 252, 7). This is filled with fluid which seems to be in part a secretion of the follicular cells, in part a result of their disintegration. The cavity is known as the *follicular cavity* or *antrum*, the fluid as the *liquor folliculi*. Lining the follicular cavity are several rows of follicular cells with granular protoplasm—the *stratum granulosum*. With increase in the liquor folliculi the ovum becomes still further pressed to one side of the follicle, where, surrounded by an accumulation of follicular cells, it forms a distinct projection into the cavity (Fig. 257, and Fig. 252, 8 and 9). This

is known as the *germ hill* (*discus proligerus—cumulus ovigerus*). The cells of the germ hill nearest the ovum become columnar and arranged in a regular single layer around the ovum—the *corona radiata* (Fig. 258). The ovarian stroma immediately surrounding the Graafian follicle becomes somewhat modified to form a sheath for the follicle—

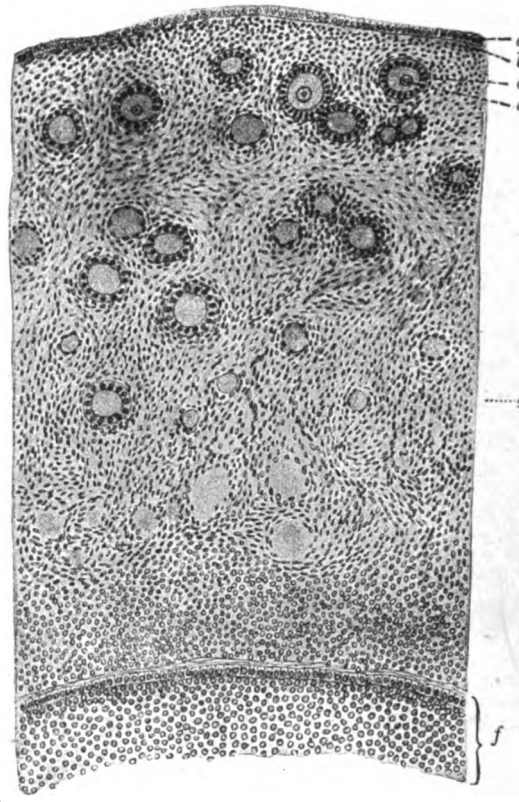

FIG. 254.—Vertical Section through Cortex of Ovary of Young Girl. ×190. (Böhm and von Davidoff.) *a*, Germinal epithelium; *b*, tunica albuginea; *c*, follicular epithelium; *d*, ovum; *e*, primitive Graafian follicles in ovarian cortex; *f*, granular layer of large Graafian follicle.

the *theca folliculi* (Fig. 256). This consists of two layers, an outer more dense fibrous layer, the *tunica fibrosa*, and an inner more cellular and vascular, the *tunica vasculosa*. Between the theca folliculi and the stratum granulosum is an apparently structureless basement membrane.

While these changes are taking place in the follicle, the ovum is also undergoing development. The ovum of the primitive follicle

is a spherical cell, having a diameter of from 40 to 70μ and the structure of a typical cell. The nucleus or germinal vesicle (so called on account of the part it takes in reproduction) is about half the diameter of the cell, and is spherical and centrally placed (Fig. 255). It is surrounded by a double-contoured nuclear membrane, and contains a distinct chromatic network and nucleolus or *germinal spot.* The cytoplasm is quite easily differentiated into a spongioplasm network and a homogeneous hyaloplasm. Such ova are present in all active ovaries, *i.e.*, during the childbearing period, but are especially numerous in the ovary of the infant and child (Fig. 254).

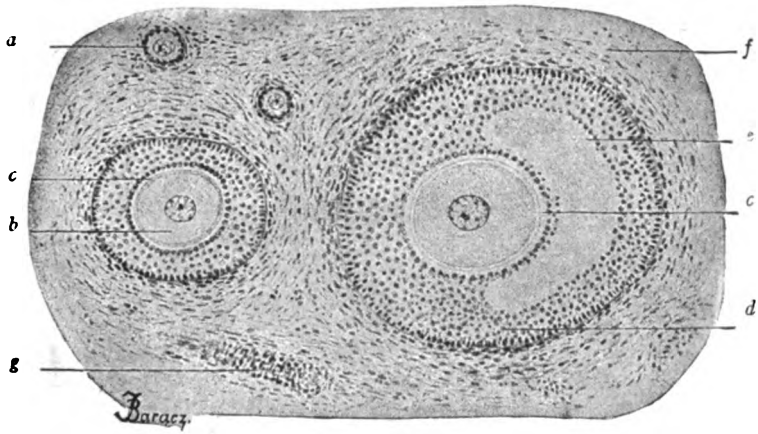

FIG. 255.—From Section through Cortex of Ape's Ovary. ×150. (Szymonowicz.) *a*, Primitive follicle; *b*, ovum, with nucleus and nucleolus; *c*, zona pellucida; *d*, follicular epithelium; *e*, follicular cavity; *f*, ovarian stroma; *g*, blood-vessel in stroma.

With the development of the follicle the ovum increases in size and becomes surrounded by a clear membrane, the *zona pellucida*, believed by some to be a cuticular formation deposited by the egg cell, by others to be a product of the surrounding follicular cells. Minute canals extend into the zona pellucida from its outer surface. These contain processes of the cells of the corona radiata. A narrow cleft, the *perivitelline space*, has been described as separating the ovum from the zona pellucida. During the growth of the ovum its cytoplasm becomes coarsely granular from the development of yolk or deutoplasm granules (Fig. 258). Immediately surrounding the nucleus, and just beneath the zona pellucida, the egg protoplasm is fairly free from yolk granules.

Oögenesis.—In preparation for union with the spermatozoön

the ovum passes through a series of changes (maturation) quite similar to that described for the sperm cell (spermatogenesis, p. 250), and with the same end results, namely, the reduction of its chromosomes to one half the somatic number for the species. The changes differ, however, in two main features: (1) in the male, one primary spermatocyte gives rise to four spermatozoa all functionally capable; in the female, one primary oöcyte gives rise to but one mature ovum, the other three bodies formed being extruded and cast off as useless (Figs. 256 *A*, and 244 *B*, *a*); (2) in the ovum there is no accessory

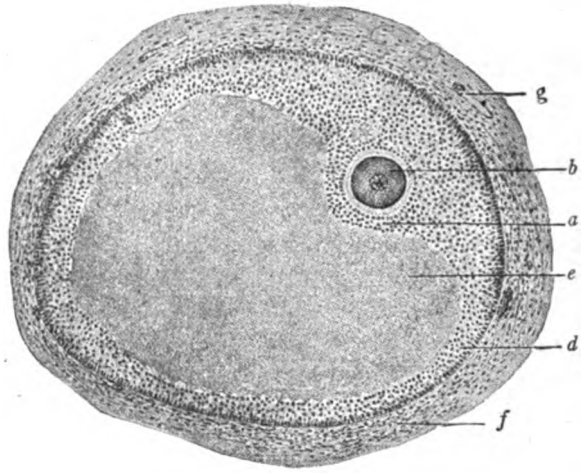

FIG. 256.—Section through Graafian Follicle of Ape's Ovary. ×90. (Szymonowicz.) Later stage of development than Fig. 255. *a*, Germ hill; *b*, ovum with clear zona pellucida, germinal vesicle, and germinal spot; *d*, follicular epithelium (membrana granulosa); *e*, follicular cavity; *f*, theca folliculi; *g*, blood-vessel.

chromosome. The oögonia, containing the somatic number of chromosomes, divide mitotically as do the spermatogonia and, after an indefinite number of generations, enter upon a rest or growth period at the end of which they are known as primary oöcytes (Fig. 244 *B*, *a*). During this growth-period synapsis occurs. From this point the changes differ in different animals. In Ascaris (somatic chromosome number = 4) the process is very simple and has been very thoroughly studied (Fig. 256*A*). Here reduction takes place after the sperm has entered the egg. The spindle forms near the surface of the cell and the two tetrads which have resulted from synapsis pass to the equatorial plane. Each tetrad divides into two

dyads one of which remains in the egg while the other with a small amount of surrounding cytoplasm is extruded as the first polar body. Without a resting stage a new spindle forms, the dyads pass to its equatorial plane and divide, each into two monads, one of which remains as the nucleus of the now mature ovum, while the other is extruded as the second polar body. Similar division of the first polar body also occurs. The primary oöcyte, like the primary spermatocyte thus gives rise to four end bodies; in the case of the oöcyte, however, only one of these end bodies develops. In both cases the number of chromosomes is reduced one half, while the chromatic substance itself is reduced quantitatively to one quarter its original amount.

In many of the lower animals maturation is completed outside the ovary. In the higher animals and man the entire process takes place within the ovary, the second polar body being extruded just before the escape of the ovum from its follicle.

The youngest of the Graafian follicles are found just under the tunica albuginea near the germinal epithelium, from which they originate (Fig. 252, 5). As the follicle matures it passes deeper into the cortex. With complete maturity the follicle usually assumes macroscopic proportions—8 to 12 mm.—and often occupies the entire thickness of the cortex, its theca at one point touching the tunica albuginea. Thinning of the follicular wall nearest the surface of the ovary next takes place (Fig. 259), while at the same time an increase in the liquor folliculi determines increased intrafollicular pressure. This results in rupture of the Graafian follicle and the discharge of its ovum, together with the liquor folliculi and some of the follicular cells.

An escape of blood into the follicle from the torn vessels of the theca always accompanies the discharge of the ovum. The follicle closes over and again becomes a closed cavity, filled with clotted blood and forming the *corpus hemorrhagicum* (Fig. 260), which represents the earliest stage in the development of the *corpus luteum*.

The *corpus luteum* (Fig. 261), which gradually replaces the corpus hemorrhagicum, consists of large yellow cells—*lutein cells*— and of connective tissue. The latter with its blood-vessels is derived from the inner layer of the theca. The origin of the lutein cells is not clear. They are described by some as derived from the connective-tissue cells of the theca; by others as the result of proliferation of the cells of the stratum granulosum. The cells have a yellow color from the

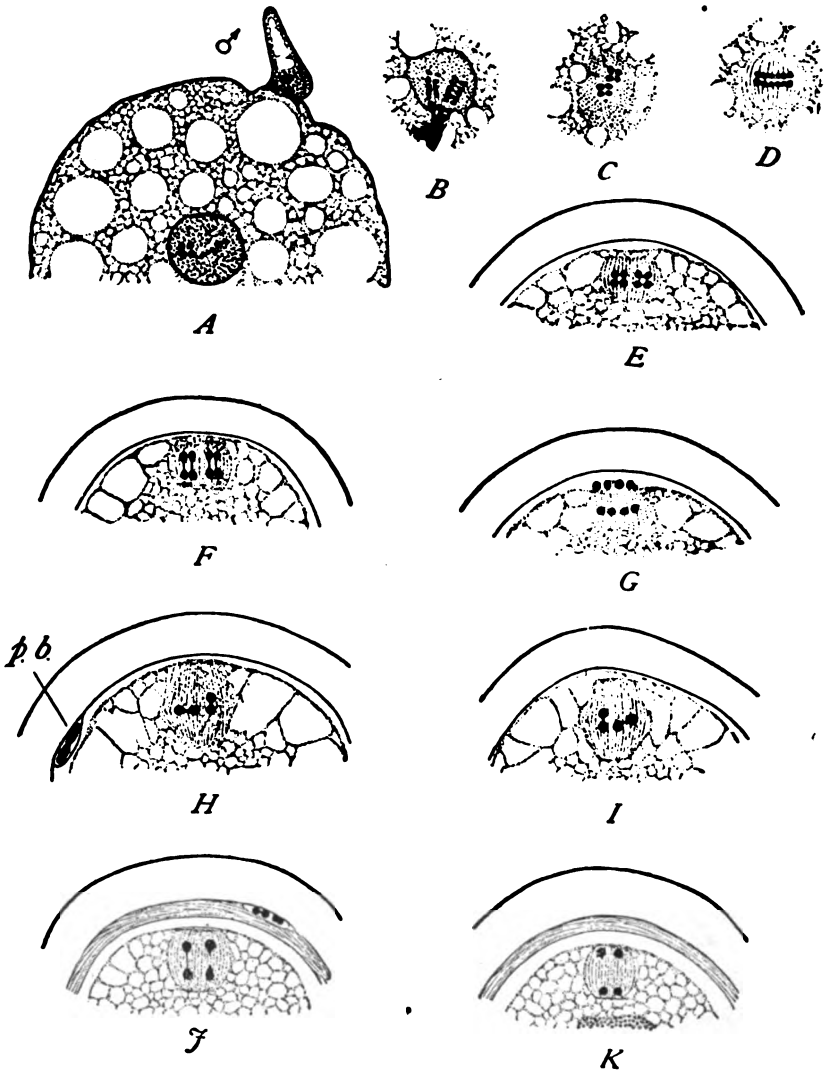

FIG. 256*A*.—Maturation of the ovum of Ascaris megalocephala (bivalens). *Boveri, Wilson.* A, The ovum with the spermatozoön just entering at ♂; the egg nucleus contains 2 tetrads (one not clearly shown), the somatic number of chromosomes being 4. B, Tetrads in profile. C, Tetrads on end. D, E, First spindle forming. F, Tetrads dividing. G, First polar body formed, containing 2 dyads; 2 dyads left in the ovum. H, I, Dyads rotating in preparation for next division. J, Dyads dividing. K, Each dyad divided into 2 single chromosomes, thus completing the reduction.

presence of a pigment, lutein, in their protoplasm and in the fat droplets which soon infiltrate the cells, and it is to this pigment that the characteristic yellow color of the corpus luteum is due. Both lutein cells and new connective tissue first appear around the periphery of the corpus hemorrhagicum and work their way toward its

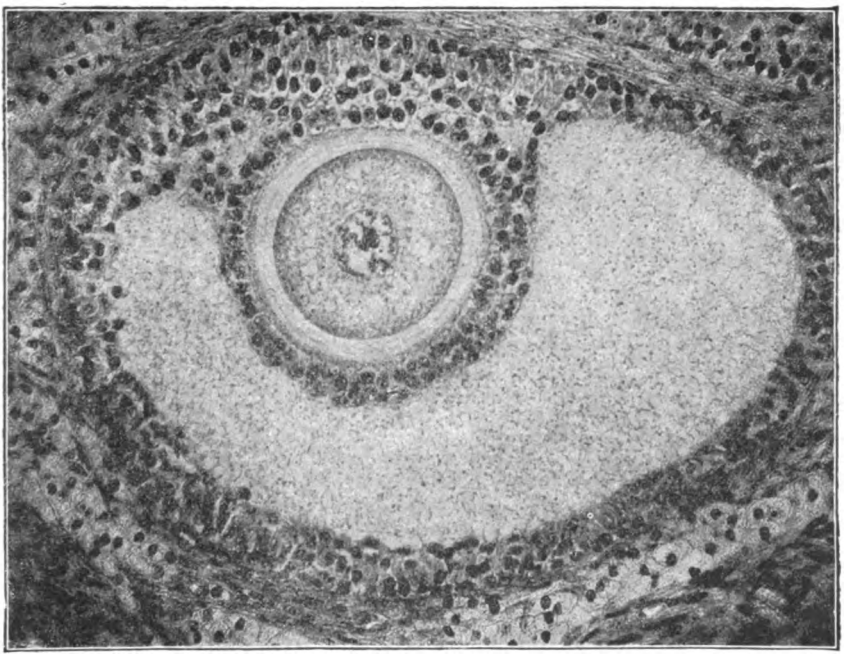

FIG. 257.—Graafian Follicle and Contained Ovum of Cat; directly reproduced from a photograph of a preparation by Dahlgren. ×235. (From "The Cell in Development and Inheritance," Prof. E. B. Wilson; The Macmillan Company, publishers.) The ovum is seen lying in the Graafian follicle within the germ hill, the cells of the latter immediately surrounding the ovum forming the corona radiata. The clear zone within the corona is the zona pellucida, within which are the egg protoplasm, nucleus, and nucleolus. Encircling the follicle is the connective tissue of the theca folliculi.

center. As they advance the blood clot undergoes absorption. Growth of lutein cells and of new connective tissue is not restricted to the area occupied by the corpus hemorrhagicum but extends also peripherally into or replacing a considerable area of surrounding ovarian stroma. The corpus luteum is thus larger than the replaced corpus hemorrhagicum. This is especially true of the corpus luteum of pregnancy (see p. 368). In this way a definite cellular structure with

a supporting connective-tissue framework replaces the corpus hemorrhagicum, remains of which are usually present in the shape of orange-colored crystals of hematoidin. By degeneration and subsequent absorption of its tissues the corpus luteum becomes gradually reduced in size, loses its yellow color, and is then known as the *corpus albicans*.

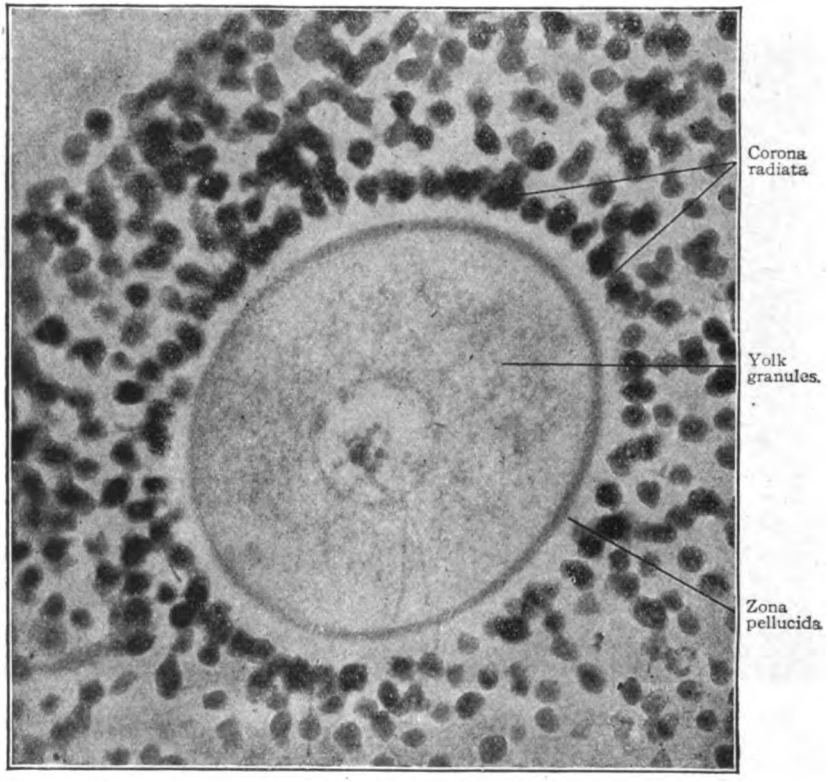

FIG. 258.—From a Section of a Human Ovum. Section taken from the ovary of a 12 year old girl. The ovum lies in a large mature Graafian follicle and is surrounded by the cells of the "germ hill" (the inner edge of which is shown in the upper left-hand corner of the figure). Photograph. (Bailey and Miller.)

This also is mostly absorbed, being finally represented merely by a small area of fibrous tissue.

Corpora lutea are divided into *true corpora lutea* (corpora lutea vera or corpora lutea of pregnancy) and *false corpora lutea* (corpora lutea spuria). The former replace follicles whose ova have undergone fertilization, the latter, follicles whose ova have not been fertilized. The structure of both is similar, but the true corpus luteum

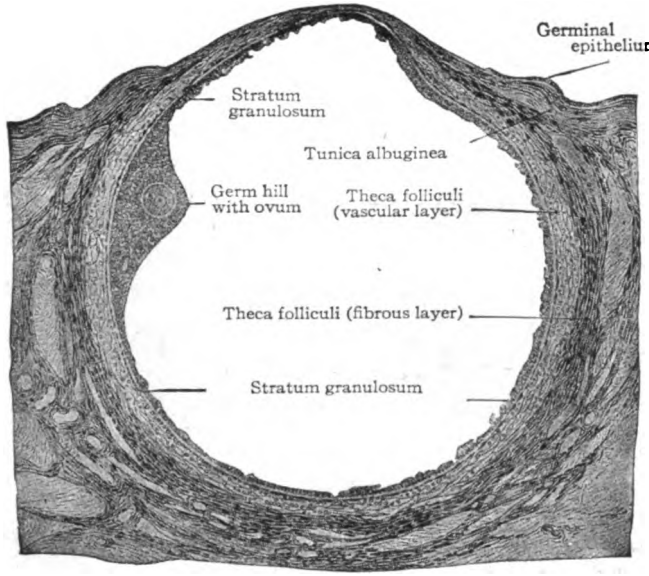

FIG. 259.—From Section of Human Ovary, showing mature Graafian follicle ready to rupture. (Kollmann's Atlas.)

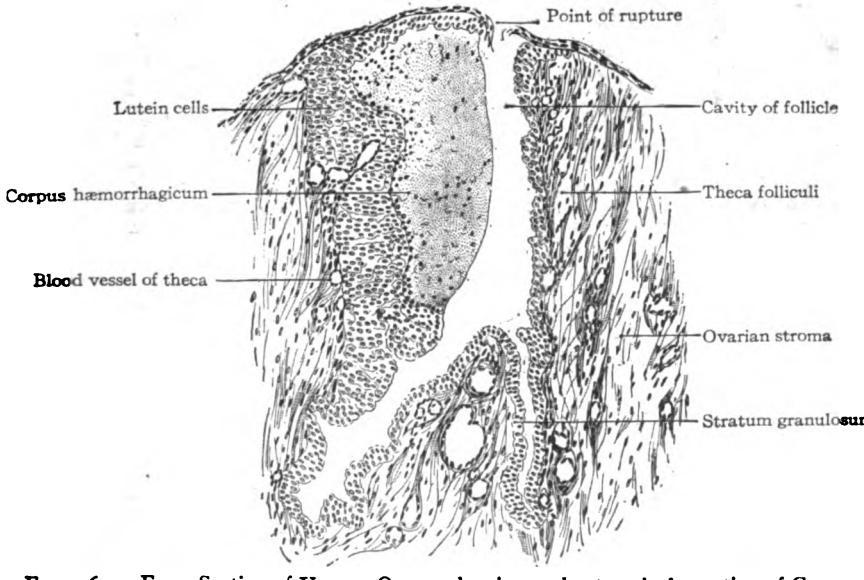

FIG. 260.—From Section of Human Ovary, showing early stage in formation of Corpus Luteum. (Kollmann's Atlas.)

is larger as a result of greater growth peripherally of the lutein cells and new connective tissue, and both it and its corpus albicans are slower in passing through their retrogressive changes, thus remaining much longer in the ovary.

While the function of the corpus luteum is not known, the experiments of Fraenkel seem to be confirmatory of the theory advanced by Born, that the corpus luteum is a gland having an inter-

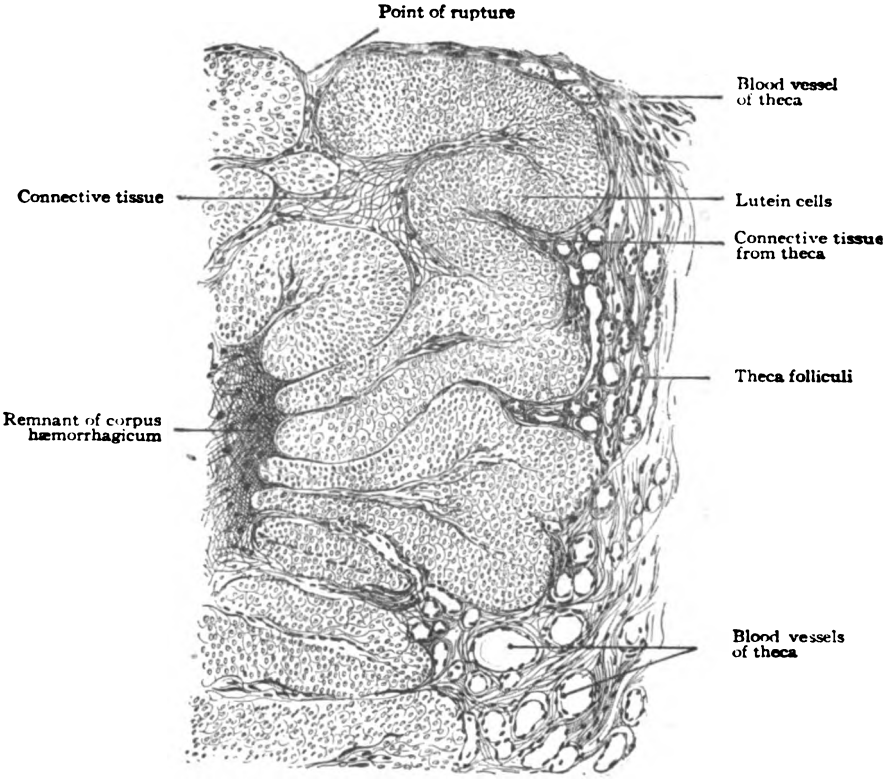

FIG. 261.—From Section of Human Ovary, showing later stage of Corpus Luteum than Fig. 260. (Kollmann's Atlas.)

nal secretion, which appears to have some influence upon the attachment of the fecundated ovum to the uterus and upon its nutrition during the first few weeks of its development. According to Fraenkel the corpus luteum is a periodically rejuvenated ovarian gland, which gives to the uterus a cyclic nutritional impulse, which prepares it for the implantation of the ovum or favors menstruation whenever the ovum is not fertilized.

Of the large number of ova—estimated at seventy-two thousand in the human ovaries—only comparatively few, according to Henle about four hundred, reach maturity. The majority undergo, together with their follicles, retrogressive changes known as atresia of the follicle. The nucleus of the ovum, as well as the nuclei of the follicular cells, passes through a series of chromatolytic changes, or in some cases apparently simply atrophies. The cell bodies undergo fatty or albuminous degeneration and the cells become reduced to a homogeneous mass, which is finally absorbed, leaving in its place a connective-tissue scar, probably the remains of the theca folliculi.

Blood-vessels.—The arteries, branches of the ovarian and uterine, enter the ovary at the hilum and ramify in the medulla. From these are given off branches which pass to the cortex and end in a capillary network in the tunica albuginea. In the outer layer of the theca folliculi the capillaries form a wide-meshed network, which gives rise to a fine-meshed network of capillaries in the inner layer of the theca. From the capillaries veins arise which form a plexus in the medulla and leave the ovary at the hilum.

Lymphatics.—These begin as small lymph spaces in the cortex, which communicate with more definite lymph vessels in the medulla, the latter leaving the organ at the hilum.

Nerves.—Medullated and non-medullated fibres enter the ovary at the hilum and follow the course taken by the blood-vessels. Many of the fibres end in the vessel walls; others form plexuses around the follicle and end in the theca folliculi. Some describe fibres as passing through the theca and ending in the follicular epithelium. Others claim that nerve fibres do not enter the follicle proper. Groups of sympathetic ganglion cells occur in the medulla near the hilum.

As is the case with the testicle, certain rudimentary organs, the remains of fœtal structures, are found connected with the ovary.

The *paroöphoron* consists of a number of cords or tubules of epithelial cells, sometimes ciliated, sometimes non-ciliated. It is found in the medulla, or, more commonly, in the connective tissue of the hilum.

The *epoöphoron* is a similar structure found in the folds of the broad ligament. Its tubules open into a duct known as Gärtner's duct. In man this duct ends blindly. In some of the lower animals it opens into the vagina. Both paroöphoron and epoöphoron are

remains of the embryonal mesonephros, the former of its posterior segment, the latter of its middle segment.

The Oviduct

The oviduct or Fallopian tube is the excretory duct of the ovary, serving for the transmission of the discharged ovum from ovary to uterus. Although there is no sharp demarcation between them, it is convenient to divide the tube into three segments: (1) The isthmus, beginning at the uterus and extending about one-third the

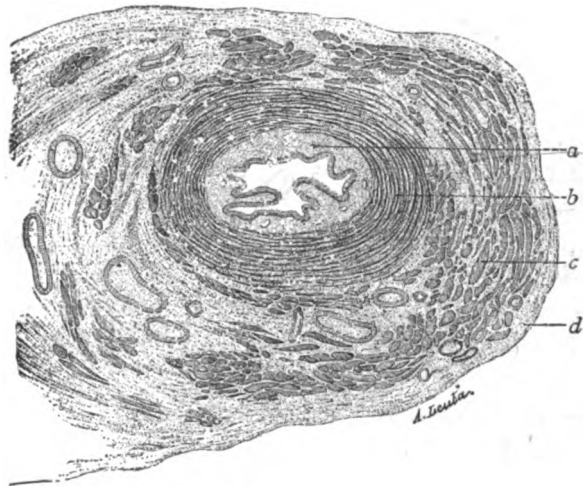

FIG. 262.—Cross Section of Oviduct near Uterine End. *a*, Mucous membrane; *b*, circular muscle coat; *c*, longitudinal muscle coat; *d*, connective tissue of serous coat. (Orthmann.)

length of the tube; (2) the ampulla, about twice the diameter of the isthmus, and occupying somewhat more than the middle third; and (3) the fimbriated or ovarian extremity.

The walls of the oviduct consist of three coats: (1) Mucous, (2) muscular, and (3) serous (Figs. 262 and 263).

The *mucous membrane* presents numerous longitudinal foldings. In the embryo four of these folds can usually be distinguished, and these are known as primary folds. In the adult many secondary folds have developed upon the primary, especially in the ampulla and fimbriated extremity where the folds are high and complicated (Fig. 263). The epithelium lining the tube is of the simple columnar ciliated type, and completely covers the foldings of the mucous mem-

brane. The ciliary motion is toward the uterus. The stroma consists of a cellular connective tissue, quite compact in structure in the isthmus, where the folds are low, more loosely arranged in the high folds of the ampulla and fimbriated extremity.

The *muscular coat* consists of an inner circular and an outer longitudinal layer. The latter is a comparatively thin layer in the isthmus, consists of discontinuous groups of muscle cells in the ampulla, and in the fimbriated extremity is frequently absent.

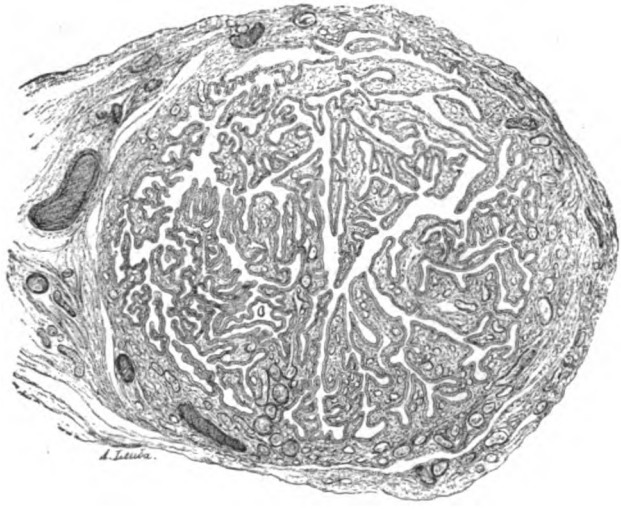

FIG. 263.—Cross Section of Oviduct near Fimbriated Extremity, showing complicated foldings of mucous membrane. (Orthmann.)

The *serous coat* has the usual structure of peritoneum.

The larger **blood-vessels** run in the stroma along the bases of the folds. They send off branches which give rise to a dense capillary network in the stroma.

Of the **lymphatics** of the tube little is known.

The **nerves** form a rich plexus in the stroma, from which branches pass to the blood-vessels and muscular tissue of the walls of the tube and internally as far as the epithelial lining.

TECHNIC

(1) Child's Ovary.—Remove the ovary of a new-born child, being careful not to touch the surface epithelium, fix in Zenker's fluid (technic 10, p. 8), and harden in alcohol. Cut sections of the entire organ through the hilum. Stain with hæmatoxylin-eosin (technic 1, p. 23) and mount in balsam.

(2) For the purpose of studying the Graafian follicle in the different stages of

its development remove an ovary from an adult cat or dog and treat as above. Technic (1). These sections also, as a rule, are satisfactory for the study of the corpus luteum.

(3) The adult human ovary is little used for histological purposes on account of the few follicles it usually contains and its proneness to pathological changes. Its study is, however, so extremely important, especially with reference to the pathology of the ovary, that if possible a normal human ovary should be obtained from a young subject for purposes of comparison with the above. Technic (1).

(4) For studying the egg cords of Pflüger and their relation to the germ epithelium, ovaries of the human fœtus, and of very young cats, dogs, and rabbits are satisfactory. Technic (1).

(5) Sections of the fimbriated end of the oviduct are usually found in the sections of ovary. For the study of other parts of the tube, cut out thin pieces from different regions, fix in formalin-Müller's fluid, stain transverse sections with hæmatoxylin-eosin, and mount in balsam.

FIG. 264.—Muscle cells from (*a*) non-pregnant uterus; *b*, pregnant uterus; drawn to same scale. (Sellheim.)

The Uterus

The wall of the uterus consists of three coats which from without inward are serous, muscular, and mucous.

The *serous coat* is a reflection of the peritoneum, and has the usual structure of a serous membrane.

The *muscularis* consists of bundles of smooth muscle cells separated by connective tissue. The muscle has a general arrangement into three layers, an inner, a middle, and an outer, which are distinct in the cervix, but not well defined in the body and fundus.

The inner layer—*stratum submucosum*—is mainly longitudinal, although some obliquely running bundles are usually present.

The middle layer—called from the large venous channels which it contains, the *stratum vasculare*—is the thickest of the three layers, forming the main bulk of the muscular wall. It consists mainly of circularly disposed muscle bundles.

The outer layer—*stratum supravasculare*—is thin and consists partly of circular bundles, partly of longitudinal. The latter predominate and form a fairly distinct layer just beneath the serosa.

The muscle cells of the uterus are long spindle-shaped elements, some having pointed, others blunt, branched, or frayed ends. In the virgin uterus they have a length of from 40 to 60μ. During pregnancy the muscular tissue of the uterus is greatly increased. This is due partly to increase in the number, partly to increase in the size of the muscle cells. At term the muscle cells frequently have a length of from 250 to 600μ. (Fig. 264.)

The *mucous membrane*. As the mucosa presents marked variation in structure, dependent upon the functional condition of the organ, it is necessary to describe:

1. The mucosa of the resting uterus.
2. The mucosa of the menstruating uterus.
3. The mucosa of the pregnant uterus.

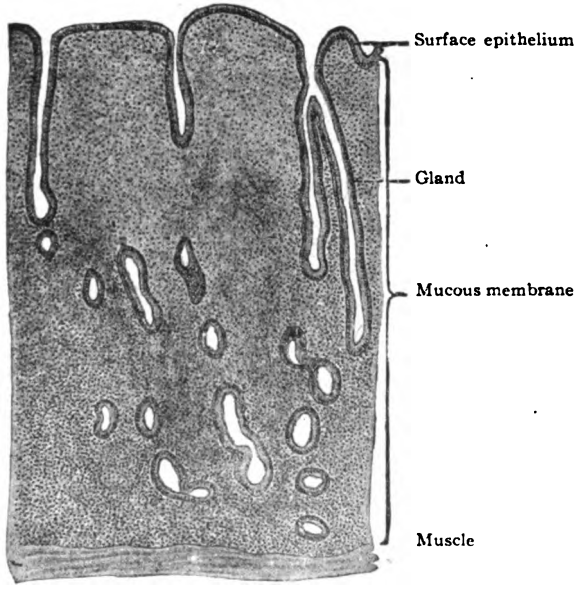

FIG. 265.—From Uterus of Young Woman. (Böhm and von Davidoff; preparation by Dr. J. Amann.) × 34.

1. THE MUCOSA OF THE RESTING UTERUS

This is from 1 to 3 mm. thick, and consists of a stroma, containing glands, and of a lining epithelium (Fig. 265). The stroma resembles embryonal connective tissue, consisting of fine fibrils and long irregular branching cells which form a sort of network, the meshes

of which are filled in with lymphoid cells and leucocytes. The epithelium is of the simple high columnar ciliated variety, the ciliary motion being toward the cervix. A basement membrane separates the epithelium from the underlying stroma. The glands are simple forked tubules lined by a single layer of columnar ciliated cells resting upon a basement membrane and continuous with the surface cells. The glands extend completely through the stroma. Near the surface they run a comparatively straight course. Deeper in the stroma their course is more tortuous, while the fundus is frequently turned at right angles to the rest of the tubule.

In the cervix the stroma is firmer and less cellular, and the mucous membrane is thicker and presents numerous folds—the *plicæ*

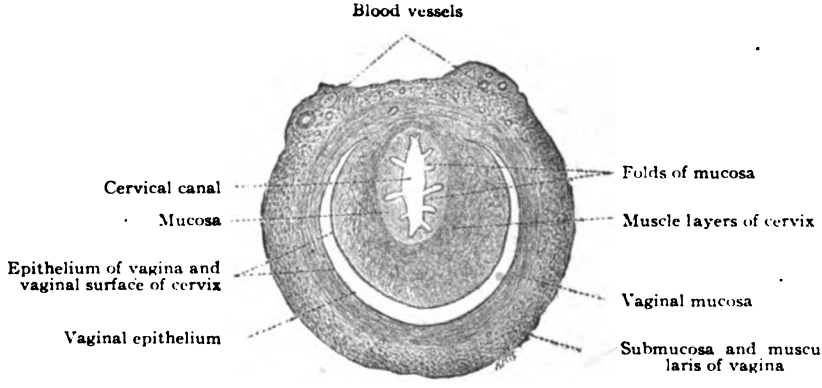

FIG. 266.—From Section of Dog's Cervix. × 4. (Technic 2, p. 385.)

palmatæ. The epithelium is higher than in the body of the organ. In addition to glands like those found in the body of the uterus, the cervical mucosa contains peculiar short, sac-like invaginations, lined with a continuation of the surface epithelium, which secretes a glairy mucus. Closure of the mouths of some of these sacs frequently occurs, leading to the formation of retention cysts, the so-called ovula Nabothi. At about the junction of middle and lower thirds of the cervical canal a change takes place in the epithelium. Here the simple columnar ciliated epithelium of the upper part of the cervix gradually passes over into a stratified squamous epithelium. Near the external os papillæ appear, the vaginal surface of the cervix being covered with a stratified squamous epithelium with underlying papillæ similar to and continuous with that of the vagina.

Near the external os the epithelium changes over into the stratified squamous epithelium with underlying papillæ, similar to that of the external surface of the cervix.

The Mucosa of the Menstruating Uterus

During the child-bearing period, the uterine mucosa is undergoing constant change. These changes occur in definitely limited cycles of approximately twenty-eight days each and, unless inhibited by

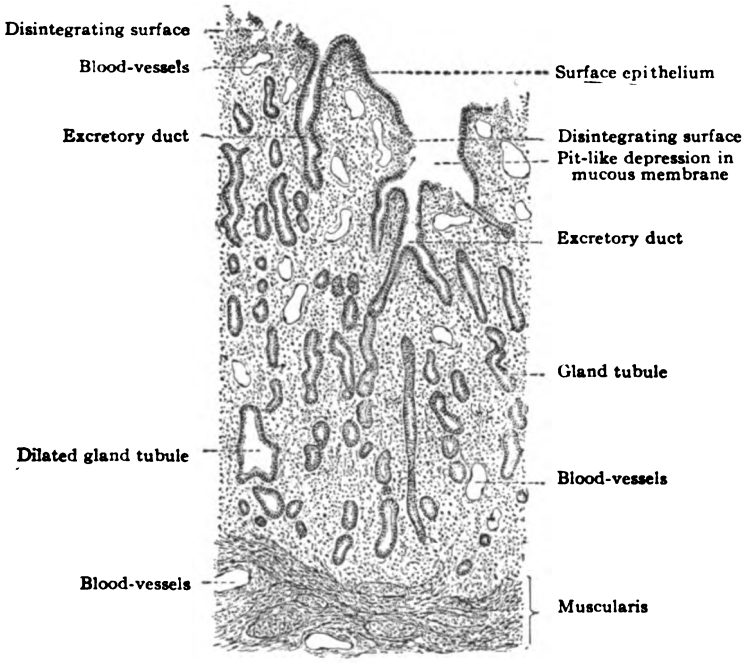

Fig. 267.—Section through Mucous Membrane of Virgin Uterus during First Day of Menstruation. × 30. (Schaper.)

the advent of pregnancy, reach their culmination in the phenomena of menstruation. While these changes occur in an evenly progressive manner, it is convenient for purposes of description to divide them into three stages:

(*a*) The stage of preparation.
(*b*) The stage of menstruation proper.
(*c*) The stage of reparation

(*a*) THE STAGE OF PREPARATION.—This begins five or six days before the actual flow of blood, and is marked by changes which affect the entire extent of the mucosa although they begin first in the fundus where they are always greatest and gradually spread toward the cervix where they are always least pronounced. The entire thickness of the mucous membrane and all its elements are altered progressively up to the onset of menstruation proper. The blood vessels, especially those near the surface become much distended and serum and lymph cells pass out into the stroma which thus becomes soft and edematous. The glands increase greatly in length, in side branchings, in width of lumina which become distended with mucous, and in increase in size and number of their lining epithelial cells. These glandular changes are most marked in the deeper parts of the mucosa, and give to it a meshy appearance—spongy layer, as contrasted with the more dense surface layer—the compact layer. There is also an increase in both number and size of the connective tissue cells especially in the surfacial layers. The cells become much larger by increase in cytoplasm and their nuclei become large and pale staining. They thus come to somewhat resemble decidual cells (see placenta). The surface at the same time becomes irregular and has a finely papillar appearance, the glands opening into deep pits or depressions. (Fig. 267.)

All of these changes increase progressively up to the onset of menstruation proper. Just before the external appearance of hemorrhage, at first minute, then larger subepithelial capillary hemorrhages occur. These coalesce forming larger lakes of blood just under the surface epithelium. The mucous membrane has now reached a thickness of about 6 mm., and is known as the *decidua menstrualis* (Fig. 267).

(*b*) THE STAGE OF MENSTRUATION PROPER.—This is marked by the escape of blood from the engorged vessels and the appearance of the external phenomena of menstruation. The blood escapes mainly by rupture of the vessel walls but also probably partly by diapedesis. The hemorrhage is at first subepithelial, but the epithelium soon gives way and the blood escapes into the cavity of the uterus. Much difference of opinion exists as to the amount of epithelial destruction during menstruation. That it must be great is evidenced by the amount and extent of the hemorrhages and by the extensiveness of repair required. Some claim that the entire

epithelium is destroyed with each menstrual period, others that the epithelium remains almost intact. Complete destruction of the epithelium is hardly compatible with the restoration of the epithelium which always follows menstruation. While there is undoubtedly destruction of most or all of the surface epithelium and of the glands to some considerable depth, the deeper portions of the glands always remain to take part in the succeeding regenerative phenomena.

(*c*) THE STAGE OF REPARATION.—After from three to five days the bleeding from the uterine mucosa ceases and the return to the nesting condition begins. This is marked by disappearance of the congestion, by decrease in thickness of the mucosa and in the size of the glands, and by restoration of the surface epithelium. Repair of the surface epithelium is extremely rapid, according to some there being a complete epithelial surface covering within twenty-four hours after the cessation of the menstrual bleeding.

3. THE MUCOSA OF THE PREGNANT UTERUS

This is known as the *decidua graviditatis*, and presents changes in structure somewhat similar to those which occur during menstruation, but more extensive. It is divided into three parts:

(*a*) The decidua serotina or decidua basalis—that part of the mucosa to which the ovum is attached.

(*b*) The decidua reflexa or decidua capsularis—that part of the mucosa under which the ovum is buried.

(*c*) The decidua vera—which consists of all the remaining mucosa.

The development of the decidua vera resembles the changes which take place in the mucosa during menstruation. There is the same thickening of the mucosa, and this thickening is due to the same factor, *i.e.*, distention of the blood-vessels and proliferation of the tissue elements. These changes are, however, much more extensive than during menstruation. The superficial part of the stroma between the mouths of the glands becomes quite dense and firm, forming the *compact layer*. The deeper part of the stroma contains many large veinous channels and numerous cavities, which are the lumina of the now widely distended and tortuous glands and which give to it a meshy appearance, the *spongy layer*.

Within the stroma, especially of the compact layer, develop the so-called *decidual cells*. These are peculiar typical cells derived from connective tissue cells. They are of large size (30 to 100μ), vary

greatly in shape, and in the later months of pregnancy have a rather characteristic brown color, which they impart to the superficial layers of the decidua vera. They are mostly mononuclear, although polynuclear and multinuclear forms occur.

During the latter half of pregnancy there is a gradual thinning of the decidua vera, due apparently to pressure. The surface epithelium and that of necks of the glands in the compact layer disappear, and the gland lumina in the spongy layer are changed into elongate spaces, which lie parallel to the muscular layer. The stroma of the decidua vera and the fœtal chorion are thus in close relation.

The decidua reflexa and decidua serotina have at first the same structure as the decidua vera. The decidua reflexa undergoes hyaline degeneration during the early part of pregnancy, and by the end of gestation has either completely disappeared (Minot) or has fused with the decidua vera (Leopold).

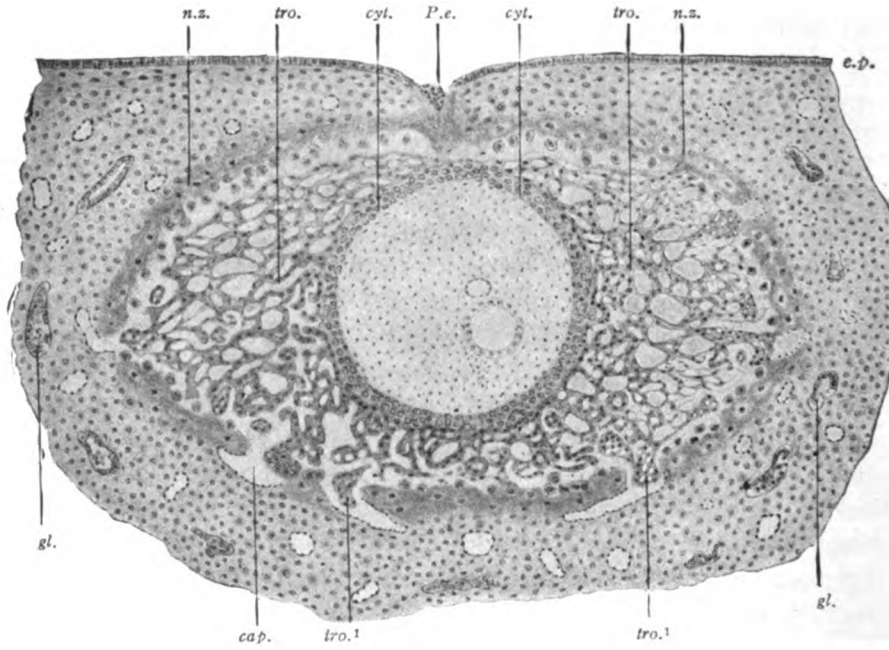

FIG. 267a.—Diagram of human ovum of 13-14 days, embedded in the uterine mucosa. *Bryce and Teacher.**

cap., Capillary; *cyt.*, cellular layer (cyto-tropohderm); *ep.*, uterine epithelium; *gl.*, uterine gland; *n.z.*, necrotic zone of decidua (uterine mucosa); *P.e.*, point of entrance of the ovum; *tro.*, syncytium (plasmodium, plasmodi-trophoderm); *tro*¹., masses of vacuolating syncytium invading capillaries. The cavity of the blastodermic vesicle is completely filled by mesoderm, and embedded therein are the amniotic and entodermic (yolk) vesicles. The natural proportions of the several parts have been observed.

The decidua serotina undergoes changes connected with the development of the placenta.

The Placenta[1]

The placenta consists of two parts, one of which is of maternal origin—*placenta uterina*—the other of fœtal origin—the *placenta fœtalis* or chorion frondosum. As it is in the placenta that the interchange takes place between the maternal and the fœtal blood, the relations between the maternal and fœtal parts of the placenta are extremely intimate. This relation consists essentially in the growing out from the fœtal placenta of finger-like projections—*villi*—which penetrate the maternal placenta, the latter being especially modified for their reception.

THE PLACENTA FŒTALIS.—This is a differentiated portion of the chorion. On the surface directed toward the fœtus the chorion after the third month is covered by a delicate fœtal membrane, the placental portion of the amnion. This consists of a surface epithelium, resting upon a layer of embryonal connective tissue which attaches it to the chorion. The chorion consists of (*a*) a compact layer—the *membrana chorii*—composed at first of embryonal, later of fibrous, connective tissue, and containing the main branches of the umbilical vessels and (*b*) an inner villous layer, which gives rise to finger-like projections which extend down from the fœtal into the maternal placenta and serve to connect the two.

The *chorionic villi* first appear as short projections composed entirely of epithelium. Each of these primary villi branches dichotomously, giving rise to a number of secondary villi. As they develop, the central portion of the original solid epithelial structure is replaced by connective tissue. Septa of connective tissue from the maternal placenta pass down among the villi and separate them into groups or *cotyledons*. The main or primary villi run a quite straight course from the chorion into the maternal placental tissue, apparently serving to secure firm union between the two. They are thus known as roots of attachment or *fastening villi* (Fig. 268). The secondary villi are given off laterally from the primary villi, end freely in the spaces between the latter—intervillous spaces (Fig. 268)—and are known as *free, terminal* or *floating villi* (Fig. 268).

The chorionic villus thus consists of a central core of connective

[1] For many facts as to the structure of the placenta, the writer is indebted to the excellent chapter on the subject added by Prof. Alfred Schaper to the fifth edition of Stöhr's "Textbook of Histology."

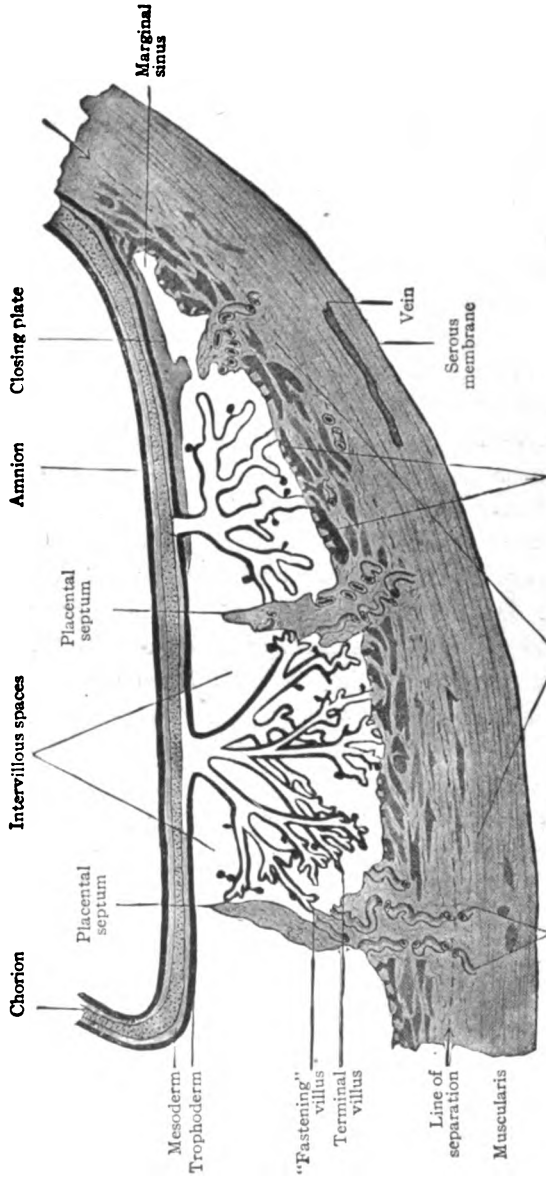

FIG. 268.—Diagrammatic section of placenta (*Strahl, Bonnet*)

tissue covered by a layer of epithelium. The connective tissue is of the mucous type and serves for the transmission of numerous blood-vessels. In the villi of early pregnancy the epithelium consists of an inner layer of distinctly outlined cells and an outer layer of fused cell bodies—a *syncytium* (Fig. 270, *A*, *a*)—containing small scattered nuclei. The villi of the later months of pregnancy have no definite epithelial covering, but are surrounded by a delicate homogeneous membrane, probably the remains of the syncytium. At various points on the surface of the villus are groups of nuclei. These stain

FIG. 269.—Section of Chorion of Human Embryo of one month (9 mm.). (Grosser.)

intensely, are surrounded by a homogeneous protoplasm, and form knob-like projections above the general surface of the villus. They are known as *cell patches*, or more properly as *nuclear groups* (Fig. 270, *c*), and represent remains of the nuclei of the epithelium of the younger villus. Between the nuclear groups the villus is covered only by a thin homogeneous membrane. Small villi usually resemble more closely in structure the younger villus, being frequently covered by a nucleated syncytium. Portions of the syncytium, especially of older villi, sometimes become changed into a peculiar hyaline substance containing numerous channels. This is known as *canalized*

fibrin, and may form dense layers upon the surface of the chorion. (Fig. 269.)

THE PLACENTA UTERINA.—This develops from the decidua serotina. The latter becomes much thinner than the rest of the decidua (decidua vera), but still shows a division into a deeper spongy portion containing gland tubules, and a superficial compact portion in which are large numbers of decidual cells. From the superficial portion connective-tissue septa—*placental septa*—grow into the fœtal placenta, as described above, separating its villi into cotyledons. Near the margins of the placenta these septa pass to the chorionic membrane and form beneath it a thin membrane, the *subchorionic placental decidua*. At the edge of the placenta, where decidua serotina passes over into the thicker decidua vera, there is a close attachment of the chorion to the former.

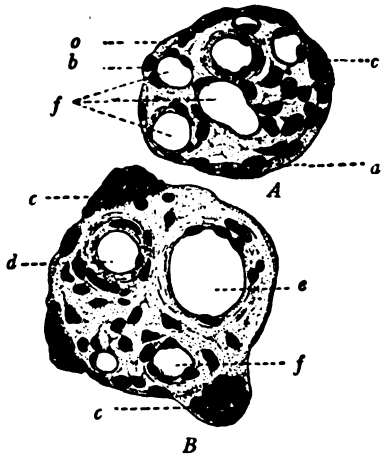

FIG. 270.—Cross Sections of Human Chorionic Villi at End of Pregnancy. ×250. (Schaper.) *A*, Small villus; *B*, larger villus. *a*, Protoplasmic coat (syncytium); *b*, epithelial nucleus; *c*, nuclear groups; *d*, small artery; *e*, small vein; *f*, capillaries.

As the placenta serves as the place of interchange of materials between the maternal and the fœtal circulations, the arrangement of the placental blood-vessels is of especial importance. Arterial branches from vessels of the uterine muscularis enter the serotina. In the very tortuous course which these vessels take through the serotina (Fig. 268) their walls lose their muscular and connective-tissue elements and become reduced to epithelial tubes. These branch in the placental septa and finally open into the intervillous spaces along the edges of the cotyledons. The veins take origin from these spaces near the centres of the cotyledons. The maternal blood thus passes through the intervillous spaces from periphery to centre, and in its course comes into direct contact with the freely terminating chorionic villi. It is to be noted that the blood-vessel systems of the mother and of the fœtus are both closed systems, and that consequently there is no direct admixture of maternal and fœtal blood. Interchange of materials must therefore always take place through the capillary walls and through the walls of the chorionic villi. (Fig. 268.)

Blood-vessels.—The arteries enter the uterus from the broad ligament and pass to the stratum vasculare of the muscularis, where they undergo extensive ramification. From the arteries of the stratum vasculare branches pass to the mucosa and give rise to capillary networks, which surround the glands and are especially dense just beneath the surface epithelium. From these capillaries the blood passes into a plexus of veins in the deeper portion of the mucosa, and these in turn empty into the venous plexuses of the stratum vasculare. Thence the veins accompany the arteries, leaving the uterus through the broad ligament.

Lymphatics.—These begin as minute spaces in the stroma and empty into the more definite lymph channels of the muscularis, which are especially well developed in the stratum vasculare. These in turn communicate with the larger lymph vessels in the subserous connective tissue.

Nerves.—Both medullated and non-medullated nerve fibres occur in the uterus. The latter are associated with minute sympathetic ganglia and supply the muscular tissue. The medullated fibres form plexuses in the mucosa, from which are given off fine fibres which terminate freely between the cells of the surface epithelium and of the uterine glands.

The Vagina

The wall of the vagina consists of four coats, which from without inward are fibrous, muscular, submucous, and mucous.

The *fibrous coat* consists of dense connective tissue with many coarse elastic fibres. It serves to connect the vagina with the surrounding structures.

The *muscular coat* is indistinctly divided into an outer longitudinal and an inner circular layer. The latter is usually not well developed and may be absent.

The *submucosa* is a layer of loose connective tissue, especially rich in elastic fibres and blood-vessels. Numerous large venous channels give to the submucosa the character of erectile tissue.

The *mucous membrane* consists of a papillated connective-tissue stroma of mixed fibrous and elastic tissue. The stroma usually contains diffuse lymphoid tissue and more rarely solitary nodules. Covering the stroma is a stratified squamous epithelium, the surface cells of which are extremely thin. The surface of the mucosa is not smooth,

but is folded transversely, forming the so-called *rugæ*. Most authorities agree that glands are wanting in the vagina, the mucus found there being derived from the glands of the cervix.

Blood-vessels.—The larger blood-vessels run in the submucosa, giving off branches which break up into capillary networks in the submucosa, muscularis, and stroma. The vascular networks have a general direction parallel to the surface. The capillaries empty into veins which form a plexus of broad venous channels in the muscularis.

The Lymphatics.—These follow in general the distribution of the blood-vessels.

Nerves.—Nerve fibres from both cerebro-spinal and sympathetic systems are found in the vagina. Medullated (sensory) fibres, the dendrites of spinal ganglion cells, form plexuses in the mucosa, from which are given off delicate non-medullated terminals to the epithelial cells. Non-medullated sympathetic fibres supply the muscularis and the muscle of the vessel walls. Along these nerves are small sympathetic ganglia.

In the *vestibule* the epithelium gradually takes on the structure of epidermis. Here are located small mucous glands—*glandulæ vestibulares minores*—especially numerous around the clitoris and opening of the urethra. Larger mucous glands—*glandulæ vestibulares majores*, or *glands* of *Bartholin*—analogous to Cowper's glands in the male, are also found in the walls of the vestibule.

The *clitoris* consists mainly of erectile tissue similar to that of the corpora cavernosa of the penis. It is covered with a thin epithelium with underlying papillæ, and is richly supplied with nerves having highly specialized terminations.

Development of the Urinary and Reproductive Systems

The development of the genito-urinary system is complicated by the appearance, and disappearance for the most part, of two sets of urinary organs, and the final formation of the permanent set. The three sets, in the order of their appearance, are the pronephroi, mesonephroi, and metanephroi. The first two sets, which are present only in the embryo in the higher animals, are the representatives of organs that function in the adult in the lower vertebrates. They are also intimately concerned in the development of the efferent duct system of the male reproductive organs in higher animals. The metanephroi, generally known as the kidneys, are the functional urinary organs in the majority of reptiles and in all birds and mammals.

The **pronephroi** are represented in the human embryo of 3 to 5 mm. by one or two small, condensed masses of mesoderm just lateral to the primitive segments

on each side in the cervical region. These masses, which are probably derived from the mesothelial lining of the body cavity, may or may not become hollow, but do not connect with the pronephric duct, and soon disappear. The *pronephric duct* appears about the same time as a derivative of the mesoderm just lateral to the primitive segments. It extends from the cervical region to the caudal region of the embryo where it bends mesially and opens into the gut. These ducts persist and become the ducts of the mesonephroi.

The **mesonephroi** begin to develop almost as soon as the pronephroi and just caudal to them. Condensations appear in the mesodermal tissue lateral to the primitive segments and become more or less tortuous. Lamina appear in these condensations, thus forming tubules which then connect at one end with the pronephric duct (now the mesonephric or Wolffian duct). The tubules develop progressively from before backward and finally form a series extending from the cervical region to the pelvic region of the embryo. At the distal end of each tubule a glomerulus, containing branches from the aorta, develops. The tubules increase in length and number and come to form a pair of large structures which project into the dorsal part of the body cavity. These are often spoken of as the *Wolffian bodies*. They reach the height of their development during the fifth or sixth week.

During the period of their existence in the embryo in higher animals, the mesonephroi functionate as urinary organs, not only through the agency of the glomeruli but also by means of the epithelium of the tubules themselves, among which numerous branches of the posterior cardinal veins ramify.

From the sixth week on, and coincident with the development of the metanephroi or kidneys, the mesonephroi atrophy, leaving finally only certain parts which differ in the two sexes. In the male some of the tubules in the cephalic portion persist as the vasa efferentia, while a few in the caudal portion remain as the paradidymis and vasa aberrantia; the duct persists as the vas epididymidis, vas deferens, and ejaculatory duct. In the female the mesonephric tubules disappear for the most part, only a few remaining to form the epoöphoron and paroöphoron, while the duct persists in part as Gärtner's canal.

Each **kidney** begins in embryos of 5 to 6 mm. as a hollow bud on the dorsal side of each mesonephric duct near its opening into the gut. This bud grows dorsally, and then turns cranially in the mesoderm between the vertebral column and the mesonephros. The proximal portion remains more slender as the ureter, while the distal end becomes dilated to form the primitive renal pelvis. From this dilated end a number of secondary evaginations grow out to form the papillary ducts and straight collecting tubules.

The mesodermal tissue surrounding the outgrowths from the primitive renal pelvis becomes condensed in places and gives rise to the convoluted portions of the uriniferous tubules and to Henle's loops. A glomerulus develops in connection with the distal end of each convoluted tubule. The portion of each tubule derived from the mesodermal tissue unites secondarily at the arched (junctional) tubule with the portion derived from the renal pelvis. Thus the kidney tubules are derived in part directly from undifferentiated mesoderm (convoluted tubules and Henle's loops) and in part from an outgrowth from the mesonephric duct (straight collecting tubules and papillary ducts).

During fœtal life the kidneys are distinctly lobulated, but after birth the surface becomes quite smooth.

The *genital gland* on each side appears on the mesial surface of the mesonephros as a thickening of a narrow band of the mesothelial lining of the body cavity. The cells in the band become differentiated into two kinds—small cuboidal cells which stain rather intensely, and larger spherical cells with clearer cytoplasm and vesicular nuclei. The latter are the *sex cells* which are destined to give rise to the ova in the female or the spermatozoa in the male. The whole thickened band is known as the *germinal epithelium*.

The cells of the germinal epithelium increase in number by mitosis and soon become differentiated into two layers—a superficial layer which retains its epithelial character and contains the sex cells, and a deeper layer which is destined to give rise in part to the stroma of the genital gland. The elevation caused by the increased number of cells projects into the body cavity as the *genital ridge*. From the superficial layer containing the sex cells a number of plugs or columns of cells grow down into the deeper layer carrying some of the sex cells with them. Thus far (up to about the fifth week) the changes are common to both sexes, and only later does the sex differentiation occur.

After about the fifth week certain changes occur in the genital ridge which differ accordingly as the ridge is to become an ovary or a testicle. In the case of the ovary a layer of loose connective tissue grows in between the surface epithelium and the cell columns or plugs mentioned above. The cell columns are thus pushed farther from the surface and constitute the medullary cords. These ultimately disappear. The surface epithelium again sends plugs of cells (Pflüger's egg cords) down into the underlying tissue. These cords are made up for the most part of epithelial cells which give rise to the follicular cells, but contain also a considerable number of sex cells (primitive ova). The egg cords then become broken up into smaller masses each of which contains a single primitive ovum (rarely more) and constitutes a primitive Graafian follicle. The sex cell grows in size and becomes the primary oöcyte (and finally the mature ovum), while the epithelial cells around it give rise to the stratum granulosum and germ hill of the mature Graafian follicle. During these processes the stroma also increases in amount, while the original germinal epithelium becomes reduced to a single layer of cuboidal cells. The formation of egg cords is usually completed before birth. (See also p. 360.)

In the case of the testicle a layer of dense connective tissue, the tunica albuginea, develops between the germinal epithelium and the sex cords. The epithelium becomes reduced to a single layer of flat cells. The sex cords which first grew into the underlying tissue and which contain the sex cells, are destined to give rise to the convoluted seminiferous tubules. This phase of development differs from that in the ovary inasmuch as in the latter case the first formed sex cords (medullary cords) disappear, Pflüger's egg cords being formed later and having no homologue in the testicle. The sex cords of the testicle become more and more convoluted and the sex cells (spermatogonia) proliferate rapidly. Beginning after birth and continuing up to the time of puberty, lumina appear in the sex cords and they thus give rise to the convoluted seminiferous tubules. The supporting cells (of Sertoli) are probably derived from the undifferentiated epithelial cells of the sex cords. (See also p. 341.)

TECHNIC

(1) A human uterus—if possible from a young adult—or, if this cannot be obtained, the uterus of a cat or dog, is cut transversely into slices about 1 cm. thick and fixed in Zenker's fluid (technic 10, p. 8) or in formalin-Müller's fluid (technic 6, p. 7). For topography these slices are cut in half through the middle of the uterine cavity and sections made through the entire half organ. These are stained with hæmatoxylin-picro-acid-fuchsin (technic 3, p. 24) and mounted in balsam. For details of the mucous membrane, cut away most of the muscle from around the half slice, being careful not to touch the mucous surface; make thin sections, stain with hæmatoxylin-eosin (technic 1, p. 23), and mount in balsam.

(2) Sections of the cervix may be prepared in the same manner as the preceding.

(3) Placental tissue may be cut into small cubes and treated with the same technic (1).

(4) If a human or animal uterus with the placenta *in situ* is obtainable it should be cut into thin slices and fixed in formalin-Müller's fluid. The blocks of tissue should be so arranged that sections include the utero-placental junction. They may be stained with hæmatoxylin-eosin or with hæmatoxylin-picro-acid-fuchsin (see above).

(5) Treat pieces of the human vagina according to technic 1, p. 259.

General References for Further Study

Ballowitz: Weitere Beobachtungen über den feineren Bau der Saugethier-Spermatozoen. Zeit. f. wiss. Zool., Bd., lii, 1891.

Hertwig: Lehrbuch der Entwickelungsgeschichte des Menschen und der Wirbelthiere, Jena, 1896.

Hilschmau und Adler: Der Bau der Uterusschleimhaut des geschlechtsreifen Weibes mit besonderer Berücksichtigung der Menstruation. Monat. f. Gebmtshülfe u. Gynaekologie. B. 27, 1908.

Kölliker: Handbuch der Gewebelehre des Menschen.

Nagel: Das menschliche Ei. Arch. mik. Anat., Bd. xxxi, 1888.

Ruckert: Zur Eireifung der Copepoden. Anat. Hefte, I. Abth., Bd. iv, 1894.

Schaper: Chapter on the Placenta in Stöhr's Text-book of Histology, 5th ed.

Sobotta: Ueber die Bildung des Corpus luteum bei der Maus. Arch. f. mik. Anat., Bd. xlvii, 1896.—Ueber die Bildung des Corpus luteum beim Kaninchen. Anat. Hefte, I. Abth., Bd. viii, 1897.

CHAPTER XX

THE SKIN AND ITS APPENDAGES

The Skin

THE skin or cutis consists of two parts: (1) The derma, corium, or true skin, and covering this, (2) the epidermis or cuticle. The derma is a connective-tissue derivative of the mesoderm, the epidermis an epithelial derivative of the ectoderm.

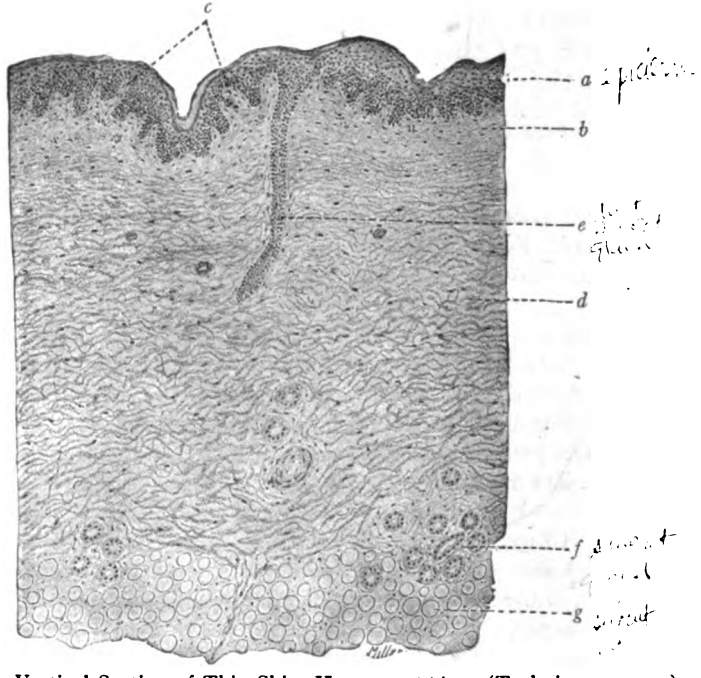

FIG. 271.—Vertical Section of Thin Skin, Human. ×60. (Technic 2, p. 391.) *a* Epidermis; *b*, pars papillaris of derma; *c*, papillæ; *d*, pars reticularis of derma; *e*, duct of sweat gland; *f*, sweat gland; *g*, subcutaneous fat.

THE DERMA.—This is divided into two layers which blend without distinct demarcation. The deeper is known as the pars reticularis, the more superficial as the pars papillaris (Fig. 263).

The *pars reticularis* is made up of rather coarse, loosely arranged

white and elastic fibres with connective-tissue cells in varying numbers. The fibres run for the most part parallel to the surface of the skin.

The *pars papillaris* is similar in structure to the preceding, but both white and elastic fibres are finer and more closely arranged. Externally this layer is marked by minute folds which are visible to the naked eye, and can be seen intersecting one another and enclosing small irregular areas of skin. In the thick skin of the palms and soles these furrows are close together and parallel, while between them are long corresponding ridges. In addition to the furrows and

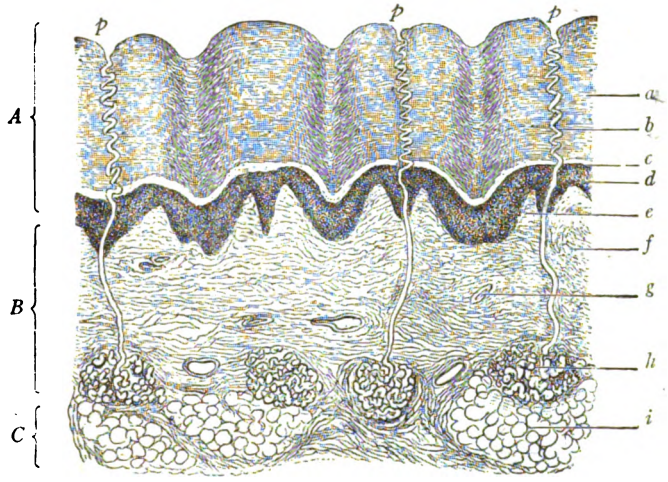

FIG. 272.—Thick Vertical Section through Skin of Finger Tip. (Merkel-Henle.) *A*, Epidermis; *B*, derma; *C*, subcutis. *a*, Stratum corneum; *b*, duct of sweat gland; *c*, stratum lucidum; *d*, stratum germinativum; *e*, papilla of derma; *f*, derma; *g*, blood-vessel; *h*, sweat gland; *i*, fat lobule; *p*, sweat pore.

ridges the entire surface of the corium is beset with minute papillæ. These vary in structure, some ending in a single point—*simple papillæ*—others in several points—*compound papillæ;* some containing blood-vessels—*vascular papillæ;* others containing special nerve terminations—*nerve papillæ* (Fig. 273).

Smooth muscle cells occur in the corium in connection with the sweat glands. In the skin of the scrotum—tunica dartos—and of the nipple, the smooth muscle cells are arranged in a network parallel to the surface. In the face and neck striated muscle fibres penetrate the corium.

Beneath the corium is the *subcutaneous tissue.* This consists of

vertically disposed bands of connective tissue—the *retinaculæ cutis*—which serve to unite the corium to the underlying structures and enclose fat lobules. In some parts of the body this subcutaneous fat forms a thick layer—the *panniculus adiposus.*

THE EPIDERMIS.—This is composed of stratified squamous epithelium. In the comparatively thin skin of the general body surface the epidermis is divided into two sublayers: (1) One lying just above the papillary layer of the derma, and known as the stratum

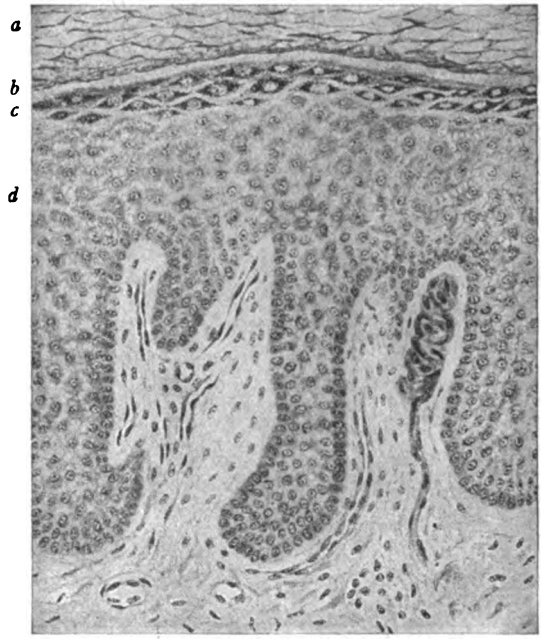

FIG. 273.—From Vertical Section through Skin of Human Finger Tip. ×200. (Schäfer.) *a*, Stratum corneum; *b*, stratum lucidum; *c*, stratum granulosum; *d*, stratum germinativum. To the left a *vascular papilla;* to the right a *nerve papilla* containing tactile corpuscle.

germinativum (stratum mucosum—stratum Malpighii); (2) the other constituting the superficial layer of the skin—the horny layer or stratum corneum. In the thick skin of the palms and soles two additional layers are developed; (3) the stratum granulosum; and (4) the stratum lucidum (Fig. 272).

(1) The *stratum germinativum* consists of several layers of cells, The deepest cells are columnar and form a single layer (stratum cylindricum), which rests upon a basement membrane separating it

from the derma. The membrane and cells follow the elevations and depressions caused by the papillæ. The rest of the stratum germinativum consists of large polygonal cells. These cells have well-developed intercellular bridges, which appear as spines projecting from the surfaces of the cells. For this reason the cells are sometimes called "prickle" cells, and the layer, the "stratum spinosum." The spines cross minute spaces between the cells, which are believed to communicate with the lymph spaces of the derma (Fig. 274, *c*). The cells of the stratum germinativum are usually in a state of active mitosis.

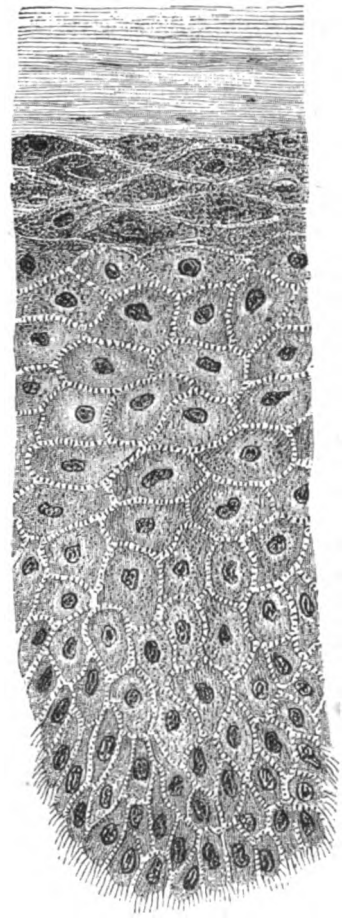

FIG. 274.—From Vertical Section through Thick Skin. (Merkel-Henle.) *a*, Stratum lucidum; *b*, stratum granulosum; *c*, stratum germinativum, showing intercellular bridges.

(2) The *stratum granulosum* is well developed only where the skin is thick. It consists of from one to three layers of flattened polygonal cells. The protoplasm of these cells contains deeply staining granules—keratohyaline granules—which probably represent a stage in the formation of the horny substance—keratin—of the corneum cells. The nuclei of these cells always show degenerative changes, and there is reason for believing that this karyolysis is closely associated with the formation of the keratohyaline granules (Fig. 274, b).

(3) The *stratum lucidum* is also best developed where the skin is thickest. It consists of two or three layers of flat clear cells, the outlines of which are frequently so indistinct that the layer appears homogeneous. The transparency of the cells is due to the presence of a substance known as *eleidin*, and derived from the keratohyaline granules of the stratum granulosum (Fig. 274, *a*).

(4) The *stratum corneum* varies greatly in thickness, reaching its greatest development in the skin of the palms and soles. The cells

are flattened and horny, especially near the surface. Some appear homogeneous, others have a lamellated appearance. They contain pareleidin, a derivative of the eleidin of the stratum lucidum. Nuclei are lost, but in many of the cells can be seen the spaces which the nuclei once occupied. Constant desquamation of these cells goes on, cells from the deeper layers taking their place.

The color of the skin in the white races is due to pigmentation of the deeper layers of the epidermis, more particularly of the stratum cylindricum. In certain parts of the body pigmentation of the connective-tissue cells of the derma also occurs In the dark races all cells of the epidermis are pigmented, although there is less pigment in the surface cells than in the cells more deeply situated.

Two kinds of glands occur in the skin—sebaceous glands and sweat glands.

SEBACEOUS GLANDS.—These are usually associated with the hair follicles, and will be described in that connection. Sebaceous glands unconnected with hair occur along the margin of the lips, in the glans and prepuce of the penis, and in the labia minora.

SWEAT GLANDS (*glandulæ sudoriparæ.*)—These are found throughout the entire skin with the exception of the margin of the lips, the inner surface of the prepuce, and the glans penis. They are simple coiled tubular glands. The coiled portion of the gland usually lies in the subcutis, although it may lie wholly or partly in the deeper portion of the pars reticularis. The excretory duct runs a quite straight course through the derma, and enters the epidermis in one of the depressions between the papillæ. In the epidermis the duct takes a spiral course to the surface, where it opens into a minute pit just visible to the naked eye—the *sweat pore* (Fig. 264). The coiled portion of the gland is lined with a simple cuboidal epithelium, having a granular protoplasm. In the smaller glands the epithelium rests directly upon the basement membrane. In the larger glands a longitudinal layer of smooth muscle cells separates the glandular epithelium from the basement membrane. The walls of the ducts consist of two or three layers of cuboidal epithelial cells, resting upon a delicate basement membrane, outside of which are longitudinally disposed connective-tissue fibres. On reaching the horny layer the epithelial wall of the duct ceases, the duct consisting of a mere channel through the epithelium (Fig. 272).

TECHNIC

(1) Fix the volar half of a finger-tip in formalin-Müller's fluid (technic 6, p. 7) or in absolute alcohol. Curling may be prevented by pinning to a piece of

cork. Sections are cut transversely to the ridges, stained with hæmatoxylin-picro-acid-fuchsin (technic 3, p. 24), and mounted in balsam. Thick sections should be cut for the study of the coil glands with their ducts; thin sections for cellular details of the layers.

(2) Prepare in the same manner and for contrast with the preceding, sections of thin skin from almost any part of the body.

(3) Prepare a piece of negro skin in the same manner and note the position of the pigment.

The Nails

The nails are modified epidermis. Each nail consists of: (*a*) a *body*, the attached uncovered portion of the nail; (*b*) a *free edge*, the anterior unattached extension of the body; (*c*) the *nail root*, the posterior part of the nail which lies under the skin (Fig. 275).

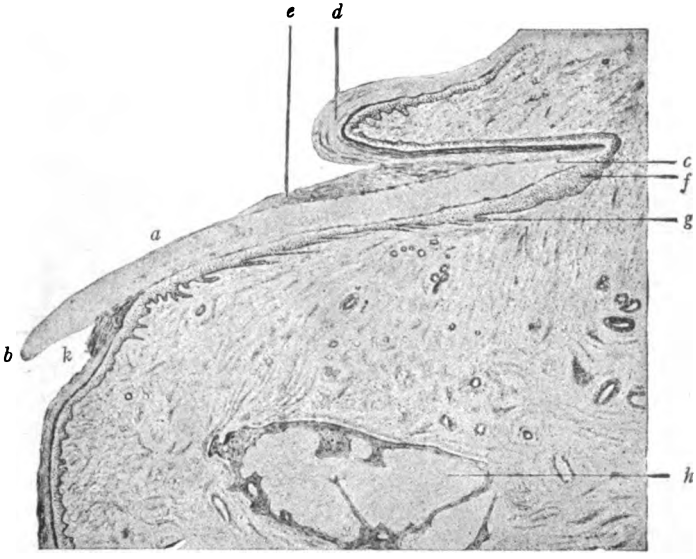

FIG. 275.—Longitudinal Section through Root of Human Nail and Nail Bed. ×10. (Schaper.) *a*, Body of nail; *b*, free edge; *c*, root of nail; *d*, epidermis; *e*, eponychium; *f*, stratum germinativum of nail; *g*, folds in derma of nail bed; *h*, bone of finger; *k*, hyponychium.

The nail lies upon a specially modified portion of the corium, the *nail bed*, which beneath the nail root and somewhat forward of the root is known as the *matrix*. The nail bed is bounded on either side by folds of skin, the *nail wall*, while between the nail wall and the nail bed is a furrow, the *nail groove* (Fig. 276).

The nail bed consists of corium. Its connective-tissue fibres are arranged partly horizontal to the long axis of the nail, partly in a

vertical plane extending from the periosteum to the nail. Papillæ are not present, but in their place are minute longitudinal ridges, which begin at the matrix and, increasing in height as they pass for-

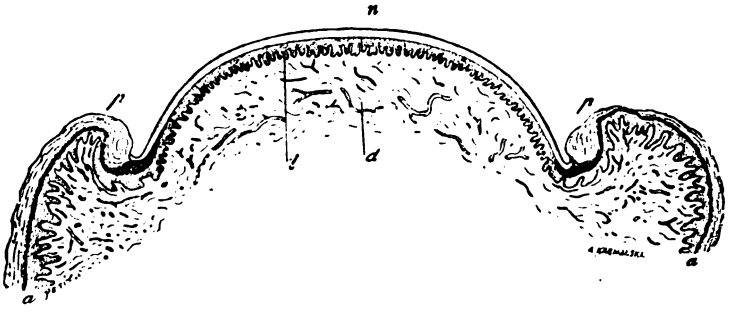

FIG. 276.—Transverse Section of Nail and Nail Bed. (Rannie.) *n*, Nail; *a*, epidermis; *p*, nail wall, to inner side of which is the nail groove; *l*, folds of derma; *d*, nail bed.

ward, terminate abruptly at the end of the nail bed, beyond which are the usual papillæ of the derma.

The nail itself consists of two parts[1]—an outer harder part or

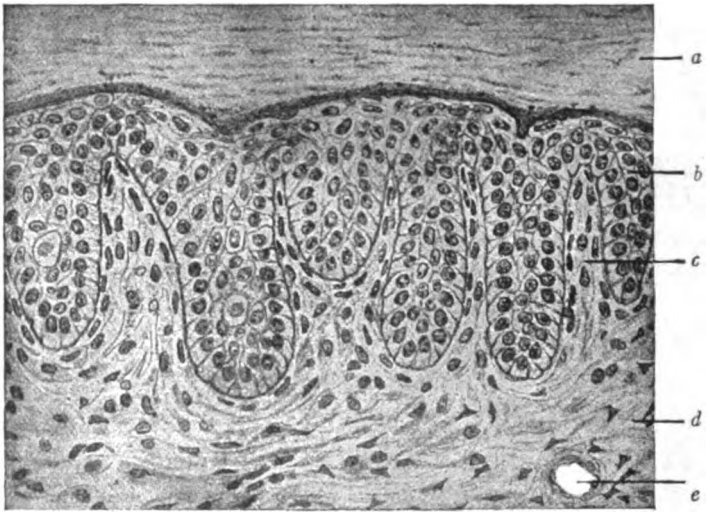

FIG. 277.—Vertical Transverse Section through Nail Body. ×280. (Szymonowicz.) *a*, Nail; *b*, stratum germinativum; *c*, ridge of nail bed; *d*, derma; *e*, blood-vessel.

true nail, and an under softer part. The outer portion is hard and horny, is developed from the stratum lucidum, and consists of several layers of clear, flat, nucleated cells. These layers overlap in such a

[1] Another division of nail and nail bed considers the nail as composed of the hard part only, the soft stratum germinativum being considered a part of the nail bed.

manner that each layer extends a little farther forward than the layer above. The under softer portion of the nail corresponds to the stratum germinativum of the skin and, like the latter, consists of polygonal "prickle" cells and a stratum cylindricum resting upon a basement membrane. In the matrix where the process of nail formation is going on, this layer is thicker than elsewhere and is white and opaque from the presence of keratohyalin. The convex anterior margin of this area can be seen with the naked eye and is known as the *lunula*.

At the junction of nail and skin, in the nail groove, the stratum corneum extends somewhat over the nail as its *eponychium*. A similar extension of the stratum corneum occurs on the under surface of the nail where the nail becomes free from the nail bed. This is known as the *hyponychium* (Fig. 275).

Growth of nail takes place by a transformation of the cells of the matrix into true nail cells. In this process the outer hard layer is pushed forward over the stratum germinativum, the latter remaining always in the same position.

TECHNIC

(1) Remove two or more distal phalanges from the fingers of a new-born child and fix in absolute alcohol or in formalin-Müller's fluid (technic 6, p. 7). After fixing, the bone should be carefully removed. Both longitudinal and transverse sections are made, stained with hæmatoxylin-picro-acid-fuchsin (technic 3, p. 24), and mounted in balsam. In cutting the sections it is usually best so to place the block that the knife passes through volar surface first, through nail last.

(2) The cellular elements of nail do not show well in sections For demonstrating the nail cells, boil a piece of nail in concentrated potash lye or warm it in strong sulphuric acid, scrape off cells from the softened surface, and mount in glycerin.

The Hair

The hair, like the nail, is a development of the epidermis. The hair itself consists of a *shaft*, that portion of the hair which projects above the skin, and a *root*, that portion embedded within the skin. At its lower end the root presents a knob-like expansion, the *hair bulb*, in the under surface of which is a cup-like depression, which receives an extension of corium. This is known as the *papilla*. Enclosing the hair root is the *hair follicle*.

THE HAIR.—This is composed of epithelial cells arranged in three layers, which from within outward are medulla, cortex, and cuticle (Fig. 279).

(1) The *medulla* occupies the central axis of the hair. It is absent

in small hairs, and in the large hairs does not extend throughout their entire length. It is from 16 to 20μ in diameter, and consists of from two to four layers of polygonal or cuboidal cells with finely granular, usually pigmented protoplasm and rudimentary nuclei.

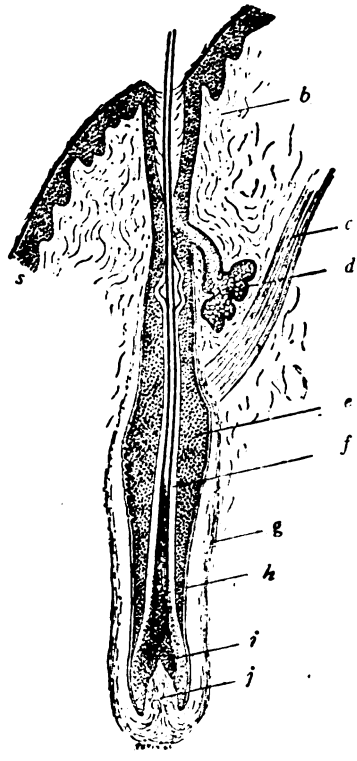

FIG. 278.—Longitudinal Section of Hair and its Follicle from Vertical Section of Scalp. (Ranvier.) *a*, Shaft of hair; *b*, derma; *c*, arrector pili muscle; *d*, sebaceous gland; *e*, outer root sheath; *f*, inner root sheath; *g*, connective-tissue follicle; *h*, vitreous membrane; *i*, hair bulb; *j*, papilla; *s*, epidermis.

(2) The *cortex* makes up the main bulk of the hair and consists of several layers of long spindle-shaped cells, the protoplasm of which shows distinct longitudinal striations, while the nuclei appear atrophied. As these striations give the hair the appearance of being composed of fibrillæ, the term "cortical fibres" has been applied to them. In colored hair, pigment granules and pigment in solution are found in and between the cells of this layer. This pigment determines the color of the hair. In the root the cortical cells are less flattened than in the shaft.

(3) The *cuticle* has a thickness of about 1μ, and consists of clear scale-like, non-nucleated epithelial cells. These overlap one another like shingles on a roof, giving to the surface of the hair a serrated appearance (Fig. 279).

THE HAIR FOLLICLE.—This is also a modification of the skin. In the formation of the follicles of the finer (lanugo) hairs the epidermis alone is concerned. The follicles of the larger hairs contain both epidermal and dermal elements. The latter form the connective-tissue follicle, while the epidermis forms the root sheaths.

(1) The *root sheath* consists of two sub-layers—the *inner root sheath* and the *outer root sheath* (Figs. 280, 281 and 282).

(*a*) The inner root sheath consists of three layers, which from within outward are the cuticle of the root sheath, Huxley's layer, and Henle's layer.

The *cuticle* of the root sheath lies against the cuticle of the hair and is similar to the latter in structure. It consists of thin scale-like overlapping cells, nucleated in the deeper parts of the sheath, non-nucleated nearer the surface (Figs. 280, 281 and 282, *c*).

Huxley's layer lies immediately outside the cuticle of the root sheath, constituting the middle layer of the inner root sheath. It consists of about two rows of elongated cells with slightly granular protoplasm containing eleidin. In the deeper portion of the root

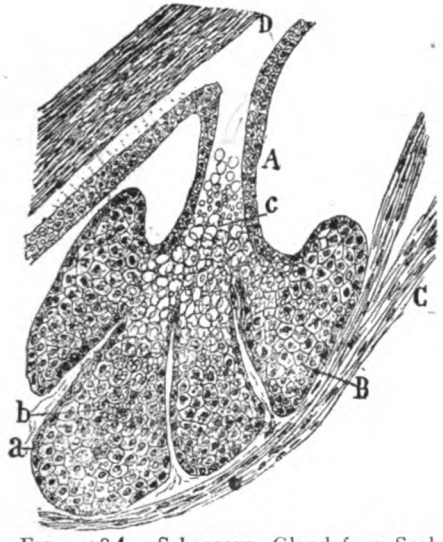

FIG. 278*A*.—Sebaceous Gland from Scalp (Cajal). *A*, excretory duct; *B*, gland alveolus; *C*, arrector pili muscle; *D*, hair; *a*, peripheral cells containing few secretion granules; *b*, central cells full of secretion granules; *c*, cellular secretion entering duct.



FIG. 279.—Longitudinal Section of Hair. ×350. (Kölliker.) *a*, Medulla; *b*, cortex; *c*, cuticle.

these cells contain nuclei. Nearer the surface the nuclei are rudimentary or absent (Figs. 280, 281 and 282, *d*).

Henle's layer is a single row of clear flat cells. In the bulb these cells may contain nuclei, elsewhere they are non-nucleated (Fig. 282, *e*).

(*b*) The outer root sheath is derived from the stratum germinativum to which it corresponds in structure. Next to the vitreous membrane is a single layer of columnar cells (stratum cylindricum). Inside of this are several layers of "prickle" cells (Figs. 280, 281 and 282, *f*).

(2) The *connective-tissue follicle* consists of three layers—an inner vitreous membrane, a middle vascular layer, and an outer fibrous layer.

(*a*) The vitreous or hyaline membrane is a thin homogenous

structure of the nature of an elastic membrane. It lies next to the outer root sheath and corresponds to the basement membrane of the derma (Figs. 280, 281 and 282, *g*).

(*b*) The middle or vascular layer is composed of fine connective-tissue-fibres, the general arrangement of which is circular. Cellular elements are quite abundant, while elastic fibres are, as a rule, absent. As its name would indicate, this layer is especially rich in blood-vessels (Figs. 280, 281 and 282, *i*).

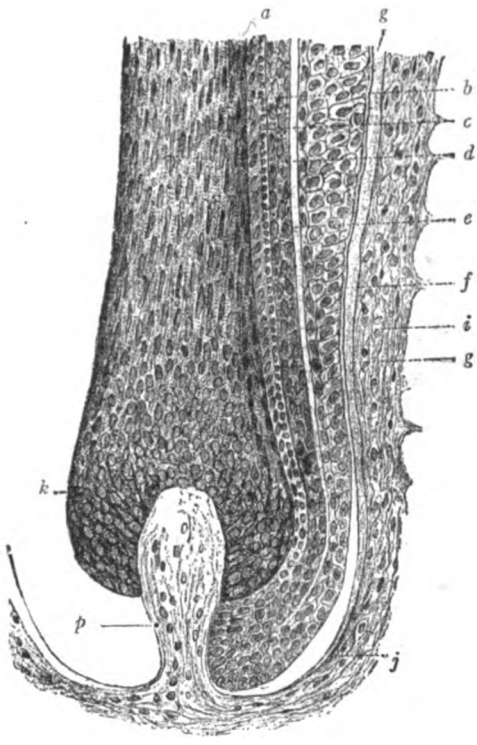

FIG. 280.—Longitudinal Section of Lower End of Root of Hair, including Papilla. (Kölliker.) *a*, Root of hair; *b*, cuticle of hair; *c*, cuticle of root sheath; *d*, Huxley's layer of inner root sheath; *e*, Henle's layer of inner root sheath; *f*, outer root sheath; *g*, vitreous membrane; *j*, connective-tissue follicle; *k*, bulb of hair; *p*, papilla.

(*c*) The outer or fibrous layer consists of rather coarse, loosely woven bundles of white fibres, which run mainly in a longitudinal direction. Among these are elastic fibres and a few connective-tissue cells.

In the deeper portion of the root, some little distance above the bulb, all the layers of the hair and its follicle can be distinctly seen. The differentiation of the layers becomes less marked as one passes in either direction. At about the level of the entrance of the ducts of the sebaceous glands (see p. 397) the inner root sheath disappears, and the outer root sheath passes over into the stratum germinativum of the skin, while between the outer root sheath (now stratum germinativum) and the hair are interposed the outer layers of the skin, stratum granulosum and stratum lucidum when present, and stratum corneum. All of these are continuous with the same layers of the skin. In the region of the bulb the outer root sheath first becomes thinner, then disappears, while the layers of the inner root sheath retain their identity until the neck of the papilla is reached, at which point the different layers coalesce.

The *arrector pili muscle* (Fig. 278, *c*) is a narrow band, or bands, of smooth muscle connected with the hair follicle. It arises from the outer layer of the derma on the side toward which the hair slants and is inserted into the wall of the follicle at the junction of its middle and lower thirds, the sebaceous gland being usually included between the muscle and the hair (see below). The contraction of the muscle thus tends to straighten the hair and to compress the gland.

The *sebaceous glands* are with few exceptions connected with the hair follicles (Fig. 278*A*). They are simple or branched alveolar glands.

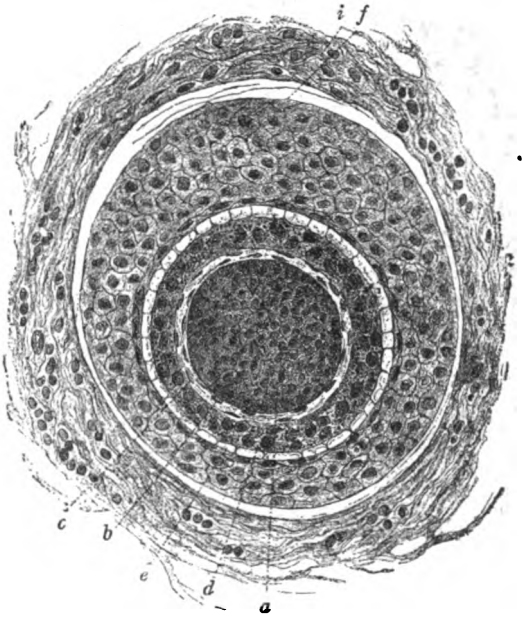

FIG. 281.—Transverse Section through Root of Hair and Hair Follicle. (Kölliker.) *a*, Hair; *b*, hair cuticle; *c*, cuticle of root sheath; *d*, Huxley's layer; *e*, Henle's layer; *f*, outer root sheath; *i*, connective-tissue follicle.

The size of the gland bears no relation to the size of the hair, the largest glands being frequently connected with the smallest hairs. The glands are spherical or oval in shape and each gland is enclosed by a connective-tissue capsule derived from the follicle or from the derma. Beneath the capsule is a basement membrane continuous with the vitreous membrane of the follicle. The wide excretory duct empties into the upper third of the follicle and is lined with stratified squamous epithelium continuous with the outer root sheath and stratum germinativum. The lower end of the duct opens into several simple or branched alveoli, at the mouths of which the epithelium becomes

reduced to a single layer of cuboidal cells. In the alveoli themselves the cells are spheroidal or polyhedral, and usually fill the entire alveolus. These cells, like those lining the duct, are derivatives of the outer root sheath. The secretion of the gland—an oily substance called *sebum*—appears to be the direct product of disintegration of the alveolar cells, which can usually be seen in all stages of the process of transformation of the cell into the secretion of the gland. The most peripheral cells show the least secretory changes, containing a few small fat droplets. The central cells and those in the lumen of the duct show the most marked changes, their protoplasm being almost wholly converted into fat, their nuclei shrunken or disintegrated or lost. In the middle zone are cells showing intermediary stages in the process.

FIG. 282.—From Longitudinal Section through Hair and Hair Follicle. Enlarged to 800 diameters. (Schäfer.) *A*, Hair. *a*, Cortex of hair; *b*, cuticle of hair. *B*, Inner sheath. *c*, Cuticle of root sheath; *d*, Huxley's layer; *e*, Henle's layer; *f*, outer root sheath; *g*, vitreous membrane; *i*, connective-tissue follicle; *m*, fat cells.

Shedding of hair occurs in most mammalia at regularly recurring periods. In man there is a constant death and replacement of hair. In a hair about to be shed, the bulb becomes cornified and splits up into a number of fibres. The hair next becomes detached from the papilla and from the root sheath and is cast off, the empty root sheaths collapsing and forming a cord of cells between the papilla and lower end of the shedding hair. If the dead hair is to be replaced by a new one, there sooner or later occurs a proliferation of the cells of the outer root sheath in the region of the old papilla. From this "hair germ" the new hair is formed in a manner similar to embryonal hair formation, the new hair growing upward, under, or to one side of the dead hair, which it finally replaces.

As to the manner in which growth of hair takes place, two views are held. According to one of these, the hair, cuticle, and inner root sheath are replenished by proliferation of the epithelial cells surrounding the papilla. These parts thus grow from below toward the surface. The oldest cells of the outer root-sheath, on the other hand, lie against the vitreous membrane, so that growth of this sheath takes place from without inward. According to the second view,

the various parts of the hair and its follicle are direct derivatives of the different layers of the skin, and their growth takes place by a continuous process of invagination. Thus the most peripheral cells of the outer root-sheath—stratum cylindricum—pass over the papilla and turn upward to form the medulla of the hair; the deeper cells—stratum spinosum—of the outer root-sheath become continuous with the cortex of the hair; the stratum lucidum, with the sheath of Henle, which turns up on the hair as its cuticle; Huxley's layer, with the cuticle of the inner root-sheath. According to this view growth of hair is accomplished by continuous growth downward from the surface, and turning up into the hair, of these layers.

TECHNIC

Pin out small pieces of human scalp on cork and fix in absolute alcohol or in formalin-Müller's fluid (technic 6, p. 7). From one block cut sections perpendicular to the surface of the scalp and in the long axes of the hair and follicles; From a second block cut sections at right angles to the hair follicles, *i.e.*, not quite parallel to the surface of the scalp but a little obliquely. By this means not only are transverse sections secured, but if the block be sufficiently long the follicles are cut through at all levels. Sections are stained with hæmatoxylin-picro-acid-fuchsin (technic 3, p. 24) and mounted in balsam.

Blood-vessels of the skin. From the larger arteries in the subcutaneous tissue branches penetrate the pars reticularis of the derma, where they anastomose to form cutaneous networks. The latter give off branches, which pass to the papillary layer of the derma and there form a second series of networks, the subpapillary, just beneath the papillæ. From the cutaneous networks arise two sets of capillaries, one supplying the fat lobules, the other supplying the region of the sweat glands. From the subpapillary networks are given off small arteries which break up into capillary networks for the supply of the papillæ, sebaceous glands, and hair follicles. The return blood from these capillaries first enters a horizontal plexus of veins just under the papillæ. This communicates with a second plexus just beneath the first. Small veins from this second plexus pass alongside the arteries of the deeper part of the corium, where they form a third plexus with larger, more irregular meshes. Into this plexus pass most of the veins from the fat lobules and sweat glands, although one or two small veins from the sweat glands usually follow the duct and empty into the subpapillary plexus. The blood next passes into a fourth plexus in the subcutaneous tissue, from which arise veins of considerable size. These accompany the arteries.

Small arteries from the plexuses of the skin and subcutis pass to the hair follicle. The larger arterioles run longitudinally in the outer

layer of the follicle. From these are given off branches which form a rich plexus of small arterioles and capillaries in the vascular layer of the follicle. Capillaries from this plexus also pass to the sebaceous glands, the arrectores pilorum muscles, and the papillæ.

The **lymphatics** of the skin. These begin as clefts in the papillæ, which open into a horizontal network of lymph capillaries in the pars papillaris. This communicates with a network of larger lymph capillaries with wider meshes in the subcutaneous tissue. The latter also receives lymph capillaries from plexuses which surround the sebaceous glands, the sweat glands, and the hair follicles.

The **nerves** of the skin. These are mainly sensory. Efferent sympathetic axones supply the smooth muscle of the walls of the blood-vessels, the arrectores pilorum, and secretory fibres to the sweat glands. The medullated sensory nerves are peripheral processes of spinal ganglion cells. The larger trunks lie in the subcutis, giving off branches which pass to the corium, where they form a rich subpapillary plexus of both medullated and non-medullated fibres. From the subcutaneous nerve trunks and from the subpapillary plexus are given off fibres which terminate in more or less elaborate special nerve endings (see page 430). Their location is as follows: (1) *In the subcutis:* Vater-Pacinian corpuscles, the corpuscles of Ruffini, and the Golgi-Mazzoni corpuscles of the finger-tip. The first two forms are most numerous in the palms and soles. (2) *In the derma:* Tactile corpuscles of Meissner and Wagner. These are found in the papillæ, especially of the finger tip, palm, and sole. Krause's end bulbs—usually in the derma just beneath the papillæ, more rarely in the papillæ themselves. (3) *In the epithelium:* Free nerve endings among the epithelial cells.

Branches of the cutaneous nerves supply the hair follicles. As a rule but one nerve passes to each follicle, entering it just below the entrance of the duct of the sebaceous gland. As it enters the follicle the nerve fibre loses its medullary sheath and divides into two branches, which further subdivide to form a ring-like plexus of fine fibres encircling the follicle. From this ring, small varicose fibrils run for a short distance up the follicle, terminating mainly in slight expansions on the vitreous membrane.

TECHNIC

For the study of the blood-vessels of the skin inject (technic, p. 10) the entire hand or foot of a new-born child. Examine rather thick sections either mounted unstained or stained only with eosin.

Development of the Skin, Nails, and Hair

The epidermis is, as already noted, of ectodermic origin. It consists at first of a single layer of cuboidal cells. This soon differentiates into two layers—

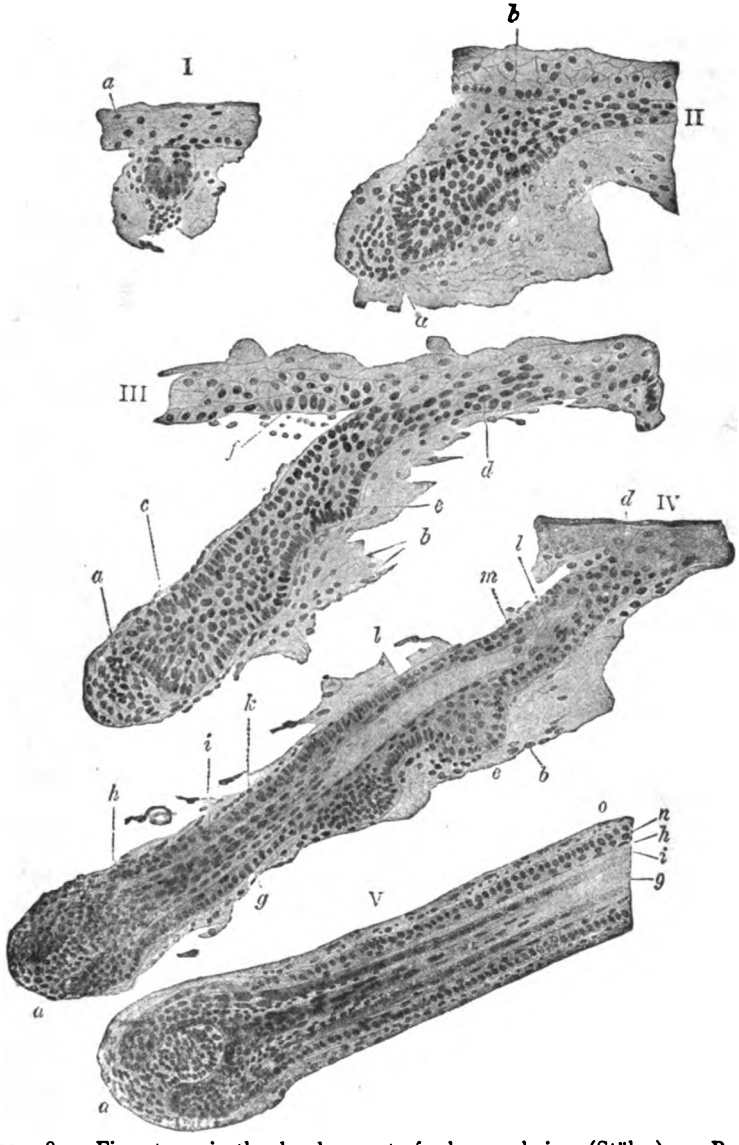

Fig. 283.—Five stages in the development of a human hair. (Stöhr.) *a*, Papilla; *b*, arrector pili muscle; *c*, beginning of hair shaft; *d*, point where hair shaft grows through epidermis; *e*, anlage of sebaceous gland; *f*, hair germ; *g*, hair shaft; *h*, Henle's layer; *i*, Huxley's layer; *k*, cuticle of root sheath; *l*, inner root sheat; *m*, outer root sheath in tangential section; *n*, outer root sheath; *o*, connective-tissue follicle.

an outer, the future stratum corneum, and an inner, the future stratum germinativum. The stratum granulosum and stratum lucidum are special developments of the stratum germinativum. The corium is of mesoblastic origin. It is at first smooth, the papillæ being a secondary development.

The nail first appears as a thickening of the stratum lucidum. This spreads until the future nail bed is completely covered. During development the stratum corneum extends completely over the nail as its eponychium. During the ninth month (intra-uterine) the nail begins to grow forward free from its bed and the eponychium disappears, except as already noted.

The hair also develops from ectoderm. It first appears about the end of the third fœtal month as a small local thickening of the epidermis. This thickening is due mainly to proliferation of the cells of the stratum mucosum, and soon pushes its way down into the underlying corium, forming a long slender cord of cells—the hair germ. Differentiation of the surrounding connective tissue of the corium forms the follicle wall, while an invagination of this connective tissue into the lower end of the hair germ forms the papilla. The cells of the hair germ now differentiate into two layers: a central core the middle portion of which forms the hair, while the peripheral portion forms the inner root sheath; and an outer layer which becomes the outer root sheath. The sublayers are formed from these by subsequent differentiation. The hair when first formed lies wholly beneath the surface of the skin. As the hair reaches the surface its pointed extremity pierces the surface epithelium to become the hair shaft (Fig. 283).

The sebaceous gland develops as an outgrowth from the outer root sheath. This is a flask-shaped and at first solid mass of cells, which later differentiate to form the ducts and alveoli of the gland.

The sweat glands first appear as solid ingrowths of the stratum germinativum into the underlying corium. The lower end of the ingrowth becomes thickened and convoluted to form the coiled portion of the gland, and somewhat later the central portion becomes channelled out to form the lumen. The muscle tissue of the sweat glands, which lies between the epithelium and the basement membrane, is the only muscle of the body derived from the ectoderm.

The Mammary Gland

The mammary gland is a compound alveolar gland. It consists of from fifteen to twenty lobes, each of which is subdivided into lobules. The gland is surrounded by a layer of connective tissue containing more or less fat. From this periglandular connective tissue broad septa extend into the gland, separating the lobes (interlobar septa). From the latter finer connective-tissue bands pass in between the lobules (interlobular septa). From the interlobular septa strands of connective tissue extend into the lobule where they act as support for the glandular structures proper. An excretory duct passes to each lobe where it divides into a number of smaller ducts

(lobular ducts), one of which runs to each lobule. Within the latter the lobular duct breaks up into a number of terminal ducts, which in turn open into groups of alveoli. The fifteen to twenty main excretory ducts pass through the nipple and open on its surface. At the base of the nipple each main duct presents a sac-like dilatation, the *ampulla*, which appears to act as a reservoir for the storage of the milk.

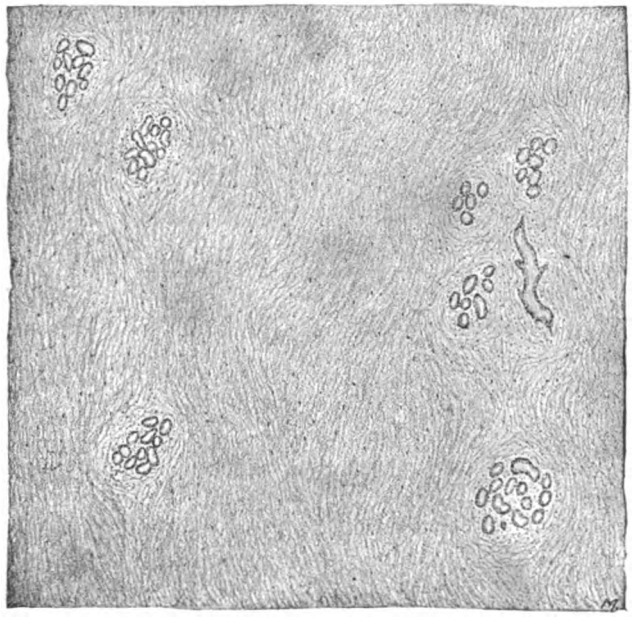

FIG. 284.—From Section of Human Inactive Mammary Gland. ×25. (Technic 1, p. 407.) Gland composed almost wholly of connective tissue; few scattered groups of tubules.

Until puberty the gland continues to develop alike in both sexes, but after about the twelfth year the male gland undergoes retrogressive changes, while the female gland continues its development.

THE INACTIVE MAMMARY GLAND, by which is meant the female gland up to the advent of the first pregnancy and between periods of lactation, consists mainly of connective tissue and a few scattered groups of excretory ducts (Fig. 284). Around the ends of some of the ducts are small groups of collapsed alveoli. Both ducts and alveoli are lined with a low columnar, often rather flat epithelium. In some cases the flat cells are two or three layers thick, forming a thin stratified squamous epithelium. The relative amount of fat and

connective tissue varies greatly, some inactive mammæ consisting almost wholly of fat tissue.

THE ACTIVE MAMMARY GLAND.—Throughout pregnancy the gland undergoes extensive developmental changes and becomes functional at about the time of birth of the child. The microscopic appearance of the active gland differs greatly from that of the inactive (Fig. 285). There is a marked reduction in the connective tissue of the gland, its place being taken by newly developed ducts and alveoli. The alveoli are spheroidal, oval, or irregular in shape, and vary con-

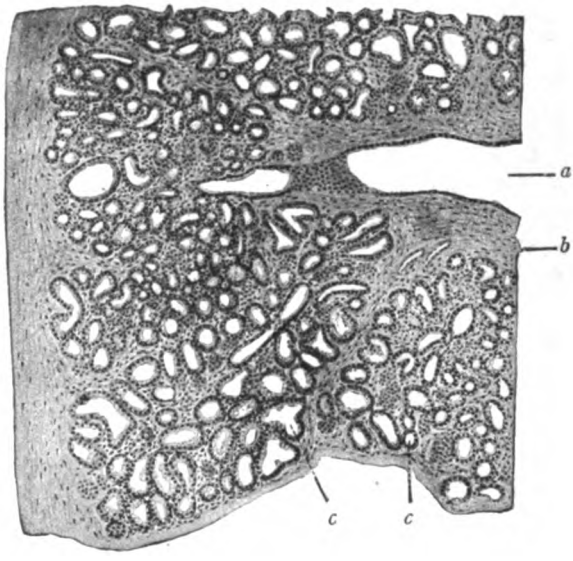

FIG. 285.—From Section of Human Mammary Gland during Lactation. ×50. (Stöhr.) *a*, Branch of excretory duct; *b*, interlobular connective tissue; *c*, alveoli.

siderably in size. The alveoli are lined by a single layer of low columnar or cuboidal epithelial cells which rest upon a homogeneous basement membrane. The appearance of the cells differs according to their secretory conditions. The resting cell is cuboidal and its protoplasm granular. With the onset of secretion the cell elongates, and a number of minute fat droplets appear. These unite to form one or two large globules of fat in the free end of the cell. The fat is next discharged into the lumen of the alveolus, and regeneration of the cell takes place from the unchanged basal portion (Fig. 287). As to the number of times a cell is able to go through this process of secretion and repair before it must be replaced by a new cell,

nothing definite is known. Active secretion does not as a rule take place in all the alveoli of a lobule at the same time. Each lobule thus contains both active and inactive alveoli. The smallest ducts are lined with a low columnar or cuboidal epithelium. This increases in height with increase in the diameter of the duct until in the largest ducts the epithelium is of the high columnar type.

The secretion of the gland is milk. This consists microscopically of a clear fluid or plasma in which are suspended the milk

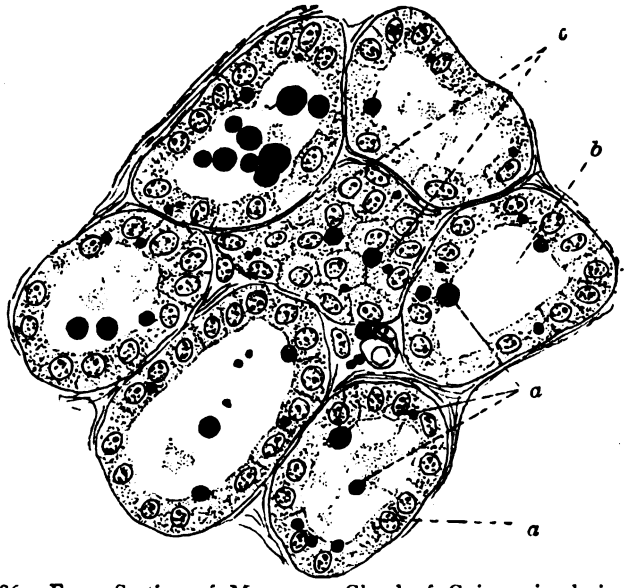

FIG. 286.—From Section of Mammary Gland of Guinea-pig during Lactation. ×500. (Osmic acid.) (Szymonowicz.) *a*, Basement membrane; *b*, lumen of alveolus; *c*, tangential section of alveolus; *d*, fat globules.

globules. The latter are droplets of fat from 3 to 5μ in diameter, each enclosed in a thin albuminous membrane which prevents the droplets from coalescing. Cells, probably leucocytes, containing fat droplets may also be present. In the secretion of the gland during the later months of pregnancy, and also for a few days following the birth of the child, a relatively large number of large fat-containing leucocytes—*colostrum corpuscles*—are found.

Blood-vessels.—These enter the gland, branch and ramify in the interlobar and interlobular connective tissue, and finally terminate in capillary networks among the alveoli and ducts. From the capillaries arise veins which accompany the arteries.

Lymphatics.—Lymph capillaries form networks among the alveoli and terminal ducts. The lymph capillaries empty into larger lymphatics in the connective tissue. These in turn communicate with several lymph vessels which convey the lymph to the axillary glands.

Nerves.—Both cerebro-spinal and sympathetic nerves supply the gland, the larger trunks following the interlobar and interlobula

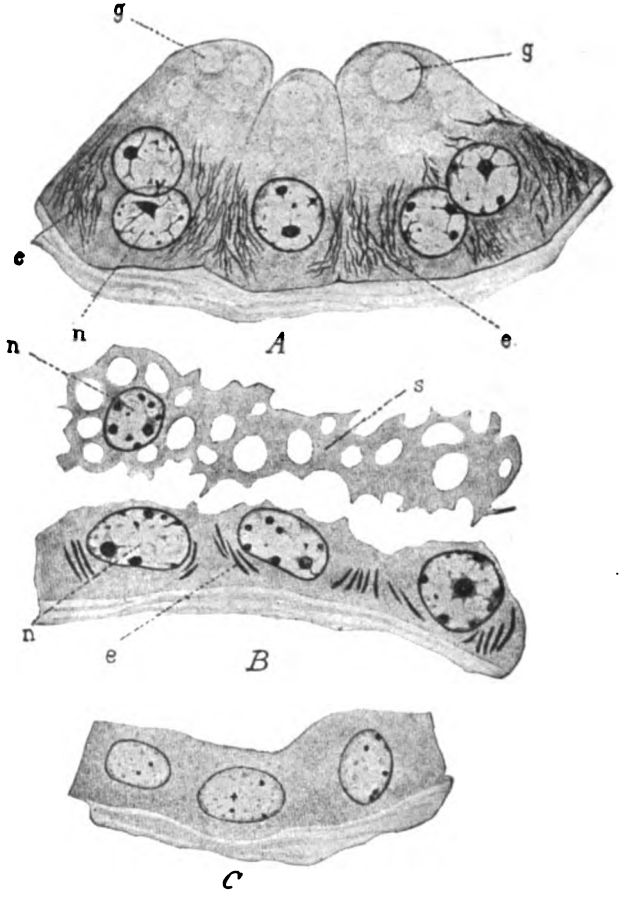

FIG. 287.—*A*, Mammary gland cells—secreting stage; *B*, same—excreting stage; the secretion having separated from the cells; *C*, resting stage; *n* = nucleus. *e* = ergastoplasm filaments. *g* = droplets of secretion. (Simon.)

connective-tissue septa. The nerve terminals break up into plexuse which surround the alveoli just outside their basement membranes. From these plexuses delicate fibrils have been described passing through the basement membrane and ending between the secreting cells.

DEVELOPMENT.—The development of the mammary gland is quite similar to the development of the sebaceous glands. The gland first appears as a dipping down of solid cord-like masses of cells from the stratum mucosum. The alveoli remain rudimentary until the advent of pregnancy. After lactation the alveoli atrophy, being replaced by connective tissue, and the gland returns to the resting state. After the menopause a permanent atrophy of the gland begins, fat and connective tissue ultimately almost wholly replacing the glandular elements.

TECHNIC

(1) Fix thin slices of an inactive mammary gland in formalin-Müller's fluid (technic 6, p. 7). Stain sections with hæmatoxylin-eosin (technic 1, p. 23), and mount in balsam.

(2) Prepare sections of an active mammary gland, as in preceding technic (1).

(3) Fix very thin small pieces of an active gland in one per cent. aqueous solution of osmic acid. After twenty-four hours wash in water and harden in graded alcohols. Thin sections may be mounted unstained, or after slight eosin stain, in glycerin.

General References for Further Study

Kölliker: Handbuch der Gewebelehre des Menschen.

McMurrick: Development of the Human body.

Ranvier: Traité Technique d'Histologie.

Schäfer: Essentials of Histology.

Spalteholz: Die Vertheilung der Blutgefässe in der Haut. Arch. Anat. u. Phys., Anat. Abth., 1893.

CHAPTER XXI

THE THYREOID AND PARATHYREOID, THE HYPOPHYSIS CEREBRI, THE EPIPHYSIS CEREBRI, THE PARAGANGLIA AND THE ADRENAL.

The Thyreoid

The thyreoid (Fig. 288) is a ductless structure built upon the general principle of a compound alveolar gland. There are usually two lateral lobes connected by a narrow band of glandular tissue, the "isthmus." Each lobe is surrounded by a connective-tissue capsule, from which septa pass into the lobe, subdividing it into

FIG. 288.—Section of Human Thyreoid. Most of the alveoli contain colloid.

lobules. From the perilobular connective tissue finer strands extend into the lobules, separating the alveoli. The latter are spherical, oval, or irregular in shape. They vary greatly in diameter (40 to 120μ) and are as a rule non-communicating. At birth most of the alveoli are empty, but soon become more or less filled with a peculiar substance known as "colloid." The alveoli are lined with a single

or double layer of cuboidal epithelial cells. Two types of cells are recognized.

One of these is actively secreting colloid and is known as a *secreting* or *colloid* cell. The other contains no colloid and is known as a *resting* or *reserve* cell. It is probable that their names indicate the relation of these cells to each other and that the reserve cell ultimately becomes a colloid-secreting cell.

The colloid cell appears in some cases simply to pour out its colloid secretion into the lumen, after which it may assume the character of a resting cell; in other cases the cell appears to be completely transformed into colloid, its place being taken by proliferation of the resting cells. In certain alveoli which are much distended with colloid the lining epithelium is flattened.

That the thyreoid exerts a decided influence upon general body metabolism is shown by the symptoms resulting from congenital absence of the gland (congenital myxœdema or cretinism) and by the effects of complete removal, the latter giving rise to a train of symptoms known as the "cachexia strumipriva."

The **blood supply** of the thyreoid is extremely rich, the vessels branching and anastomosing in the connective tissue and forming dense capillary networks around the alveoli.

Lymphatics accompany the blood-vessels in the connective tissue.

Nerves are mainly non-medullated fibres which form plexuses around the blood-vessels and in the connective tissue surrounding the alveoli. Terminals to the secreting cells end in club-like dilatations against the bases of, or between the epithelial cells. A few afferent medullated fibres are found in the plexuses surrounding the blood-vessels.

DEVELOPMENT.—The thyreoid originates as a diverticulum from the entoderm of the primitive pharynx. It first appears in embryos of 3 to 5 mm. and grows ventrally into the mesoderm of the ventral wall of the neck. Here it forms a mass which lies transversely across the neck. It is composed of solid cords of cells which become hollow to form the alveoli of the gland. At first the gland is connected with the surface by the thyreo-glossal duct. This either disappears entirely or is represented in the adult by such rudimentary structures as the so-called prehyoid, suprahyoid, and accessory thyreoid glands. Ingrowths of connective tissue divide the solid cords of cells of which the gland at this stage consists into groups or lobules, and at the same time break up the long cords into short segments. Dilatation of the alveoli occurs with the formation of colloid.

The Parathyreoids

These are small ductless glands which usually lie upon the posterior surface of the lateral lobes of the thyreoid. There are commonly two pairs, a superior and an inferior, on each side. The number is, however, subject to variation. Each gland is from 6 to 8 mm. long, about half that in breadth, and 2 mm. thick. Small groups of cells having the structure of the parathyreoids have been found below the thyreoid and within the thyreoid and thymus.

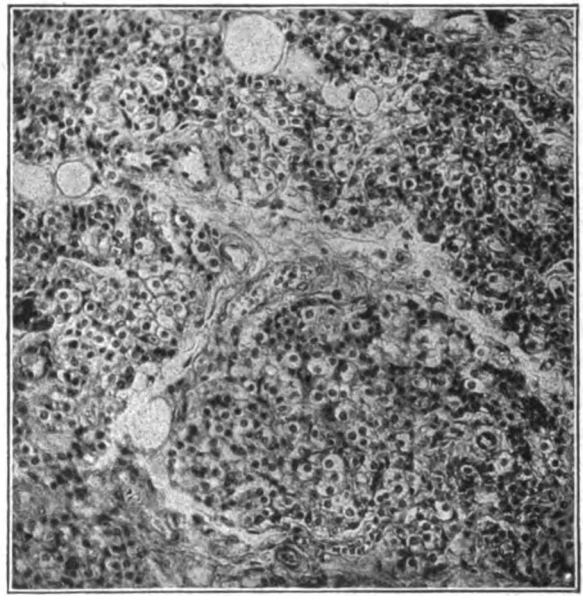

FIG. 289.—Section of Human Parathyreoid; showing mainly "clear," "principal," or "chief" cells. (Pool.)

The parathyreoid is surrounded by a thin connective-tissue capsule which sends a variable amount of connective tissue into the gland as septa. When the amount is considerable the gland shows a subdivision into lobules. The stroma consists largely of reticular tissue and is very vascular. The number and arrangement of the cells vary. The gland may be almost wholly cellular with very little connective tissue, the groups of cells may be widely separated by interstitial tissue, or there may be any intermediate condition. The cells are arranged in irregular groups or cords (Figs. 289, 290) sometimes around tubules, sometimes having a distinctly alveolar structure (Fig.

291); in the latter case colloid may be present in the lumen. Colloid has also been found between, and colloid and glycogen within, the cells.

The cells themselves are spheroidal, cuboidal or pyramidal, with basal nuclei. The appearance of the cells varies sufficiently to have caused two or three types to be distinguished. All, however, probably represent different functional conditions of the same cell. (1) *Chief* or *clear cells* (Fig. 289). These are the more numerous. Their bodies are small and clear, and the cytoplasm does not stain readily. The nuclei

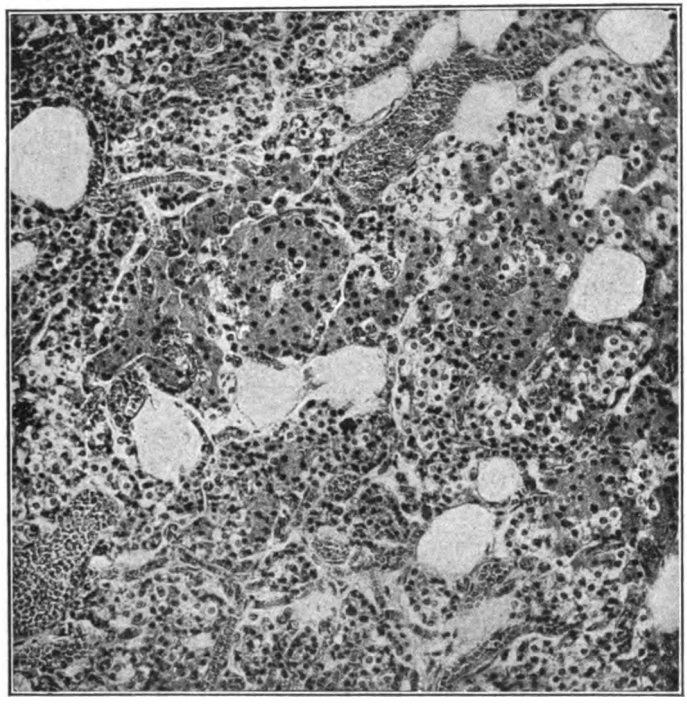

FIG. 290.—Section of Human Parathyreoid showing groups of oxyphile cells. (Pool.)

are large in proportion to the cell and are clear and vesicular with loosely arranged pale chromatin network. (2) *Oxyphile cells* (Fig. 290). These are larger, their cytoplasm is more granular and takes a strong eosin stain. The nucleus is small, its chromatin network closely arranged and takes a dark stain. Compact groups of these cells occur especially just beneath the capsule. They are also found throughout the gland, arranged as cords, as single cells, or as small groups among the clear cells. Intermediate types have been de-

scribed. It is probable that the clear cells represent the resting, the granular cells the active secreting condition of the same cell.

The parathyreoids originate as epithelial evaginations from the third and fourth branchial grooves, and develop wholly independently of the thyreoid.

The powerful influence which these minute organs exert is shown both clinically and experimentally. Fatal tetany, resulting from the earlier operations for complete removal of the thyreoids, has been shown by animal experimentation to be due not to the removal of the thyreoids, but to coincident removal of the parathyreoids, the removal of the latter only, in animals, giving the same results.[1]

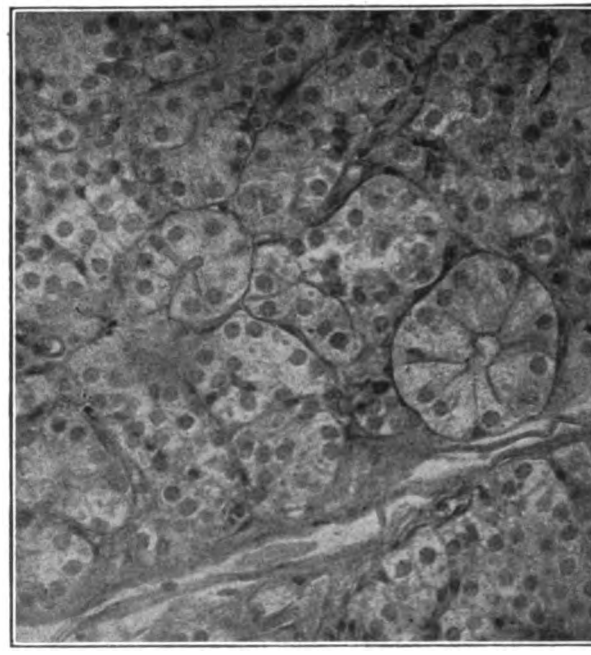

FIG. 291.—Section of Human Parathyreoid, showing lumina indicating tubular or tubulo-alveolar structure. (Pool.)

TECHNIC

The thyreoid and parathyreoid glands are best fixed in formalin-Müller's fluid. Sections may be stained with hæmatoxylin-eosin or hæmatoxylin-picro-acid-fuchsin and mounted in balsam.

General Reference for Further Study

Pool: Tetany Parathyreopriva. Annals of Surgery, October, 1907.

[1] For much of the description of the parathyreoids and for the photograph the writer is indebted to Dr. Eugene H. Pool.

THE HYPOPHYSIS CEREBRI

(Pituitary Body)

The Hypophysis Cerebri is a neuro-glandular organ, its glandular portion being of the ductless, endocrin, or internal secretion type.

The hypophysis develops in accord with its neuro-glandular character as two evaginations, one of oral ectoderm from the primitive buccal cavity, the other of neural ectoderm from the third ventricle. These two unite to form the hypophysis. The remains of the neural connection persist in the infundibulum, the buccal connection disappears In the human embryo of 20 mm. the hypophysis is present as two definite lobes in approximately their adult position.

The hypophysis is usually described as composed of two main lobes, which are totally different in structure, origin and probably in function. They are separated by a cleft, the *inter-glandular cleft*, (residual lumen or ventricle of the hypophysis). A narrow strip of the posterior lobe bordering the cleft, presents a structure different from other parts of the gland. This has been designated the *intermediate portion* or *pars intermedia* (Fig. 292).

The very thorough work of Frederick Tilney upon the hypophysis in various species, has greatly clarified our knowledge of its development and structure and forms the basis of the following description. Tilney calls attention to the inadequacy of the foregoing subdivision of the gland and its inconvenience in comparative anatomy, and suggests a more accurate analysis based upon its development and structure. He divides the gland into two main lobes or parts, a (1) *pars neuralis* and (2) *pars buccalis* or *glandularis*, their names signifying their respective developmental origins. The pars neuralis is subdivided into three parts, (a) the *eminentia saccularis* of the *tuber cinereum*, (b) the *infundibulum*, and (c) the *infundibular process*. The pars buccalis or pars glandularis is divided into a *pars juxta-neuralis* and a *pars distalis*. The juxta-neural portion is further divided into a *pars infundibularis* which completely surround the infundibulum and infundibular process, and a *pars tuberalis* which surrounds the eminentia saccularis of the tuber cinereum. This analysis is tabulated as follows:—

I. Pars Neuralis:
   1. Eminentia Saccularis
   2. Infundibulum
   3. Processus infundibuli.

II. Pars Buccalis or Glandularis:
   1. Pars juxta-neuralis.
      (*a*) Pars tuberalis.
      (*b*) Pars infundibularis.
   2. Pars distalis.

Comparing this with the older nomenclature, the pars distalis equals the anterior lobe, the pars neuralis equals the posterior lobe, the pars juxta-neuralis equals the intermediate portion.

I. Pars Neuralis (Posterior Lobe).—This is surrounded by a connective tissue capsule from which trabeculæ pass into the substance of the lobe to form its connective tissue frame work. In the human adult, the pars neuralis contains many fusiform and stellate cells resembling neuroglia cells, and fibres resembling neuroglia fibres. Some cells may contain pigment granules, especially in the aged. Small or rudimentary ganglion cells and a few nerve fibres have been described. In some lower forms and in the human embryo the nervous elements have been described as much more prominent and more definitely arranged. Thus Berkley describes the posterior lobe of the hypophysis of the dog as consisting of three distinct zones: (1) An outer zone of three or four layers of cells resembling ependymal cells, connective-tissue septa from the capsule separating the cells into irregular groups. (2) A middle zone of glandular epithelium, some of the cells of which are arranged as rather indefinite alveoli which may contain colloid. This is termed the pars intermedia. (3) An inner layer of nerve cells and neuroglia cells. These react to the Golgi stain, the nerve cells having axones and dendrites. Most of the axones appeared to pass in the direction of the infundibulum, but could not be traced into the latter.

II. Pars Buccalis or Glandularis.—The cellular elements of the glandular portion of the hypophysis have been usually classified as chromophiles and chromophobes. This classification is based upon the relative stainability of the cells. To these terms Tilney raises the objections that in his comparative studies of many species he found no chromophobes until the higher Sauropsida were reached,

and that the two types very likely represent different functional conditions of the same cell. He suggests their differential stainability as a more accurate basis of classification, and divides them with reference to their stainability by acid and basic stains into a *acidophiles* and *basophiles*. These two types were found in all species examined and there was a marked segregation, the two types tending to keep themselves separate.

In each type, two varieties are distinguished. Of the acidophiles, some are large cells, which take a deep stain and are comparatively

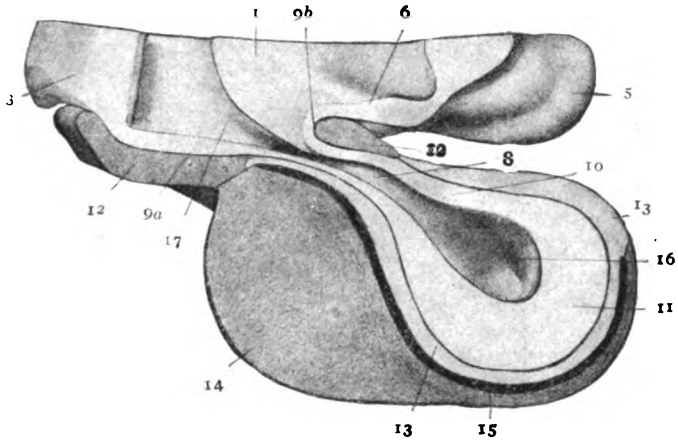

FIG. 292.—Reconstruction showing the relation of the hypophysis in the adult cat to the diencephalen (sagittal view). (Tilney.) 1 Third ventricle; 3, optic chiasma; 5, corpora mammillaris; 8, recessus infundibuli; 9, eminentia saccularis; 9a, ventrocephalic surface of eminentia saccularis; 9b, caudal surface of eminentia saccularis; 10, infundibulum; 11, processus infundibuli; 12, pars tuberalis; 13, pars infundibularis; 14, pars distalis; 15, lumen residuale; 16, recessus processi infundibuli; 17, recessus tuberis.

few in number, others are small, more lightly staining cells, with little cytoplasm. In like manner two types of basophiles are found: large cells of polygonal or columnar shape with small nuclei and considerable deeply staining cytoplasm, and medium-sized cells with large granular nuclei and comparatively little lightly staining cytoplasm.

The Pars Distalis, or Anterior Lobe, constitutes the main bulk of the glandular portion of the hypophysis. It is surrounded by a strong fibrous connective tissue capsule continuous with that of the neural portion. From the capsule rather delicate septa pass into

the substance of the gland where they subdivide to form its connective tissue framework.

The cells are grouped in three well-defined areas. A large central area which extends to the periphery anteriorly, is composed of large deeply staining basophiles arranged in apparent acini against a background of faintly staining basophiles. Dorso-superiorly and laterally is a large triangular area composed almost exclusively of acidophiles, the deeply staining cells being arranged in cords against a back ground of faintly staining cells. A few basophiles are present. A thin superficial layer of faintly staining basophiles covers the gland.

The Pars Juxta-neuralis is composed wholly of basophiles. In the pars tuberalis of the dog (Fig. 292*A*) there is a very evident ar-

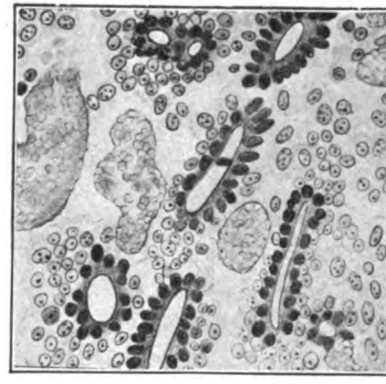

FIG. 292*A*.—Section through Pars Tuberalis of Hypophysis of Dog. (Tilney.)

rangement of large deeply staining cuboidal cells around widely open acini. These lie in a back ground of faintly staining cells. In the pars infundibularis basophiles alone are present. These are mainly of the small faintly staining type and diffusely arranged. There are usually a few small acini (Fig. 292*B*).

Colloid, or a substance resembling colloid occurs in the acini of the hypophysis and in the residual lumen. Sometimes large masses of colloid distend the lumen and cyst-like evaginations from the lumen. The origin of the colloid is not known.

The hypophysial secretion, its function, and its relation to the

various kinds of cells have been subjects of much controversy. According to some investigators each type of cell contributes its own special secretion to the general secretion of the gland. According to others the different types of cells represent merely different stages in the elaboration of the secretion. Some consider the colloid a special secretion, others derive it from the cell granules and consider it as possibly representing a final stage, or "normal degenerative condition of the secretion." Tilney calls attention to the quite uniform distribution of the two types of cells with reference to their possible functions. Thus the juxta-neural epithelial part is always basophile, also the anterior wall of the residual lumen when present, also some peripheral and central areas of the pars distalis. The

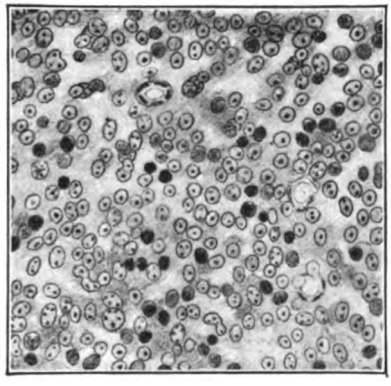

FIG. 292*B*.—Section through Pars Infundibularis of Hypophysis of Dog. (Tilney.)

basophiles thus tend to come into close relation with the residual lumen, while basophile areas are notably poor in vascularity. This is especially noticeable in certain lower forms and suggests the possibility that the secretion of these cells passes into the cerebrospinal fluid. The acidophile areas, on the other hand, are always extremely vascular, and the cells are always in very intimate relation with capillaries and large blood spaces, as is usual with the cells of endocrin glands where the secretion passes directly into the blood stream.

Pregnancy apparently induces increased activity of the gland. This is of interest in connection with the clinical use of the extract

of pituitary body for the purpose of inducing contractions in an atonic uterus during parturition or for the control of post-partum bleeding. Pathological conditions of the pitutiary, more particularly tumors or hyperplasia of the anterior lobe, are apparently associated with a clinical condition known as acromegaly in which there is marked connective-tissue hypertrophy, especially of certain bones. The connection between acromegaly and lesions of the pituitary body would seem to be somewhat similar to that between myxœdema and lesions of the thyreoid. Removal of the thyreoid

FIG. 292*C*.—Section through Pars Distalis of Hypophysis of Cat. (Tilney.)

results in enlargement of the pituitary body, especially in increase of colloid. Increase of colloid has also been reported after removal of the pancreas.

Blood Supply.—This comes from a number of small arteries which are branches of the circle of Willis. They pass to the under surface of the gland and give rise within the gland to a rich plexus of capillaries, sinusoidal vessels and blood spaces.

Nerves.—These are probably derived from the carotid plexus of the sympathetic.

The Epiphysis Cerebri.

The epiphysis cerebri or pineal body is a small conical structure about 7 mm. long and 5 mm. broad attached by means of the *pineal*

stalk to the roof of the third ventricle, and resting upon the anterior corpora quadrigemina. It first appears about the fifth embryonic week as a protrusion from the caudal end of the median ridge of the diencephalon. The epiphysis has long been considered a rudimentary or vestigial structure, the homologue of the third or median reptilian eye. Recent investigations however, tend to the classification of the epiphysis as an endocrin gland having a definite though unknown function, and producing a secretion which passes directly into the blood stream and is of functional importance.

It is surrounded by a firm connective tissue capsule which is an extension of the pia mater and which sends trabeculæ into the organ. These divide it into indefinite and irregular lobules. The parenchyma is usually described as composed of two types of cells, neuroglia cells and inter-neuroglia or gland cells. Tilney, in a very complete analysis of the epiphysis, expresses doubt as to the presence of true neuroglia cells, considers the epiphysis in man as a distinctly glandular organ, and describes four types of parenchyma cells: (1) large cells with much cytoplasm and large vesicular deeply staining nuclei; (2) similar cells with pale nuclei; (3) small cells with little cytoplasm composed almost wholly of large deeply basophile nuclei; (4) small granular cells with faintly staining nuclei. The large cells with deeply staining nuclei (type 1) are the most prominent elements of the gland. They are arranged in somewhat regular masses which however run into each other. These masses lie in a background composed of the other types of cells. The entire gland is extremely vascular being pervaded by a rich capillary network. Scattered through the gland are often found calcareous deposits known as "brain sand."

The Paraganglia

Under the head of Paraganglia are grouped certain small ductless glands and small groups of cells which are closely associated both anatomically and embryologically with the sympathetic system. They include the *carotid*, the *coccygeal*, and *tympanic glands*, the *parasympathetic organ of Zuckerkandl*, and the *medulla* of the *adrenals*. The most marked characteristic of these organs aside from their

close relation to the sympathetic, is that their cells take a yellowish brown stain when placed in solutions of chromic acid or chrome salts, retaining the color even after prolonged washing in water. For this reason the cells are sometimes referred to as *chromaffin cells* and the organs as *chromaffin organs.*[1]

While each organ has its own peculiar structure, all agree in certain general features. (1) The cells are polyhedral and have a general arrangement into cord-like structures rather than into lobules; (2) they are all ductless glands· (3) the cells lie in very close relation

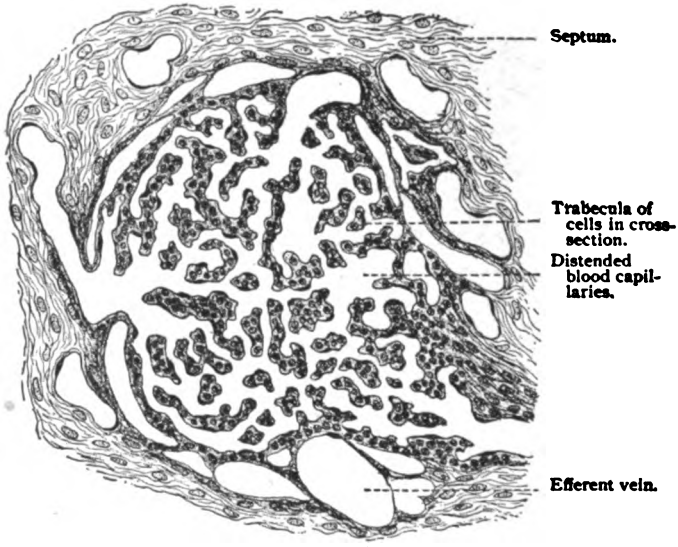

FIG. 293.—Section of human carotid gland. × 160. (Schaper.)

to rich capillary networks of large vessels, some of which resemble sinusoids and have been described as having incomplete walls, the gland cells thus being in direct contact with the blood stream; (4) unstained the cells show a clear, highly refractive cytoplasm, but contain secretion granules which stain yellowish brown with chromic acid and chrome salts, red with safranine, and black with osmic acid; (5) all, as far as has been determined, produce an internal secretion which passes directly into the blood and which acts as a regulator of vascular tone.

The Carotid Glands.—These are two small ductless glands, each about the size of a rice grain, which lie one on either side of the

[1] Cells containing chromaffin granules have also been described as occurring in sympathetic ganglia, and by Rose as present in many different organs, *e.g.*, the ovary, testicle, blood-vessel walls, etc.

bifurcation of the carotid artery. They are composed of a vascular connective tissue supporting spheroidal groups of large polyhedral epithelial cells with poorly marked boundaries and closely associated with tufts of capillaries. These capillaries are of large diameter and thin walled, and have been described as sinusoidal in character. The amount of connective tissue and the blood-vessels increase with age at the expense of the epithelial elements. This probably led to

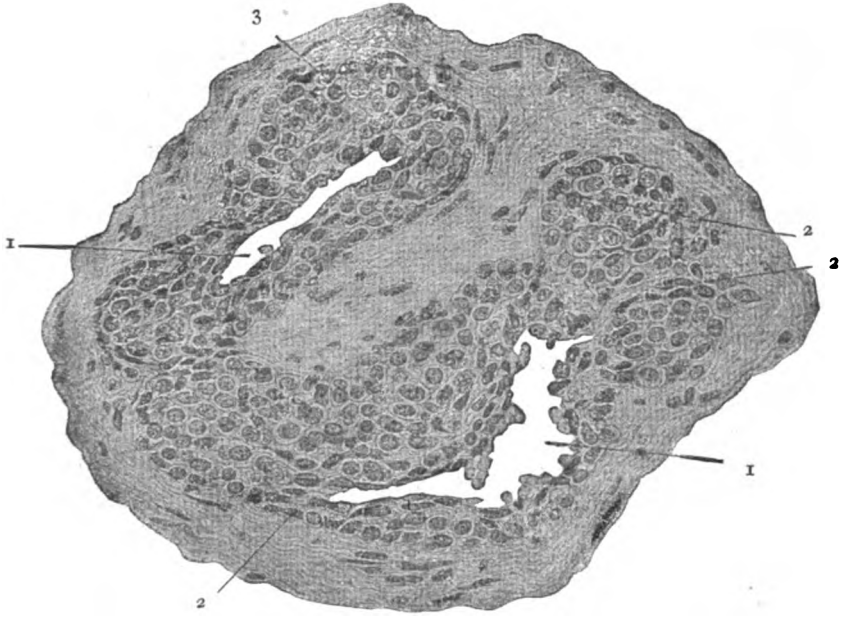

FIG. 294.—Section through coccygeal gland. (Walker.) 1. Blood space; 2. epithelium; 3. connective tissue.

the earlier description of the gland as a vascular or glomerular structure. The gland cells themselves contain chromaffin granules (p. 416) and secrete a blood-pressure-raising substance apparently identical with, or similar in nature to, the secretion of the adrenal (p. 418).

The Coccygeal Gland.—This is a small ductless gland which lies just in front of the apex of the coccyx. It is similar in structure to the preceding but has its cell groups more irregularly arranged (Fig. 294). There is the same general arrangement of gland cells, the same relation of gland cells to the connective-tissue framework and to large sinusoidal blood-vessels, the same vascular and con-

nective tissue changes with age, the same reaction of its cells to chrome salts, and the same or a similar secretion.

The tympanic gland and the organ of Zuckerkandl are small collections of chromaffin cells, the former lying on Jacobson's nerve in the tympanic canal, the latter lying in the retroperitoneal tissue at about the level of the bifurcation of the abdominal aorta.

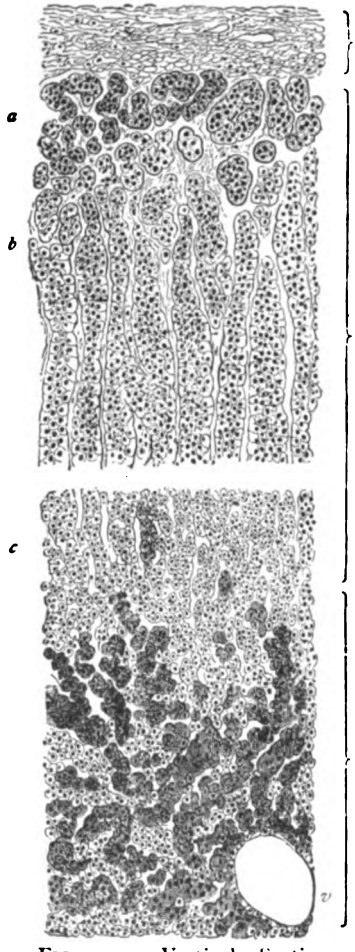

FIG. 295.—Vertical Section of Adrenal. (Merkel-Henle.) *A*, Capsule; *B*, cortex; *C*, medulla; *a*, glomerular zone; *b*, fascicular zone; *c*, reticular zone; *v*, vein in medulla.

The Adrenal

The adrenal is a ductless gland situated on the upper and anterior surface of the kidney. It is surrounded by a *capsule* and consists of an outer zone or *cortex* and a central portion or *medulla*. The cortex and medulla are sharply differentiated both in general appearance and in histological structure. The former is of rather firm consistency, its cells are arranged in rows with the blood-vessels between them, giving the zone a striated appearance. Its cells contain fat droplets and peculiar granules known as *lipoid granules* which give the cortex a yellowish tint. In contrast the medulla is soft, vascular, has a dark reddish appearance, and its cells contain granules known as *chromaffin* or *phæochrome granules*.

The CAPSULE (Fig. 295, *A*) is composed of fibrous connective tissue and smooth muscle. In the outer part of the capsule the connective tissue is loosely arranged and merges with the surrounding fatty areolar tissue. The inner layer of the capsule is more dense and forms a firm investment for the underlying glandular tissue. From the capsule trabeculæ extend into the organ forming its framework and outlining compartments,

which contain the glandular epithelium. This connective tissue is reticular in character.

The CORTEX (Fig 295, *B*) is subdivided into three layers or zones: (*a*) A narrow, superficial layer, the *glomerular zone;* (*b*) a broad middle layer, the *fascicular zone;* and (*c*) a narrow deep layer, the *reticular zone.* The names of the layers are indicative of the shape of the connective-tissue-enclosed compartments and of the contained groups of gland cells. In the glomerular zone (Fig. 295, *a*) the high, irregularly columnar epithelium is arranged in spherical or oval groups. The protoplasm of the cells is granular, contains fat droplets, and their nuclei are rich in chromatin. In the fascicular zone (Fig. 295, *b*) polyhedral cells are arranged in long columns or fascicles. The cytoplasm is granular and usually contains many large fat droplets. The nuclei contains less chromatin than those in the glomerular zone. The appearance which the protoplasm of the cells richest in fat presents has led to their being called "spongioblasts." In the reticular zone (Fig. 295, *c*) similar though somewhat more darkly staining cells, containing small fat droplets or sometimes no fat droplets, form a coarse reticulum of irregular anastomosing cords.

This division of the cortex into zones is more distinct in some of the lower animals. It does not indicate any fundamental structural or functional differences. The cells in the different zones show only minor variations in structure, the characteristic appearance of the zone depending upon the arrangement of the cells and the shape of the connective-tissue compartments. According to Gottschau the glomerular zone is the zone in which active formation of new cells takes place, these cells gradually passing toward the medulla, according to some, finally completing their history as medullary cells. Others terminate the life history of these cells with the deepest layer of the cortex. The pigment formation in the cells of the reticular zone is considered by some a degenerative, by others a secretory process. Still other investigators look upon the deeper cortical layers as the site of most active cell proliferation and an indifferent cell here situated as giving rise on the one hand to pigment cells and on the other to fat-producing cells. If the deeper cells are the older, the deeper zone would contain the more mature and probably the more functionally active cells, and it is here that are found cells crowded with fat droplets or with pigment granules. The former begin, according to some investigators, in the superficial cell as droplets of ordinary fat, which becomes changed into *lecithin*—an easily broken-down, acid, phosphorus-containing fat with which many of the cells of the deeper layers are filled. As already noted, this pigment is regarded by some as the last stage in fat formation, by others as an entirely independent secretion. This interrelation of cortical and medullary cells is not, however, in accord with the findings of embryology or of comparative anatomy (p. 421).

The MEDULLA (Fig. 295, *C*) consists of spherical and oval groups and cords of polygonal cells. After alcohol or formalin fixation these cells take a paler stain than those of the cortex. After fixation in solutions containing chromic acid or chrome salts the cells of the medulla assume a peculiar characteristic deep brown color, which cannot be removed by washing in water and which is due to chromaffin granules which they contain (p. 416). The chromaffin content varies in different animals and with age. Thus while in the adult human the chromaffin reaction is strong, little or no reaction is present in the fœtal adrenal. The secretion of the medullary part of the adrenal is known as *adrenalin*, apparently the mature condition of the intra-cellular chromaffin granules. As already noted (p. 417) it is probably an active agent in the regulation of arterial tension.

Scattered in irregular groups among the chromaffin cells are many sympathetic ganglion cells.

Blood-vessels.—The arteries supplying the adrenal first form a poorly defined plexus in the capsule. From this are given off three sets of vessels—one to the capsule, one to the cortex, and one to the medulla. The first set breaks up into a network of capillaries, which supply the capsule. The vessels to the cortex break up into capillary networks, the shape of the mesh corresponding to the arrangement of the connective tissue in the different zones. The vessels to the medulla pass directly through the cortex without branching and form dense capillary networks among the groups of medullary cells. The relations of the capillaries to these glands cells are extremely intimate, especially in the reticular zone and medulla, where the cells in many cases immediately surround the capillaries in much the same manner as the glandular cells of a tubular gland surround their lumina. From the capillaries of both cortex and medulla small veins arise. These unite to form larger veins which empty into one or two main veins situated in the center of the medulla.

Lymphatics.—These follow in general the course of the blood-vessels. The exact distribution of the adrenal lymph system has not been as yet satisfactorily determined.

Nerves.—The nerve supply of the adrenal is so rich and the nerve elements of the gland are so abundant as to have led to its classification by some among the organs of the nervous system. Both medullated and non-medullated fibres—but chiefly the latter—form plexuses in the capsule, where they are associated with groups

of sympathetic ganglion cells. From the capsular plexuses fine fibres pass into the cortex, where they form networks around the groups of cortical cells. The nerve terminals of the cortex apparently do not penetrate the groups of cells. Bundles of nerve fibres, larger and more numerous than those to the cortex, pass through the cortex to the medulla. Here they form unusually dense plexuses of fibres, which not only surround the groups of cells, but penetrate the groups and surround the individual cells. Associated with the plexuses of the medulla, less commonly of the cortex, are numerous conspicuous groups of sympathetic ganglion cells.

DEVELOPMENT.—The cortex and medulla have entirely different developmental histories. In the lower vertebrates (fishes) the two parts of the gland continue separate throughout life. In the ascending mammalian scale, the two parts become more and more closely united until in mammals they form a single organ. The cortex develops from mesoderm, first appearing in embryos of about five to six mm. At about the level of the cephalic third of the mesonephros the mesothelium sends outgrowths into the mesenchyme. These outgrowths soon lose their connection with the main mass of mesothelium and constitute the anlage of the adrenal cortex. The medulla has an entirely independent origin, being derived from ectoderm, as part of the peripheral sympathetic nervous system. The cells of some of the sympathetic ganglia differentiate into *sympathoblasts* and *phæochromoblasts*, which give rise to the sympathetic cells and chromaffin cells respectively. These cells soon separate from their ganglia of origin and come to lie first near, then within, the developing cortex, thus forming the medulla.

General References for Further Study

Flint: The Blood-vessels, Angiogenesis, Organogenesis, Reticulum and Histology of the Adrenal. Contributions to the Science of Medicine, Johns Hopkins Press, 1900.

Pfaundler: zur Anatomie der Nebenniere. Anzeiger Akad. Wien, 29, 1892.

Nagel: Ueber die Entwickelung des Urogenitalsystem des Menschen. Arch. f. Mik. Anat., Bd. xxxiv.

Stohr: Lehrbuch der Histologie B. 15th Ed.

Prenant: Traite d'Histologie.

Tilney: Int. Monat Für Anat. *v.* Phys., Bd., 30, 1913–14.

Tilney: Contribution to the Study of the Hypophysis Cerebri with Especial Reference to its Comparative Histology. Mem. No. 2, Wistar Ins. Anat. and Biol., 1912.

Tilney and Warren: The Morphology and Evolutional Significance of the Pineal Body. Amer. Anat. Mem. No. 9, Feb. 1919.

CHAPTER XXII

THE NERVOUS SYSTEM*

By Oliver S. Strong

GENERAL STRUCTURE AND HISTOLOGICAL DEVELOPMENT

The nervous mechanism in man, as in other vertebrates, consists of two principal parts: the *central nervous system*, consisting of the brain (encephalon) and spinal cord (myelon or medulla spinalis) and the *peripheral nervous system* consisting of the cerebral or cranial and spinal nerves (cerebrospinal nerves) and sympathetic system. The peripheral nerves consist essentially of bundles of nerve fibres together with certain groups of nerve-cell bodies (ganglia) and connect the central nervous system with various portions of the body.

The various vital activities of the human body, as of all other living organisms, may be regarded as a series of adjustments which enable the various parts to act harmoniously and also enable the organism to adjust itself to environmental changes. In the more highly organized living forms various kinds of adjustments are performed by the various differentiated tissues and organs. Many of these adjustments of a physico-chemical nature are performed largely through the intermediation of the hæmo-lymphatic vascular system; other adjustments are brought about by changes passing from one part of the body to another along the various conducting elements or neurones which form the nervous system. Those adjustments or reactions of the organism to its environment or of one part of the organism to another which are performed by the intervention of the nervous system may be termed *neural reactions*. The respective parts played in neural reactions by the peripheral and central nervous systems are quite evident from their general structure. The bundles of long nerve fibres constituting the bulk of the peripheral nervous system either transmit stimuli from various parts of the body to the central nervous system or transmit nerve

*For a synopsis see Table of Contents.

impulses from the central nervous system to the various parts of the body whose activities they modify. On the other hand the central nervous system with its complicated interconnecting systems of neurones, adjusts the incoming stimuli to the outgoing impulses, in other words it determines what part or parts of the body shall be affected by the stimuli it receives—it is the adjusting or coördinating part of the nervous mechanism.

Those peripheral nerve fibres which conduct stimuli to the central nervous system are termed *afferent peripheral nerve fibres* ("sensory" fibres). The neurones of which the peripheral afferent nerve fibres are a part are termed *afferent peripheral neurones* (proto-neurones, receptor neurones or elements, "sensory" neurones). Those peripheral nerve fibres which conduct impulses from the central nervous system are termed *efferent peripheral nerve fibres.* The neurones of which the efferent peripheral nerves fibres are a part are termed the *efferent peripheral neurones.* The various structures of the body which first receive stimuli and which usually contain the distal endings of the afferent peripheral nerve fibres are termed *receptors* (sense organs, etc.); those structures in which changes, or effects, are brought about by impulses transmitted to them by the efferent peripheral nerve fibres and which contain the distal endings of the latter are termed *effectors* (muscles and glands). The neurones lying wholly within the central nervous system may be termed the *central* or *intermediate neurones.*[1]

It is evident from the above that a complete neural reaction will pursue the following path: receptor—afferent peripheral neurone —central neurones (central nervous system)—efferent peripheral neurones—effector.

Another important division of the nervous system is the division into the *somatic* nervous system and the *splanchnic* or *visceral* nervous system. In the nervous system a great number of reactions are initiated by external changes and take effect in the voluntary musculature. The larger part of our conscious activities fall under this category. These reactions are performed by the somatic system. On the other hand, other reactions are initiated by internal bodily (visceral) changes and take effect in the involuntary musculature and glands. They are more largely unconscious and are concerned with those functions called "vegetative" *i.e.*, functions connected

[1]The latter would correspond largely to Gaskell's "connector neurones" except the latter include the neurones giving rise to the preganglionic sympathetic fibres which here, by definition, are included in the peripheral neurones.

with nutritional, metabolic, secretory and vascular activities. These reactions are performed by the splanchnic system. The splanchnic reactions which are conscious, dealing as they do with fundamental, imperative bodily needs, are usually of an instinctive and emotional character. The two systems are, however, closely connected, both in the central and peripheral nervous systems. While some neural reactions may be purely somatic or purely splanchnic, many are mixed, *e.g.*, an external stimulus (sight of food, sight of something causing fear etc.) may produce secretory and vasomotor effects (somato-splanchnic reactions) and visceral stimuli (hunger, colic) may produce very energetic voluntary movements (splanchno-somatic reactions).

Peripherally, the splanchnic nervous system is represented by the *sympathetic* (autonomic) nervous system consisting practically of several series of ganglia in head and trunk lying at varying distances from the central nervous system and composed of cells which send their fibres to the visceral effectors. They are connected with the rest of the nervous system by communicating branches consisting of afferent and efferent fibres (p. 448). The remainder of the peripheral nervous system is termed the *cerebrospinal* peripheral system. The two are not, however, entirely separable.

The beginning differentiation of the nervous system appears very early in embryonic life. It is first indicated by a longitudinal median thickening of the outer embryonic layer or ectoderm, to form the *neural plate.* The sides of the plate become elevated to form the *neurals folds,* leaving between them the *neural groove.* By the dorsal union of these folds the neural groove is converted into the *neural tube.* The lumen of the neural tube corresponds to the *central canal* of the cord and the *ventricles* of the brain in the adult, and from the ectodermic cells which form the walls of this tube practically the entire nervous system is developed. In the wall of the neural tube four longitudinal zones or plates can be distinguished: a dorsal median zone or plate, the *roof plate;* a ventral median zone, the *floor plate* and the two side walls or lateral zones. The latter are usually divided into dorso-lateral zones or *alar plates* and ventro-lateral zones or *basal plates.* The median zones do not undergo so much change and are the most conservative portions of the neural tube in vertebrates. It is principally the lateral walls which develop into the massive nervous structures mentioned below. The ventro-lateral or basal plate contains the motor elements, the dorso-lateral or alar plate is receptive and also expands into the suprasegmental structures men-

tioned below. The caudal portion of the tube is of nearly uniform diameter—the *spinal cord.* At the cephalic end, the neural plate, even before its closure, is wider and forms, when closed, an expanded portion of the tube, the *brain.* In their further development, the walls of the brain form three expansions—the three brain "vesicles" known as the *forebrain* (*prosencephalon*), *midbrain* (*mesencephalon*), and *hindbrain* (*rhombencephalon*). In the forebrain two main divisions are usually distinguished, the *endbrain* (*telencephalon*) and the *interbrain* (*diencephalon*). The basal part of the endbrain forms the *corpora striata* and *rhinencephalon*, while the dorso-lateral part expands into the *pallium* (*cerebral hemispheres*). In the interbrain may be distinguished a dorsal part, the *epithalamus;* a middle (largest) part, the *thalamus;* and a ventral expansion, the *hypothalamus.* In the midbrain the basal part becomes the *tegmentum*, and the dorso-lateral part expands into the *corpora quadrigemina* or *inferior* and *superior colliculi.* The narrower part, connecting midbrain and hindbrain, is the *isthmus.* The basal part of the hindbrain forms the *medulla oblongata* and part of the dorso-lateral wall expands into the *cerebellum.* In the later development of the brain, the pallium, and with it parts of the cerebellum, becomes enormously enlarged and structures are formed constituting connections between the pallium and the rest of the brain. The most massive of these are the *pes pedunculi*, added ventrally to the thalamus and midbrain; the *pons Varolii*, added ventrally to part of the midbrain and a considerable part of the hindbrain; and the *pyramids*, added ventrally to the medulla. The basal part of the mid- and hindbrain, thus covered ventrally by the pes and pons, is the *tegmentum.* Portions of the roof plate of the forebrain and hindbrain form thin-walled expansions which, together with vascular mesodermic coverings, are the *tela chorioidea* and *chorioid plexuses* of the lateral, third, and fourth ventricles. The cavities of the cerebral hemispheres are the *lateral ventricles;* the cavity of the interbrain is the *third ventricle;* that of the midbrain is the *iter* or *aquæductus Sylvii;* that of the hindbrain is the *fourth ventricle.*

The wall of the neural tube is at first composed of a single layer of epithelial cells. By proliferation of these cells the epithelium soon becomes many-layered, and forms a syncytium—the *myelospongium* of His—although some of the original epithelial cells appear to extend through the entire thickness of the wall.

Some of the syncytial cells which extend through the entire thick-

ness of the wall of the neural tube (*spongioblasts* of His) increase in length as the wall increases in thickness. The inner ends of these cells form the lining of the tube, while other parts of the cells between the lumen and the surface tend to collapse, forming cord-like structures. The outer ends of the cells, on the other hand, become perforated and unite to form a thick network—the *marginal veil* of His. Of these cells, some retain this position, with nuclei near the lumen, in the adult and are known as *ependymal cells;* others move away from the central canal and become *neuroglia cells.*

Still other of the cells of the neural tube are destined to become neurones, and as such are known as *neuroblasts.* From the neuroblast a neurofibrillated process grows out—the future *axone. Dendrites,* which at this stage are absent, develop later in a similar manner, *i.e.,* by extensions of the cell protoplasm.[1] The neuroblasts soon leave their original position near the lumen and pass outward along the spaces between the elongated ependymal cells, but their bodies do not usually penetrate the marginal veil. Some may, however, pass through and even leave the neural tube along with the efferent roots. The axones of many neuroblasts located in the ventral part of the neural tube pierce the marginal veil and leave the neural tube as the *efferent root fibres.* These nerve cells together with many of the sympathetic neurones (see below) are the *efferent peripheral neurones* (p. 423). Their axones pass to sympathetic ganglia or directly to the various structures (muscles, glands) the activities of which they affect (*effectors,* p. 423). The axones of other neuroblasts do not completely pierce the marginal veil, but are directed upward and downward within it, thus forming fibres connecting various parts of the central nervous system. Axones of still other neuroblasts, especially in suprasegmental structures (see p. 427), are directed toward the lumen. These neurones, whose axones do not leave the neural tube, are the *intermediate* or *central neurones,* as distinguished from the peripheral neurones (p. 423); intermediate, because they serve as intermediate links connecting, within the central nervous system, the terminations of the afferent peripheral neurones (see below) with the bodies of the efferent peripheral neurones; central, because they are confined to the central nervous system. Many of their axones later become medullated and constitute the great majority of the fibres of the white matter of the central nervous system.

[1]According to other views, other cells may participate in the formation of the axone, and the dendrites may anastomose with other neuroblasts (see Chap. VI).

During the closure of the neural groove, groups of cells from the crest of each neural fold become separated from the rest of the developing nervous system. Some of these cells form the *cerebro-spinal ganglia*, while, according to most authorities, others migrate still further from the neural tube and form the various *sympathetic ganglia*. Some cells (neuroblasts) develop into the *nerve cells* of the cerebro-spinal and sympathetic ganglia. Others form, according to some authorities, enveloping cells, such as the *capsule cells* around the ganglion cell bodies and the *neurolemma cells* around the peripheral nerve fibres. These latter would thus correspond to the neuroglia cells of the central nervous system. The majority of the neuroblasts of the cerebro-spinal ganglia develop two processes: peripheral processes (*afferent nerve fibres*) to the various structures (*receptors*) which receive stimuli; and central processes, forming the *afferent roots* and passing into the central nervous system where they usually bifurcate and form longitudinal ascending and descending arms. These cells are at first bipolar, later the cell body withdraws from the two processes and thus assumes the adult unipolar condition (see page 439). Other processes may also appear. Most of the neuroblasts of the sympathetic ganglia develop dendrites and axones while others form branching cells in which the two kinds of processes cannot be easily distinguished. Sympathetic cells may also be derived from cells which migrate from the neural tube along the efferent roots.

The cerebro-spinal ganglionic neurones, together with some sympathetic neurones, certain neurones in the olfactory mucous membrane, retina, and possibly midbrain roof, constitute the *afferent peripheral neurones* of the entire nervous system. Most of the sympathetic neurones are efferent. The peripheral processes of the afferent peripheral neurones, the axones of the efferent peripheral neurones after they have emerged from the central nervous system, and the axones of the sympathetic ganglion cells, together with all their sheaths and connective-tissue investments, form the *peripheral nerves*. The bodies of the afferent peripheral neurones and sympathetic neurones form the groups, already mentioned as *ganglia*. The peripheral neurones, except those lying in the viscera, are arranged *segmentally*, as shown by the series of ganglia and nerves.

The sympathetic ganglionic neurones innervating viscera, glands, blood-vessels, and smooth, heart and, in part, striated voluntary muscle, and those neurones, with cell bodies in the central nervous

system, which send fibres to the sympathetic ganglia (preganglionic sympathetic neurones) are peripheral *visceral* or *splanchnic* neurones. Those cranial nerve neurones which innervate the striated voluntary (branchio-motor) muscles of jaw, ear, face, pharynx, and larynx are usually classed as splanchnic. Those afferent cerebrospinal ganglionic neurones innervating visceral receptors may also be classed as splanchnic. The remainder of the peripheral neurones are peripheral *somatic* neurones.

From the foregoing it will be seen that all the neurones of the nervous system fall into two categories: *peripheral* neurones and *central* or *intermediate* neurones.

I. *Peripheral* neurones. Portions, at least, of the processes of these neurones lie outside the central nervous system, forming the peripheral nerves. The peripheral neurones may be classified as follows: A. *Afferent peripheral* (all the neurone bodies located outside the central nervous system, except the retinal and possibly some trigeminal neurones in midbrain root). The afferent peripheral neurones are (1) the cerebro-spinal ganglion cells, which may be (*a*) somatic, (*b*) splanchnic (*i.e.* to visceral receptors); (2) cells in olfactory membrane, retina, and possibly midbrain; (3) possibly some sympathetic ganglionic neurones (splanchnic). B. *Efferent peripheral* neurones. These are (1) cerebro-spinal (neurone bodies located in ventral part of central nervous system), (*a*) somatic (to voluntary striated muscles except (*b*)), (*b*) splanchnic to voluntary striated branchiomotor muscles (p. 425); (2) sympathetic, (*a*) ganglionic (splanchnic, bodies in sympathetic ganglia, sending axones to smooth muscle, heart muscle, striated voluntary muscle and glands), (*b*) preganglionic (bodies in central nervous system and sending preganglionic fibres to sympathetic ganglia). (Figs. 310 and 311.)

II. *Central* or *intermediate* neurones. These lie entirely within the central nervous system.

In the central nervous system the bodies and dendrites of the neurones are usually aggregated within certain localities which, on account of their appearance when examined in fresh condition, are collectively termed the *gray matter* (*substantia grisea*). The gray matter also contains, of course, the beginnings and endings of the nerve fibres. The parts of the nervous system where the bodies and dendrites are absent and which are composed (exclusive of the neuroglia, blood-vessels, etc.) of medullated and non-medullated nerve fibers are collectively termed the *white matter* (*substantia alba*).

The central nervous system may be divided into a *segmental* part and certain *suprasegmental* parts. The former is in more immediate relation with the peripheral (segmental) nerves. It comprises the spinal cord and basal part of the brain (*segmental* brain). It contains all the bodies of the efferent cerebro-spinal and preganglionic sympathetic neurones and practically all the terminations of the central processes (afferent root fibres) of the afferent peripheral neurones. In it the gray matter is internal, as a rule, and the white matter external. The suprasegmental parts comprise the expanded portions of the dorsal wall of the neural tube already mentioned, namely the pallium, corpora quadrigemina, and cerebellum. These constitute the highest coördinating centers of the nervous system. Here the gray matter is external, constituting a *cortex*, and the white matter is internal. Intermediate neurones which link together different parts of the same segment may be termed *intrasegmental neurones*. Intermediate neurones which link together different segments of the cord and segmental brain may be termed *intersegmental neurones*. Other intermediate neurones form conduction paths (see below) to and from suprasegmental parts (*afferent* and *efferent suprasegmental neurones*) and still others are *suprasegmental associative neurones*, confined to suprasegmental structures (Fig. 296).

The grouping of peripheral neurones into ganglia and nerves has already been mentioned. In the central nervous system more or less definite *groups* or *systems* of neurones having certain definite connections may also be distinguished. The axones of such a system constitute a *tract* or, when aggregated into a definite bundle, a *fasciculus*. A group of neurone bodies is termed a *nucleus*. The group or collection of bodies whose axones form a certain tract is the *nucleus of origin* of that tract. The same nucleus may receive the terminations of some other tract and is then the *terminal nucleus* of that tract. A *conduction path*, or simply *path*, consists of those neurones which conduct a given nerve impulse from some given part of the body or nervous system to another. A conduction path may consist of simply one group of neurones; it is more usually, however, composed of several groups of neurones linked together, thus forming a series of relays. For example, the touch path from skin to spinal cord consists simply of the spinal ganglionic neurones whose peripheral processes terminate in the tactile receptors of the skin; on the other hand a touch path from skin to pallium consists of the

above spinal ganglionic neurones and added neurone groups (*e.g.* bulbo-thalamic and thalamo-cortical neurones). (Figs. 341 and 342).

As already stated all neural reactions must ultimately take effect upon some part of the body or effector and are usually initiated by changes in some receptor. Such a circuit from receptor to effector may be termed a *neural arc* (Fig. 296), and will involve afferent peripheral neurones, efferent peripheral neurones and usually intermediate neurones. The complexity of such arcs depends largely upon the number and character of intermediate neurones intercalated in the arc between the afferent and efferent peripheral neurones. Such arcs may obviously traverse centrally only the cord or segmental brain or may also traverse one or more of the suprasegmental parts of the nervous system.

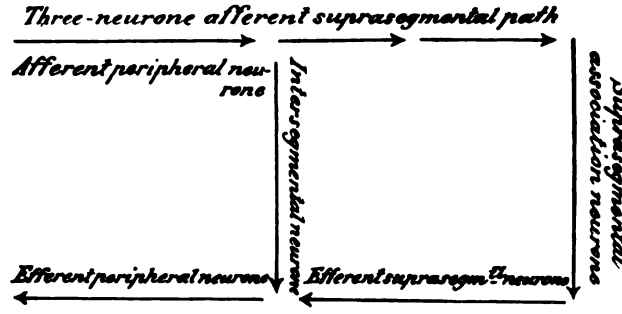

FIG. 296.—Diagram illustrating an arc transversing only the segmental, and an arc transversing the suprasegmental part of the nervous system.

The distinction between somatic and splanchnic neural reactions has already been mentioned (p. 423). Other types of neural reactions are the *kinetic*, *static* or *tonic*, *reflex*, *conscious*, *skilled*, *habit* and *instinct* reactions.

The kinetic reactions are those which involve a more or less complete but transient contraction of the muscles, producing movements; the static or tonic reactions are those which involve the constant state of partial contraction of the muscles, *i.e.* their tonus. Tonus is due to nervous influences largely arising from the organs of position and movement (muscles and tendons) themselves. It is the muscular condition responsible for posture. The various viscera maintain a more or less constant tension in relation to their contents and the voluntary musculature maintains prolonged positions of various parts of the body. One important stimulus which maintains posture in the latter case is the constant action of gravity (Sherring-

ton). The maintenance of posture usually involves a position against gravity and the resultant tension of muscles and tendons stimulates the receptors in these organs (proprioceptors), resulting in a maintenance reflexly or otherwise of the tonus of the muscles. Not only does each muscle thus reflexly maintain its own or "self contraction" but the stimuli from these and other receptors of position and movement are diffused over the central nervous system to various parts which integrate them for the maintenance of general postures of the whole body, for the regulation of movements or kinetic reactions and, by means of proprioceptive memories, for the acquisition of skilled acts. A considerable part of the tonic activities are unconscious. Disturbances of the proprioceptive tonic and kinetic mechanisms are largely responsible for the various hypotonias, myotonias, dystonias, ataxias and, probably to some extent, the various abnormal involuntary movements (choreas, athetoses etc).

Reflexes are usually the simpler, mechanical reactions which, while modified by influences from other parts of the nervous system than those necessary for their performance, are not modified by the past neural activities or experience of the individual, *i.e.* they are not "acquired." Their performance does not usually necessarily involve the pallium. They may be somatic or splanchnic or both. What are usually known as the conscious reactions, on the other hand, are performed by neural circuits involving the associative pallial and thalamo-pallial mechanisms. Their character is usually partly determined by past pallial and thalamo-pallial activities, *i.e.* the past experience of the individual. They are thus usually partly acquired reactions. The skilled reactions (skilled acts such as speech and writing—praxis) always involve the pallial associative apparatus and are conscious. In their case, however, the acquisition of skill (reduction of unessential movements and increase of accuracy and speed) is accompanied by a diminution of the consciousness of the performance of the act, which has been organized into a mechanism which is consciously set in action as a whole but not as to its details. Habit reactions are much the same except the term is usually applied to simpler acquired reactions the performance of which tends to be still more unconsciously performed. The term is also applied to habitual actions of a compulsive character where other internal elements are in play. By instinct reactions in animals are usually meant the more complicated, often not acquired, reactions tending to the preservation of the individual or species. In man the acquired

pallial activities have partly been added to or superseded these and what are here termed instinct reactions are usually those pallial and thalamo-pallial ones which are more directly for the above ends and in which internal bodily (visceral) states play an especially obvious and important rôle (comp. p. 592).

While the leading, most complicated and most extensive neural reactions, those representing the individual as a whole, are those which are conscious, yet it is obvious from the above that conscious activities are far from being coëxtensive with all neural activities. The conscious activities appear to be largely those which are the activities and alterations of the previously acquired pallial and thalamo-pallial associative mechanisms. In them as well as in unconscious neural processes both somatic and splanchnic elements play a part. The unconscious (subconscious) modification of thalamo-pallial and pallial mechanisms, especially by internal bodily states, probably plays an important part in the psychic life of the individual and its abnormal activity may form the basis of various "functional" nervous disturbances.

MEMBRANES OF THE BRAIN AND CORD

The brain and cord are enclosed by two connective-tissue membranes, the dura mater and the pia mater, a part of the latter being often referred to as a separate membrane, the arachnoid (Fig. 297).

The *dura mater* is the outer of the two membranes and consists of dense fibrous tissue. The *cerebral dura* serves both as an investing membrane for the brain and as periosteum for the inner surfaces of the cranial bones. It consists of two layers: (*a*) An inner layer of closely packed fibro-elastic tissue containing many connective-tissue cells, and lined on its brain surface with a single layer of flat cells; and (*b*) an outer layer, which forms the periosteum and is similar in structure to the inner layer, but much richer in blood-vessels and nerves. Between the two layers are large venous sinuses. The *spinal dura* corresponds to the inner layer of the cerebral dura, which it resembles in structure, the vertebræ having their own separate periosteum. The outer surface of the spinal dura is covered with a single layer of flat cells, and is separated from the periosteum by the *epidural space*, which contains anastomosing venous channels lying in an areolar tissue rich in fat. The spinal dura is said to contain lymphatics which open on both of its surfaces. Beneath the spinal

dura, between it and the arachnoid, is the *subdural space*, a narrow cleft containing a fluid probably of the nature of lymph. It is stated that this space communicates by lymph clefts with the lymph spaces in the sheaths of nerves and also communicates with the deep lymph-

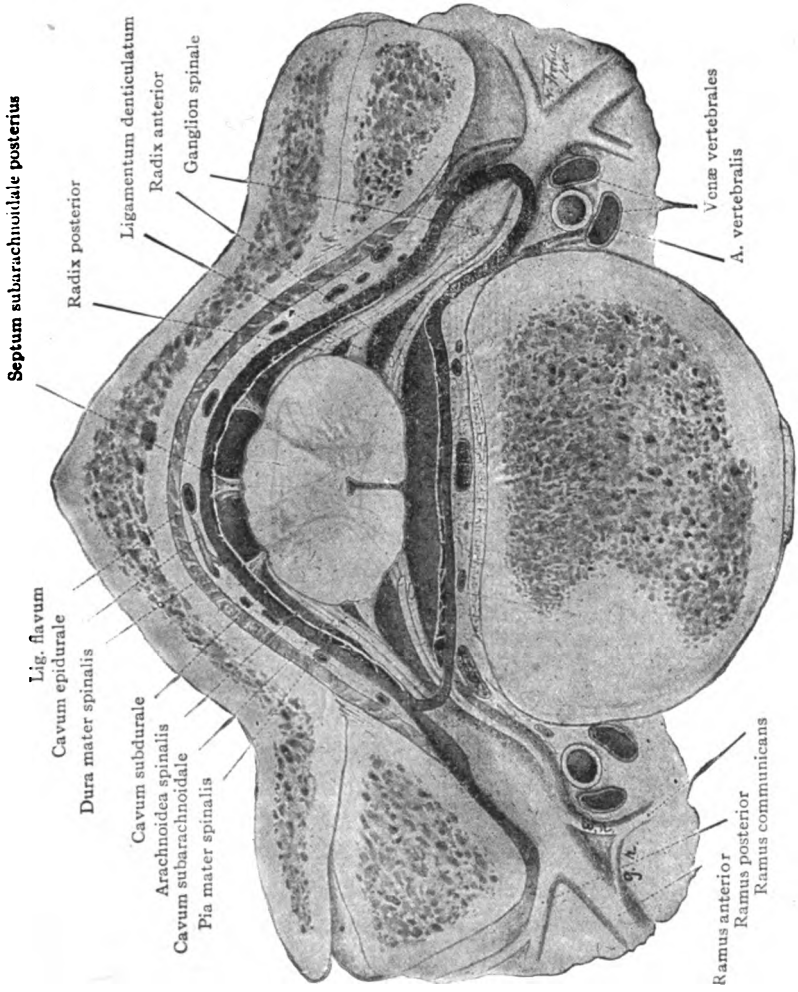

FIG. 297.—Transverse Section through the Fourth Cervical Vertebra, showing the Coverings of the Cord. (Rauber-Kopsch, Anatomie.) *g.r.*, gray ramus communicans; *w.r.*, white ramus communicans.

atic vessels and glands of the neck and groin. It has no direct communication with the subarachnoid space (see below).

The *pia mater* closely invests the brain and cord, extending into the sulci and sending prolongations into the ventricles. It consists

of fibro-elastic tissue arranged in irregular lamellæ, forming a spongy tissue, the cavities of which contain more or less fluid. The outer lamellæ are the most compact, and are covered on the dural surface by a single layer of flat cells. It is this external layer of the pia which is frequently described as a separate membrane, the *arachnoid*. The space beneath the arachnoid is the *subarachnoid space* and contains cerebrospinal fluid. There is direct communication in the roof of the fourth ventricle between the subarachnoid space and the brain cavity (ventricle). The subarachnoid space communicates with the lymphatic spaces within the nerve sheaths. It is also stated that it communicates with the lymph spaces contained within the vascular connective tissue (adventitia) of the blood-vessels which penetrate the central nervous system (the *Virchow-Robin* or *adventitial lymph spaces*). Whether there is normally a perivascular lymph space between adventitia and glial membrane (p. 467) is doubtful and the existence has also been denied, by good authorities, of lymph spaces within the glia, the glial membrane forming in normal conditions a continuous structure. The inner lamellæ of the pia are more loosely arranged, are more cellular and more vascular. Especially conspicuous are large, irregular cells with delicate bodies and large distinct nuclei. They lie upon the connective-tissue bundles, partially lining the spaces.

The *Pacchionian bodies* or *arachnoid villi* are peculiar outgrowths from the pia-arachnoid cerebralis. They are most numerous along the longitudinal fissure and usually project into a venous sinus or venous lacuna. They contain trabeculæ of connective tissue and are separated from the venous space into which they project by a continuation of the subdural space and inner layer of the dura.

Blood-vessels.—The spinal dura and the inner layer of the cerebral dura are poor in blood-vessels. The outer layer of the cerebral dura, forming as it does the periosteum of the cranial bones, is rich in blood-vessels which pass into and supply the bones. The pia is very vascular, especially its inner layers, from which vessels pass into the brain and cord.

TECHNIC

For the study of the structure of the membranes of the brain and spinal cord, fix pieces of the cord with its membranes, and of the surface of the brain with membranes attached, in formalin-Müller's fluid (technic 6, p. 7) and stain sections with hæmatoxylin-eosin (technic 1, p. 23).

THE PERIPHERAL NERVOUS SYSTEM

GENERAL STRUCTURE OF THE PERIPHERAL NERVES

The peripheral nerves are divided into spinal nerves and cranial nerves, the former being connected with the cord, the latter with the brain. Each spinal nerve consists of two parts—a motor or efferent part and a sensory or afferent part. Of the cranial nerves some are purely efferent, others purely afferent, while still others consist, like the spinal nerves, of both efferent and afferent fibres. The efferent fibres of the spinal nerves are axones of cell bodies situated in the ventral and lateral horns of the cord (p. 426; Figs. 310, 317) and axones of sympathetic ganglion cells. The former leave the cord in several bundles, which join to form the motor or efferent root. The afferent fibres are peripheral processes of cell bodies situated in the spinal ganglia located on the dorsal root (p. 427 and Figs. 317. 300). These leave the ganglion and join with the fibres of the motor root to form the mixed spinal nerve (Fig. 317, *f.*) The connection of the ganglion with the cord is by means of the central processes of the spinal ganglion cells, which enter the cord as the dorsal root. Among the afferent fibres of the dorsal root are also found, in some animals, a few efferent fibres (Fig. 317, *c*). processes of cells in the cord. Some fibres from the spinal ganglion and from the efferent roots form the white ramus communicans to the sympathetic ganglia. Fibres from the sympathetic ganglia form the gray ramus communicans to the mixed spinal nerve (Figs. 297 and 310). The same fundamental relations hold for the cranial nerves, *i.e.*, the afferent fibres arise from cell bodies outside the central nervous system and the efferent fibres either from cell bodies lying within the brain or from sympathetic ganglion cells outside the brain. The optic "nerve" and possibly part of the trigeminus form an exception to this. The optic nerve is a tract connecting the retina (an evaginated part of the neural tube) with the brain, and the trigeminus contains, possibly. some afferent fibres originating from cell bodies lying within the brain (the mesencephalic root, from non-migrating ganglion cells?). The olfactory nerve arises from cells in the olfactory mucous membrane which thus retain their primitive position at the surface of the body. For further details regarding cranial nerves see pp. 504–506 and chapter on Organs of Special Sense.

The peripheral nerve consists of nerve fibres supported by connective tissue (Fig. 298). Enclosing the entire nerve is a sheath of

dense connective tissue, the *epineurium*. This sends septa into the nerve which divide the fibres into a number of bundles or *fascicles*. Surrounding each fascicle the tissue forms a fairly distinct sheath, the *perifascicular sheath* or *perineurium*, which is covered with a layer of flat cells. From the perineurium, delicate strands of connective tissue pass into the fascicle, separating the individual nerve fibres. This constitutes the *intrafascicular connective tissue* or *endoneurium*. In the connective-tissue layers of the perineurium are blood-vessels, and lymph spaces lined with endothelium, which communicate with lymph channels within the fascicle. When nerves branch, the con-

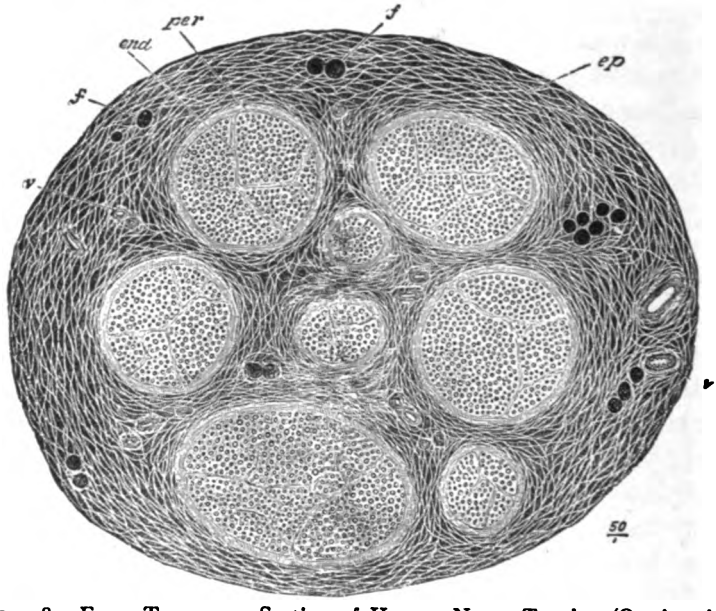

FIG. 298.—From Transverse Section of Human Nerve Trunk. (Osmic acid fixation.) (Quain.) *ep*, Nerve sheath or epineurium surrounding the entire nerve and containing blood-vessels (*v*) and small groups of fat cells (*f*); *per*, perifascicular sheath or perineurium surrounding each bundle or fascicle of nerve fibres; *end*, interior of fascicle showing supporting connective tissue, the endoneurium.

nective tissue sheaths follow the branchings. When the nerve becomes reduced to a single fibre, the perineural and endoneural connective tissue still remaining constitutes the sheath of Henle. The space between the neurolemma and sheath of Henle has been described as a lymph space communicating with the rest of the lymphatic system of the nerve. On emerging from the central nervous system, the root fibres receive an investment of connective tissue (endoneurium and perineurium) as they pass through

the pia mater. This is reinforced by additional connective tissue (epineurium), as the nerve passes through the dura mater. For description of medullated and non-medullated nerve fibres see Chap. VI.

TECHNIC

Fix a medium-sized nerve, such as the human radial or ulnar, by suspending it, with a weight attached to the lower end, in formalin-Müller's fluid (technic 6, p. 7). Stain transverse sections in hæmatoxylin-picro-acid-fuchsin (technic 3, p. 24), hæmatoxylin-eosin (technic 1, p. 23), or better in Mallory's phospho-tungstic acid hæmatoxylin or acid fuchsin-anilin blue-orange stain and mount in balsam. Pieces of nerve should also be fixed in osmic acid imbedded, cut, and mounted without further staining. Pieces of fresh nerve may be tested and examined without staining.

THE AFFERENT PERIPHERAL NEURONES AND RECEPTORS

These comprise, as already stated, the bodies and processes of the cerebro-spinal ganglion cells or cerebro-spinal ganglionic neurones, possibly some of the sympathetic ganglion cells, certain cells of the retina and certain cells of the olfactory mucous membrane. The two last named are described in connection with the organs of special sense.

The number of medullated fibres in the dorsal spinal roots (medullated central processes of spinal ganglion cells) has been estimated at 653,000 on one side in man, of which 258,000 innervate the leg, 193,000 the arm, 117,600 the trunk and 84,400 the neck (Ingbert). About one-fifth convey impressions from muscles and four-fifths from cutaneous structures. Only about 2 per cent. are connected with the sympathetic.

The Cerebro-spinal Ganglia

A cerebro-spinal ganglion contains the bodies of the cerebro-spinal ganglionic neurones whose processes form the afferent root of the cerebro-spinal nerve. It lies in the dorsal root, a dorsal root being that part of the nerve which lies between the exit of the dorsal root fibres from the cord and their junction with the ventral root, if there be one, otherwise the part connecting ganglion and central nervous system. Each ganglion is surrounded by a connective-tissue capsule which is continuous with the perineurium and epineurium of the peripheral nerves. (Fig. 297.) From this capsule connective-tissue trabeculæ extend into the ganglion, forming a

connective-tissue framework. Within the ganglion the nerve cells are separated into irregular groups by strands of connective tissue and by bundles of nerve fibres. Each ganglion cell contains a centrally located nucleus and a distinct nucleolus, and is surrounded by a capsule of flat, concentrically arranged cells which are probably derived from the neural plate (p. 427) and are often called *amphicytes* or *capsule* cells (Fig. 301). Stained by Nissl's method the cytoplasm is seen to contain rather small, finely granular chromophilic bodies, which show a tendency to concentric arrangement around the nucleus. Pigmentation is common, the granules usually forming a group in the vicinity of the point of origin of the main process of the cell or sometimes lying near the periphery

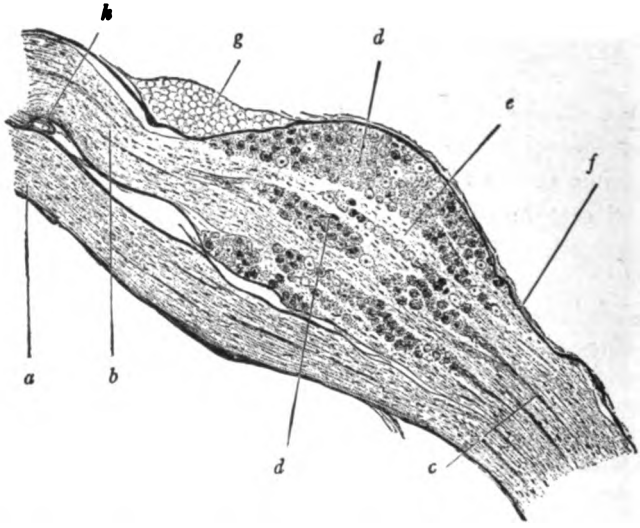

FIG. 299.—Longitudinal Section through a Spinal Ganglion. ×20. (Stöhr.) *a*, Ventral nerve root; *b*, dorsal nerve root; *c*, mixed spinal nerve; *d*, groups of ganglion cells; *e*, nerve fibres; *f*, perineurium; *g*, fat; *h*, blood-vessel.

In general at least four types may be distinguished (Warrington): (a) *Large clear cells* (35–100μ, cat) with fine chromophilic bodies, rather larger near the periphery, distributed about equally through the cytoplasm. There may be a perinuclear and peripheral clear zone. The nucleus is large and clear (vesicular type). These cells comprise about ¼ to ⅓ of all spinal ganglion cells. The larger probably send their peripheral processes to the corpuscles of Pacini, muscle spindles and other deep end organs of body wall and viscera (p. 445 *et seq.*), the smaller ones to cutaneous structures and possibly to visceral structures. (b) *Obscure cells* (10–56μ) with fine chromophilic bodies, rather larger near the nucleus. The cytoplasm and nucleus also stain diffusely by Nissl's method. These cells comprise ½ to ¾ of the spinal ganglion cells.

They send their peripheral processes to cutaneous and visceral structures (pain and pressure or touch?). (c) *Coarsely granular cells* (35–50μ). The chromophilic bodies are somewhat large but few in number. There is a clear perinuclear zone. The nucleus is clear. These cells comprise about 2½ to 4 per cent. of the spinal ganglion cells. They do not show degenerative changes after cutting the dorsal root just distal to the ganglion and consequently may not send any peripheral process outside the ganglion. They would thus be apparently represented by cells 7 and 9 in Fig. 300. (d) *Smallest cells* (under 25μ). Cells of this size and of both clear and obscure types also do not show degenerative changes. They comprise about 7½ to 14 per cent. of the spinal ganglion cells of which about ⅓ are clear cells. They are believed by Warrington to be immature cells.

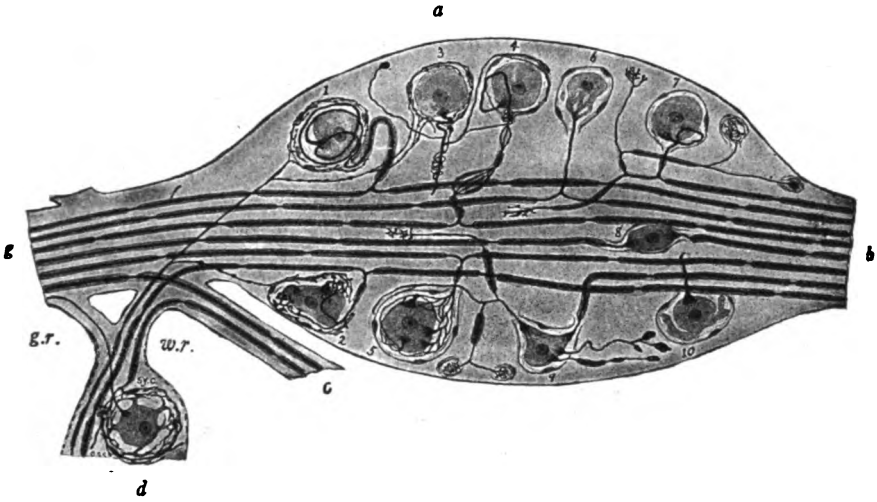

FIG. 300.—Various Types of Cells and Nerve Terminations found in a Spinal Ganglion. Schematized from Dogiel. *g.r.*, gray ramus communicans; *sy.c.*, sympathetic cell; *w.r.*, white ramus communicans. *a*. Spinal ganglion; *b*, dorsal or afferent root; *c*, ventral or efferent root; *d*, sympathetic ganglion; *g*, spinal nerve. For further explanation see text (pp. 439–440).

The majority of the cells of the spinal ganglia have one principal process which, at some distance from the cell body, divides into a peripheral branch which becomes an afferent fibre of the peripheral nerve and a central branch which enters the cord as a dorsal root fibre (p. 427). These cells are usually called unipolar cells. The principal process usually becomes medullated soon after emerging from the cell capsule (Fig. 300). A large number of the processes of spinal ganglion cells, or afferent nerve fibres, are however, non-medullated, possibly as many as half. These fibres probably originate from the smaller cells.

Among the spinal ganglion cells a number of forms have been distinguished

by Dogiel: (a) Cells with simple principal process. This process may pass almost directly from the capsule, but often takes several turns around the cell body, forming a "glomerulus," before emerging from the capsule (Fig. 300, 1 and Fig. 301, *A*). This form is usually represented as the typical cerebro-spinal ganglion cell, but constitutes only a minority of these cells. Cells of all sizes may be of this type. The principal process and its divisions may be medullated or non-medullated. (b) The principal process gives off collaterals. These lie within the capsule or are given off outside the capsule and terminate in other parts of the ganglion and its covering, either in terminal arborizations or in terminal enlargements or bulbs. The collaterals may branch. Some of the terminations may be around the capsules of other cells. There may be one or several collaterals, sometimes a number of very short intracapsular collaterals. This last variety of cell may have two main processes which fuse. The principal process usually undergoes the T or Y division into medullated peripheral and central arms. There may be some exceptions. These cells are of medium and large size. (Fig. 300, 2 and 3, Fig. 301, *B*). (c) Cells with split processes. Here the main process divides into a number of fibres which reunite; this may be repeated. The splitting may be intracapsular or extracapsular. A variation of this is where there are two to six processes from the cell which form a complicated intracapsular network, finally uniting to form the single main process (Fig. 300, 4 and 5 and Fig. 301, *C* and *D*). The principal process in most of these cells divides into the usual peripheral and central arms, which may be medullated or non-medullated. They are of varying sizes but mostly of medium size. There are many cells of this type. (d) Cells with a number of dendrite-like processes which divide, forming an intracapsular network which finally fuses into the main process which divides as usual. These cells are scarce and usually small (Fig. 300, 6). (e) Cells whose principal process divides as usual, but the peripheral branch terminates by arborizations or bulbs in the ganglion and in its covering, or in the neighborhood of the dorsal root (Fig. 300, 7). The branches are usually medullated. These cells are large or medium. (f) Bipolar cells (Fig. 300, 8). Their processes are usually in part at least medullated. They are medium-sized cells. (g) Multipolar cells with a number of intracapsular dendrites and a main process (Fig. 300, 10; Fig. 301, *E* and *F*). These are small cells. (h) Cells with a principal process which probably enters the dorsal root and a number of processes which may be dendrite-like in character, but also become medullated in places, and which branch and terminate in arborizations or bulbs in various parts of the ganglion. These latter apparently collectively represent the peripheral process which here ends in the ganglion (Fig. 300, 9). These are large or medium-sized cells.

The various endings in the ganglion of collaterals and other processes of ganglion cells often have capsules and resemble the terminations in receptors in other parts of the body (corpuscles of Pacini, end bulbs, etc.) and, together with their envelopes, may represent the receptors of the ganglion itself and of the connected nerves.

Sympathetic fibres enter the ganglion, according to Dogiel, and form a plexus within it from which fibres pass and terminate within the capsules of the various ganglion cells.

The Receptors

The modes of termination of the peripheral processes of the spinal ganglion cells in receptors (p. 425) are extremely varied and

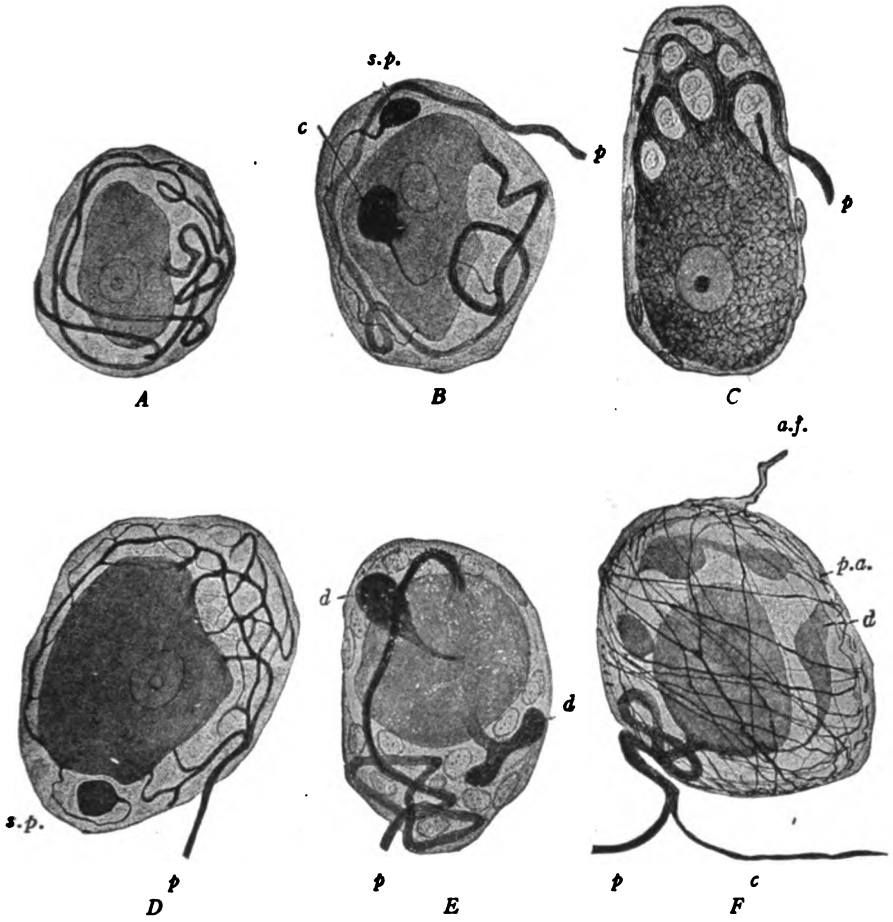

FIG. 301.—Cerebro-spinal Ganglion Cells and their Capsules. (Cajal.) *A* (adult man), unipolar cell with single process forming a glomerulus; *B* (man), cell with short process ending in intracapsular bulb and main process giving off intracapsular collateral; *C* (dog), "fenestrated" cell with several processes uniting to form main process; *D* (ass), more complicated form of the same; *E* (man), cell with short bulbous dendrites; *F* (man), cell with bulbous dendrites and enveloped with pericellular arborizations (*p.a.*) of fibres (*a.f.*) terminating around cell; *c*, collateral; *d*, dendrite; *p*, principal process; *s.p.*, short process. (Cajal's silver stain.)

complicated. These peripheral terminations are always free, in the sense that, while possibly sometimes penetrating cells, they probably never become directly continuous with their protoplasm.

The receptors are often divided into two categories the *non-encapsulated* and *encapsulated* according to whether they are enclosed in a connective tissue capsule. The former are often called free or diffuse endings.

In the skin, and in those mucous membranes which are covered with squamous epithelium, the nerve fibres lose their medullary sheaths in the subepithelial tissue, and, penetrating the epithelial layer, the axis-cylinder splits up into minute fibrils (terminal arborization) which pass in between the cells and terminate there, often in little knob-like swellings (Fig. 302). Such terminal fibrils

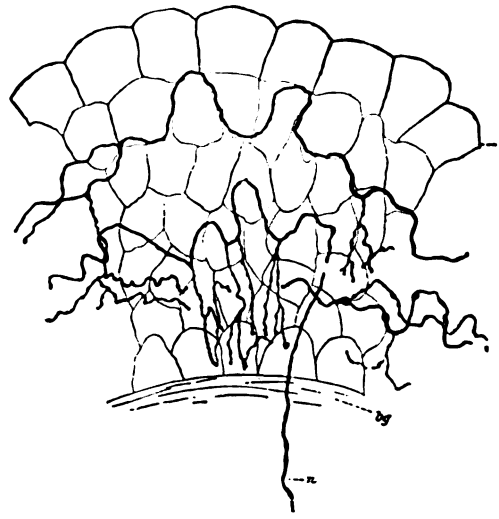

FIG. 302.—Free Endings of Afferent Nerve Fibres in Epithelium of Rabbit's Bladder. (Retzius.) *o*, Surface epithelium of bladder; *b g*, subepithelial connective tissue; *n*, nerve fibre entering epithelium where it breaks up into numerous terminals among the epithelial cells.

do not penetrate among the squamous cells. Similar "*diffuse*" endings are found in serous membranes and in simple epithelia, also in connective tissue. In the case of glandular epithelia such endings may, in part at least, be terminations of efferent (secretory) fibres from sympathetic ganglion cells (p. 445). Diffuse endings have also been described on endothelial surfaces such as endocardium and in smooth muscle. The latter are to be distinguished from the regular motor endings described below. An important form of diffuse ending is the *peritrichial* in which terminal fibrils encircle and end in the outer root sheaths of hair follicles (Fig. 303). Nerve

endings are abundant in the pulp of teeth. There has been some dispute as to whether they penetrate the dentine. In addition to such comparatively simple nerve endings, there are also found in the skin and mucous membranes, especially where sensation is most acute, much more elaborate terminations. These may be classified as (1) tactile cells, (2) tactile corpuscles, and (3) end bulbs.

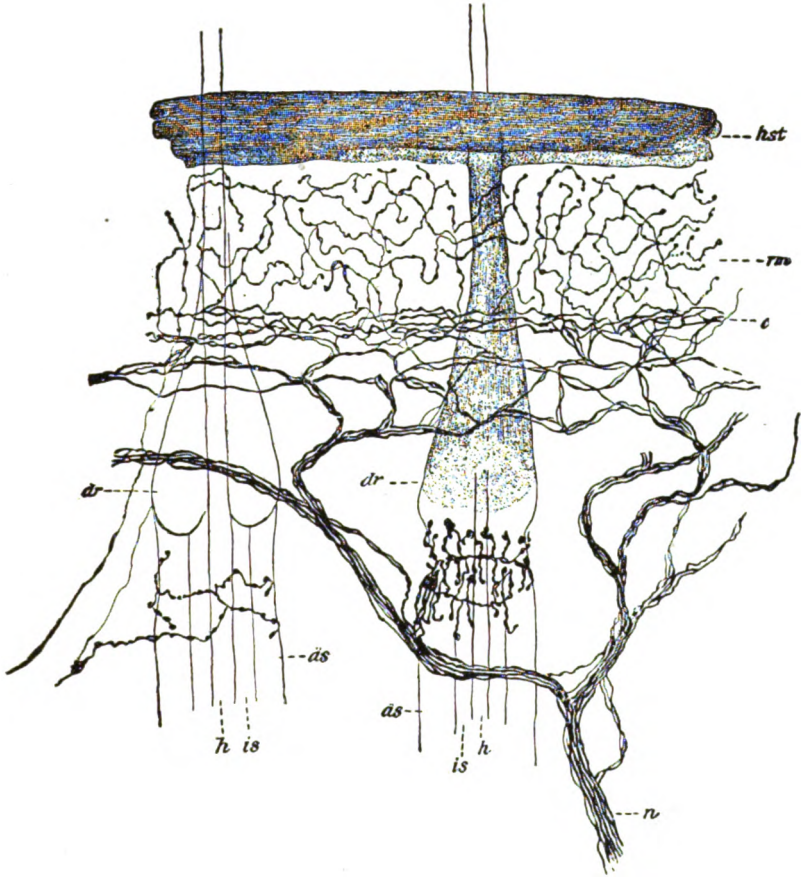

FIG. 303.—Nerves and Nerve Endings in the Skin and Hair Follicles. (After G. Retzius.) *As*, Outer root sheath; *c*, most superficial nerve-fibre plexus in the cutis: *dr*, sebaceous glands; *h*, the hair itself; *hst*, stratum corneum; *is*, inner root sheath of hair; *n*, cutaneous nerve; *rm*, stratum germinativum Malpighii.

A *simple tactile cell* is a single epithelial cell, the centrally directed end of which is in contact with a leaf-like expansion of the nerve terminal, the *tactile meniscus*. In the corpuscles of Grandry, found in the skin of birds, and in Merkel's corpuscles, which occur in mammalian skin, several epithelial cells are grouped together to

receive the nerve terminations. These are known as *compound tactile cells*. the axis cylinder ending in a flat tactile disc or discs between the cells.

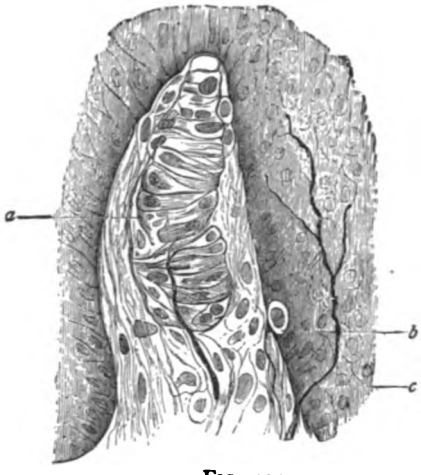

FIG. 304.

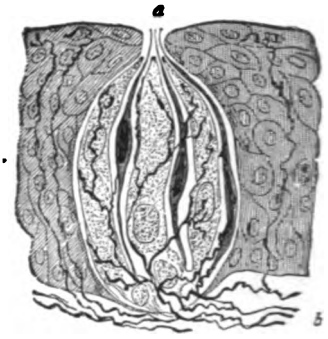

FIG. 305.

FIG. 304.—Tactile Corpuscles of Meissner, tactile cell and free nerve ending. (Merkel-Henle.) *a*, Corpuscle proper, outside of which is seen in the connective-tissue capsule, *b*, fibre ending on tactile cell; *c*, fibre ending freely among epithelial cells.

FIG. 305.—Taste Bud from Circumvallate Papilla of Tongue. (Merkel-Henle.) *a*, Taste pore; *b*, nerve fibres entering taste bud and ending upon neuro-epithelial cells. On either side fibres ending freely among epithelial cells.

Of the *tactile corpuscles* (Fig. 304) those of Meissner, which occur especially in the hairless portions of the skin and are most numerous in the volar surfaces of the fingers, are the best examples. These corpuscles lie within the papillæ of the derma. They are

FIG. 306.—End Bulb from Conjunctiva. (Dogiel.) *a*, Medullated nerve fibre, axone of which passes over into dense end skein.

oval bodies, surrounded by a connective-tissue capsule and composed of flattened cells. From one to four medullated nerve fibres are distributed to each corpuscle. As a fibre approaches a corpuscle, its connective-tissue sheath becomes continuous with the fibrous capsule, the medullary sheath disappears, and the fibrillæ of the

terminal aborization pass in a spiral manner in and out among the epithelial cells. These terminal fibrils usually end in a flattened expansion consisting of neurofibrils and perifibrillar substance. Tactile corpuscles are also found in the skin of the hands and feet, on the volar surface of the forearm, eyelids, lips and tip of the tongue.

Of the so-called *end bulbs*, the simplest, which are found in the mucous membrane of the mouth and conjunctiva, consist of a central core formed by the more or less expanded end of the branched axis cylinder, surrounded by a mass of finely granular, nucleated protoplasm—the inner bulb—the whole enclosed in a capsule of flattened connective-tissue cells continuous with the sheath of Henle. Other end bulbs may be compound. End bulbs are found also in the lips, in the mucous membrane of the tongue, cheeks, soft palate, epiglottis, nasal cavities, lower end of rectum, peritoneum, serous membranes, tendons, ligaments, connective tissue of nerve trunks, synovial membranes of certain joints and external genitals, especially the glans penis and clitoris.[1]

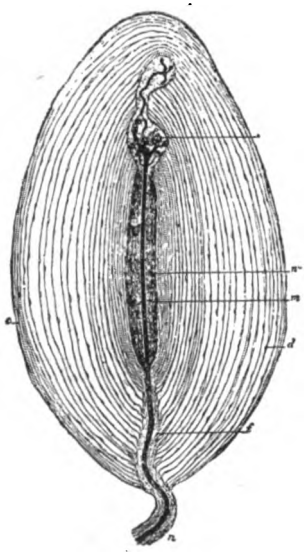

FIG. 307.—Pacinian Body from Mesentery of Cat. (Ranvier.) *c*, Lamina of capsule; *d*, epithelioid cells lying between laminæ of capsule; *n*, nerve fibre, consisting of axis cylinder surrounded by Henle's sheath, entering Pacinian body; *f*, perineural sheath; *m*, inner bulb; *n*, terminal fibre which breaks up at *a* into an irregular bulbous terminal arborization.

The *Pacinian bodies* (Fig. 307) are laminated, elliptical structures which differ from the more simple end bulbs already described, mainly in the greater development of the perineural capsule. The capsule is formed by a large number of concentric lamellæ, each lamella consisting of connective-tissue fibres lined by a single layer of flat connective-tissue cells. The lamellæ are separated from one another by a clear fluid or semi-fluid substance. As in the simpler end bulbs, there is a cylindrical mass of protoplasm within the capsule known as the inner bulb. Extending lengthwise through the centre of the inner bulb and often ending in a knob-like extremity is the axis cylinder. Arteries in

[1]This description of the distribution of the various receptors is principally taken from the excellent account in Schäfer's "Text-Book of Microscopic Anatomy." An admirable and still more detailed account is to be found in "The Nervous System," by Barker.

the vicinity of the corpuscle break up into capillary networks surrounding the corpuscle. From this network capillaries enter the corpuscle, usually near the nerve fibre, and penetrate among the lamellæ, even reaching the distal end of the corpuscle. They do not enter the inner bulb. The Pacinian bodies are found in the subcutaneous fat, especially of the hand and foot, in the parietal peritoneum, mesentery, penis, clitoris, urethra, nipple, mammary gland, in the vicinity of tendons, ligaments and joints and in other parts of body wall and viscera. They are usually attached to the finer branches of the nerves supplying these parts.

In voluntary muscle afferent nerves terminate in Pacinian corpuscles, in end bulbs, and in complicated end organs called *muscle spindles*, or neuromuscular bundles. The muscle spindle (Fig. 308)

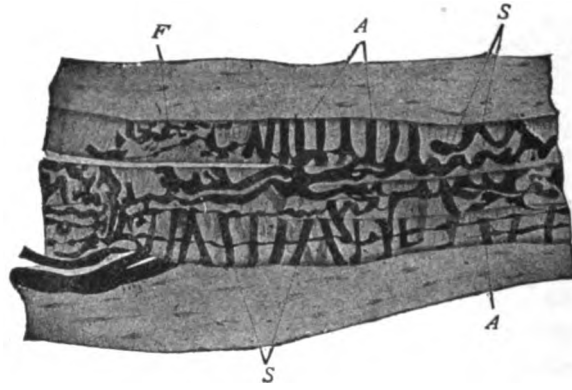

FIG. 308.—Middle Third of Muscle Spindle from Striated Voluntary Muscles of Cat. (From Barker, after Ruffini.) *A*, annular terminations; *S*, spiral terminations; *F*, arborescent terminations.

is an elongated cylindrical structure within which are muscle fibres, connective tissue, blood-vessels, and medullated nerves. The whole is enclosed in a connective-tissue sheath which is pierced at various points by nerve fibres. A single spindle contains several muscle fibres and nerve fibres. The muscle fibres differ from ordinary fibres, being fine and containing more nuclei and sarcoplasm in the middle. The muscle spindles are more numerous in the limb muscles than in those of the trunk, and in the distal than the proximal part of the limb. There are few in eye muscles and in some muscles they have not been detected. According to Ruffini, there are three modes of ultimate terminations of the nerve fibres within the spindles: one in which the end fibrils form a series of rings which

encircle the individual muscle fibre, termed *annular terminations;* a second in which the nerve fibrils wrap around the muscle fibres in a spiral manner—*spiral terminations;* a third in which the terminations take the form of delicate expansions on the muscle fibre—*arborescent terminations.*

At the junction of muscle and tendon are found the elaborate afferent terminal structures, known as the *muscle-tendon organs of*

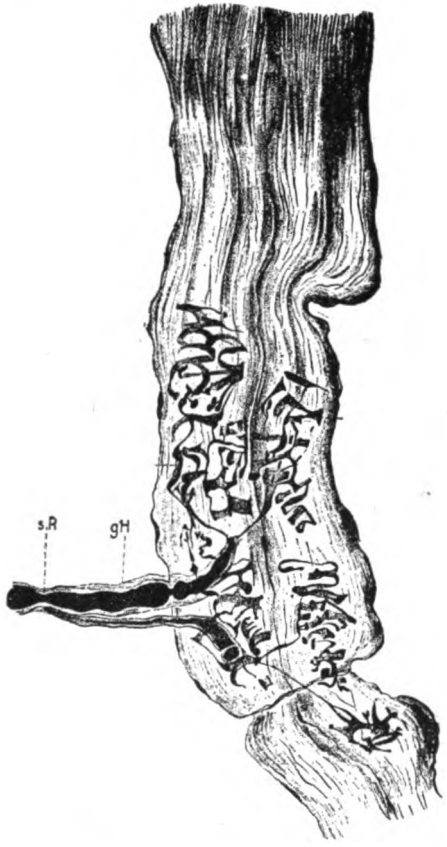

FIG. 309.—Tendon of Muscle of Eye of Ox. (Ciaccio.) Two muscle-tendon organs of Golgi, each showing ring-like and brush-like endings. *gh*, sheath of Henle; *sr*, node of Ranvier.

Golgi (Fig. 309). This is a spindle-shaped body composed of several tendon bundles. Into this there enter one or several nerve fibres which break up into complicated terminal arborizations upon the tendon bundles.

Other forms of nerve endings enclosed within connective-tissue

sheaths are corpuscles of Ruffini found in the subcutaneous tissue of the finger and corpuscles of Golgi-Mazzoni found on the surfaces of tendons and also in the subcutaneous tissue of the fingers and in other parts of the skin.

It is evident from the above that the nerve terminations are only stimulated through the intermediation of surrounding cells which may form quite elaborate structures. These cells probably render the various nerve terminations they envelop more or less inaccessible to all but one particular kind of stimulus. The receptors described above are scattered throughout head and body (*general* or *common body sensibility, somæsthesia*) as distinguished from those which are concentrated into the organs of the *special senses* (smell, sight, hearing, taste) present only in the head. The various stimuli received by the former may give rise to sensations of light pressure or touch (tactile cells and tactile corpuscles, terminations in hair sheaths), temperature and pain (diffuse terminations in epithelium and connective tissue?), muscle-tendon sense of movement and position (muscle spindles and possibly end bulbs, etc., in muscles; tendon organs of Golgi). The above may be roughly grouped into *general cutaneous* or *superficial sensation* and *deep sensation* (muscle-tendon and other bodily sensations). All receptors, both of general and special senses, may be classified (Sherrington) as those receiving stimuli from the external world (*extero-ceptors:* superficial sensation, smell, sight, and hearing), those concerned with visceral reactions (*intero-ceptors*, including taste) and those giving information of bodily changes, especially position and movement produced by contractions of voluntary muscles (*proprio-ceptors*). The exteroceptors are divided into *distance receptors* which receive stimuli from distant objects (smell, vision and hearing) and *contact receptors* (touch, pressure, cutaneous pain and temperature).

THE SYMPATHETIC SYSTEM

(Figs. 310 and 311)

The sympathetic system consists essentially of a series of ganglia added to the efferent peripheral path so that the efferent path instead of being composed of one system of neurones, as is the case with the somatic path to voluntary striated muscle, is composed of two systems of neurones, one (preganglionic, p. 428) passing from central nervous system to the sympathetic ganglia and the second, the sympathetic ganglia, the fibres of which pass (postganglionic fibres) to the visceral effectors and to striated voluntary muscle. Peripheral processes of cerebrospinal ganglion cells (and possibly some sympathetic ganglion cells) furnish its afferent fibres. The connections between central nervous system and ganglia are in four regions: (1) the *midbrain* (cranial nerve III), (2) *bulbar* (cranial nerves VII, IX, and X), (3) *thoraco-lumbar* (thoracic and first three or four lumbar spinal segments) and (4) *sacral*. The first, second and fourth

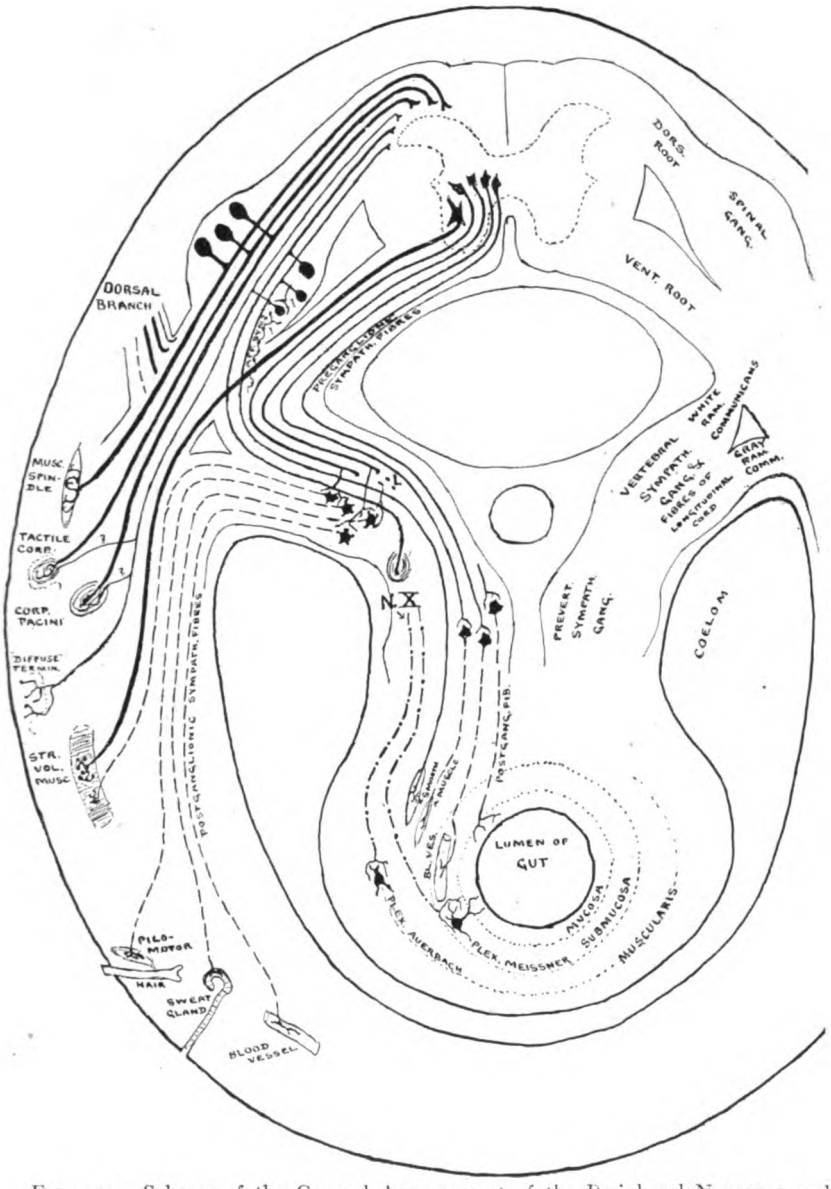

FIG. 310.—Scheme of the General Arrangement of the Peripheral Neurones and Innervation of the Principal Receptors and Effectors in a typical Segment of the Body. The somatic neurones (except the neurone having a diffuse termination) are indicated by thick lines, the splanchnic afferent (and the neurone with diffuse termination) and splanchnic (sympathetic) preganglionic neurones are indicated by thin lines and the sympathetic ganglionic neurones by broken lines. Vagus fibres (*N.X.*) are indicated by dashes and dots. At *L* some of the transversely cut longitudinal fibres of the sympathetic cord are indicated. From the afferent neurone with diffuse termination are seen (at "?") branches to other receptors; such branches might make possible the transmission of painful stimuli from such other receptors ordinarily receiving stimuli of a different character. The collateral seen in the spinal ganglion passing from a visceral to a cutaneous ganglionic neurone would form a possible path by which a visceral stimulus would pass into the cutaneous cord centers (referred pains?). The wavy line in the ganglion represents the termination in the ganglion of a possible afferent sympathetic ganglionic neurone.

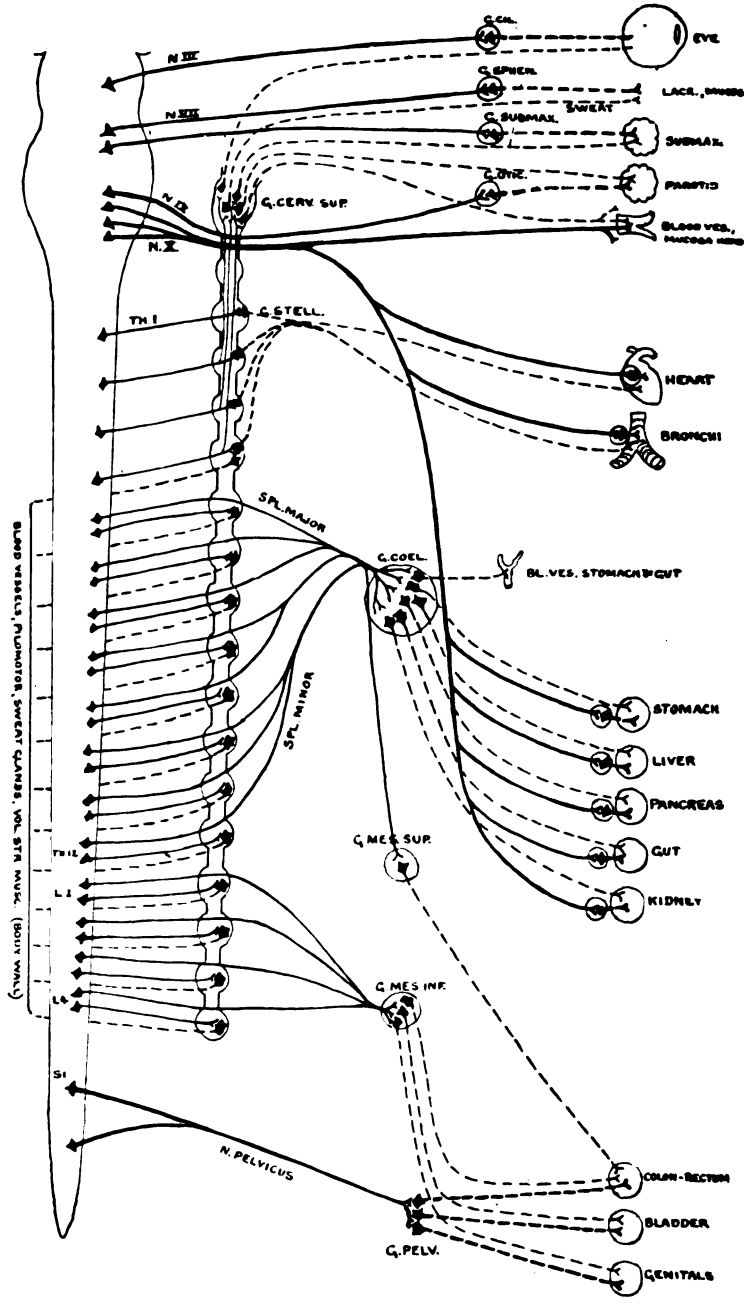

FIG. 311.—Scheme of the General Longitudinal Arrangement of the Sympathetic Neurones. Afferent elements and the longitudinal fibres of the sympathetic cord, except those to the superior cervical ganglion, are omitted. Preganglionic fibres are represented by continuous lines, postganglionic by broken lines. The cranial and sacral systems are represented by thicker lines than the thoraco-lumbar system. *G.* = ganglion. The ganglia which receive vagus fibres (terminal ganglia) lie within the walls of the organs they supply. The pelvic ganglia lie on the outside of the walls of the organs they supply. (Modified from Higier).

have certain features in common and an antagonistic physiological action to the third. They may be termed collectively the *cranio-sacral* sympathetic as opposed to the *thoraco-lumbar* sympathetic.[1]

The ganglia of the cranial sympathetic, lying in the head, are the *ciliary* (III), *sphenopalatine*, *submaxillary* and *sublingual* (VII) and *otic* (IX). These receive preganglionic fibres from the nerves indicated and send their fibres (postganglionic fibres) to the smooth ciliary and sphincter iridis muscles of the eye (ciliary ganglion), to the blood vessels and mucous glands of the mucous membranes of the head and to the lacrimal glands (sphenopalatine ganglion), to the submaxillary salivary gland (submaxillary ganglion) and the parotid gland (otic ganglion). In addition the bulbar (X) sends fibres to *terminal* sympathetic ganglia in the walls of the heart and viscera, innervating the heart and the glands and smooth muscle of the digestive tract from mouth to descending colon including also respiratory tract, liver and pancreas. According to some authorities there may be partial relays in the distal root ganglia (nodosum and petrosum) of IX and X. The bulbar system thus innervates practically the gut and its appendages from mouth to large intestine.

The ganglia of the sacral sympathetic, called collectively the *pelvic ganglia*, receive preganglionic fibres (pelvic nerve) from the sacral cord and send their postganglionic fibres to the arteries of rectum, anus and external generative organs, muscles of external generative organs, walls of bladder, urethra, and descending colon to anus. The sacral system thus practically innervates those portions of the visceral organs not innervated by the bulbar sympathetic. The pelvic ganglia, or ganglia of the pelvic plexuses, are located outside, not within, the walls of the above organs.

The ganglia of the thoraco-lumbar sympathetic receive preganglionic fibres from thoracic and upper three or four lumbar segments of the cord. There are two series of ganglia: the *vertebral* (*lateral*) *ganglia*, connected by a longitudinal bundle of fibres and thereby forming the sympathetic cord or chain, and the irregular collections of ganglion cells in the prevertebral plexuses, *prevertebral* (*collateral*) *ganglia*. The preganglionic fibres from the cord pass out with the other ventral root fibres, separate from the latter and form the *white rami communicantes*, consisting principally of fine medullated

[1]Langley suggested the term autonomic for the whole system, subdividing it into the cranial, sympathetic *sensu stricto* and sacral portions. This has led to the mistaken application of the term autonomic ("parasympathetic") to only the cranial and sacral portions.

fibres. The preganglionic fibres have two general destinations: (*a*) They terminate in the vertebral ganglia, either the one in the same segment or they pass upward or downward in the sympathetic cord giving off collaterals and terminating in vertebral ganglia above or below the segment of their exit. In the sympathetic cord the preganglionic fibres from the lower thoracic segments pass mainly downward, those from the upper thoracic segments pass upward. Some of the latter, from the four upper thoracic segments, pass upward in the cord to the upper cervical vertebral ganglion and terminate in it. (*b*) Other preganglionic fibres pass beyond the vertebral ganglia, form the rami efferentes (splanchnic nerves) and terminate in the prevertebral ganglia. The postganglionic fibres (mostly non-medullated) of many of the vertebral ganglia form the *gray rami communicantes* to the spinal nerves, of which they are a part. The upper cervical ganglion sends fibers (*via* the carotid and cranial plexuses) to the dilatator pupillæ, orbital muscle of Müller, smooth muscle portion of the levator palpebræ, blood-vessels of the head, salivary glands and probably the sweat glands of the face. Cervical and upper thoracic ganglia send post-ganglionic fibres to the heart (accelerator) and respiratory tract. The lower vertebral ganglia which receive preganglionic fibres from the lumbar cord send fibres to the colon-rectum, bladder and generative organs. The remaining vertebral ganglia send fibres forming gray rami communicantes to the spinal nerves and thence to the various effectors in the body wall, viz., blood-vessels of skin and muscles, smooth muscles (pilomotor) and glands of the skin and to the voluntary striated muscles. The prevertebral ganglia send their postganglionic fibres to the blood-vessels and smooth muscle (sphincters) of the digestive tract. The thoraco-lumbar thus is distributed to all parts of the body, to the parts innervated also by the craniosacral sympathetic, which parts thus receive a double sympathetic innervation, and also to the outer body wall which it alone innervates. While the sympathetic fibres to the outer body wall pass out in company with the other spinal nerve fibres, those to the viscera usually run with the arteries.

The terminal ganglia, which receive the vagus fibres, form in the walls of the intestine the plexuses of Meissner (submucosal plexus) and of Auerbach (myenteric plexus). According to some authorities these plexuses mediate the reflex activities persisting after the gut has been cut off from the central nervous system. According to another view some of these activities may be accounted

for by impulses passing from one neurone to another by collaterals of axones (axone-reflex or pseudo-reflex of Langley).

The afferent fibres traveling in the sympathetic system undoubtedly come in part at least from cerebrospinal ganglion cells. Fibres from spinal ganglia form part of the white rami communicantes and may apparently pass along in the sympathetic cord. Some of them are the largest fibres present in the sympathetic. A portion at least of these large fibres innervate the corpuscles of Pacini found in the viscera. The vagus also sends afferent fibres to the viscera and afferent fibres of other cranial nerves, especially

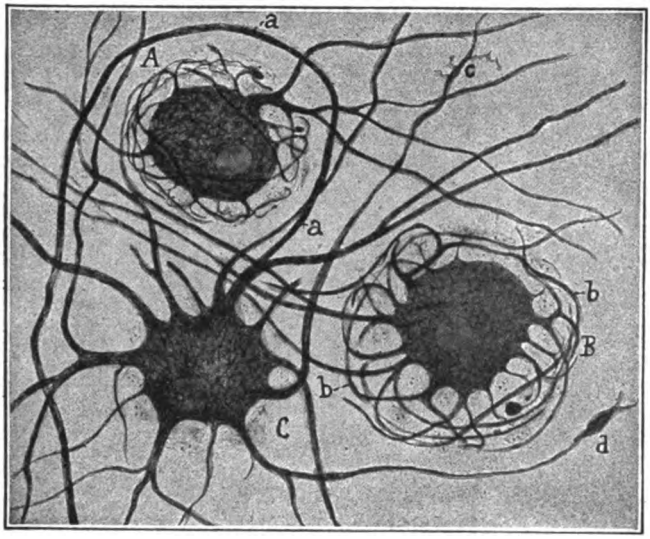

FIG. 312.—Sympathetic Nerve Cells (woman of 36 years). (Cajal.) *A* and *B*, cells whose dendrites (*b*) form a pericellular plexus. *C*, cell with long dendrites. *a*, axone; *c* and *d*, terminal part of a dendrite. The capsular cells are faintly indicated. (Cajal's silver stain.)

the trigeminus, travel with sympathetic fibres in the head. Some authorities maintain that there are also afferent sympathetic ganglion cells, the central processes of which, however, do not enter the central nervous system but terminate in the spinal ganglia.

The cells of type *b* in the spinal ganglia (p. 440) may be among those sending their processes to receptors in the viscera and in such cases the visceral stimulus might in certain cases, be transferred also to another spinal ganglion cell connected with the outer body wall thus accounting for referred pains. (See also Fig. 310.)

The larger sympathetic ganglia resemble the spinal ganglia in having a connective-tissue capsule and framework. The cells are smaller and often pigmented. Each cell is surrounded by a capsule of cells similar to those surrounding the spinal ganglion cells. Often two or three cells and their interlocked dendrites are enclosed within a common capsule (Fig. 313, *A*).

The typical sympathetic nerve cell is a multipolar cell with short branching dendrites confined to the capsule of the cell and often inter-

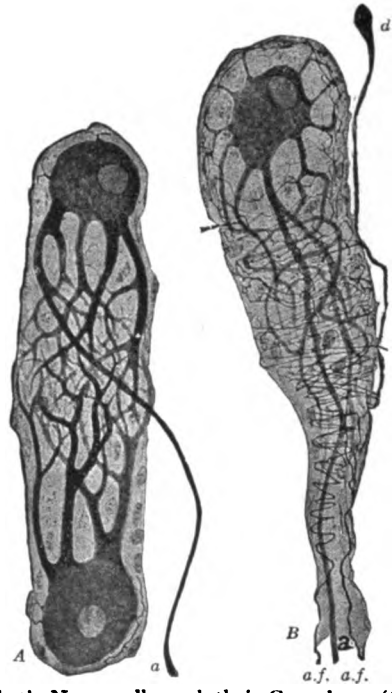

FIG. 313.—Sympathetic Nerve-cells and their Capsules. (Cajal.) *A*, Two-celled glomerulus; *B*, cell surrounded with the pericellular terminal arborizations of two fibres (*a.f.*) passing to the cell; *a*, axones; *d*, fibre, probably dendritic, with bulbous termination. (Cajal's silver stain.)

locked with the dendrites of adjacent cells, forming glomeruli. Sometimes a dendrite will pass some distance from the cell, arborize, and interlock with a similar dendritic arborization of another cell. Another form of sympathetic cell has long slender dendrites often indistinguishable from axones. These cells are more frequent in the terminal ganglia. Some of these cells have been considered to be afferent sympathetic cells. (Figs. 312 and 313.) The majority of the axones of the sympathetic ganglion cells are non-medullated but

a considerable number are provided with a medullary sheath. This is especially the case with those of the ciliary ganglion.

The sympathetic cells receive fibres which form arborizations around and within their capsules and also around the long dendrites. Many of these are terminations of the visceral cerebro-spinal efferent neurones, *i.e.*, the preganglionic fibers (Figs. 310 and 312, *B*).

As already noted, the axones of the efferent sympathetic cells terminate in the following effectors: heart muscle (cardio-motor), smooth muscle of viscera (viscero-motor), of blood-vessels (vaso-motor) and of hairs (pilomotor), glandular epithelia (secretory) and, finally, striated voluntary muscle. In heart muscle (Fig. 314) and in smooth muscle (Fig. 315) the nerves of the sympathetic system end in simple arborizations the fibrils terminating in slight enlargements which are in relation with the muscle cells. Satisfactory differentiation between efferent terminals and afferent terminals in heart and in smooth muscle has not yet been made. The sympathetic terminations in voluntary striated muscle are motor end plates similar to those described below (p. 456) for the efferent peripheral somatic neurones but smaller and simpler.



FIG. 314.—Nerve Endings on Heart Muscle Cells. (From Barker, after Huber and De Witt.)

In organs whose parenchyma is made up of glandular epithelium, the sympathetic nerves terminate mainly in *free endings* which lie

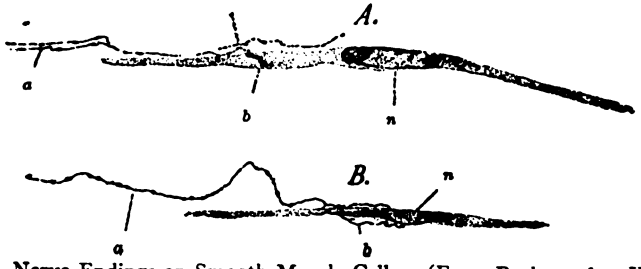

FIG. 315.—Nerve Endings on Smooth Muscle Cells. (From Barker, after Huber and De Witt.) *a*, Axis cylinder; *b*, its termination; *n*, nucleus of muscle cell.

in the cement substance between the cells, thus coming in contact with, though not penetrating, the epithelial cells.

TECHNIC

(1) Fix spinal and sympathetic ganglia in formalin-Müller's fluid (technic 6, p. 7). Stain sections with hæmatoxylin-eosin (technic 1, p. 20), or with hæmatoxylin-picro-acid-fuchsin (technic 3, p. 24).

(2) Fix spinal and sympathetic ganglia in absolute alcohol or in 10-per cent. formalin, and stain sections by Nissl's method (technic, p. 39).

(3) See also technic 1, p. 20.

(4) Ganglia should also be prepared by Cajal's silver method, using the alcohol fixation (p. 38).

EFFERENT PERIPHERAL SOMATIC CEREBRO-SPINAL NEURONES

It has been seen that the bodies of these neurones lie in the ventral part of the neural tube where they form a part of the ventral gray column in the cord (pp. 426–8), and the motor nuclei of cranial nerves in the segmental brain. The axones of these cell bodies form part of the efferent roots and efferent fibres of the peripheral nerves and

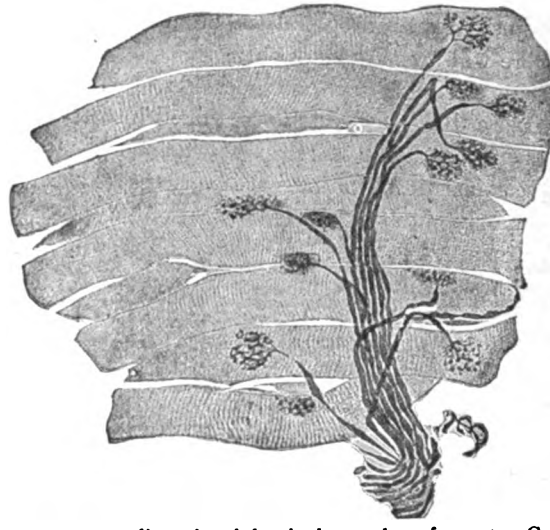

FIG. 316.—Motor nerve-endings in abdominal muscles of a rat. Gold preparation. ×170. (Szymonowicz.)

terminate in the striated voluntary muscles of the body and head. In the spinal nerves these fibres pass beyond the spinal ganglia and then join the afferent fibres; in some cranial nerves they pass out with the afferent fibres. On their way to the muscles the motor axones may bifurcate several times, thus allowing one neurone to innervate more than one muscle fibre. On the other hand a single muscle fibre may be innervated by more than one root fibre—even by fibres from different segments of the cord (Agduhr). In the perimysium the nerve fibres undergo further branching, after which the fibres lose their medullary sheaths and pass to the individual

muscle fibres. Here each fibre breaks up into several club-like terminals. These terminals are imbedded in a nucleated protoplasmic mass on the outside of the muscle fibre and probably composed of sarcoplasm. It is stated that the neurilemma of the nerve fibre is continuous with the sarcolemma and that a continuation of the sheath of Henle covers the whole structure which is known as the *motor end plate.* (Fig. 316.) The number of medullated fibers in the ventral spinal roots has been estimated to be in man about 400,000 on one side. (Ingbert).

It will be seen from the above that all the various activities of the nervous system can only take effect by the impulses passing out by the peripheral efferent neurones, somatic and splanchnic. These neurones thus constitute the *final common pathway* (Sherrington).

Injury to these neurones (*e.g.*, cutting ventral root fibres) gives rise to a loss or diminution of function of the effectors they innervate. In the case of striated voluntary muscle there is complete loss of tone and a degenerative atrophy of the muscle fibres. Accordingly the neurones in question are said to exercise a tonic and "trophic" influence upon the muscle. There is of course a loss of reflex and voluntary muscular contraction and also, concomitantly with the atrophy, a loss of contraction to direct stimulation. The somatic neurone produces the contraction of the muscle and probably plays the major part in maintaining tonus and "trophism." The rôle of the sympathetic neurone innervating the striated voluntary muscle fibre is more obscure. Some observations tend to show that it plays a part in maintaining tonus but this has been disputed. *A priori* one would expect it to exert a trophic influence and it has been thought that it is in especial connection with the sarcoplasm of the muscle fibre. The effect upon the visceral effectors (cardiac and smooth muscle and glands) of cutting the sympathetic is naturally a more or less lasting disturbance of function and, in the case of smooth muscle, loss of tone, shown by circulatory changes and diminished secretory activity.

THE CENTRAL NERVOUS SYSTEM

THE SPINAL CORD

The spinal cord encased in its membranes lies loosely in the vertebral canal, extending from the upper border of the first cervical vertebra to the middle or lower border of the first lumbar vertebra. It is cylindrical in shape and continuous above with the medulla oblongata, while below it terminates in a slender cord, the *filum terminale.* At two levels, one in its cervical and one in its lumbar region, the diameter of the cord is considerably increased. These are known, respectively, as the *cervical* and *lumbar enlargements.*

The spinal nerve roots leave the cord at regular intervals, thus indicating a division of the cord into segments, each segment extending above and below it nerve roots one-half the distance to the next adjacent roots. There are 31 segments corresponding to the 31 spinal nerves; 8 cervical, 12 thoracic, (older term "dorsal") 5 lumbar, 5 sacral, and 1 coccygeal (usually indicated by abbreviations C, Th (or D), L and S.

Origin of the Fibres which Make up the White Matter of the Cord

It has already been observed that the white matter of the cord is composed mainly of medullated nerve fibres, most of which run in a longitudinal direction and form the white columns or funiculi of the cord (p. 426). From the study of the neurone it follows that each of these fibres must be the axone of some nerve cell. The bodies of these cells, the medullated axones of which form the white columns of the cord, are situated as follows:

A. Cell bodies outside the spinal cord. (*Extrinsic cells.*)
   (1) Cell bodies outside the central nervous system (spinal ganglion cells).
   (2) Cell bodies in other parts of the central nervous system (in the brain).

B. Cell bodies situated in the gray matter of the cord. (*Intrinsic cells.*)
   (3) Cell bodies in the gray, whose axones form the ventral root (root cells). These axones pass out directly, and thus do not become longitudinal column fibres.
   (4) Cell bodies whose axones enter into the formation of the fibre columns of the cord (column cells.)
   (5) Cell bodies the axones of which ramify in the gray matter (Golgi, type II). (These cells do not give rise to fibres of the white matter, but are conveniently mentioned here among the other cord cells.)

(1) The Spinal Ganglion Cells and the Origin of the Dorsal Columns

It has already been seen that the central processes of these cells enter the cord as dorsal root fibres and split into ascending and descending longitudinal arms composing the greater part of the dorsal white column and the zone of Lissauer. They are described more in detail later (pp. 474 *et seq.* and 485).

(2) Cells Situated in Other Parts of the Central Nervous System which Contribute Axones to the White Columns of the Cord.

The bodies of these cells are situated in the precentral (motor) areas of the cortex of the pallium, in the midbrain, cerebellum(?), and various parts of the segmental brain (tegmentum and bulb). The axones of these cells pass down the cord, forming the descending fibre tracts of the cord (p. 492). Collaterals and terminals of these fibres enter the gray matter of the cord to terminate there.

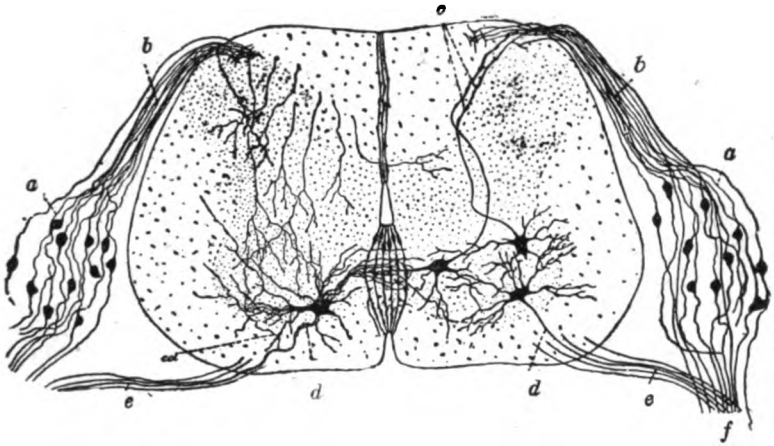

Fig. 317.—Transverse Section through Spinal Cord and Dorsal Root Ganglia of an Embryo Chick. (Van Gehuchten.) (*a*), Spinal ganglion, its bipolar cells sending their peripheral processes outward to become fibers of the mixed spinal nerve (*f*), their central processes into the dorsal columns of the cord as the dorsal root fibres (*b*); within the dorsal columns these fibres can be seen bifurcating and sending collaterals into the gray matter of the cord, one collateral passing to the gray matter of the opposite side. The rare efferent fibres of the dorsal root (*c*) are disproportionately conspicuous. The large multipolar cells of the ventral horns are seen sending their acones (*d*) out of the cord as the ventral root fibres (*e*) which join the peripheral processes of the spinal ganglion cells to form the mixed spinal nerve (*f*); *col*, collateral from axone of ventral horn cell. Dendrites of the ventral horn cells are seen crossing the median line in the ventral commissure. About the centre of the cord is seen the central canal; dorsal and ventral to the latter are seen some ependymal cells stretching from the canal to the periphery of the cord.[1] The preganglionic sympathetic neurones are not shown. (Golgi Method.)

(3) Ventral Root Cells: Motor Cells of the Ventral Horn and Preganglionic Sympathetic Cells

These cells send their axones either directly out to voluntary striated muscles or to sympathetic ganglia as already described

[1] What are designated as "white columns" in this and following figures of preparations from embryos are in reality the marginal zones which only contain at this period of development young non-medullated axones. The "white" columns, strictly speaking, only exist when these axones become medullated.

(p. 448) and consequently only pass transversely through the white columns. The bodies are described on pp. 470–472.

(4) Column Cells

These are cells the bodies of which lie in the gray matter of the cord and send their axones into the white columns or funiculi (see p. 472) where they either bifurcate or turn up or down, becoming longitudinal fibres. Some of the cells send their axones into the

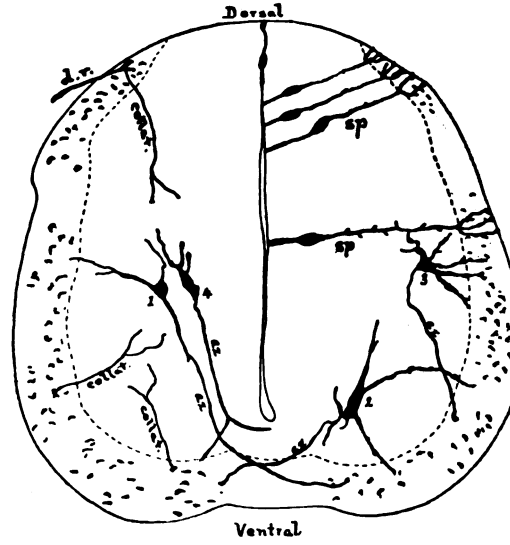

Fig. 318.—Transverse Section through Spinal Cord of Embryo Chick of Seven Days Incubation (Golgi Preparation). The boundary between the mantle zone (future gray) and marginal zone (future white) is indicated by the dotted line. 1 and 2, heteromeric column cells whose axones (*ax*) pass through the ventral or anterior commissure to the opposite ventral white columns; 3, tautomeric column cells whose axone (*ax*) passes to the ventro-lateral white column on the same side; 4, hecateromeric column cell whose axone (*ax*) bifurcates, one branch entering the ventral white column of the same side and the other branch passing through the anterior commissure to the opposite side. A number of longitudinal fibres in the white columns are shown, cut transversely or obliquely. Three collaterals (*collat.*) are shown on the left, one from a dorsal root fibre (*d.r.*). Four spongioblasts (*sp*) are shown on the right. See footnote p. 459.

white matter of the same side of the cord. These are known as *tautomeric* (*ipsilateral* or *homolateral*) *cells* (Fig. 318, 3). Others send their axones as fibres of the ventral commissure to the white matter of the opposite side of the cord. These are known as *heteromeric* (*heterolateral*) *cells* (Fig. 318, 1 and 2). The axones of a few cross in the dorsal white commissure. In a few others the axone divides,

one branch going to the white matter of the same side, the other to the white matter of the opposite side. These are known as *hecateromeric cells* and are comparatively rare, (Fig. 318, 4).

The axones of many of the column cells are short, constituting the *short fibre tracts* (spino-spinal tracts, fundamental columns or ground bundles) of the cord (see page 497) others form *long ascending fibre tracts*, passing up through the cord to the brain (see page 485). Terminals and collateral branches of these longitudinal axones, especially of the short ones, are constantly re-entering the gray matter to end in arborizations around the nerve cells (FIG. 319).

(5) CELLS OF GOLGI TYPE II

The axones of these cells do not leave the gray matter, but divide rapidly and terminate in the gray matter near their cells of origin, some crossing to terminate in the gray matter of the opposite side.

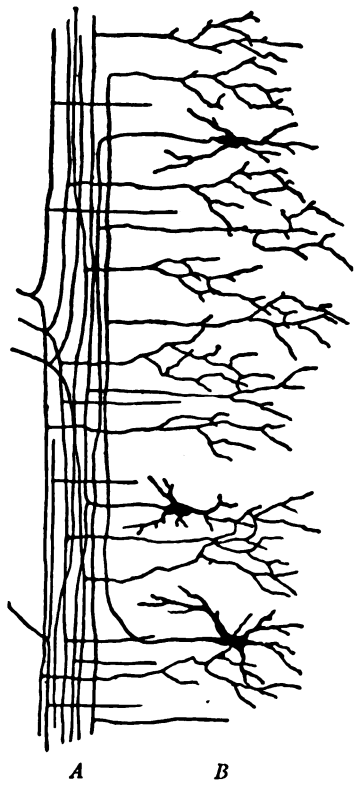

FIG. 319.—From Longitudinal Section of Spinal Cord of Embryo Chick. (Cajal.) *A*, White column of cord; *B*, gray matter. The cells of the gray matter (column cells) are seen sending their axones into the white matter, where they bifurcate, their ascending and descending arms becoming fibres of the white column. The dendrites of these cells are seen ramifying in the gray matter. To the left are seen fibres (dorsal root fibres) entering the white matter and bifurcating, the ascending and descending arms becoming fibres of the white column. From the latter are seen fibres (collaterals and terminals) passing into the gray matter and ending in arborizations (Golgi Method).

TECHNIC

(1) For the purpose of studying the spinal ganglion cell with its processes and their relations to the peripheral nerves and to the cord, the most satisfactory material is the embryo chick of six days' incubation, treated by the rapid silver method of Golgi (technic b, p. 36). Rather thick (75μ) transverse and longitudinal sections are made and mounted in balsam without a cover-glass. Owing to the uncertainty of the Golgi reaction, several attempts are frequently necessary before good sections are obtained.

(2) The root cells of the anterior horn with their axones passing out of the cord and joining the peripheral processes of the spinal ganglion cells to form the spinal nerves, can usually be seen in the transverse sections of the six-day embryo chick cord prepared as above, technic (1).

(3) For studying the column cells of the cord, embryo chicks of from five to six days' incubation should be treated as in technic (1). Owing to the already mentioned uncertainty of the Golgi reaction, it is usually necessary to make a large number of sections, mount ng only those which are satisfactorily impregnated. It is rare for a single section to show all types of cells. Some sections contain tautomeric cells, some contain heteromeric, some both, while in very few will the hecateromeric type be found.

Sections containing fewest impregnated cells frequently show collaterals to best advantage. These are seen as a fringe of fine transverse fibres crossing the boundary line between gray matter and white matter.

The blood vessels often take a brown stain with the Golgi method and appear as coarse anastomosing brownish or black bands easily distinguished from the finer, black, non-anastomosing nerve fibres.

(4) The silver method of Cajal, using the alcohol fixation (technic 2, p. 39), and the method of Bielschowsky may also be advantageously used to display many of the above details of structure in embryo chicks. They are also capricious.

Whole neurones with long axones obviously cannot be directly demonstrated in single sections. To demonstrate these serial sections and indirect methods (degeneration, etc.) are used (see Fibre Tracts of Cord, p. 479 and General Methods, etc., p. 621).

PRACTICAL STUDY

Transverse Section of Six-day Chick Embryo (Golgi preparation).—Using a lower-power objective, first locate the cord and determine the outlines of gray matter and white matter (see Footnote, p. 459). Observe the spinal ganglia lying one on either side of the cord (Fig. 317, *a*). At least one of the ganglia will probably show one or more bipolar cells, sending one process toward the periphery, the other toward the spinal cord. Note that the peripheral process is joined, beyond the ganglion, by fibres which come from the ventral region of the cord (fibres of the ventral root). In some specimens the latter can be traced to their origin in the cells of the ventral horn (Fig. 317, *d*). The union of the peripheral processes of the spinal ganglion cells and the ventral horn fibres is seen to make up the mixed spinal nerve (Fig. 317, *f*). Observe the central processes of the spinal ganglion cells entering the dorsal column of the cord and bifurcating (Fig. 317, *b*). As these branches pass up and down the cord, only a short portion of each can be seen in a transverse section. Note the fibres (collaterals) passing from the white matter into the gray matter. The fact that they are finer than the longitudinal fibres in the white matter shows that they are branches of the latter. Even in transverse section the point at which they leave the latter may occasionally be made out. Note in some of the sections a little round mass just ventral and to the inner side of the spinal ganglion, in which nerve cells may be seen, and some fibres passing into or out of it. This represents the beginning of the sympathetic system with its chain of ganglia. Note the relation which this bears to the spinal cord and spinal ganglia.

In the same or other transverse sections study the column cells of the cord,

carefully distinguishing between the dendrites and axone. This is not always easy, but the axone can usually be distinguished as being more slender, with smoother outline and more uniform size throughout its course. Axones may come off from dendrites as well as from the cell bodies. At least one tautomeric and one heteromeric column cell should be found and studied (Fig. 318). Study also the collaterals if they are stained. Remember that only a few of the elements present are stained in Golgi preparations and that there are apt to be present irregular silver precipitates without any significance. Capillaries often appear as a coarse brown-stained meshwork.

Study also any spongioblasts that may be stained. Those with nuclei near the central canal give a fair representation of the ependyma cells of the adult cord, except the cell does not usually in the latter extend entirely through the wall of the neural tube.

Longitudinal Section of Six-day Chick Embryo (Golgi preparation).—Using a low-power objective locate gray matter and white matter and identify plane of section relative to transverse section above described. Note in the white matter longitudinally running fibres from which branches pass off into the gray matter (Fig. 319). The longitudinal fibres of the dorsal columns are the ascending and descending branches of the central processes of the spinal ganglion cells, and the branches passing into the gray matter are their collaterals and terminals. If the section happens to include the entering fibres of a dorsal root, these can be seen branching in the posterior columns into ascending and descending arms (Fig. 318). The longitudinal fibres of the lateral and ventral columns are axones of column cells and of cells situated in higher centres (see pages 459 and 460). These also send collaterals and terminals into the gray matter.

General Topography of the Cord, General Structure of Gray and White Matter, Cell Groups and Arrangement of Fibres

The further description of the cord is best combined with the practical study of sections of the cord, taking sections through the lumbar enlargement as a type.

PRACTICAL STUDY OF SECTIONS THROUGH LUMBAR ENLARGEMENT

General Topography (Figs. 320 and 321).—The general features of the sections can be best seen with the naked eye or with a low-power dissecting lens.

Note the *shape* and *size* of the cord, and that it is surrounded by a thin membrane, the *pia mater spinalis;* the deep *ventral median fissure,* into which the pia mater extends; the *dorsal median septum* consisting principally of neuroglia, over which the pia mater passes without entering; and the *dorso-lateral grooves* or *sulci* at the entrance of the posterior root fibres. The *gray matter* is seen in the central part of the section (stained more lightly in the Weigert myelin preparation, on account of the presence of numerous unstained cell bodies and

dendrites) and arranged somewhat in the form of the letter H. Dorsally the gray matter extends almost to the surface of the cord as the *dorsal gray columns* (*posterior horns* or *cornua*). The *ventral gray columns* (*anterior horns*) are, on the other hand, short and broad, and do not approach the surface of the cord. Surrounding the gray matter is the *white matter* (stained deep blue in the Weigert preparation on account of the absence of the cell bodies and dendrites present

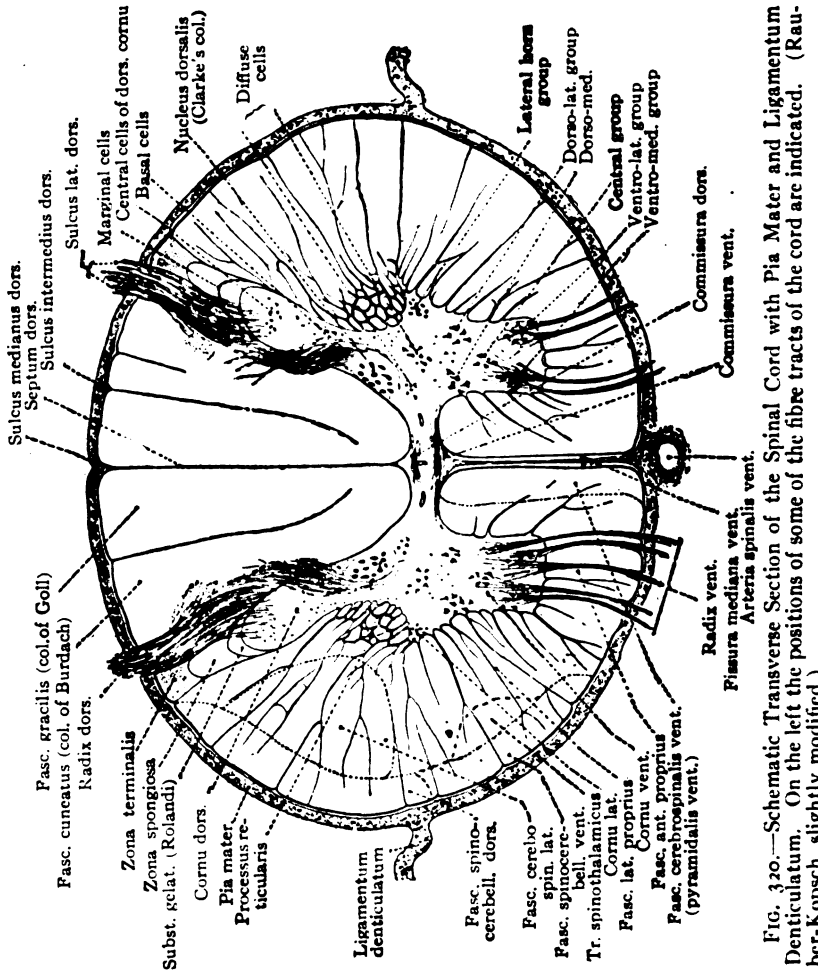

FIG. 320.—Schematic Transverse Section of the Spinal Cord with Pia Mater and Ligamentum Denticulatum. On the left the positions of some of the fibre tracts of the cord are indicated. (Rauber-Kopsch, slightly modified.)

in the gray and not staining with the Weigert myelin method). This is divided by the dorsal horn into two parts, one lying between the horn and the dorsal median septum, the *dorsal funiculus* (*dorsal* or *posterior white column*); the other comprising the remainder of the white matter, the *ventro-lateral funiculus* (*ventro-lateral* or *antero-lateral white column*). Between the two and lying between the dorsal gray column and the periphery of the cord is the fine-fibred *zone of Lissauer*. The ventro-lateral white column is again divided by the

ventral horn and nerve roots into a *lateral funiculus* (*lateral white column*) and a *ventral funiculus* (*ventral* or *anterior white column*). In the concavity between the ventral and dorsal horns some processes of the gray matter extend out into the white matter where they interlace with the longitudinally-running fibres of the latter to form the *reticular process* (not well marked in the lumbar cord).

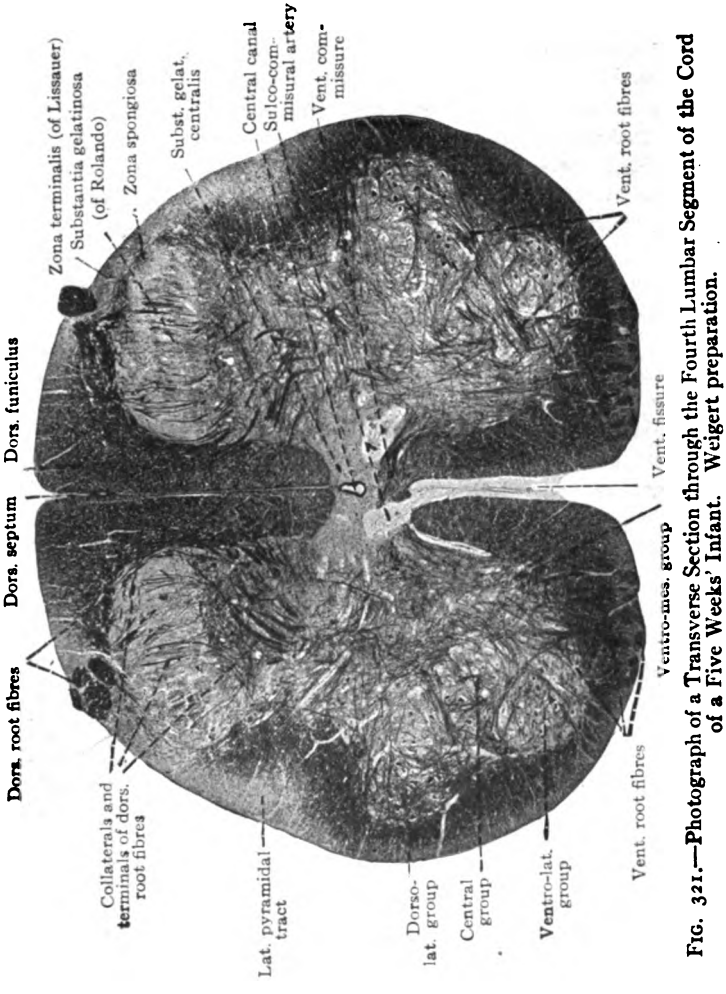

FIG. 321.—Photograph of a Transverse Section through the Fourth Lumbar Segment of the Cord of a Five Weeks' Infant. Weigert preparation.

In the thoracic segments of the cord there is usually a lateral protrusion of the gray matter slightly dorsal to the dorsal boundary of the ventral horn and not to be confused with the lateral protrusions of the latter in the cervical and lumbar enlargements. This is called the *lateral horn* (Figs. 320 and 322).

For the study of further details the low-power objective should be used.

GRAY MATTER.—In the cross portion of the H is seen the *central canal*, usually obliterated in the adult and represented only by a group of epithelial cells.

The central canal divides the gray matter connecting the two sides of the cord into a *ventral gray commissure* and a *dorsal gray commissure*. Immediately surrounding the epithelial cells is a light granular area composed mainly of neuroglia and known as the *central gelatinous substance* or *central gray*. Toward the surface of the cord the posterior horn expands into a *head* or *caput*, external to which is an area similar in general appearance to that surrounding the central canal, the *gelatinous substance of Rolando*. The head is connected with the base of the dorsal horn by a narrower *neck* or *cervix*. External to the gelatinous substance of Rolando is a thin zone containing a plexus of fine medullated fibres (Weigert stain) known as the *zona spongiosa*, and external to this, occupying the space between it and the periphery, is a zone composed of fine longitudinal medullated fibres rather sparsely arranged and therefore staining more lightly with the Weigert method. This is the zona terminalis or zone of Lissauer already mentioned and which belongs obviously to the white matter of the cord (see p. 475). The portion of the gray matter connecting the dorsal and ventral horns may be termed the *intermediate* or *middle* gray. Note the well-defined groups of large nerve cells in the anterior horns and the fibres passing out from the anterior horns to the surface of the cord, *ventral* (*anterior*) *nerve roots*. In most of the thoracic segments of the cord a more or less well-defined *lateral horn* may be seen (Figs. 320 and 322).

WHITE MATTER.—Note the general appearance of the white matter and the disposition of the supporting strands of neuroglia tissue (light in the Weigert, usually darker in other stains). The neuroglia is seen to form a fairly thick layer just beneath the pia mater from which trabeculæ pass in among the fibres, the broadest strand forming the posterior median septum. If the section has been cut through a *dorsal* (*posterior*) *nerve root*, a strong bundle of *dorsal root fibres* can be seen entering the white matter of the cord along the dorsal and mesial side of the posterior horn. Just ventral to the anterior gray commissure is a bundle of transversely-running medullated fibres—the *ventral white commissure*. (Fig. 321.) It is composed principally of the decussating axones of various heteromeric column cells and possibly of decussating collaterals of various fibres. In the dorsal part of the dorsal gray commissure are also fine transversely running medullated nerve fibres—the *dorsal white commissure*. It consists of collaterals of fibres in the dorsal and lateral funiculi and axones of heteromeric column cells.

General Structure of Gray and White Matter (Substantia grisea and Substantia alba).—The gray and white matter is composed of nervous elements and neuroglia, both ectodermal, and mesodermal elements (blood-vessels, etc.).

(a) *The Nervous Elements.*—In the gray matter are all the nerve cell bodies and dendrites and portions of nerve fibres both medullated and non-medullated. The portions of nerve fibres are those parts passing from the cell bodies to the white matter and the terminal portions of fibres passing from the white matter into the gray to terminate there. All synapses are thus in the gray. What portions of this plexus of dendrites and fibres are seen in preparations depends upon the method of staining. In Cajal silver preparations portions of dendrites and axones appear as brown fibres of varying lengths crossing in various direc-

tions. In Weigert's myelin stain only the myelin sheaths of the medullated fibres are clearly visible and present the characteristic appearance of blue fibres crossing in various directions. In the Nissl stain most of the dendrites and fibres are nearly invisible, only chromophilic bodies and nuclei of various cells (see below) being stained.

The white matter, as a rule, contains no neurone bodies nor dendrites, the nervous elements being thus confined to portions of medullated and non-medullated fibres and their branches. These fibres in the cord are in the main longitudinal but with many transverse fibres running to and from the gray matter. There is a thin external layer containing no nerve fibres and known as the marginal glia (see below). In transverse sections stained with axis-cylinder stains such as the Cajal silver stain each axis-cylinder of the longitudinal fibres appears as a small round object surrounded by a clear ring representing the unstained or dissolved out myelin (Fig. 324). In the Weigert myelin stain the transversely cut medullated longitudinal fibres appear as blue rings, the myelin sheaths, enclosing the usually unstained axis-cylinders.

(b) *The Neuroglia.*—This has been seen to consist of branching, probably anastomosing cells with their nuclei and granular cytoplasm, of fine, unbranched neuroglia fibres and of a more homogeneous substance representing either an exoplasm or an intercellular matrix. There are also a few round, unbranched neuroglia cells. The neuroglia may be divided, according to its location, into three portions: the ependyma, the diffuse glia, and the marginal glia (Held). The ependyma is composed of the ependyma cells lining the cavities of cord and brain. They are elongated cells, vertical to the cavity and resembling columnar epithelial cells in ordinary stains but their basal ends extend some distance into the wall of the neural tube and branch, joining the diffuse glia network. They are practically spongioblasts (embryonic neuroglia cells) which have retained their primitive form, largely, and their original position next to the lumen of the neural tube. They contain glia fibres. In the adult cord the lumen of the canal is frequently closed and the ependyma cells are represented by a mass of apparently rounded cells. Near the central canal, in the central gelatinous substance are often seen small groups or nests of glia cells. The diffuse glia extends through the wall of the neural tube (gray and white matter) and envelopes the neurone bodies, dendrites and nerve fibres. In certain preparations this envelope appears like a network. It is not entirely certain whether the apparent anastomoses of glia cells with each other consist of anastomoses of their granular cytoplasm or whether it is more a coagulum of the exoplasm or matrix. Neuroglia fibres are imbedded in the glial meshwork but it is doubtful whether they are always in contact with the granular protoplasm of the glia cells. The marginal glia is that glia occupying the thin peripheral zone which is destitute of nervous elements and is therefore composed solely of glia except where penetrated by blood-vessels. The glia here also consists of branched glia cells, glia fibres and a probable matrix. According to some of the most careful investigators, the glia forms everywhere a limiting membrane, the *membrana limitans gliæ*, which is the boundary of the nervous tissue lying immediately beneath the pia mater and next to the adventitia of the blood-vessels which enter the nervous system. This membrane is supposed to be continuous in normal conditions and

consequently the adventitial lymph spaces or any other lymph spaces outside the nervous system would not have any continuations passing in between the nervous elements. The question as to what channels are followed by the lymph or

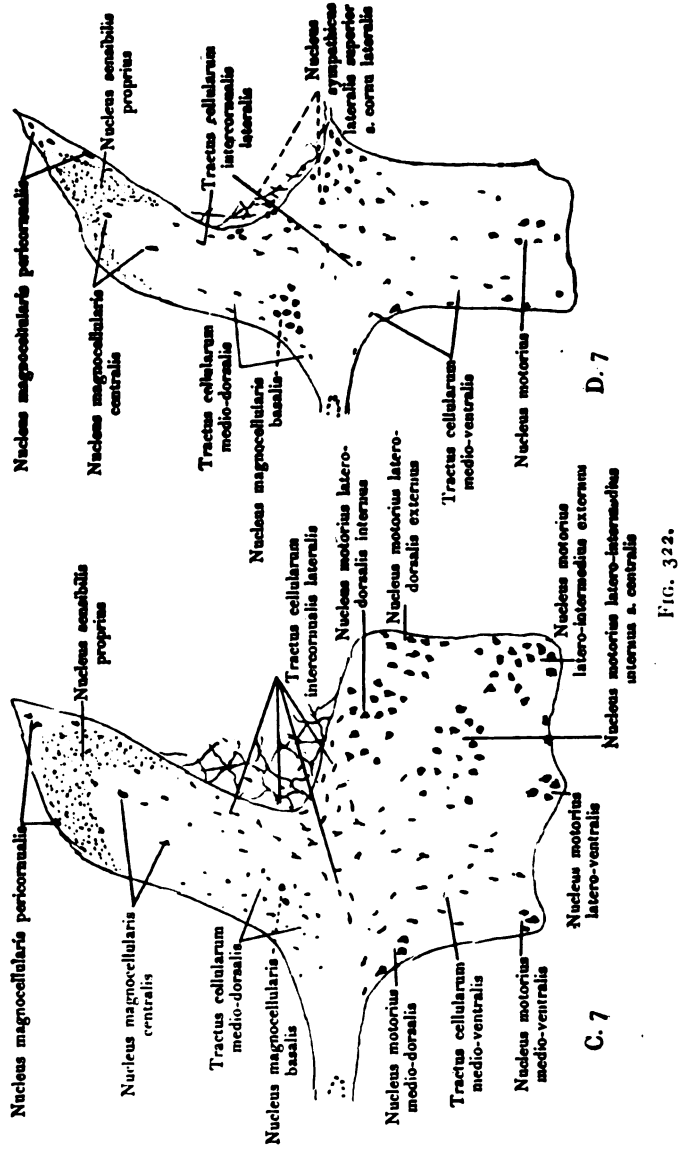

FIG. 322.

lymph-like fluids in the central nervous system is however, still rather obscure (p. 434).

If we regard the neurolemma cell as a kind of peripheral glia cell, the neuro-

lemma membrane would represent the glial membrane and each peripheral nervous element would be thus separated from the mesodermal structures.

(c) *The Mesodermal Elements.*—These are comprised largely or entirely by

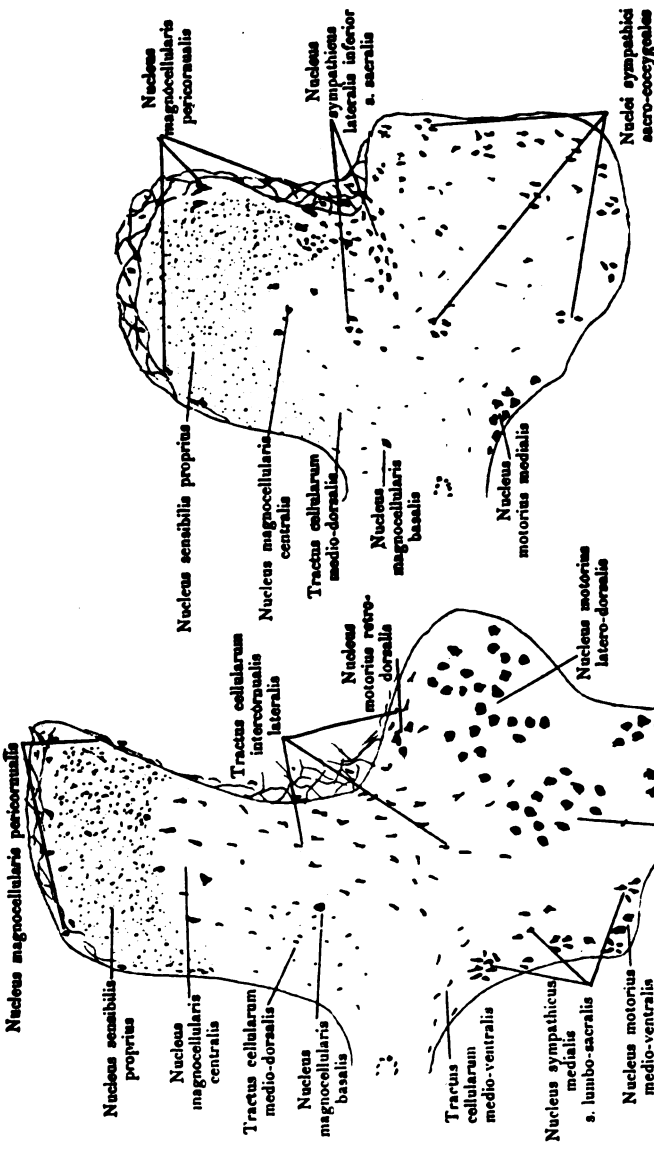

FIGS. 322 and 323.—Sections of the 7th Cervical, 7th Thoracic, 5th Lumbar and 4th Sacral Segments of the Spinal Cord, showing the Cell Groups. (L. Jacobsohn.) *Tractus cellularum*, diffuse cells.

the elements composing the blood-vessels which penetrate the central nervous system. They have much the same structure as blood-vessels elsewhere. The presence of the adventitial or Virchow-Robin lymph space has been noted

(p. 434). According to good authorities there is no true perivascular space *i.e.*, a space between adventitia and glial membrane. Connective tissue septa from the pia are usually described penetrating the nervous system. It is doubtful whether there are such true connective tissue septa except in the vicinity of blood-vessels.

In ordinary stains, such as hæmatoxylin-eosin, and in the Nissl stain numerous nuclei are seen in both gray and white matter other than those in the gray which obviously belong to nerve-cells. In the gray matter the nuclei of the majority of the nerve cells except those in the gelatinous substance of Rolando are of the vesicular type, *i.e.*, clear nuclei with one or two distinct nucleoli. Some very small nerve cells, such as those composing the bulk of the gelatinous substance of Rolando (cells of Gierke) have more deeply staining nuclei with chromatin network which cannot be easily distinguished from the neuroglia nuclei. Aside from these, the apparently "free" nuclei seen belong principally to the neuroglia cells, others are nuclei of the endothelial cells and other connective tissue and smooth muscle cells forming the walls of the blood-vessels and the nuclei of leucocytes within the blood-vessels. In the white matter where there are no nerve cell bodies all nuclei must belong either to glia cells or to the above-mentioned vascular elements. The neuroglia nuclei vary from small, deeply staining nuclei to larger, paler nuclei with a few more or less distinct nucleoli. The structure of the blood-vessels and pia (see p. 432) should be carefully studied in the various preparations.

Cell Groups (Nuclei, Neurone body Groups).—The positions and groupings of the various cell bodies should now be studied. (Nissl, Hæmatoxylin-Eosin, Cajal stains, Figs. 320, 321, 322 and 323).

The cell groups of the cord vary somewhat according to various authors. The following are largely those given by Jacobsohn. The division of the cell bodies into groups is based upon their location in separate areas and their character (size, shape and internal structure). As will be seen, the groups also correspond in many cases to differences of distribution of their axones. For convenience their general arrangement throughout the cord is given and also the probable courses of many of their axones, though these can only be demonstrated by other preparations and methods.

A. Root Cells (Efferent Peripheral Neurones)

(1) Nuclei Motorii Cornu Ventralis.—These are the groups of somatic motor cells located in the ventral gray column or horn of the cord, the axones of which pass without interruption to voluntary striated muscle. They are the largest cells of the cord with many large well-defined Nissl bodies. They consist of the following groups and subgroups:

(a) *Medial Cell Group* or cell column, often subdivided into dorsal (dorso-medial or medio-dorsal) and ventral (ventro-medial or medio-ventral) groups. This group extends practically throughout the cord, from C_1 to S_4 except in C_7 and C_8 and in L_5, S_1 and S_2 where it is nearly or entirely absent. It innervates the dorsal trunk musculature (via the dorsal spinal branch) and probably also the ventral trunk musculature.

(b) *Lateral Cell Group*, subdivided into three larger, constant groups and two smaller groups. The first three are the (ba) ventro-lateral or latero-ventral, (bb) dorso-lateral or latero-dorsal and (bc) central (latero-internal or latero-central) groups (Fig. 322), and the last two a (bd) ventral (L_3 and L_4) and (be) retrodorsal group (Fig. 323). The lateral cell group (or groups) is not present in most of the thoracic cord nor below S_3. It is therefore divisible into a cervico-thoracic portion (C_1 to Th_2) and a lumbo-sacral portion ($L_1 - S_3$). The uppermost segments of the cervico-thoracic portion (C_1 to C_4 or C_5) innervate principally the neck musculature, and the lowermost segments ($C_5 - Th_2$) the muscles of the upper extremitv. The lumbo-sacral portion innervates the muscles of the lower extremity. There is some uncertainty about the exact innervation of various muscles or muscle groups by the subgroups of the lateral cell group but in a general way the more external or lateral of the groups appear to innervate

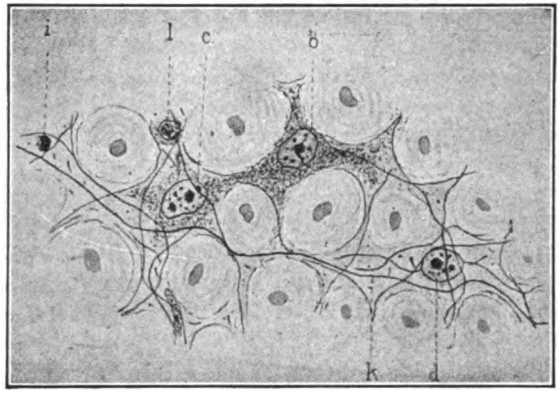

FIG. 324.—From Transverse Section of Elephant's Cord. (Hardesty.) Benda's Neuroglia Stain. *b*, *c*, *d*, and *i*, Four types of neuroglia cells; *k*, neuroglia fibre passing through several neuroglia cells; *l*, leucocyte.

the more distal muscles, and the more dorsal groups the more ventral muscles *i.e.*, the muscles derived from the more ventral parts of the myotome. The largest motor cells are in the lumbo-sacral ventral horn, the next largest in the cervical ventral horn. The size of the cells and their axones are probably correlated with the length of the axones and the number of muscle fibres supplied by each axone. Special groups which may be mentioned are the *phrenic* group (C_4), centrally situated (latero-internal group), to the diaphragm, and the *nucleus accessorius* ($C_1 - C_6$) more laterally located, to part of the trapezius and to the sterno-mastoid muscles.

2. NUCLEI SYMPATHICI (PREGANGLIONIC SYMPATHETIC NEURONES). These are the neurone bodies whose axones pass out *via* the ventral roots and white rami communicantes to sympathetic ganglia (see sympathetic system, pp. 428 and 448). They are smaller than the somatic motor cells of the ventral horn, sometimes only half their size, and tend to be somewhat crowded together. Their thinner, shorter dendrites are not so conspicuous so that they often present an ovoid appearance under low powers. They are also polygonal and often much elongated in appearance, especially in the lateral horn. In Weigert

preparations the surrounding matter has a clear gelatinous appearance like that of the gelatinous substance of Rolando. The cells under low powers look homogeneous and glassy. They contain fine Nissl bodies. The cell nuclei are vesicular with well-defined nucleoli. The sympathetic nuclei may be divided into the following three groups:

(a) *Nucleus Sympathicus Lateralis Superior* or *Thoracalis* or *Cornu Lateralis* (*Intermedio-lateral group*). This nucleus begins in the caudal portion of C_8 and extends to the upper part of L_2. It is largest in $Th_3 - Th_8$ and in $Th_{11} - L_1$, especially in Th_{12}. It occupies the lateral horn and adjacent gray and also may extend somewhat dorsally to it. The cells are 12–60μ in diameter and there are 88,500 on each side (Bruce).

(b) *Nucleus Sympathicus Lateralis Inferior* or *Sacralis*.—This nucleus begins in the lower part of S_2 and extends through the remaining lower sacral and coccygeal segments. Its upper portion occupies a position similar to (a) but in the lower sacral cord it fuses with (c) and the two occupy the greater part of the ventral horn (Fig. 323).

(c) *Nucleus Sympathicus Medialis Inferior* or *Lumbo-sacralis*. This nucleus begins in L_4 and extends downward through the remaining segments of the cord. It occupies the medial part of the ventral horn and in the lower sacral segment fuses with (b) as already indicated (Fig. 323).

Of the above sympathetic nuclei (a) sends its preganglionic fibres to the vertebral and prevertebral ganglia of the thoraco-lumbar sympathetic while (b) and part at least of (c) send their axones to the pelvic ganglia of the sacral sympathetic (Fig. 311). According to some authorities preganglionic fibres pass out in the roots of the spinal accessory nerve. (For further details see Sympathetic System, pp. 448–452).

In general the cells of the sympathetic nuclei appear to show variations in number corresponding to the segments of the cord. Their separation into vascular, cardiac, gut musculature, striated voluntary musculature, pilomotor and secretory nuclei has not been successfully accomplished.

The sympathetic cells may possibly include other cells in the intermediate gray of the cord which are among those described below (paracentral groups of some authors).

B. Column Cells and Golgi's Type II

3. Nuclei Magnocellulares Cornu Dorsalis.—These nuclei comprise all those single or grouped cells in the dorsal horn which are distinguishable from the majority of the cells by their greater size and deeper stain. They fall into three groups.

(a) *Nucleus Magnocellularis Basalis* or *Spino-cerebellaris* (*Dorsal nucleus of Stilling, Column of Clarke*). This nucleus begins to be well-defined in C_8 and extends throughout the thoracic cord. It is largest in Th_{12}, large in L_1 and then diminishes, becoming indistinguishable in L_3 or L_4. In the cervical segments there are a few cells apparently of this type, especially in C_3, but no distinct group. In sections 10 to 20μ thick the number in each side of each section ranges from 3 or 4 in the upper thoracic to 10 to 15 in the middle and 20 in Th_{12}. The nucleus occupies the medial portion of the base of the dorsal horn. The

cells of Clarke's column are large, especially in the lower segments, many being nearly as large as the motor cells of the ventral horn. They are multipolar but have a spheroidal shape and a more homogeneous appearance than the latter. This last is probably due to the fact that the Nissl bodies are usually confined to the periphery of the cell. They contain considerable pigment. The cell nuclei are large, vesicular with well marked nucleoli and often eccentric in position. The axones of the cells of Clarke's column form the coarse-fibred dorsal spino-cerebellar tract to the vermis of the cerebellum. They are largely or entirely uncrossed and may be seen as coarse fibres proceeding laterally from Clarke's column to the periphery of the cord where they bend upward to form the tract.

(b) *Nucleus Magnocellularis Centralis Cornu Dorsalis* (*Solitary cells*).—The cells of this nucleus are found in all segments of the cord, are most numerous in the cervical and lumbo-sacral cord, and lie in the cervix and caput cornu dorsalis. They are either somewhat more than medium size, in which case they are often spindle-shaped, or they sometimes reach the size of the motor ventral horn cells in which case they are broader and have more numerous conspicuous dendrites. They stain deeply with Nissl's method. In sections 10–20μ thick they range from 0 to 5 or 6 on each side. They are most numerous in the lumbar and upper sacral cord.

(c) *Nucleus Magnocellularis Pericornualis* or *Perigelatinosa* (*Marginal cells, Zonal Cells*).—These cells lie between the gelatinous substance of Rolando and the marginal zone of Lissauer thus occupying the zona spongiosa. They also lie more laterally in the processus reticularis. The cell bodies are polygonal or often elongated and lying parallel with the boundary of the gelatinosa. In sections 10 to 20μ thick they range from 0 to 6 to 10 on each side, the latter numbers being usually only reached in the lumbo-sacral cord.

The destinations of the axones of groups (b) and (c) are not very definitely known. Both send many axones to the adjoining dorsal portion of the lateral column and to the opposite half of the cord *via* the ventral commissure. From their size and from analogous arrangements elsewhere it would seem probable that their axones form those long medullated ascending tracts of the cord to the brain not accounted for otherwise (spino-thalamic and ventral spino-cerebellar tracts) and it is probable that the axones of the central group at least have these destinations. On the other hand, Golgi preparations indicate that a considerable part at least of the pericornual or marginal group and many of the central group send their axones into the adjacent lateral column where there are no long tracts of this character. These may be reflex tracts. The apparently small number of these cells is also an argument in favor of their giving rise to long fibres, it being only the short fibres of a few segments in length which require many cells. An average of only one cell on each side per section of 20μ thickness would total to about 20,000 cells on each side, probably not far from an adequate number for the tracts in question (the lateral pyramidal tracts have 60,000 or so fibres on each side). The apparent over-representation of groups (b) and (c) as well as other groups mentioned above, in the lumbo-sacral cord is not only due to the more massive peripheral structures (lower extremities) innervated but also to the fact that the lumbo-sacral segments are the shortest

of the cord and this necessitates a greater number of cells in each cross section to bring up the total.

4. Nucleus Sensibilis Proprius. (Cells of the Substantia Gelatinosa of Rolando).—This nucleus is largest in the first cervical and lumbo-sacral segments of the cord. It is present in all segments and varies in size *pari passu* with the size of the dorsal roots, the increased size in the first cervical being due to the presence in considerable number of the descending fibres of the spinal trigeminal root. Its cells are small faintly staining polygonal cells, larger polygonal cells and small, round deeply staining cells. The latter are the characteristic cells and are termed the *cells of Gierke*. The majority of the cells of the gelatinosa are so small that the cytoplasm is barely evident in a Nissl preparation (cytochrome cells). Golgi preparations indicate that the cells of this nucleus send most of their axones to the adjacent portion of the lateral column, to the zona spongiosa and marginal zone of Lissauer and also into the dorsal horn. Their great number and small size indicate that they give rise to short, probably principally intrasegmental fibres. The small number of medullated fibres shown in Weigert preparations (fibres merely passing through?) indicates that many of their axones are non-medullated. As mentioned later they probably form an important part of the paths for painful, thermal and probably other cutaneous stimuli, either conscious, reflex, or both.

5. Diffuse Cells.—These are the cells which are not arranged in definite cell groups. They probably constitute a majority of the cells of the cord aside from those of the substantia gelatinosa of Rolando. They are medium and small cells. They show however a certain tendency to be arranged in three ill-defined groups or columns. (a) The *medio-ventral group* occupying the medial border of the ventral horn and most marked in the lumbo-sacral cord. (b) The *medio-dorsal group*, occupying the medial part of the dorsal horn and lying around the column of Clarke where the latter is present. Nearly all its cells are small. It is inconspicuous except in the lumbo-sacral cord. (c) The *lateral intercornual group*. This group occupies the lateral border of the dorsal horn, including the processus reticularis, reaching to the dorsal border of the ventral horn where it passes into the interior of the latter. It is the largest group and is well represented in all levels of the cord. The cells are polygonal, often elongated and somewhat larger than those of the two preceding groups. Its cells cannot always be easily distinguished from the sympathetic cells of the lateral horn.

The destinations of the axone of the diffuse cells are not known. Reasoning as above, their axones should give rise to the short spino-spinal tracts and possibly long non-medullated tracts if there be such. Some may be Golgi's Type II.

All the cells of the cord except the smallest cells are larger in the lumbo-sacral than in the cervico-thoracic cord.

Arrangement of Fibres (Figs. 321, 5, 6 and 8).—With the low- and high-power objectives the course of the transverse nerve fibres (longitudinally cut in transverse sections) should be carefully studied in Weigert and Cajal preparations. These fibres pass from gray to white matter or *vice versa*, and are in general (a) root fibres entering or leaving the cord, (b) either axones of column cells in

the gray passing out into the white there to become longitudinal fibres by turning or splitting, or (c) collaterals and terminals of the fibres of the white matter entering the gray to terminate there (comp. pp. 462–463).

The arrangement of these fibres should be carefully studied in all parts of the section (Weigert and Cajal), taking one field at a time. In the dorsal part of the cord, the dorsal roots can be seen entering. Each dorsal root after entering divides into a lateral, fine-fibred portion which enters the

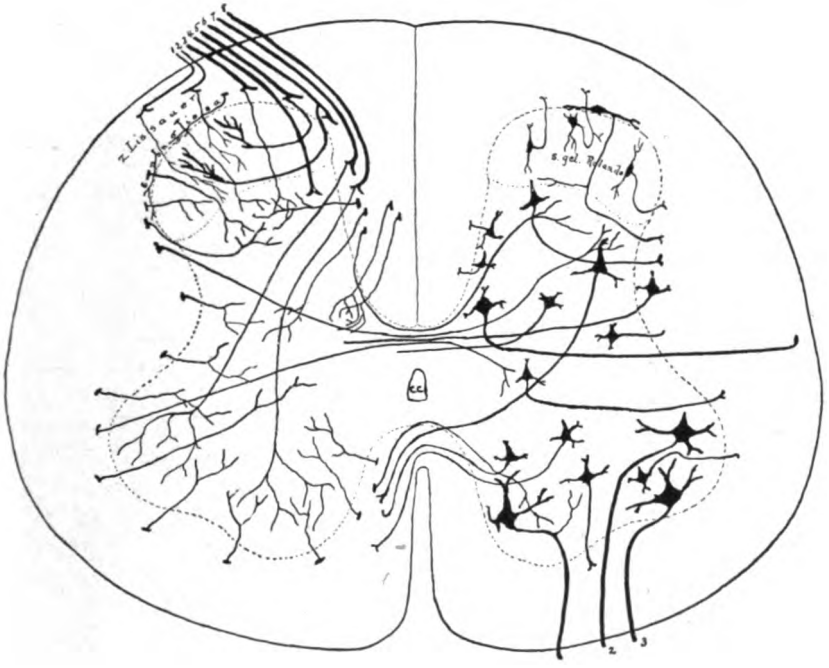

FIG. 325.—Transverse Section of the Spinal Cord, showing the Arrangement of Collaterals (left) and Cell Bodies and their Axones (right) as seen in Golgi Preparations of Various Young and Fœtal Mammals. (After Cajal and Lenhossék). Dorsal root fibres 1 and 2 represent the fine lateral dorsal root fibres to the zone of Lissauer; fibres 3 to 8 represent various coarse dorsal root fibres to the medial, coarse-fibred portion of the dorsal white column. Collaterals from 1 and 2 enter the substantic gelatinosa of Rolando, those from 3 to 8 enter the gelatinosa, head and neck of dorsal horn, intermediate gray and ventral horn. Some collaterals from dorsal root fibres of other, probably lower, levels are seen leaving the dorsal white column and terminating in the dorsal horn, intermediate gray and (most mesially) the column of Clarke. Some cross in the dorsal commissure. Probably there are other heteromeric column cells whose axones cross in the ventral commissure, besides those indicated, which are not traceable by the Golgi method. *c.c.*, central canal. Preganglionic sympathetic root cells are not shown. Compare Figs. 321, 326 and 328.

fine-fibred zone of Lissauer and a medial coarse-fibred portion which enters the coarse-fibred medial or main portion of the dorsal white column lying medial to the dorsal horn. The fine fibres bifurcate in the zone of Lissauer into short ascending and descending arms. The coarse fibres of the root pass along the dorsal and mesial side of the dorsal horn, forming the *zone of entry* of the dorsal roots. They bifurcate and form the majority of the longitudinal fibres of the

the dorsal white column. The bifurcations are not usually visible in transverse sections, especially in Weigert preparations. In some sections of the cord coarse root fibres traverse the mesial portion of the substantia gelatinosa and form longitudinal bundles along its inner (ventral) side in the caput of the dorsal horn. These appear to represent a lateral protrusion of the dorsal column into the horn. From the entering root fibres and fibres of the dorsal funiculus, bundles of fine fibres (collaterals and terminals) pass radially through the gelatinous substance of Rolando or sweep around its mesial side and enter the gray. Some of these terminate in the gelatinous substance of Rolando, some form part of the dense plexus of fibres in the caput and terminate there, others can be traced

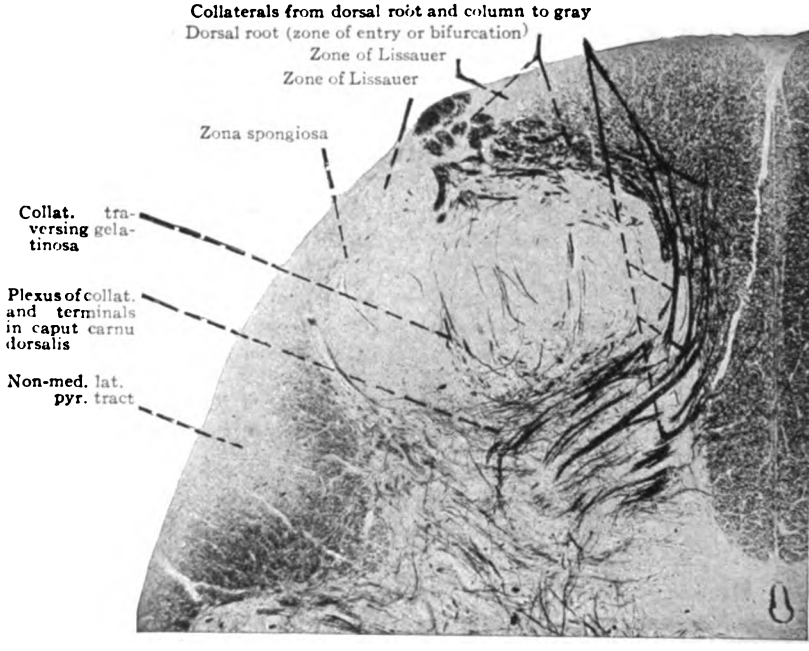
Collaterals from dorsal root and column to gray
Dorsal root (zone of entry or bifurcation)
Zone of Lissauer
Zone of Lissauer
Zona spongiosa
Collat. traversing gelatinosa
Plexus of collat. and terminals in caput carnu dorsalis
Non-med. lat. pyr. tract

FIG. 326.—Portion of Transverse Section of Lumbar Spinal Cord of 5 weeks' Infant, showing Entrance of Dorsal Root and its Collaterals. *non-med.*, non-medullated. Weigert's myelin stain. Photograph. Compare Figs. 321 and 325.

to the intermediate gray and, in some cases, some ("direct reflex collaterals") can be traced to the ventral horn (Figs. 321 and 325). It will be noted that not many come from the mesial part of the dorsal funiculus. Collaterals and terminals from the zone of Lissauer and from the coarse medial root fibres enter the gelatinous substance of Rolando. In the middle part of the cord there is a similar interchange of fibres between the plexus in the gray and the adjoining white matter, consisting of axones of column cells entering the white columns, or terminals and collaterals of the longitudinal fibres of the white columns entering the gray. In the ventral part of the cord a similar interchange takes place, but here besides these fine fibres are seen the coarse fibres of the ventral roots

gathered from various parts of the ventral horn to form bundles which leave the ventral side of the horn, pass through the white matter and emerge as the ventral root fibres. The larger bundles of fibres in the ventral horn separate the cell groups, but between individual cells are seen numerous fine medullated fibres (principally terminals of fibres from the white funiculi). Trace as far as possible the course of the fibres of the ventral and dorsal white commissures. The ventral commissure consists of the decussating axones of heteromeric column and II type cells whose bodies lie near the same level and some decussating collaterals. The dorsal commissure contains a few decussating axones of column cells and also collaterals from the dorsal column, possibly from the zone of Lissauer and also from the dorsal part of the lateral column.

Blood-vessels (Fig. 327).—Study the arrangement. and structure of the blood-vessels of the cord and pia. There are three principal longitudinal arteries,

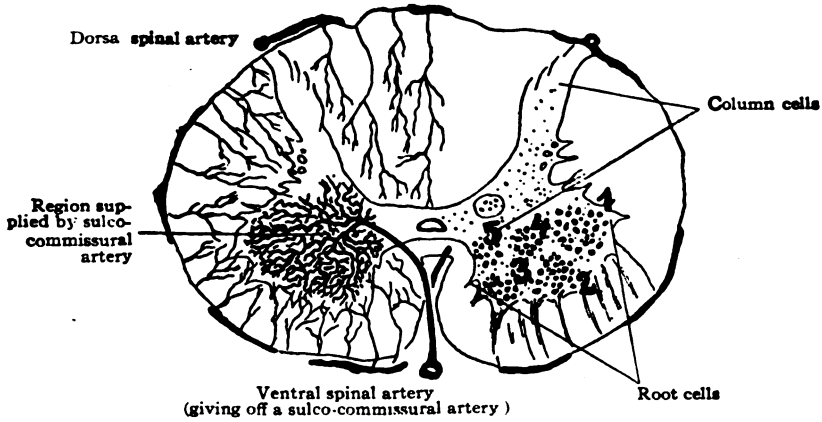

FIG. 327.—Schematic transverse section of Cord, Showing General Distribution of Blood-vessels (left) and Nerve-cells (right) (Bing). Root-cells: 1, dorso-lateral group; 2, ventro-lateral group; 3, ventro-medial group; 4, central group; 5, dorso-medial group. The broken black lines on the surface of the cord are portions of the vascular network in the pia mater.

the *ventral* or *anterior spinal artery* given off from the vertebral arteries near their union into the basilar artery, and two *dorsal* or *posterior spinal arteries*, given off also from the vertebral arteries. These arteries are reënforced by small arteries passing to the cord along the dorsal and ventral roots and form an arterial network in the pia mater. From the network, *terminal* (*i.e.*, non-anastomosing) branches enter the cord, supplying all parts except the ventral horn and column of Clarke. The latter are supplied by branches from the anterior spinal artery which pass dorsally in the ventral sulcus (*sulco-commissural arteries*) and enter the cord alternately to right and left. They then break up into a rich capillary network in the ventral horn, supplying also a branch to the column of Clarke. The veins of the cord also form a plexus in the pia mater. Larger *dorsal median* and *ventral median veins* can be distinguished. Portions of the above vessels can be seen, cut in various planes in the pia and in the cord. The general appearance and structure of the blood-vessels, including capillaries, should be noted in the various methods of staining.

Variations in Structure at Different Levels

While the general structure above described obtains throughout the cord, the size and shape of the cord, the size and shape of the gray matter, and the relative proportion of gray matter and white matter, vary in different parts of the cord, which must therefore be separately considered. These variations are due to: (1) Variations in the size of the nerves entering and leaving, which cause corresponding variations in the gray matter which receives the afferent fibres and contains the cells of origin of the efferent fibres. Thus the

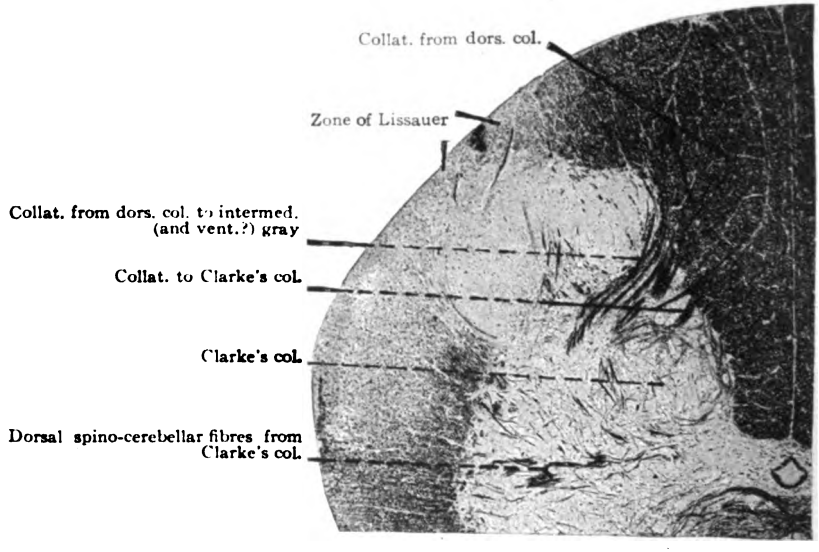
Collat. from dors. col.
Zone of Lissauer
Collat. from dors. col. to intermed. (and vent.?) gray
Collat. to Clarke's col.
Clarke's col.
Dorsal spino-cerebellar fibres from Clarke's col.

FIG. 328.—Portion of Transverse Section of Twelfth Thoracic Segment of Spinal Cord of 5 weeks' Infant, showing Collaterals from Dorsal Column to Column of Clarke and Dorsal Spino-cerebellar Fibers from latter. Weigert's myelin stain. Photograph. Compare Fig. 325.

larger nerves of the extremities cause an increase in size of the gray matter of the cervical and lumbo-sacral cord with which they are connected (addition of the lateral motor nuclei of the ventral horn), and also an increase in the dorsal funiculi. The outflow of the preganglionic sympathetic fibres in the thoracic cord is represented by the lateral gray horn. (2) A gradual increase in the white matter of the cord, as higher levels are reached, due to an increase in the number of long ascending and descending fibres to and from the brain.

C. II

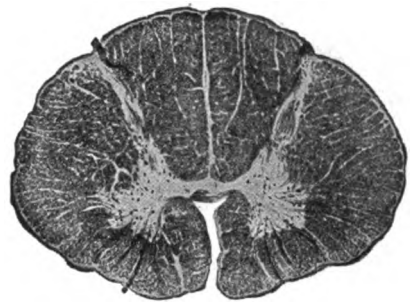

C. III

C. IV

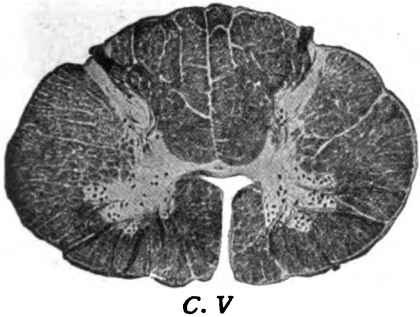

C. V

C. VI

C. VII

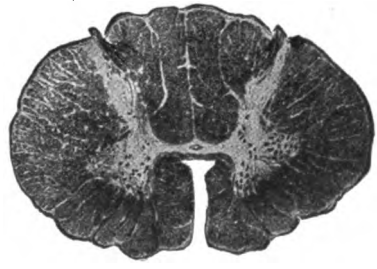

C. VIII

FIG. 329.—Transverse Sections through the Cervical (II–VIII) Segments of the Cord. Weigert preparations. (Rauber-Kopsch.)

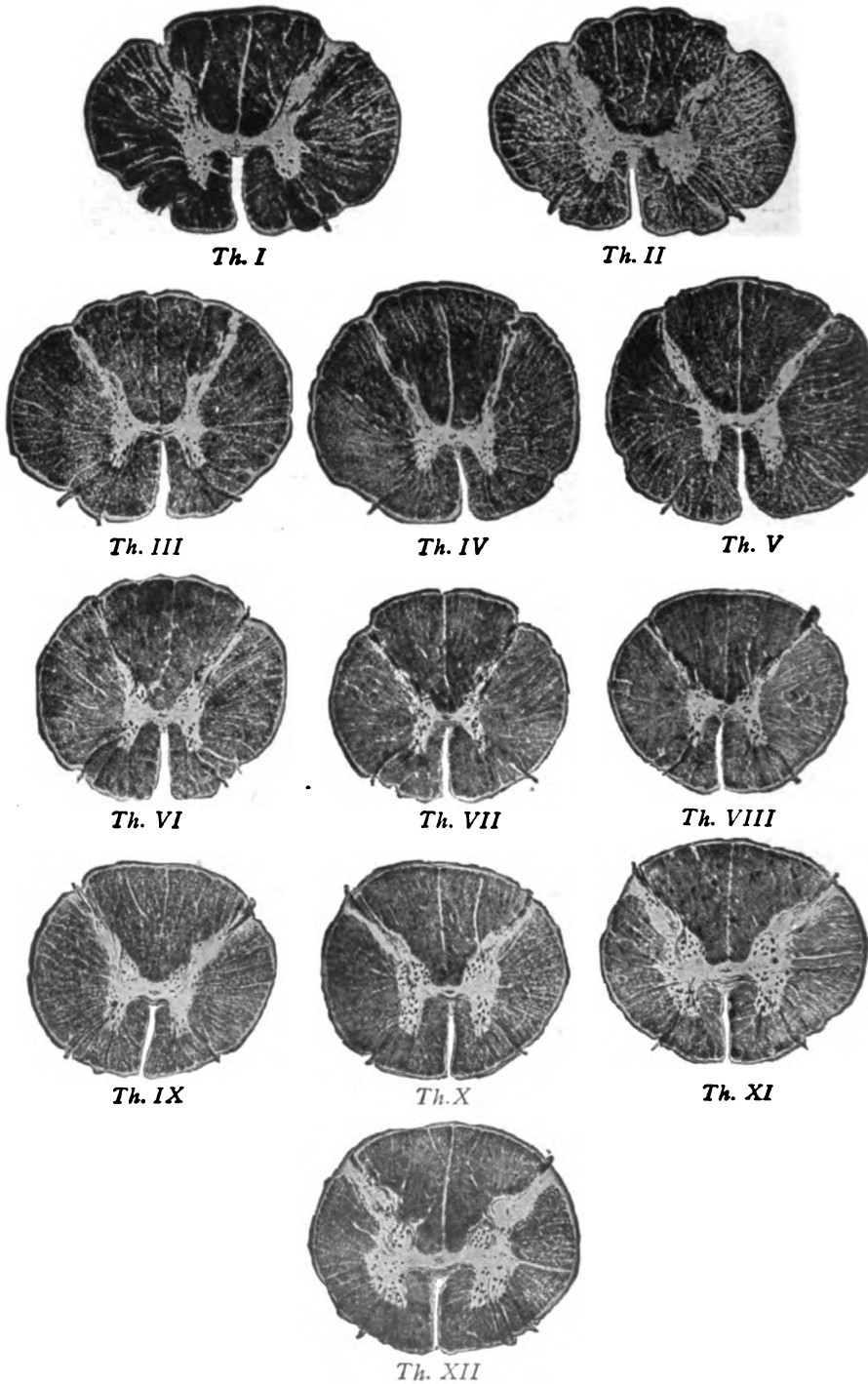

FIG. 330.—Transverse Sections through the Thoracic (I–XII) Segments of the Cord. Weigert preparations. (Rauber-Kopsch.)

L. I

L. II

L. III

L. IV

L. V

S. I

S. II

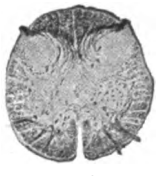

S. III

S. IV

S. V

FIG. 331.—Transverse Sections through the Lumbar (I-V) and Sacral (I-V) Segments of the Cord. Weigert preparations. (Rauber-Kopsch.)

PRACTICAL STUDY

Section through the Twelfth Thoracic Segment (Fig. 324).—Note that the cord is smaller than in the lumbar enlargement and somewhat flattened dorso-ventrally; that the amount of gray matter and white matter is diminished; that both ventral and dorsal horns are more slender, the ventral horn containing comparatively few cells. At the inner side and base of the dorsal horn may be seen the group of cells known as *Clarke's column* (p. 456). Medullated fibres can be seen passing from the dorsal funiculus into Clarke's column, where they interlace among the nerve cells. These fibres are collaterals of the dorsal root fibres terminating in the nucleus. From the nucleus coarser fibres can be seen gathering at its ventral side and thence passing outward to the periphery of the cord where they bend upward forming the beginning of the dorsal spino-cerebellar tract (see. p. 490). Note the lateral horn and the intermedio-lateral cell group (p. 471). See also Figs. 328 and 322.

Section through the Mid-thoracic Region (Fig. 330).—Compare with the lumbar sections. Note the change in shape and size; that the cord is more nearly round and smaller; that while the reduction in size affects both gray matter and white matter it is the former that shows the greater decrease. The horns are even more slender than in the twelfth thoracic section, and the ventral horn contains still fewer cells. Clarke's column is present, but not so large. Note the lateral horn. See also Fig. 322.

Section through the Cervical Enlargement (Fig. 329).—Note the marked increase in size of the cord, which affects both gray matter and white matter. Depending upon the exact level at which the section is taken, the cord may be nearly round or flattened dorso-ventrally. The dorsal horns are somewhat enlarged while the ventral are much broader than the dorsal horns. The *reticular process* is more prominent than in any of the previous sections. As in the lumbar cord, the cell groups of the ventral horn are numerous and well defined. A more or less definite septum divides the dorsal column into an inner part, the *column of Goll* or *fasciculus gracilis*, and an outer part, the *column of Burdach* or *fasciculus cuneatus*. See also Figs. 320 and 322.

For further variations and differences. between the segments of the cord, compare Figs. 329, 330 and 331; also Fig. 322 and 323.

Fibre Tracts of the Cord

The determination of the fibre tracts of the cord has been accomplished principally by methods II, VI, VIII, IX and X combined with IV *a*, *d*, *e* and *f* (p. 621) though the other methods have also been used. The method of secondary degeneration is especially valuable. Thus if the cord is cut at some particular level, at any level above the cut all fibres present which originate from cells below the cut will show degeneration ("ascending" degeneration), while the cell bodies of the cut fibres will show the axonal degeneration changes. On the other hand, at any level below the cut, fibres

which originate from cells above the cut will show degeneration ("descending" degeneration), while the cell bodies of these fibres, located above the cut, will exhibit axonal degeneration. The indication this gives as to the direction of conduction is evident when it is remembered that the impulse passes from neurone body along the axone to its termination.

It will be recalled that various groups or systems of neurones (nuclei and tracts) are linked together to form conduction paths (p. 429). In general an *afferent* ("*sensory*") *conduction path* consists of: (1) a particular kind of receptor. (2) A primary neurone group or protoneurones (cerebrospinal ganglionic) whose distal terminations are in the receptors and whose central endings are in its terminal nucleus in the central nervous system. (3) A secondary group of neurones whose bodies constitute the terminal nucleus of (2) and whose axones form a secondary tract. To these may be added a tertiary group of neurones, etc. to the final termination, usually in the cortex of pallium, midbrain or cerebellum. The ascending tracts of the cord thus form parts or links of afferent conduction paths to pallium, midbrain or cerebellum (given more fully at p. 507). An *efferent* ("*motor*") *conduction path* begins in some part of the central nervous system, often in cortical neurones of pallium, midbrain or cerebellum, and descends by a series of neurone groups the last of which is always the efferent peripheral neurone group, or end neurones, somatic or splanchnic, which thus constitutes the final common pathway to the effectors (muscles and glands) already mentioned (p. 457). The descending tracts of the cord are thus usually parts of descending paths from pallium, midbrain or cerebellum. In general the paths from receptors to pallium and midbrain, and from pallium and midbrain to effectors are crossed or heterolateral, *e.g.*, one cerebral hemisphere is connected with the opposite half of the body. The paths to and from the cerebellum are predominatingly uncrossed or homolateral. In a crossed afferent conduction path the second long neurone group is the one which usually crosses. The afferent pallial paths are all relayed in the thalamus, the last neurone being a thalamo-cortical neurone.

Significance of Relays in Conduction Paths.—There are a variety of reasons why conduction paths consist of more than one group of neurones. The following may be suggested: (a) a phylogenetic reason. A conduction path may be carried further to a newer center by the addition of a neurone group. This may be the case with many thalamo-cortical neurones. (b) There may also be

ontogenetic, developmental reasons. (c) Economy of neurones. A moment's consideration will show that nearly every receptor in the body may, in certain circumstances, cause contractions of almost any muscle in the body. Without central neurones every ganglionic neurone would have to connect with every effector or with every efferent peripheral neurone at least and there would not be much possibility of varied adjustments, aside from the probable impossibility

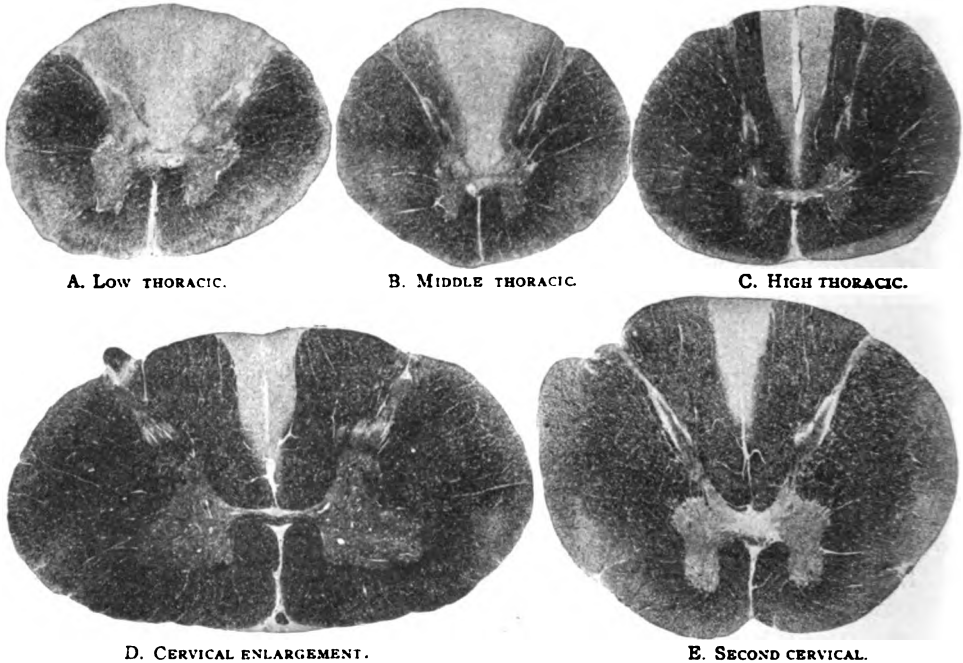

A. Low thoracic. B. Middle thoracic. C. High thoracic.

D. Cervical enlargement. E. Second cervical.

Fig. 332.—Five Transverse Sections of Various Segments of a Human Spinal Cord which had been crushed some time previously in the Lumbo-sacral region. Weigert's myelin stain. Photographs. In the dorsal columns is shown the progressive diminution of the ascending secondary degeneration due to the passing into the gray of the short and medium ascending arms of the lumbo-sacral dorsal root fibres; also the progressive increase of normal fibres, next to the dorsal horn, due to the addition of ascending arms of dorsal root fibres entering the cord above the injury. There is also degeneration of scattered fibres in the spino-cerebellar and spino-thalamic tracts. The greater degeneration in A is due to the degeneration there of spino-spinal ascending fibres which do not reach the higher levels. Compare Figs. 334 and 336.

of the giant neurones required. Such an arrangement would resemble a telephone system without central adjusting stations. Each relay furnishes the possibility of (1) a splitting into more than one connection, *e.g.*, the connections of dorsal root fibres with a number of neurone groups forming reflex, cerebellar, pallial, etc., paths. (2) A general diffusion of stimuli ("avalanche" of Cajal) whereby stimuli traveling along a certain number of fibres may be multiplied, *e.g.*, the inferior olivo-cerebellar fibres to all parts of the cerebellar cortex. The olive probably receives fewer fibres than it sends to the cerebellum. The great diffusion and consequent increase in neural energy due to intercalation

of neurones is best shown by the action of the whole nervous system where at times a stimulus traveling from periphery by only a few fibres (*e.g.*, a painful stimulus) may cause contractions of many muscles involving impulses traveling along hundreds of thousands of efferent peripheral nerve fibres. This capacity of multiplication obviously depends upon the ability of a nerve fibre to stimulate, by means of its branches and terminal arborizations, a number of other neurones. (3) A fusion of paths, *e.g.*, the red nucleus receives fibres from cerebellum and corpus striatum and possibly from cortex pallii. (4) A concentration of stimuli, *e.g.*, the dentate and other internal nuclei of the cerebellum receive fibres probably from all the Purkinje cells of the cerebellar cortex, the fibres passing from these nuclei (superior cerebellar peduncles, etc.) must be much fewer in number. The narrowing down of the 100,000,000 rods and cones of the retina to 500,000 optic nerve fibres is another example. The most striking example, again, of fusion and concentration is shown by the activities of the entire central nervous system, including the billions of cortical neurones, which finally take effect in impulses passing out by at most a million or two, usually much fewer, efferent peripheral neurones constituting the final common path. Fusion and concentration (3 and 4) obviously economize neurones. It may be wondered how the individuality of say a local stimulus is preserved through relays in which neurone bodies receive impulses from a number of nerve fibres but it must be remembered that, for example, for the cortex pallii to discriminate between stimuli from two points on the skin 3 mm. apart it is only necessary for each stimulus to reach the cortex *via* a different *combination* of neurones from the other. (5) The presence of synapses may be necessary for proper functioning. More intercalated synapses may furnish higher threshold paths, *e.g.*, pain pathways; synapses may permit stimuli to pass only in one direction (irreciprocity of conduction through more than one neurone); it is possible that variations in synaptic resistances may result in a number of alterations in stimuli traversing the gray; may be a factor in consciousness, habit formation, etc. Synapses and cell bodies are more vulnerable to various products of metabolism, hormones, drugs, toxins, etc. and conduction through them shows more fatigue than when simply along nerve fibres. Explanations of the mechanism of sleep, of various changes in the physiological state of the nervous system, of the action of anesthetics, etc., may perhaps be found here.

Long Ascending Tracts

I. Long Ascending Arms of Dorsal Root Fibers (*Dorsal White Columns*).—The origin of these tracts—central processes of the cells of the spinal ganglia—has been described (p. 458). The distribution of the posterior root fibres to the gray matter of the cord was noted in connection with the study of the lumbar enlargement section (p. 475). The general arrangement of these fibres in the dorsal funiculi remains to be noted.

It has been seen (p. 475) that each dorsal root divides into a lateral fine-fibred part and a medial coarse-fibred part. The fine-

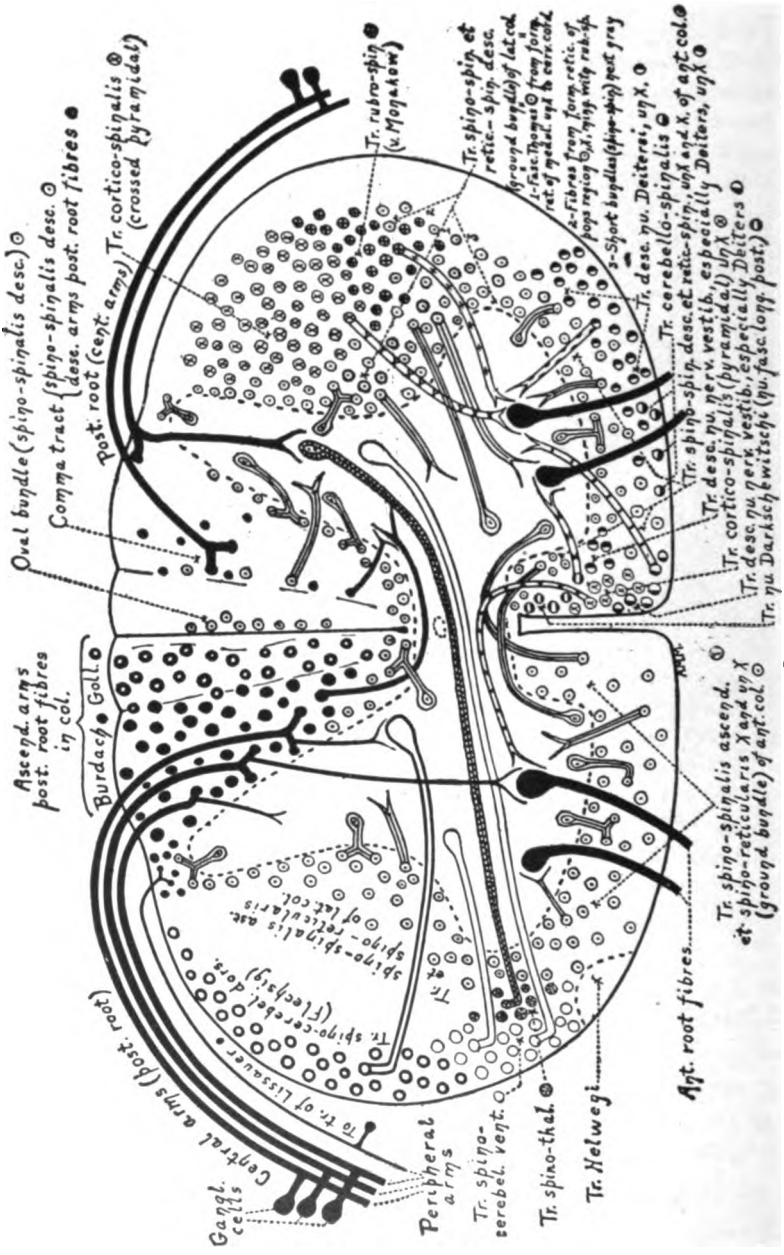
Oval bundle (spino-spinalis desc.)
Comma tract (spino-spinalis desc. desc. arms post. root fibres
Post. root (cept. arms)
Tr. cortico-spinalis (crossed pyramidal)
Tr. rubro-spin. (v. Monakow)
Ascend. arms post. root fibres in col.
Burdach
Goll
Tr. spino-spin. et retic.-spin. desc.
Tr. spino-spin. desc. et retic.-spin., upt and X of ant. col.
Tr. desc. nu. nerv. vestib. especially Deiters
Tr. cortico-spinalis (pyramidal) unX
Tr. desc. nu. nerv. vestib., especially Deiters
Tr. nu. Darkschewitschi (nu. fasc. long. post.)
Tr. cerebello-spinalis
Tr. desc. nu. Deiters, unX
Ant. root fibres
Tr. spino-spinalis ascend.
Tr. spino-reticularis X and unX (ground bundle) of ant. col.
Peripheral arms
Tr. spino-cerebel. vent.
Tr. spino-thal.
Tr. Helweg
Ganglion cells
Central arms (post. root)
To Tr. of Lissauer
Tr. spino-cerebel. dors. (Flechsig)
Spino-spinalis ant. of lat. col.
Spino-reticularis

FIG. 333.

fibred part enters the zone of Lissauer and divides into short ascending and descending arms, probably not more than one segment in length. The coarse-fibred part enters the dorsal white column just mesial to the dorsal horn. Its fibres divide into ascending and descending arms of varying lengths, many of the ascending arms passing upward the whole length of the cord. As each successive dorsal root sends its fibres into the cord next to the dorsal horn and therefore lateral to the ascending arms from the next root below, the long ascending arms of the lower roots as they pass up the cord are gradually pushed toward the median line until they finally occupy that part of the posterior column lying near the posterior septum. The dorsal column at any given level thus consists largely of the ascending arms of the roots entering at lower levels and arranged in order of entry with the ascending arms of the lowermost roots next the dorsal septum. The separation of the dorsal column by a connective-tissue septum into the column of Goll and the column of Burdach occurs only in the cervical cord (Figs. 320 and 329). Here the most median fibres, *i.e.*, those lying in the column of Goll, are the longest fibres of the dorsal columns, having come from the lower spinal ganglia (lower thoracic, lumbar and sacral), while the column of Burdach (Fig. 320) consists of short and medium length fibres (upper thoracic and cervical dorsal root fibres). The fibres of Goll's column end in the *nucleus fasciculi gracilis* or *nucleus of the column of Goll* in the medulla (see p. 531 and Fig. 346). Those fibres of Burdach's which do not terminate in the spinal cord terminate in the medulla in the *nucleus fasciculi cuneati* or *nucleus of the column of Burdach* (p. 531 and Fig. 346). The nucleus gracilis and nucleus cuneatus—which will be seen in sections of the medulla (Fig. 346)—thus serve as terminal nuclei for the afferent root fibres in the columns of Goll and those of the columns of Burdach which do not terminate within the cord. Inasmuch as many of the ascending arms are short, it is evident that only a fraction of the dorsal root fibres are repre-

FIG. 333.—Diagram of the Tracts of the Cord (Cervical Region). Ascending tracts are shown on the left side, and descending tracts on the right. It will be noticed that the tracts of the cord are roughly divisible into three concentric zones: (1) A zone occupying most of the dorsal columns and the peripheral part of the lateral columns. This zone comprises the principal long ascending tracts (beginnings of afferent suprasegmental paths). (2) The second zone lies immediately within the first in the lateral columns and also occupies the peripheral part of the ventral columns. It comprises the principal long descending tracts from various parts of the brain (terminal portions of efferent suprasegmental paths). (3) The third zone borders the gray matter and includes the ground or fundamental bundles of the cord (chiefly spinal intersegmental fibres).

In the figure, for *nu. Darkshewitschi*, etc., read also nucleus interstitialis and for Deiters read also vestibularis.

sented at the higher levels. Those long arms which reach the medulla constitute the beginning of one of the principal afferent cerebral or pallial pathways.

The long ascending arms of afferent roots in the dorsal column conduct those impressions from proprioceptors which ultimately reach the pallium and give rise to sensations of position and movement. They also conduct to the pallium those impressions from tactile receptors (probably the corpuscles of

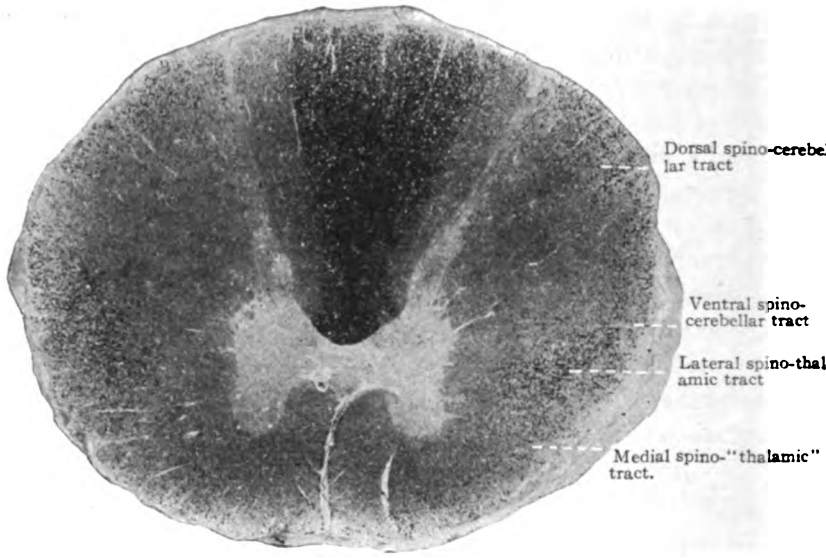

FIG. 334.—Transverse Section of Thoracic Human Spinal Cord which had been crushed not long previously in the Lumbo-sacral Region. Marchi osmic stain of degenerating medullated fibres. Photograph. The degenerating ascending fibres from the lumbo-sacral segments are represented by black granules. The granules in the dorsal column (long ascending arms of dorsal lumbo-sacral roots) form a compact mass; those in the long ascending tracts located in the ventro-lateral columns are more scattered (compare the solid degeneration of the spino-cerebellars in Fig. 336 where the injury is cervical). There is also some degeneration shown in long ascending intersegmental tracts *e.g.* the sulco-marginal tract of Marie next to the ventral sulcus. Compare Figs. 332B and 336.

Meissner) which are necessary for discrimination of points, form and size of objects. Stimuli produced by the application of a rapidly vibrating object (tuning fork), especially to bone, and giving rise to sensations of vibration also travel up the dorsal column. (For the complete paths see paths 4, p. 509, 1*a*, p. 507 and 5, p. 509).

According to some authorities some of the long arms pass directly from medulla to cerebellum and others decussate and terminate in a nucleus in the medial part of the bulb.

II. The Lateral Spino-thalamic Tract.—This arises from heteromeric cells lying probably principally in the dorsal horn (see p. 473). Their axones cross in the ventral commissure and reach the opposite

lateral funiculus where they ascend in a position mesial to the ventral spino-cerebellar tract (see below). The decussation takes place in the cord not far above the level of entry of the dorsal roots which convey impulses to the neurones involved. Associated with this system are some fibres to the superior colliculus (*spino-collicular* or *spino-tectal tract*). (See path 13, p. 511). (Figs. 333, 335 and 342).

There are other long ascending fibres lying nearer or within the ventral white column. Those lying nearest to the lateral spino-thalamic tract have been called the *medial* or *ventral spino-thalamic tract.* It is doubtful whether any of these fibres actually reach the thalamus in man. Some of them terminate in nuclei in the bulb, others in the tegmentum, reaching as far as the mid-brain. Probably other tactile impulses (contact, pressure, and touch localization; from peritrichial endings and corpuscles of Pacini?) pass upward in these fibres. (See path 1*b*, p. 507).

The lateral spino-thalamic tract conveys impressions of pain and temperature and possibly a portion of touch. (See paths 2 and 3, p. 508).

It is probable that the dorsal root fibres conveying into the cord painful stimuli do not pass directly to the lateral spino-thalamic neurones but that short neurones are intercalated. The dorsal root fibres in question are almost certainly the fine fibres entering the zone of Lissauer (Ranson) and terminating in the gelatinosa, the cells of which would be the intercalated cells in question. Such intercalation would account possibly for the high threshold and diffuse character of pain reactions. According to one view pain stimuli not only have their own receptors but their own ganglionic neurones. According to another view the same ganglionic neurone may bring in both stimuli from pain receptors and from other receptors. A third view is that excessive stimulation of tactile or other receptors above may also give rise to painful stimuli. In the latter case the differentiation between pain reactions and those due to other stimuli would be performed entirely by the central nervous system, there being an overflow into the higher threshold pain path. In either case the pain path is probably one with more synapses. The principal path for conscious pain in the cord is a crossed one in the opposite lateral column, the crossing taking place within a few segments. Some authorities believe there is also a less important homolateral path and that deep pain may in part pass up the dorsal column. The path for temperature is largely similar to that for pain. Regarding touch it has already been seen that it has, in the cord, at least two paths one uncrossed in the dorsal white column (touch discrimination, etc.) and one crossed in the ventro-lateral column (mere contact and localization). It is not improbable that there are still other tactile paths in the cord. Touch is the form of sensation least apt to be completely abolished in cord lesions. Whether there are neurones interposed between the dorsal root fibres and the long ascending neurones in the case of contact and localization is not certain. Some authorities

believe that all spinal cutaneous sensory paths (except touch discrimination) are interrupted in the gelatinosa of Rolando. The interpretation of Golgi and Weigert preparations is complicated by our inability to distinguish with certainty between the reflex and long path connections. The above considerations also apply to other affective (protopathic, *i.e.*, agreeable and disagreeable) stimuli, beside pain, as opposed to stimuli used in making discriminations as to intensity, locality, etc. (epicritic). According to Head the two have different peripheral paths (see also p. 589).

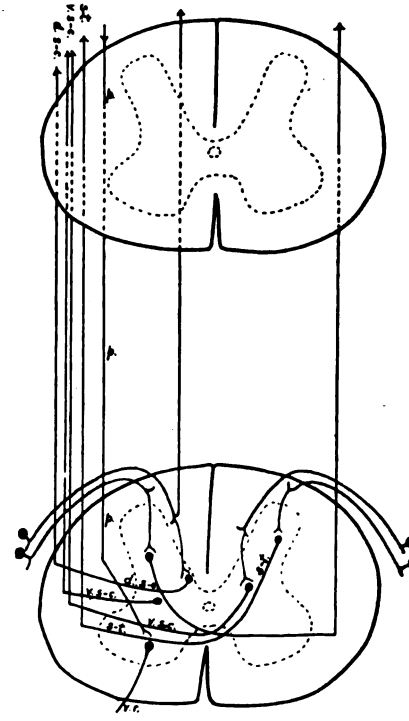

FIG. 335.—Diagram showing Beginnings of Principal Long Ascending Tracts of Cord and Termination of Lateral Pyramidal Tract. Each group of neurones is represented by one or two neurones. *d.s-c.*, Dorsal spino-cerebellar tract; *p*, lateral pyramidal tract; *s-t.*, lateral spino-thalamic tract; *v.s-c.*, ventral spino-cerebellar tract; *v.r.*, ventral root.

III. The Dorsal Spino-cerebellar Tract (*Tract of Flechsig, Direct* or *Uncrossed Cerebellar Tract*).—This tract lies along the dorso-lateral periphery of the cord, being bounded internally by the crossed pyramidal tract (Figs. 320, 333 and 336). The fibres of the direct cerebellar tract are the axones of the cells of Clarke's column (tautomeric column cells) (Figs. 328, 333, 335 and 342). These axones cross the intervening gray matter and white matter of the same side and turn upward as the direct cerebellar tract. In the medulla they form part of the restiform body or inferior cerebellar peduncle

and pass to the cerebellum. Here they enter the gray matter of the anterior portion of the vermis of the same and opposite sides, ending in ramifications among the nerve cells. Some fibres either end in, or send off collaterals to the cerebellar nuclei. The tract first appears in the upper lumbar cord, and increases in size until the upper limit of Clarke's column has been reached (p. 472).

As already noted above, some fibres of the dorsal root, or their collaterals, end in the column of Clarke. This path is composed then of two systems of neurones, spinal ganglion cells and Clarke's column cells. and is uncrossed (with the exception that some

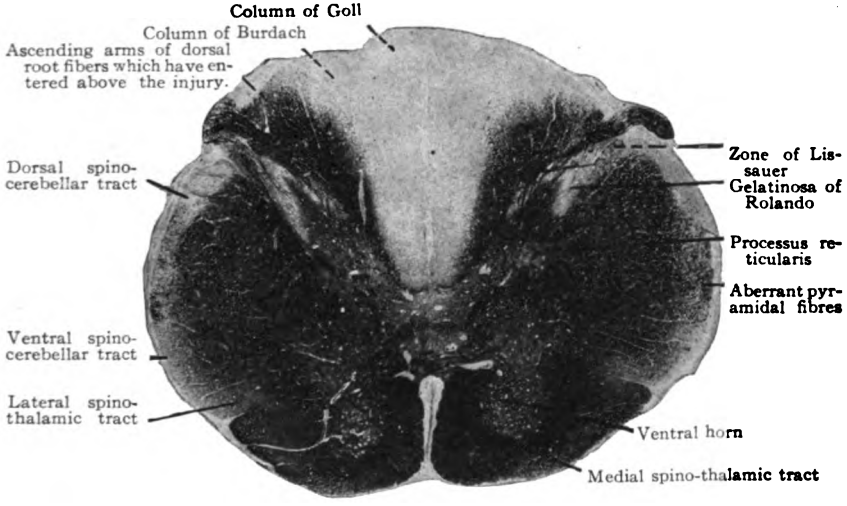

FIG. 336.—Transverse Section of the Second Cervical Segment of a Human Spinal Card which had been crushed some time previously in the Lower Cervical Region. Weigert myelin stain. Photograph. Owing to the high level of the injury practically all of the fibres of the spino-cerebellar and spino-thalamic tracts have undergone secondary degeneration; also all the ascending arms of dorsal root fibres in the dorsal column except those which have entered above the injury, *i.e.* the middle and upper cervicals. Compare with the corresponding level (*E*) in Fig. 332 and also with Fig. 338.

fibres are interrupted in the nucleus lateralis of the medulla and that some of the fibres from the nucleus lateralis cross). (See path 15*a*, p. 511.) (Fig. 368). Some fibres, composing the dorsal part of the tract have been traced by some observers into the nucleus of the descending vestibular root (p. 495).

The collaterals from dorsal column to Clarke's column arise mesially to the zone of root entry showing that they are branches of ascending arms from lower segments.

IV. The Ventral Spino-cerebellar Tract.—This tract lies along the periphery of the cord, extending from the ventral limit of the

direct cerebellar to about the exit of the ventral roots (Fig. 320, 334 and 336). It is probably formed by axones whose cell bodies are scattered through the intermediate gray matter or dorsal horn (p. 473 and Fig. 333). These cells probably receive collateral similar to those of Clarke's column. Some fibres come from tautomeric, others from heteromeric cells, the axones of the latter crossing in the ventral commissure. The tract first appears in the upper lumbar cord and naturally increases in size as it passes upward. The fibres of this tract also end in the vermis of the cerebellum. They reach their destination in the cerebellum by a different route, ascending considerably farther than the dorsal spino-cerebellar fibres and then turning back along the outer side of the superior cerebellar peduncle to the vermis. This path is thus also a two-neurone path (spinal ganglion cells and spino-cerebellar neurones) and is partly crossed and partly uncrossed. The ventral spino-cerebellar and spino-thalamic tracts are sometimes referred to as Gower's tract. (Figs. 342 and 368). (See path 15*b*, p. 511).

The spino-cerebellar tracts probably convey to the cerebellum stimuli from the muscle-tendon receptors which enable the cerebellum to exercise its regulative tonic and synergizing influence upon the voluntary muscles, in coöperation with the pallium. Injury to them results in an incoördination of muscular action producing disturbances of posture and movement.

Long Descending Tracts

I. The Pyramidal Tracts or Pallio-spinal Tracts (*Tractus Cortico-spinalis* or *Cerebrospinalis*).—The cell bodies of the neurones ("upper" motor neurones) whose axones make up this system are situated in the cerebral cortex anterior to the fissure of Rolando (precentral area, Fig. 392). Their axones converge in the corona radiata and pass downward through the internal capsule, pes pedunculi, pons, and medulla, sending off fibres to the motor nuclei of the cranial nerves. (See path 18, p. 512.) In the medulla the tracts come to the surface as the *anterior pyramids*. At the junction of medulla and cord occurs what is known as the *pyramidal decussation*. Here (*a*) most of the fibres of each tract cross to the opposite dorso-lateral region of the cord and continue downward as the *crossed* or *lateral pyramidal tract*. This lies in the dorsal part of the lateral column (Figs. 337 and 338). It extends to the lowermost part of the cord. In the cervical and dorsal region it is separated from the

surface of the cord by the direct cerebellar tract. In the lumbar region the latter tract is no longer present and the crossed pyramidal tract comes to the surface. In the upper cervical cord a few of its fibres, just below the decussation, occupy a position for a short distance outside the dorsal spino-cerebellar tract. (*b*) The minority of the fibres of the anterior pyramids, instead of decussating, remain on the same side to pass down the cord along the anterior median fissure as the *direct* or *anterior pyramidal tract*, occupyng a small oval area adjacent to the ventral sulcus (Fig. 337). It does not usually extend below the middle or lower thoracic region of the cord.

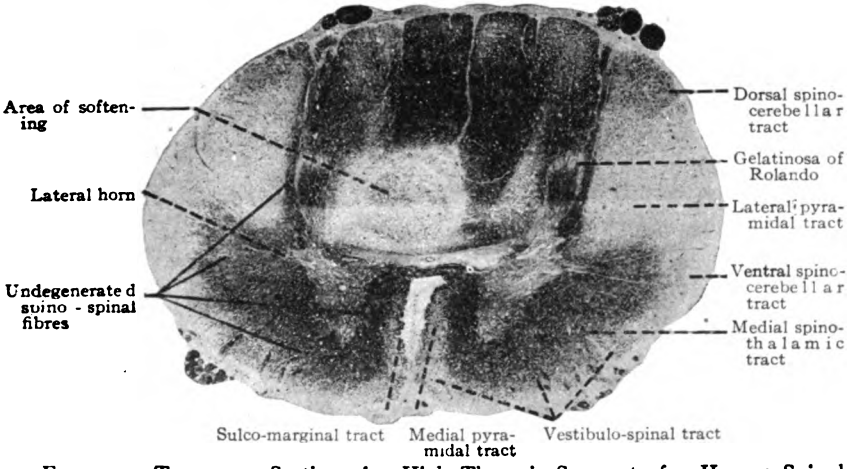

FIG. 337.—Transverse Section of a High Thoracic Segment of a Human Spinal Cord which had been crushed some time previously in the Lower Cervical Region (same Cord as in Fig. 336). Weigert myelin stain. Photograph. The section shows not only a secondary degeneration of the descending tracts but a degeneration (traumatic and "retrograde") of the long ascending tracts, only the short tracts of the ventro-lateral columns escaping. The areas of degeneration in the dorsal columns are probably partly traumatic and partly a secondary degeneration of the comma and septo-marginal tracts. Compare Figs. 336 and 338.

As the pyramidal tracts descend they decrease in size from loss of fibres which continually leave them to terminate in the gray matter. The fibres of the crossed tract terminate mainly in the gray of the same side, while most of the fibres of the direct tract probably cross through the ventral commissure to the opposite side of the cord. These tracts are thus mainly crossed tracts, as the great majority of their fibres cross to the opposite side of the cord. There are, however, some homolateral (uncrossed) fibres in the lateral pyramidal tract. The tracts are apt to differ in size on the two sides of the cord, owing to the fact that the proportion of fibres which decus-

sate is not constant. The axones terminate in arborizations around the motor cells of the ventral horns or, according to some authorities, around cells in the intermediate gray matter whose axones, which form a part of the ground bundles, in turn terminate around the efferent root cells. Short axone (Golgi type II) cells might also of course be intercalated in this connection. (Figs. 341 and 342.)

The pyramidal tracts convey to the cord the impulses which result in voluntary movements, especially, probably, individual movements of parts of the limbs (foot, hand, finger, etc.). Lesions of it not only give rise to loss of voluntary movement of the part affected but also to increased tonus (spasticity) of the muscles, increased deep reflexes, increased associated movements and loss or change of superficial reflexes (upper motor neurone or cerebral or spastic or non-degenerative paralysis). For complete path, see path 18, p. 512.

II. The Colliculo-spinal Tract (*Tecto-spinal Tract*) originates in the colliculi of the midbrain roof, decussates and descends to the cord, where it lies near the ventral sulcus. Its presence in the cord has been disputed. (Fig. 383.) (See path 29, p. 516.)

III. The Tract from the Interstitial Nucleus (*Nucleus of the Posterior or Medial Longitudinal Fasciculus*).—This nucleus is located in the reticular formation of the tegmentum of the midbrain cephalad to the nucleus of nerve III.[1] The tract originating from it forms in the brain a part of the posterior or medial longitudinal fasciculus. It is uncrossed and lies near the floor of the brain cavity and next the median line. In the cord it occupies a similar position near the ventral sulcus. Its fibres terminate in the ventral horn. Some fibres have been traced into the lumbar cord. (Figs. 333 and 383.)

Tracts II and III, reasoning from anatomical relations, should give rise to optic reflexes taking effect in the muscles of the body. (See path 30, p. 516).

IV. The Rubro-spinal Tract (*von Monakow's Tract*).—This consists of axones of the red nucleus (nucleus ruber) located in the tegmentum of the midbrain. These axones cross and descend to the cord, being joined by axones of the other cells in the reticular formation in the region of the pons. In the cord the tract lies mingled with and ventral to the lateral pyramidal tract. Its fibres terminate in the dorsal part of the ventral horn.

[1]The fibres in question have been variously stated to originate from the nucleus of Darkschewitsch, the "nucleus of the posterior longitudinal fasciculus," and the nucleus of the posterior commissure. Other fibres from the midbrain, including uncrossed colliculo-spinal fibres probably pass down in the complex bundle known as the medial longitudinal fasciculus.

This tract conveys to the lower motor neurones influences from at least the cerebellum and corpus striatum and possibly from the pallium. It thus represents "extra-pyramidal" influences acting upon the lower motor neurones. They apparently aid in the proper performance of voluntary movements and in the maintenance of posture. (For the various paths involving the rubro-spinal tract see paths 20, 21 and 31, pp. 514, *et seq.* and Figs. 342 and 368).

V. The Vestibulo-spinal Tract (*Deitero-spinal Tract*).—This tract originates from Deiters' nucleus and other vestibular nuclei (superior, medial and descending) which lie in the medulla and receive fibres from the vestibular division of the acoustic nerve and also from the cerebellum (see below). The exact contribution from each vestibular nucleus is not certain. There may be among them also some fastigio-spinal fibres from the nucleus fastigii in the cere-

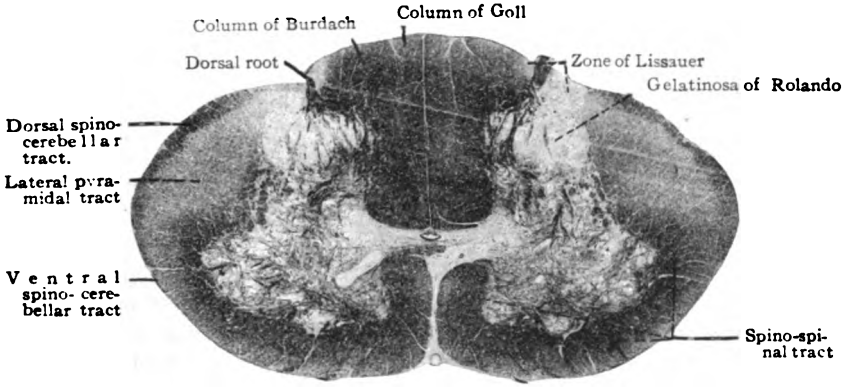

FIG. 338.—Transverse Section of the Cervical Enlargement of a Normal Spinal Cord of a 5 weeks' Infant. Weigert Myelin Stain. Photograph. The pyramidal tracts are lighter on account of their incomplete myelinization. Compare with Figs. 336 and 337.

bellum. The tract occupies the ventral and mesial periphery of the cord. The more lateral fibres are uncrossed, those near the ventral sulcus come from nuclei of both sides. Descending with these fibres are probably axones of other nuclei in the gray reticular formation (reticulo-spinal fibres) of the medulla. These fibres all terminate in the ventral horn. Some fibres have been traced to the sacral cord. All the fibres of tract V are sometimes collectively called the antero-lateral descending tract or marginal bundle of Löwenthal. (Figs. 333 and 331. For the complete path see path 32, p. 517, and Figs. 361 and 368).

Tract III and the mesial part of tract V constitute the major portion of the descending fibres of the important bundle in the segmental brain known as the *posterior* or *medial longitudinal fasciculus.*

The vestibulo-spinal tracts probably bring to the lower motor neurones impulses directly from the vestibular mechanism of the ear and from the cerebellum. These probably exert a tonic influence upon the musculature of the trunk and extremities and aid in maintaining their equilibrium and position, especially in correlation with positions of the head (See path 32, p. 517).

VI. The Fasciculus of Thomas.—Besides the reticulo-spinal fibres already mentioned are fibres in the lateral column which originate in the reticular formation of the medulla and terminate in the gray of the cervical cord. These are known as the tract of Thomas. (Fig. 333).

VII. Helweg's tract is a small triangular bundle of fibres lying along the ventro-lateral margin of the cord, and is traceable upward as far as the olives (Fig. 333). The origin and destination of its fibres are not definitely known. According to some authorities some of its fibres appear to originate in the cord and terminate in the inferior olivary nucleus in the medulla (spino-olivary fibres), according to other authorities the fibres are from olive to cord (olivo-spinal). The connection with the olive is not certain.

VIII. The Septo-marginal Tract.—This is a small bundle of fibres lying next the dorsal septum. It appears to change its location in different levels, *e.g.*, in the sacral cord it occupies a small dorso-median triangle, the triangle of Phillippe and Gombault; in the lumbar region it forms an oval bundle (oval bundle of Flechsig) at the middle of the septum and a superficial bundle; in the thoracic and cervical cord its fibres are more scattered. Authorities differ as to whether this bundle or bundles are long descending arms of dorsal root fibres which shift in position or whether they are descending axones of cells in cord or even in brain or both. The first view is more probable. (Fig. 333).

IX. The "comma" tract of Schultze is a small comma-shaped bundle of descending fibres lying about the middle of the dorsal column (Fig. 333). It is most prominent in the dorsal cord. Its fibres are probably short descending arms of dorsal root fibres.

In general the descending tracts fall into two categories: (1) Tracts which are descending or efferent suprasegmental paths, or are parts of such paths. These comprise (*a*) the efferent pallial path (tract I), (*b*) the efferent midbrain paths (tracts II and III) and (*c*) the efferent cerebellar paths (tracts IV and V). (2) Descending intersegmental tracts. Of the latter some originate in nuclei lying in the segmental brain (nucleus of the medial longitudinal fasciculus, nucleus ruber, vestibular nuclei) which receive efferent suprasegmental fibres, and thus form links of descending suprasegmental paths. Other fibres come from other nuclei in the gray reticular formation (reticulo-spinal fibres). Other still shorter tracts (spino-spinal), from cells in the cord, form the descending fibres in the ground bundles (see below).

All of the paths of which the above descending tracts are parts probably pass out by the somatic root neurones to voluntary striated

muscle. The descending path from the pallium which terminates around the bodies of the splanchnic efferent neurones in the cord may consist of two groups of neurones, pallio-bulbar neurones to the medulla and bulbo-spinal neurones to the efferent peripheral neurones in the cord. The axones of the latter pass out of the cord as preganglionic fibres to the sympathetic ganglion cells. There may be another interruption in the thalamus (thalamo-bulbar neurones). (See path 28, p. 515.) In the cord the fibres of this path probably lie in the ventro-lateral columns, though some authorities place them in the dorsal columns.

This pallio-bulbo-spino-sympathetic path is the path by which various psychic states (emotions, perceptions, memories) affect the splanchnic effectors, as seen in blushing, perspiring, erection, pupillary changes, etc.

Many tracts may also contain fibres proceeding in a direction opposite to that of most of the fibres.

Short Intersegmental or Spino-spinal Tracts (Fundamental Columns or Ground Bundles)

The ascending and descending tracts above described are known as the long tracts of the cord. If the area which these tracts occupy be subtracted from the total area of white matter, it is seen that a considerable area still remains unaccounted for (compare Figs. 336 and 337). This area is especially large in the ventro-lateral region, and extends up along the lateral side of the dorsal horn between the latter and the crossed pyramidal tract (Figs. 333 and 337). A small area in the dorsal column just dorsal to the dorsal commissure, and extending up a short distance along the medial aspect of the horn, should also be included (cornu-commissural tract). These areas are occupied by the fundamental columns or *short-fibre* (spino-spinal or proprio-spinal or internuncial) *tracts* of the cord. Their fibres connect the different segments of the cord (Fig. 340). The shorter fibres lie nearest the gray matter and link together adjacent segments. The longer fibres lie farther from the gray matter and continue through several, it may be many, segments. The origin of these fibres as axones of cells of the gray matter, and the manner in which they re-enter the gray matter as terminals and collaterals have been considered (pp. 460 and 461).

The fact, alluded to above, that the shorter fibres lie nearest, or mingled with the gray is, in a general way, true throughout the

central nervous system. A result of this in the cord is the superficial position of many of the longest tracts.

Examples of Neural Arcs Involving the Spinal Cord

Attention has already been called to the concept of neural arcs which may traverse the cord or both cord and suprasegmental structures (p. 430).

It must be kept in mind that there are probably no *isolated* neural arcs and that every neural reaction involving any given arc always influences and is influenced by other parts of the nervous system.

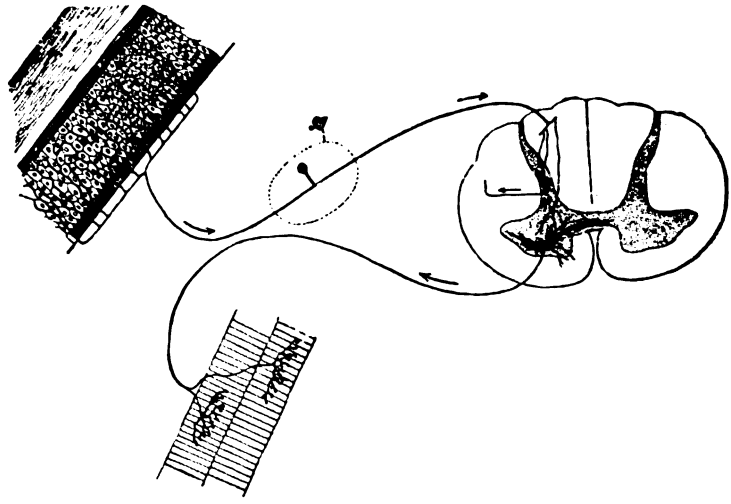

Fig. 339.—Diagram illustrating a Two-neurone Spinal Reflex Arc. Groups of neurones are represented by one neurone. *gg*, Spinal ganglion. (Van Gehuchten.) A proprioceptor rather than the cutaneous receptor shown would represent better the actual two-neurone reflexes.

From the neurones thus far studied and the tracts which their axones form, the following neural arcs may be constructed:

(1) *A Two-neurone Spinal Reflex Arc* (Fig. 339).—(*a*) *Peripheral afferent neurones;* their peripheral processes and receptors, the spinal ganglion cells, their central processes with collaterals terminating around motor cells of ventral horn; (*b*) *peripheral efferent neurones*, *i.e.*, motor cells of ventral horn with axones passing to effectors. Such a two-neurone reflex arc is chiefly uncrossed and in most cases involves only one segment or closely adjacent segments. As it involves only one synapsis (in the ventral gray) it is sometimes termed a *monosynaptic* arc.

It is not improbable that the deep (tendon and periosteal) reflexes and possibly the tonus-maintaining stimuli from a muscle back to itself follow such arcs.

(2) *A Three-neurone Spinal Reflex Arc* (Fig. 329).—(*a*) *Peripheral afferent neurones* as in (1), but terminating around column cells of the cord. (*b*) *Cord neurones* (column cells)—axones in the fundamental columns with collaterals and terminals to ventral horn cells of different levels. (*c*) *Peripheral efferent neurones* as in the two-neurone reflex. Such a three-neurone or *disynaptic* reflex arc may involve segments above or below the segment of entrance of the stimulus and is uncrossed or crossed according as the cord neurones are tautomeric or heteromeric.

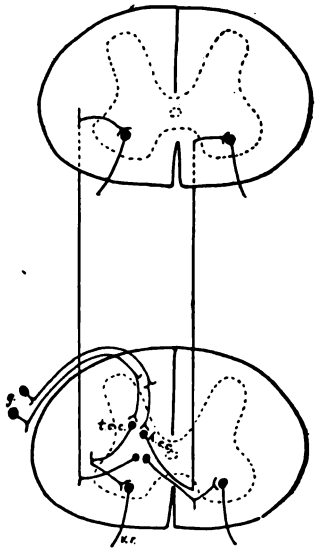

FIG. 340.—Diagram illustrating Three-neurone Spinal Reflex Arcs of one segment and more than one segment. Groups of neurones are represented by one neurone. *g*, Spinal ganglion cells; *h.c.c.*, heteromeric column cell; *t.c.c.*, tautomeric column cell; *v.r.*, ventral root.

The arcs followed by the superficial (cutaneous and mucosal) reflexes involve certainly at least three neurone groups. Cutaneous stimuli may not only give rise to contraction of voluntary striped muscle but may affect smooth muscle and glands (vasomotor, pilomotor and secretory reflexes). Such reflexes initiated in somatic receptors and completed in splanchnic effectors are the somato-splanchnic reflexes already mentioned (p. 431).

The independence of the cord as a reflex mechanism is much diminished in man but recent work has shown that this reflex mechanism is present.

(3) *A Cerebellar Arc* may be constituted as follows: (*a*) Peripheral afferent neurones to (*b*) column cells in cord (*e.g.*, Clarke's column) *via* spino-cerebellar tracts to cerebellar cortex; (*c*) various associative cortical cerebellar neurones; (*d*) axones of cortical cells to (*e*) dentate nucleus the axones of which (superior peduncle) pass to (*f*) nucleus ruber *via* rubrospinal tract to (*g*) efferent peripheral neurones in cord. Another arc would consist of (*a*), (*b*) and (*c*) the same, (*d*) cerebellar cortex to nucleus fastigii in cerebellum to (*e*) nucleus of Deiters to (*f*) efferent peripheral neurones to effectors (Figs. 342 and 368).

The cerebellum probably does not act merely as a part of a complicated reflex arc. It probably not only receives and synthesizes proprioceptive stimuli

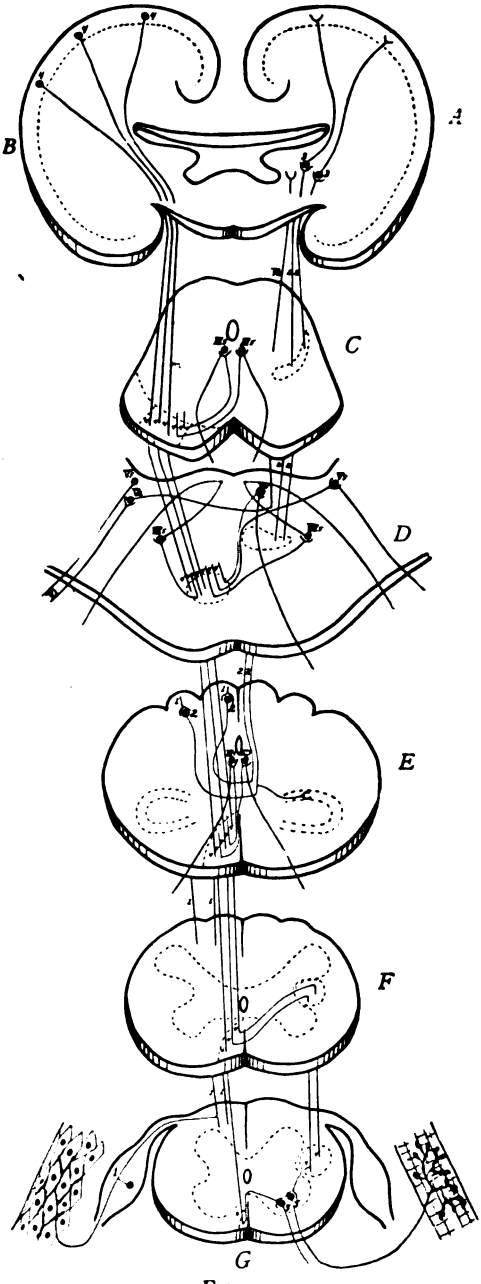

FIG. 341.

but also receives pallial impulses and by its efferent paths regulates the status and movements of voluntary muscles.

(4) *A Cerebral or Pallial Arc:* (*a*) Peripheral afferent neurones, ***via*** long ascending arms to (*b*) nucleus gracilis or cuneatus, thence as medial lemniscus to (*c*) thalamus to cortex pallii; (*d*) associative neurones of cortex; (*e*) cortical precentral neurones *via* pyramid to (*f*) efferent peripheral neurones to effectors. Another arc would involve the spino-thalamic tract instead of the lemniscus. (Voluntary movements resulting from sensations of movement or pain.) (Figs. 341 and 342.)

Similar arcs may include efferent sympathetic neurones. (See pp. 448 and 497.) For a more detailed account of the various paths composing neural arcs, see pp. 507–521.

TECHNIC

(1) Carefully remove the cord (human if possible; if not, that of a large dog) with its membranes, cut into two or three pieces if necessary, and lay on sheet

FIG. 330.—Diagram showing the Most Important Direct Paths which an Impulse follows in passing from a Receptor (*S*) to the Cerebral Cortex and from the latter back to an Effector (*M*) (*e.g.*, muscle), also some of the cranial-nerve connections with the cerebral cortex. Groups of neurones are represented by one or several individual neurones. *A*, Sensory cortex; *B*, motor cortex; *C*, level of third nerve nucleus; *D*, level of sixth and seventh nerve nuclei; *E*, level of fillet or sensory decussation; *F*, level of pyramidal or motor decussation; *G*, spinal cord.

The exact course of the aberrant (pallio-nuclear) pyramidal fibres is not indicated (see path 18, p. 512).

From Periphery to Cortex

Neurone No. 1.—The Peripheral afferent Neurone: 1, *Spinal*, cell bodies in spinal ganglia; receptor, *S*, peripheral arm of spinal ganglion cell; central arm of spinal ganglion cell as fibre of dorsal root to column of Goll or of Burdach, thence to nucleus of one of these columns in the medulla. V_1, *Cranial* (example, fifth cranial nerve, trigeminus; cell bodies in Gasserian ganglion); receptor; peripheral arm of Gasserian ganglion cell; central arm of Gasserian ganglion cell to medulla as afferent root of fifth nerve, thence to terminal nuclei in medulla.

Neurone No. 2.—2, *Spinal connection*—Cell body in nucleus of Goll or of Burdach; axone passing as fibre of fillet to thalamus. V_2, *Cranial nerve connection* (trigeminal), cell body in one of trigeminal nuclei in medulla, axone as fibre of secondary trigeminal tract to thalamus.

Neurone No. 3.—3, Cell body in thalamus, axone passing through internal capsule to termination in cortex. (Various association neurones in cortex omitted.)

From Cortex to Periphery

Neurone No. 4.—4, Cell body in motor cerebral cortex; axone through internal capsule and pes to (*a*) motor nuclei of cranial nerves (*b*) by means of pyramidal tracts to ventral gray of spinal cord.

Neurone No. 5.—5, *Spinal*, cell body in ventral gray of cord; axone as motor fibre of ventral root through mixed spinal nerve to effector (muscle).

Neurone No. 5.—*Cranial*—V_5, Cell body in motor nucleus of trigeminus; axone passing to muscle as motor fibre of fifth nerve.

III_5, Peripheral efferent neurone of third nerve—oculomotor. VI_5, Peripheral afferent neurone of sixth nerve—abducens. VII_5, Peripheral efferent neurone of seventh nerve—facial. XII_5, Peripheral efferent neurone of twelfth nerve—hypoglossal.

cork. Slit the dura along one side of the cord, lay the folds back, and pin the dura to the cork. Care must be taken to leave the dura very loose, otherwise it will flatten the cord as it shrinks in hardening. With a sharp razor now cut the cord, but not the dura, into segments about 1 cm. thick. Fix in Orth's fluid (p. 7). Pieces of the cord may be cut out as wanted and embedded in celloidin. Sections should be cut about 15μ in thickness.

(2) For the study of the general internal structure of the cord, stain a section through the lumbar enlargement of a cord prepared according to the preceding technic (1) in hæmatoxylin-picro-acid-fuchsin (technic 3, p. 24) and another section through the same level in Weigert's hæmatoxylin (technic p. 33). Mount both in balsam. For Weigert staining, material fixed in formalin or in Orth's fluid should be further hardened in Müller's fluid for at least a month, changing the fluid frequently at first to remove the formalin. Mallory's glia stain should also be used with material fixed in Zenker's fluid (technic, p. 30). The silver method of Cajal (alcohol-fixation) should also be used (technic, p. 38) and that of Nissl (technic p. 39).

(3) From a cord prepared according to technic 1, remove small segments from each of the following levels: (1) the twelfth dorsal, (2) the mid-dorsal, and (3) the cervical enlargement. The segments are embedded in celloidin, sections cut 15 to 20μ thick, stained by Weigert's method (p. 33), and mounted in balsam. Medullated sheaths alone are stained by this method and appear dark blue or black.

(4) A human cord from a case in which death has occurred some time after fracture of the vertebræ with resulting crushing of the cord, furnishes valuable but of course rarely available material. If death occur within a few weeks after the injury, the method of Marchi should be used; if after several weeks, the method of Weigert (p. 33). The picture in the cord is dependent upon the fact that axones cut off from their cells of origin degenerate and disappear. After a transverse lesion of the cord, therefore, ascending tracts show degeneration above the lesion, descending tracts show degeneration below the lesion. The method of Marchi gives a positive picture of osmic-acid-stained degenerating myelin in the affected tracts. The method of Weigert gives a negative picture, the neuroglia tissue which has replaced the degenerated fibres being unstained in contrast with the normal tracts, the myelin sheaths of whose fibres stain, as usual, dark blue or black.

(5) Human cords from cases which have lived some time after the destruction of the motor cortex, or after interruption of the motor tract in any part of its course, may also be used for studying the pyramidal tracts.

(6) The cord of an animal may be cut or crushed, the animal kept alive for from two weeks to several months, and the cord then treated as in technic (4). The most satisfactory animal material may be obtained from a large dog by cutting the cord half-way across, the danger of too early death from shock or complications being much less than after complete section.

(7) The cord of a human fœtus from the sixth month to term furnishes good material for the study of the anterior and posterior root fibres, the plexus of fine fibres in the gray matter, the groupings of the anterior horn cells, etc. The pyramidal tracts are at this age non-medullated and are consequently unstained

in Weigert preparations. The cord of an infant of about one month is also excellent. Here the majority of the pallio-spinal fibres are medullated but very thinly so that they are easily distinguishable by their lighter stain. The Weigert-Pal method gives the best results.

(8) For the study of the course of the posterior root fibres within the cord, cut any desired number of posterior roots between the ganglia and the cord and treat material by the Marchi or the Weigert method, according to the time elapsed between the operation and the death of the animal.

THE BRAIN

General Structure

The principal peculiarities of the brain as distinguished from the cord depend upon two factors; certain peculiarities of the receptors and effectors of the head, and the development of higher coördinating apparatus in the central nervous system of the head.

Besides the receptors of the general senses (p. 448), there are in the head the highly specialized receptors of smell, sight, hearing and position (semicircular canals), which are respectively concentrated into certain localities and form, together with certain accessory structures, the organs known as the nose, eye and ear. Each of these groups of receptors has its own special connection with the brain (nerves I, II, and VIII) and its own paths within the latter (see p. 509). The special receptors of taste show a less degree of aggregation into an organ and, together with other visceral receptors, are innervated by afferent portions of a group of nerves (VII, IX and X) which have a common continuation within the brain. The remaining somatic receptors of the general senses, scattered over the anterior part of the head, are innervated by one nerve (V) having its own central continuations. It has already been stated that all the afferent peripheral neurones which innervate these receptors (except the mesencephalic V) follow the general law of having their bodies located outside the neural tube. The central processes (root fibres) usually split on entering the tube, but the descending arms are the longer. Nerves I and II present certain special peculiarities.

The splanchnic effectors of the head include the usual splanchnic effectors—smooth muscle and glands—and also the branchial striated voluntary muscles. The somatic effectors are the remaining (myotomic) striated voluntary muscles. The striated voluntary muscles of the head fall into three groups; those of the eye (somatic); of the jaw, face, pharynx and larynx (splanchnic, modified branchial

musculature); and of the tongue (somatic).[1] The peripheral path to the smooth muscles and glands follows the same general law as in the body, *i.e.*, neurone bodies in the central nervous system send preganglionic root fibres to sympathetic ganglion cells, which in turn send their axones to the effectors (p. 448). The peripheral path to the splanchnic (branchial) striated voluntary muscles, on the other hand, follows the same law as obtains for the somatic striated voluntary muscles, *i.e.*, neurone bodies in the central nervous system send their efferent root fibres uninterrupted to the muscle. These distinctions are shown centrally by differences in grouping of the neurone bodies which supply respectively the somatic muscles, the splanchnic voluntary muscles, the smooth and cardiac muscles and glands *via* the sympathetic ganglia.

The higher coördinating apparatus or suprasegmental structures (p. 429) of the brain are essentially expansions of the dorsal walls of parts of the brain, each expansion having manifold afferent and efferent connections with the rest of the nervous system and having the endings and beginnings in it of its afferent and efferent paths complexly interrelated by enormous numbers of association neurones. The presence of these latter has probably necessitated the extensive layers of externally placed neurone bodies (cortex) characteristic of suprasegmental structures.

The structure of the basal part of the brain, connected with the cranial nerves (segmental brain, p. 429), is affected by both the peculiarities of peripheral structures mentioned above and by the presence of bundles of fibres and masses of gray forming portions of paths to and from suprasegmental structures (see below).

The following summary embodies the resulting general structural features of the brain:

Segmental Brain and Nerves

Afferent Peripheral (Segmental) Neurones. (1) *General Somatic Group* (common or general sensibility).—Semilunar ganglion of nerve V. The peripheral arms of the semilunar ganglion cells pass to the receptors of the skin of the anterior part of the head, to the mouth and meninges. The central arms of the ganglion cells form a descending tract in the medulla, the radix spinalis V. The terminal

[1] The facial muscles (muscles of expression) are not branchiomotor muscles but skin muscles of more recent origin. Arising in the region of the hyoid arch they are, however, innerved by the branchiomotor nerve of this region (motor VII).

nucleus of this tract is the continuation in the medulla of the dorsal horn. The axones of the terminal nucleus form secondary tracts to the thalamus and thence tertiary thalamo-cortical tracts pass to the central cortex cerebri. Axones of the mesencephalic nucleus of nerve V possibly innervate the muscle-tendon receptors of the jaw muscles and nerves III, IV and VI probably contain fibres to the muscle-tendon receptors of the eye muscles. A few of the ganglion cells of nerves, VII, IX and X probably also belong to the general somatic group. See path 1, 2, 3 and 4, p. 507.

(2) *Splanchnic Group* comprising nerves VII (geniculate ganglion), IX (superior and petrosal ganglia) and X (jugular and nodose ganglia). The nerves of taste probably belong entirely to this group. The peripheral arms of these ganglia innervate visceral receptors and the central arms form a descending tract in the medulla, the fasciculus solitarius. This tract ends in terminal nuclei which in turn give rise to secondary tracts. See paths 6 and 7, p. 509.

(3) *Vestibulo-Semicircular Canal Group*.—Ganglion of Scarpa of nerve VIII. The peripheral arms pass to the hair cells, the receptors, of the vestibule and semicircular canals. The central arms constitute the vestibular portion of VIII, forming descending tracts in medulla and terminating in several vestibular terminal nuclei (including Deiters' nucleus). See path 8, p. 510.

(4) *Acoustic Group*.—Ganglion spirale of nerve VIII. The peripheral arms terminate around the hair cells, the receptors, of the organ of Corti of the cochlea. The central arms form the cochlear part of nerve VIII and terminate in the medulla in various nuclei which originate the secondary tract (lateral fillet) to midbrain and to medial geniculate body in thalamus. A third (or fourth?) system of thalamo-cortical neurones passes to the temporal cortex cerebri (also p. 544. See path 9, p. 510). The cell bodies of the ganglion of Scarpa and ganglion spirale are bipolar.

(5) *Visual Group*.—Ganglion in retina. The receptors are the rod and cone cells of the retina. What may be best regarded as the second neurone system begins in the retina and forms the secondary tract (optic "nerve") to the lateral geniculate body and pulvinar in thalamus. The third thalamo-cortical neurone system passes to the calcarine cortex cerebri (also p. 599). See path 10, p. 510.

(6) *Olfactory Group*.—"Ganglion" cells in olfactory mucous membrane form the olfactory nerve (fila olfactoria) which terminates in the olfactory bulb and represent both receptors and ganglionic

neurones. Secondary tracts from the olfactory bulb (and tertiary tracts) proceed to diencephalon and hippocampus (also p. 437). See path 11, p. 510.

EFFERENT PERIPHERAL (SEGMENTAL) NEURONES.—(1) *Somatic.* Medial nuclei located near the median line in the gray matter of hindbrain (nerves XII and VI), and midbrain (nerves IV and III), to muscles of tongue (nerve XII) and eye (nerves VI, IV and III). Nerves III, IV and VI probably also contain afferent nerve fibres (p. 581 and path 4, p. 509).

(2) *Splanchnic.* (*a*) Lateral nuclei in the gray matter of the hindbrain. Their axones pass to the striated voluntary muscles of the jaw (nerve V), face (VII), pharynx and larynx (IX and X). (*b*) Nuclei of nerves III, VII, IX and X more deeply placed in the gray of mid- and hindbrain. Their axones pass as preganglionic fibres to sympathetic ganglia of head and body. (*c*) Sympathetic ganglia. These are the sympathetic ganglia of the head (ciliary, sphenopalatine, submaxillary, sublingual and otic). These ganglia receive the above preganglionic fibres from nuclei of cranial nerves III, VII, IX, and X. (See also Fig. 311).

INTRASEGMENTAL AND INTERSEGMENTAL NEURONES.—These are represented principally by the gray reticular formation of the hindbrain and midbrain and long descending tracts external to it. The gray reticular formation is composed of neurone bodies and short intersegmental tracts intermingled. Among the former are certain well differentiated nuclei (*e.g.*, nucleus ruber, nucleus of Deiters, and nucleus of the medial longitudinal fasciculus) the axones of which form long, principally descending, intersegmental tracts external to the gray reticular formation. These may also be links in efferent suprasegmental paths (see also paths 20, 21, 22, 29, 30, 31 and 32). Other cells in the gray reticular formation form the shorter tracts within it—reflex and associating efferent peripheral nuclei. The reticular formation may also contain motor nuclei of the cranial nerves and is traversed by various fibres passing to tracts and by terminals from tracts. In a general way it thus represents the associative apparatus of the segmental brain as contrasted with the cortical associative apparatus of pallium, colliculi and cerebellum.

AFFERENT AND EFFERENT SUPRASEGMENTAL PATHS

These paths are paths from receptors of body and head to cerebellum, midbrain roof (colliculi) and pallium and paths from cere-

FIG. 368.—Diagram showing some of the More Important Cerebellar Connections. Paths which an impulse might follow in passing from periphery to cerebral cortex *via* the cerebellum, and from cortex to periphery



bellum, midbrain roof and pallium to effectors of head and body. There are also paths connecting pallium, mid-brain roof and cerebellum. For convenience they are here given together. The various parts of the nervous system involved should be consulted for further details.

Afferent Suprasegmental Paths

A. Afferent Pallial

General Body Sensibility

(1) *Touch and Pressure* (general somatic).—(*a*) Discriminative. Receptors: tactile corpuscles of Meissner and possibly other receptors. Neurone group 1: spinal, trigeminal (Gasserian) and possibly a few facial and vagal ganglionic neurones whose peripheral processes terminate in the receptors and whose central processes (coarse fibres of dorsal spinal roots) split into ascending and descending arms. In the cord the path passes by the long ascending arms which terminate in the nuclei of the columns of Goll and Burdach. In the brain the root fibres concerned all probably end in one of the terminal trigeminal nuclei (especially "sensory nucleus" V?). Neurone group 2: crossed bulbo-thalamic neurones of nuclei gracilis and cuneatus (medial lemniscus) to which are probably added (especially *via* trigeminal, pontile lemniscus?) secondary trigeminal tracts from the terminal trigeminal nucleus. Neurone group 3: thalamo-cortical neurones to the post-central cortex pallii. This path being discriminative is purely cortical, *i.e.*, while relayed in the thalamus it does not undergo any special thalamic diffusion or reënforcement (non-affective, without feeling tone, see Thalamus, p. 589). The actual discrimination is of course performed by the cortical association neurones of the pallium.

(*b*) Mere Contact, Pressure, and Their Localization. Receptors: probably the same as in (*a*) and also the diffuse peritrichial endings and deeper end organs (dermal corpuscles of Pacini?). Neurone group 1: spinal, trigeminal and a few facial and vagal ganglionic neurones whose peripheral processes terminate in the receptors. The central processes to the cord (coarse and fine root fibres?) have short and medium ascending arms. Neurone group 2: crossed medial spino-thalamic neurones (marginal cells? large central cells of dorsal horn?) forming a tract medial to the lateral spino-thalamic tract and, according to some authorities, joining the medial lemniscus in the bulb. Neurone group 3: thalamo-cortical neurones to postcentral cortex pallii.

The above are the two tactile-pressure paths as usually given but there are several qualifications regarding the second: There may be short neurones intercalated between group 1 and 2; as already seen it is doubtful whether group 2 passes to the thalamus, probably only to bulb and tegmentum (p. 489); there are not improbably still other tactile paths in the cord, possibly uncrossed and, finally, a part of this path undergoes thalamic diffusion as shown by the normally agreeable or disagreeable qualities of the stimuli in question and by the change in such qualities in thalamic lesions.

The trigeminal ganglionic neurones terminate (long descending arms) in

the terminal nuclei of the spinal V, from which the secondary tracts probably pass upward in the vicinity of the spino-thalamic tracts. These may terminate more medially in the thalamus than the medial lemniscus. There is some thalamic diffusion. Terminal neurones are the thalamo-cortical group.

(*2*) *Pain.* Cutaneous pain (general somatic). Receptors: diffuse terminations in epithelium and connective tissue (and possibly the various other cutaneous receptors, see below). Neurone group 1: small spinal ganglionic neurones whose peripheral and central processes are often non-medullated, the latter entering the zone of Lissauer, with short ascending arms terminating in the gelatinosa of Rolando (nucleus sensibilis proprius). Some collaterals may cross in the posterior commissure. Neurone group 2: intrasegmental cells of the gelatinosa with short axones probably to the adjacent lateral column. These may send collaterals across in the posterior commissure. Neurone group 3: long crossed spino-thalamic neurones (nuclei magnocellulares centralis and basalis?) forming the lateral spino-thalamic tract. In the thalamus the path undergoes a thalamic diffusion (medial thalamic nuclei, see Thalamus, p. 598) and finally thalamo-cortical neurones pass to cortex pallii to reënforce the activities of its associative-memory mechanisms (*e.g.*, an object may be recognized visually, etc. as one which has previously caused pain on contact and the thalamo-cortically produced pain-avoiding "feeling tone" ensures sufficiently energetic action).

In the head the pain path principally involves the trigeminal ganglionic neurones, the relays in the trigeminal terminal nucleus (practically a continuation of the dorsal horn) being probably of the same character as in the cord. The long crossed tract is probably near the lateral spino-thalamic tract.

According to the above, (*a*) pain has its own receptors and ganglionic neurones. According to another view (*b*) it may have the same receptors as touch, pressure, proprioceptive, etc., and the same ganglionic neurones, but centrally, *via* collaterals, the more intense (painful) stimuli overflow into the shorter intercalated neurones indicated above and are shunted off to the lateral spino-thalamic, etc. tracts. Or (*c*) the same ganglionic neurone may innervate special end organs and have diffuse terminations. Finally (*d*) the various receptors may have a double innervation, their own specific innervation and also by a pain fibre. The frequent presence of fine accessory fibres in receptors may be interpreted in this manner. Thus two kinds of paths may occur, one with peripheral and one with central differentiation (see Fig. 310). There may be also a peripheral differentiation between other affective (protopathic) and discriminative (epicritic) stimuli (Head).

Deep pain may also have an uncrossed path in the dorsal column.

The path of visceral pain (properly under splanchnic paths) is not well known, even its peripheral part. It is not certain whether it reaches the central nervous system *via* the thoracic sympathetic or the vagus or both, whether by cerebrospinal ganglionic neurones or by sympathetic neurones as well (p. 453, Fig. 310). One possibility is that visceral sensations traveling by spinal ganglionic neurones may, when intense, also pass to neighboring cutaneous pain neurones in the ganglion *via* collaterals (ganglion cell type *b*, p. 440) thus accounting for referred pains. If the spinal ganglion cell's peripheral process to visceral receptor passes to other segments *via* the sympathetic cord, etc., the

reference of visceral pain to external parts in other segments might thus be accounted for. The central path may be the same as for cutaneous pain.

(3) *Temperature* (general somatic and splanchnic).—The thermal receptors are not well known. The path may be regarded as practically the same as that of pain though the two may, rarely, be dissociated centrally.

(4) *Position and Movement* (proprioceptive).—Receptors: muscle spindles, tendon organs of Golgi and possibly other end organs in the vicinity of muscle, tendon and joint. Neurone group 1: spinal, certain vagal and glossopharyngeal and possibly facial and trigeminal ganglionic neurones, also apparently certain central neurones of nerves III, IV, V and VI, all of whose peripheral processes terminate in the above receptors. In the case of the spinal ganglionic neurones the central processes enter the zone of root entry (p. 475) and divide into descending and ascending arms of which the latter terminate in the nuclei gracilis and cuneatus. Neurone group 2: crossed bulbo-thalamic neurones (medial lemniscus) with possible accessions from the trigeminal terminal nuclei in bulb and pons (secondary trigeminal tracts), and from the ventral terminal nucleus of the solitary fasciculus (secondary vago-glossopharyngeal, and facial? tracts.) Neurone group 3: thalamo-cortical neurones to post-central cortex pallii. This is a purely cortical discriminative path not apparently involving specific thalamic activities.

(5) *Vibration* (pallæsthetic, proprioceptive, not of such primary character as the above but of clinical importance). The receptors are not known. The path is similar to (4) but also has a thalamic (feeling tone) component.

(6) *General Splanchnic Sensation* (see also path 2) (visceral pain, general feelings of organic ill-being or well-being, hunger, thirst, sexual sensations, etc.). The receptors are not well known. They may lie partly in the muscle coats of the viscera. The path or paths are also uncertain. They may be similar to those of pain and temperature, which are allied to the splanchnic reactions in general character and "affect," or they may pass upward *via* non-medullated neurones not yet clearly distinguished. Visceral sensations are probably largely thalamic but secondarily activate the cortex pallii. They arouse or are aroused by emotional states. According to Winkler paths in the central gray may play an important part in visceral neural activities.

Special Senses

(7) *Taste* (special splanchnic).—Receptors: taste buds on tongue and parts of pharynx (and larynx?). Neurone group 1: certain facial (geniculate) glossopharyngeal (petrosal) and possibly vagal ganglionic neurones whose peripheral processes terminate in taste buds and whose central processes end in nucleus gustatorius of bulb. The secondary tracts are not well known. According to some they join the opposite medial lemniscus, more probably they pursue a different path (in the central gray, *via* bundle of Schütz (Winkler)?), crossing higher up. The path may involve the mamillary body and may reach the pallium *via* the bundle of Vicq d'Azyr and anterior thalamus (see p. 597). It is supposed to terminate in or near the olfactory part of the pallium (limbic lobe).

(8) *Vestibular* (special proprioceptive).—Receptors: the hair cells of the ampullæ of the semicircular canals and of the maculæ of utricle and saccule. Neurone group 1: the vestibular ganglionic neurones (ganglion of Scarpa) whose peripheral processes terminate around the hair cells and whose central processes terminate in the lateral (Deiter's), medial (Schwalbe's), superior (von Bechterew's) and descending root terminal nuclei and in the cerebellum. The further continuation to the pallium is doubtful. It may be by path 9 or *via* the cerebellum by path 12 or by the medial lemniscus.

(9) *Hearing* (distance, exteroceptive).—Receptors: the hair cells of the organ of Corti. Neurone group 1: the cochlear ganglionic neurones (spiral ganglion) whose peripheral processes terminate around the hair cells and whose central processes terminate in the dorsal (tuberculum acusticum) and ventral (accessory) cochlear terminal nuclei and possibly also in the nuclei of the superior olive, trapezoid body and lateral lemniscus. Neurone group 2 (and 3?): the preceding nuclei and their axones, forming the principally crossed lateral lemniscus to the inferior colliculus and possibly part of the brachium of the inferior colliculus to the medial geniculate body. Neurone groups 3 (and 4?): colliculo-geniculate neurones from inferior colliculus to the medial geniculate body, whose axones form the brachium of the inferior colliculus. Neurone group 4 (and 5?): the terminal geniculo-temporal group whose axones pass from the cell bodies of the medial geniculate to terminate in the transverse gyri of Heschl of the superior temporal convolution of the pallium. The strongly marked affect (thalamic) quality of sound has not been much studied neurologically.

(10) *Sight* (distance, exteroceptive).—Receptors (regarded by some as neurone group 1): the rod and cone cells of the retina. Neurone group 1: the bipolar cells of the retina (ganglion retinæ = ganglionic neurones?). Neurone group 2: the ganglion cells of the retina whose axones form the optic "nerve" and tract, partly decussating in the optic chiasma and terminating in the superior colliculus (reflex), lateral or external geniculate body and pulvinar thalami. Neurone group 3: geniculo-calcarine neurones whose axones terminate in the area striata of the calcarine cortex pallii. Other thalamo-cortical neurones may pass, probably to the occipital region, from the pulvinar. These may have something to do with the agreeable or disagreeable qualities of certain visual stimuli (too bright light, etc.).

(11) *Smell* (probably to be regarded as a special splanchnic sense).—Its complicated paths (not all pallial) can only be given much abbreviated. Receptors and neurone group 1: the nerve cells in the olfactory nasal membrane whose axones (fila olfactoria) terminate in the bulbus olfactorius in synapses (glomeruli olfactorii) with the dendrites of the mitral and other cells of the bulb. Neurone group 2: the mitral and other cells send their axones (*via* olfactory tracts or lateral olfactory striæ) to the primary cortical areas of the anterior (tuberculum and trigonum olfactorium) and posterior (anterior perforated space or olfactory area, gyrus semilunaris and gyrus ambiens) olfactory lobes and unciform gyrus (part of pyriform lobe). The anterior cerebral commissure unites these primary cortical areas of one side with the other. From the primary cortical areas tracts pass to the secondary cortical areas *i.e.*, tuber

cinereum (*via* ventral olfactory radiation), lamina terminalis (*via* fasciculus septi pellucidi), gyrus subcallosus and area of Broca (*via* stria olfactoria medialis), indusium (*via* stria Lancisii), gyrus dentatus and cornu ammonis (*via* fornix) and nucleus amygdalæ (*via* stria semicircularis).

Finally, fibres from the primary cortical areas and cornu ammonis (*via* fornix) terminate in the small-celled lateral nucleus of the mammillary body. The medial nucleus of the latter (corpus candicans) sends fibres (mammillo-thalamic fibres, bundle of Vicq d'Azyr) to the anterior nucleus of the thalamus. The latter sends fibres to the cortex pallii which would thus constitute a tertiary, neopallial, olfactory area.

(12) *Cerebello-pallial.*—Neurone group 1: cortical cerebellar neurones (cells of Purkinje) to nucleus dentatus (and possibly nucleus globosus and nucleus emboliformis) in the cerebellum. Neurone group 2: crossed dentato-rubral and dentato-thalamic neurones whose axones form the superior cerebellar peduncle and terminate in the nucleus ruber and thalamus. Neurone group 3: rubro-pallial and thalamo-pallial neurones. There may be rubro-thalamic neurones intercalated in this path. By way of the thalamus cerebellar impulses may possibly also reach the corpus striatum.

B. Afferent Mesencephalic

(13) *Spino-collicular* or *Spino-tectal.*—This path is probably unimportant in man. It may convey tactile and painful stimuli by the appropriate spinal ganglionic and crossed spino-collicular (spino-tectal) neurones to the colliculi. It may have some reflex function and is not a sensory path in the strict sense.

(14) *Retino-collicular.*—The superior colliculi also receive optic stimuli (see path 10), either optic fibres directly or possibly *via* the lateral geniculate body. These are for various optic reflexes. The superior colliculi also receive pallio-collicular fibres mentioned below (see path 22).

C. Afferent Cerebellar

(15) *General Body Proprioceptive.*—(*a*) Receptors: the proprioceptors (muscle spindles, tendon organs of Golgi, etc.) of the body. Neurone group 1: large spinal ganglionic neurones whose peripheral processes terminate in the above and whose central processes enter the root entry zone as coarse fibres which divide into descending and long ascending arms. The latter some distance above bifurcation send collaterals to the nucleus magnocellularis basalis (Clarke's column). Neurone group 2: the nucleus magnocellularis basalis sends its uncrossed axones as the dorsal spino-cerebellar tract to the caudal part of the cerebellar vermis (*via* the restiform body). Some fibres may end in the lateral reticular nucleus of the bulb the axones of which pass also to the cerebellar vermis.

(*b*) Similar to the preceding, except neurone group 2 is cells (nucleus magnocellularis centralis?) whose crossed and uncrossed axones pass as the ventral spino-cerebellar tract to the anterior portion of the vermis.

(*c*) According to some authorities the nuclei of the columns of Goll and

Burdach send some of their axones (uncrossed and crossed) to the cerebellum *via* the restiform body. The first part of the path would be similar to (4) except neurone group 2, the terminal group, would send its axones to the cerebellum instead of upward in the medial lemniscus.

(*d*) Proprioceptive stimuli from the striated muscles and tendons of the head probably pass to the cerebellum but their paths are not well known.

(16) *Special Proprioceptive or Vestibular.*—Receptors: the hair cells of the ampullæ of the semicircular canals and of the maculæ utriculi and sacculi. Neurone group 1: the vestibular ganglionic neurones (ganglion of Scarpa) whose peripheral branches terminate around the hair cells and whose central processes pass either directly to the cerebellar cortex or *via* (neurone group 2) vestibulo-cerebellar neurones.

(17) *Olivo-cerebellar.*—The important group of olivo-cerebellar neurones, whose axones probably pass to all parts of the cerebellar cortex, forms the last link in afferent cerebellar paths not well known. According to some the inferior olivary nucleus receives spino-olivary fibres (tract of Helweg?) representing especially stimuli from the upper extremities (Winkler). It certainly receives fibres from higher centers (midbrain, thalamus or lenticular nucleus?) *via* the central tegmental tract.

Pallio-cerebellar paths are obviously afferent cerebellar but are given below under efferent pallial paths (path 19).

Efferent Suprasegmental Paths

A. Efferent Pallial

(18). *Voluntary Motor.*—This can best be divided into (*a*) the path to the voluntary striated muscles of the body innervated by the motor nuclei of the ventral horn and (*b*) the path to those muscles innervated by the motor nuclei of the cranial nerves. (*a*) Neurone group 1: *pallio-spinal* upper motor neurones; those cells of Betz whose bodies lie in the lamina ganglionaris (internal pyramidal layer) of the upper part of the precentral convolution of the pallium and whose fibres pass down through the corona radiata, posterior or lenticulo-thalamic limb of the internal capsule (see p. 607 and Fig. 386), middle part of each pes pedunculi, pons, basal part of the bulb ("pyramids" in strict sense), partially decussate as described on p. 492, and pass down the cord as the lateral (principally crossed fibres) and medial (uncrossed) pyramidal tracts. Neurone group 2: probably short spino-spinal neurones (diffuse groups?). Neurone group 3: somatic efferent peripheral neurones (lower motor neurones of the ventral horn) whose axones pass out as the large medullated fibres of the ventral roots and terminate in the effectors, the voluntary striated muscles of trunk, neck and limbs.

(*b*) Neurone group 1: *pallio-nuclear* neurones or upper motor neurones to motor nuclei of cranial nerves; those cells of Betz in the middle and lower portion of the precentral convolution and the inferior frontal (eye) whose fibres pass down through corona radiata and internal capsule, near the genu (p. 607 and Fig. 386), to the pes pedunculi. There are then given off, at various levels,

bundles of pyramidal fibres to motor cranial nerve nuclei which, on account of their unusual position, are known as the aberrant pyramidal bundles. (1) The *subthalamic bundle*, given off in the subthalamic level, probably crossed and uncrossed, to nuclei of nerves III and IV. This bundle is not constant. It is supposed to raise and lower the eyeballs. (2) The midbrain or *pes-lemniscus bundles* (oculogyric and cephalogyric or eye- and head-turning fibres). These are detached from the pes at the midbrain level. Some of them pass around mesially on the outside of the pes (*superficial* or *medial pes-lemniscus bundle*) to the medial side of the medial lemniscus of the same side, others pass laterally through the substantia nigra (*deep* or *lateral pes-lemniscus bundle*) and lie in or near the medial lemniscus. Some of the pes-lemniscus fibres pass directly to the nuclei of nerves III and IV, crossed and uncrossed. Others pass, uncrossed, downward in the lemniscus and then cross to the opposite nucleus VI while the remainder keep on downward, uncrossed, and pass to the nuclei XI of the same or opposite side. (3) The *upper pontile aberrant bundles* detach themselves from the main pyramidal system about the level of the motor nucleus of nerve V. They also enter the medial lemniscus, some passing directly, crossed (and uncrossed?) to the motor V nucleus, others keeping in the medial lemniscus till near the level of voluntary motor (branchiomotor) nuclei IX, X (ambiguus) and XII where they pass, crossed and uncrossed, to these nuclei. (4) The *bulbo-pontile bundle* separates near the lower border of the pons, some fibres proceed crossed and uncrossed to the nucleus of the "upper" nerve VII (to upper facial muscles) or crossed to the lower motor nucleus VII while others keep on caudally in the lemniscus to pass, crossed and uncrossed, to the motor (voluntary) nuclei of IX, X and XII. It is interesting to note that (3) innervates nuclei performing chiefly the act of eating and (4) the nuclei performing the act of speech, though it is not claimed that these two bundles are specifically for these two acts. (5) *Bulbar bundles* pass from the pyramids, probably crossed and uncrossed, to the voluntary motor nuclei of IX, X and XII. Remainders of the aberrant pyramidal bundles in the medial fillet also rejoin the pyramids. Where fibres are both crossed and uncrossed probably the former usually predominate. Neurone group 2: the lower motor neurones of the various above cranial nerve nuclei whose axones pass out as motor root fibres to the effectors *i.e.*, the voluntary striped muscles of the eyeball, jaw, face, pharynx, larynx, tongue, sterno-mastoid, trapezius and probably other neck muscles. It is not always certain in many nerves whether the bilateral (crossed and uncrossed) control is due to the additional presence of uncrossed upper motor neurones or to crossed lower motor neurones, or both.

The musculatures which are thus bilaterally controlled are probably in general those musculatures in which one side cannot be voluntarily contracted alone (vertical eye movements, jaw, upper facial (as a rule), vocal cords and some tongue movements, also the axial trunk musculature). The reversed action of such muscles as the internal pterygoid and sterno-mastoid must also be considered.

(19) *Pallio-ponto-cerebellar* (*a*) Neurone group 1: *frontal* pallio-pontile neurones, *i.e.*, cortical cells probably lying in the prefrontal convolutions, whose axones pass downward in corona radiata, anterior or lenticulo-caudate limb of

internal capsule (p. 607 and Fig. 386) and medial part of the pes and terminate in the pontile nuclei. Neurone group 2: crossed ponto-cerebellar neurones whose bodies lie in the nuclei pontis and whose axones pass across (a few uncrossed?) as the brachium pontis or middle cerebellar peduncle to the cortex of the opposite cerebellar hemisphere.

(*b*) Neurone group 1: *temporo-parieto-occipital* pallio-pontile neurones whose bodies lie probably in the temporal and possibly in the parietal and occipital lobes, whose axones pass downward in corona radiata, retro- and sublenticular portions of the internal capsule (p. 607 and Fig. 386) and lateral portion of the pes and terminate in the nuclei pontis. Neurone group 2 is composed of crossed ponto-cerebellar neurones similar to the preceding. This path with the addition of path 31 or 32 would together constitute a roundabout pallio-cerebello-lower motor neurone path.

Some authorities assert there are rubro-cerebellar fibres in the superior cerebellar peduncle. By comparing with paths 20 and 21 below, it is evident that this would open the possibility of a pallio-rubro-cerebellar and a strio-rubro-cerebellar path.

All pallio-cerebellar paths obviously enable the pallium to secure a proper coöperation of the cerebellar synergizing activities in all pallially initiated movements. (See also p. 521.)

(20) *Pallio-rubro-spinal.*—Neurone group or groups 1: pallio-rubral neurones composed of cortical cells situated possibly in the parietal, more probably in the prefrontal and opercular regions whose axones terminate in the nucleus ruber. Neurone group 2: crossed rubro-spinal neurones. Neurone group 3: lower motor neurones of the ventral horn of the cord innervating the effectors *i.e.*, the voluntary striated muscles of the trunk and limbs. This path is regarded by many as an older (palæëncephalic) path for pallial movements of voluntary striated muscles, largely superseded by path 18, and at present accessory to it (posture? associated movements?).

(21) *Strio-rubro-spinal.*—While not, strictly speaking, an efferent pallial path the following path may be mentioned: Neurone group 1: strio-rubral neurones, the large cells of the lenticular nucleus whose fibres (part of the ansa lenticularis) pass to the nucleus ruber. Neurone groups 2 and 3 are the same as 20. The same considerations apply here as to 20. Some authorities have thought that this path of "palæokinetic" movements passes out peripherally by another system of motor fibres (J. Ramsey Hunt) (sympathetic to voluntary striated muscles??). The connection with the thalamus may provide an afferent pallio-thalamo-striate path to the striatum. (See also corpus striatum, p. 601.)

(22) *Pallio-collicular* or *Pallio-tectal.*—Cells in the calcarine cortex send fibres to the superior colliculi. The colliculi in turn act reflexly upon muscles producing eye movements, possibly head movements and other bodily movements (see paths 29 and 30). This reflex mechanism is thus under control of the visual cortex and the pallio-collicular fibres are supposed to cause the adjustment of eyes (and other parts) to objects in the field of vision (fixation of gaze). This is a fundamental, early established and almost an involuntary eye adjustment and may be contrasted with the more purely voluntary and later acquired turning of eyes etc. to sound and other stimuli (language etc.) which may be per-

formed by the frontal eye center and the oculogyric and cephalogyric fibres of the voluntary motor system (path 18, *b* 1 and 2). Other parts of the cortex also especially parietal, appear to influence eye movements.

(23) *Pallio-nigral fibres* to the substantia nigra have been described but their further connections and significance are not known.

(24) *Pallio-subthalamic fibres* to the corpus subthalamicum of Luys have also been affirmed to exist but not much further is known.

(25) *Pallio-striate fibres* to the corpus striatum are denied by most authorities but the possibility of collaterals from passing projection fibres has not perhaps been entirely excluded.

(26) *Pallio-thalamic* fibres pass from possibly all parts of the cortex to thalamus. For their significance see Thalamus.

(27) *Efferent Olfactory* (from pallium and rhinencephalon).—From the primary cortical olfactory areas (see path 11) fibres pass to the infundibular region, to tegmentum and to the mammillary body; fibres from the cornu ammonia (*via* fornix) also terminate in the small-celled lateral nucleus of the mammillary body. From the medial nucleus of the latter (beside the mammillothalamic bundle) there passes the fasciculus dorsalis tegmenti (bundle of Gudden) terminating in the nucleus dorsalis tegmenti (ganglion of Gudden) from which fibres are said to pass into the posterior longitudinal fasciculus (to oculomotor nuclei?) and dorsal longitudinal bundle of Schütz (see below). From the lateral large-celled nucleus of the mammillary body passes the bundle known as the peduncle of the mammillary body which is finally lost among the fibres of the medial lemniscus. [According to some authorities these latter fibres are afferent to the mammillary body and may represent part of a gustatory afferent path (see path 7)].

From primary cortical olfactory areas the tractus rhinencephalo-habenularis (stria terminalis in tænia thalami) passes to the nucleus (ganglion) habenulæ. The latter sends habenulo-interpeduncular fibres (fasciculus retroflexus) to the ganglion interpedunculare in the base of the midbrain. Thence fibres pass dorsally into the central gray of the midbrain where, with the fasciculus dorsalis tegmenti they pass caudally as the dorsal longitudinal bundle of Schütz probably coming into especial relations with certain nuclei of nerves IX, X and XII. (Fig. 384.)

There thus appear to be two main descending paths from the olfactory cortices: one from primary and secondary cortical areas pursuing a more ventral route *via* the mammillary body (and other basal structures), the other probably only from the primary cortical areas and pursuing a more dorsal route at first, *via* the nucleus habenulæ.

(28) *Efferent Splanchnic.*—This path is not well known anatomically but physiological evidence points to its having relays in bulb as well as cord and probably partially in the thalamus: The following path is tentatively suggested: Neurone group 1: pallio-thalamic neurones *via* lateral thalamus to medial thalamus. Neurone group 2: thalamo-bulbar neurones. Neurone group 3: bulbo-spinal neurones. Neurone group 4: sympathetic neurones of the cord whose fibres pass out as the preganglionic fibres of the white rami communicantes to the vertebral and prevertebral sympathetic ganglia. Neurone group

5: sympathetic ganglionic neurones to the effectors *i.e.*, smooth muscle, cardiac muscle, voluntary striated muscle and glands. There are probably also descending splanchnic forebrain paths to the cranial and sacral sympathetic nuclei. It is also possible that the subthalamus and substantia nigra are involved in splanchnic paths.

In the bulb the splanchnic path lies in the reticular formation near the nuclei of nerve X. Our lack of knowledge of its anatomy may arise from its being composed largely of non-medullated fibres not so easily studied with our present methods.

The splanchnic path is the path by which "emotional" states of the thalamo-pallial apparatus (painful, disagreeable or agreeable sensations, cortical perceptions associated with previous agreeable or disagreeable experiences etc.) cause involuntary bodily changes in the vegetative system (secretory, vasomotor, peristaltic, pupillary etc.).

B. Efferent Mesencephalic

(29) *Colliculo-bulbar.*—Neurone bodies in the superior colliculi send crossed colliculo-bulbar and colliculo-spinal (?) fibres (predorsal bundle) to the nucleus motorius VII (blinking reflex) and possibly other motor nuclei, also collaterals to nuclei III, IV (and VI?). (Fig. 383.)

(30) *Colliculo-Medial Longitudinal Fasciculus.*—Neurone bodies in the colliculi probably send fibres to the nucleus of the posterior commissure and the nucleus of the medial or posterior longitudinal fasciculus whose fibres may send collaterals to the oculomotor nuclei and to the ventral horn of the cord. Other collicular fibres, uncrossed, pass directly into the medial longitudinal fasciculus in which they pass downward at least as far as the cervical cord. As the superior colliculi receive optic fibres, paths 29 and 30 represent probably parts of optic reflex mechanisms. This reflex apparatus is also under the influence of the visual cortex as pointed out in path 22.

C. Efferent Cerebellar

(31) *Superior Peduncular Path.*—(*a*) *Cerebello-rubro-spinal.* Neurone group 1: cortico-dentate neurones *i.e.* cortical cerebellar neurones (cells of Purkinje) of the hemispheres whose fibres terminate in the dentate (and possibly the emboliform and globose) nuclei of the cerebellum. Neurone group 2: crossed dentato-rubral neurones, whose fibres constitute the superior cerebellar peduncle, to the nucleus ruber. Neurone group 3: crossed rubro-spinal neurones forming the rubro-spinal tract to the spinal cord. Neurone group 4: lower or peripheral motor neurones of ventral horn of cord which innervate the effectors, the voluntary striated body musculature.

The cerebello-pallial path (12) is obviously also an efferent cerebellar path.

By comparing with paths 20 and 21 it is evident that the rubro-spinal neurones form a common path for impulses from cerebellum (31), corpus striatum (21) and probably pallium (20) to the cord besides being a link in stimuli from cerebellum to pallium and possibly other higher centers (see path 12). The latter connection may involve a different, newer, portion of the nucleus ruber

(neo-ruber) which does not give rise to rubro-spinal fibres (von Monakow). It will also be noticed that the connections of the red nucleus are uncrossed with the pallium, crossed with the cerebellum and crossed with the cord. These relations apparently arise from the fact that the red nucleus forms links in pallial paths, which are crossed, and also cerebellar paths, which are uncrossed, and yet both regulate the same half of the body. Consequently the pallio-rubro-spinal path undergoes only one crossing while the cerebello-rubro-spinal, using the crossed rubro-spinal neurones, uses also crossed dentato-rubral neurones. This results in the efferent cerebellar path controlling the same half of the body and explains the curious and apparently unnecessary double crossing in the efferent cerebellar path. In like manner all connections between cerebellum on the one hand and midbrain and forebrain on the other are largely crossed.

The cerebello-rubro-spinal path is one of those whereby the cerebellum exercises its regulating influence upon the voluntary striated muscles of the body. Injury to it appears to result in the production of irregular involuntary movements of the parts innervated not only during the performance of a movement but also when the part is in a state simply of tension, *i.e.*, not completely at rest.

(*b*) *Cerebello-reticular.*—Neurone group 1: cortico-dentate neurones as above. Neurone group 2: dentato-reticular (superior peduncle) neurones (probably crossed) to the gray reticular formation. The further course of this path is not known but the intersegmental neurones of the reticular formation, some of which are of considerable length, may carry the cerebellar impulses to the appropriate motor cranial nerve nuclei in the same manner as is done by the rubro-spinal tract to the motor ventral horn cells of the cord.

Superior peduncular fibres are also stated to terminate in nucleus III.

(32) *Juxtarestiform Inferior Peduncular.*—(*a*) *Cerebello-vestibulo-spinal.*—Neurone group 1: cortico-fastigial neurones, *i.e.*, cortical cerebellar neurones (cells of Purkinje) of vermis and hemisphere, terminating in nucleus fastigii (nucleus tecti). Neurone group 2: fastigio-vestibular neurones to Deiters' nucleus and other vestibular (and reticular?) neurones. Neurone group 3: Vestibulo-spinal neurones (p. 495). Neurone group 4: lower motor neurones of ventral horn of cord whose fibres pass to the effectors, the voluntary striated muscles of the body.

(*b*) *Cerebello-vestibulo-ocular.*—In this path the axones of vestibular nuclei pass *via* the medial longitudinal fasciculus to nuclei of nerves VI, IV, and III.

Inasmuch as Deiters' and other vestibular nuclei receive directly vestibular root fibers there exist the vestibulo-spinal and vestibulo-ocular reflex paths not involving the cerebellum, making it a matter of uncertainty how far the latter may be involved in the various vestibular reactions such as deviations of movements of the extremities (pass-pointing), staggering, nystagmus (eye-deviations), vertigo and vomiting, which may all result from stimulation (head-turning, heat, cold and electrical) of the vestibular nerve. (See Figs. 361 and 368).

General Considerations Concerning the Afferent and Efferent Paths

The various *afferent paths* may be regarded as part of the differentiating mechanism of the nervous system. Each stimulus from any part of the body

may be differentiated by the nervous system and thereby give rise to a different neural reaction according to its quality or kind (*e.g.* tactile, thermal, proprioceptive, painful, visual, etc.), according to its "affective" character or feeling tone (agreeableness or disagreeableness), and according to its "discriminative" character *i.e.* its intensity and its relation in time and space to other stimuli of the same or different quality. The first differentiation is a peripheral one and is performed by the receptors, whereby each afferent peripheral nerve fibre is affected principally by only one kind of stimulus. The other, central, differentiations are those by which the reflex circuits are separated from the paths to the higher, suprasegmental centers; the differentiation into paths for the various kinds of stimuli; the differentiation into paths carrying impulses for affective and discriminative reactions and, often concomitantly with the preceding, the separation of the paths to their respective suprasegmental centers.

The separation of reflex circuits may be performed by collaterals from the afferent root fibres which pass to the lower motor neurones as appears to be the case with some of the simpler proprioceptive kinetic and tonic reflexes. More often, however, the collaterals or terminals of the afferent root fibres pass to the lower motor neurones by means of short secondary neurones or collaterals from long secondary neurones. This appears to be the arrangement of the superficial and probably the visceral reflexes. Other neurones may be intercalated in complicated reflexes, some of which are not always easily distinguished from conscious, voluntary reactions.

In the case of the nerves of the special senses where there is only one kind of stimulus, there is naturally no differentiation into paths for different kinds of stimuli, the only differentiations being into the reflex circuits and the paths of affect and discrimination. Each of these nerves has usually its own well-marked path to its higher center. In the case of nerves of general sensibility, carrying various kinds of stimuli, in addition to the separation of paths for reflex, affective and discriminative reactions, there is a differentiation into paths for the different kinds of stimuli. This differentiation takes place principally at the level of entry of the nerve and depends upon the distribution of the afferent root fibres.

The differentiation into paths for affective and discriminative reactions appears, in the case of the nerves of general sensibility, to take place partly at the level of entry (nucleus sensibilis?) and to be completed at the thalamic level. There may be also a peripheral differentiation (protopathic and epicritic). The differentiating mechanism in the paths for the nerves of special sense is not well known. It may be, in part, the smaller cells of the geniculate bodies and, in the optic pathway, the pulvinar thalami.

The separation of paths to different centers may begin at the level of entry (*e.g.* proprioceptive cerebellar and pallial paths) or higher (*e.g.* separation of spino-collicular from spino-thalamic tracts).

The discriminative associations—or dissociations—themselves are performed preëminently by the cortex pallii. This is especially true of those discriminations where time relations are involved as in so many comparisons between present and past stimuli (recognition, acquisition of skill and "learning" in general).

Owing to these successive differentiations, lesions at various levels may pro-

duce various sensory dissociations, *i.e.* sensory changes limited chiefly to one or more kind of sensation. Such, for example, is the tabetic dissociation where the most striking sensory loss is proprioceptive, the syringomyelic dissociation where the most striking loss is of pain and temperature and the dissociation seen in thalamic lesions where discrimination may be lost and "affect" increased.

In the *efferent paths* different levels of integration or fusion may be distinguished. The first is the suprasegmental level in which the various cortical associations (including pallial discriminations) are assembled into the beginnings of efferent paths (*e.g.* pyramidal, pallio-pontile and pallio-thalamic pallial areas and Purkinje cell areas sending axones to the cerebellar dentate and fastigial nuclei). Further partial integrations or fusions may take place at lower levels (*e.g.* the nucleus ruber, see path 31) until at the level of the efferent peripheral neurones the final fusion into the final common somatic and splanchnic paths takes place. It has already been seen that impulses reach the lower motor (somatic) neurones by the pyramidal, rubro-spinal and -bulbar, colliculo-spinal and -bulbar, vestibulo-spinal and -ocular, and reticulo-spinal intersegmental tracts and collaterals and terminals of afferent roots and secondary tracts, conveying to the lower motor neurones pallial, striate, thalamic, midbrain, cerebellar and various reflex influences producing voluntary, emotional, habitual, reflex and tonic reactions. The leading reaction is the conscious, purposeful, voluntary movement produced principally by the pyramidal tracts but with the coöperation of the various extra-pyramidal and reflex paths. Injury to the former results in loss of voluntary movement with the various reflex and tonic changes previously mentioned (p. 494); injury to extra-pyramidal paths may result not in loss but disturbances of voluntary movement, often with reflex and tonic changes. The disturbances of voluntary movement in some cases resemble those seen in uncontrolled emotional and infantile reactions. The various extra-pyramidal mechanisms are not well understood and their comprehension is obviously rendered more difficult by the partial integrations already mentioned. In localizing lesions affecting efferent paths, the various levels of integration have to be taken into account. The clinical picture, for example, produced by a lesion of the path of voluntary movement above its fusion with other efferent paths into the final common path ("spastic" paralysis), is entirely different from the picture produced by a lesion of the final common somatic path itself ("flaccid" paralysis) (see pp. 494 and 457). The integrations represented by the final common splanchnic path are less known. They are in part the result of thalamo-cortical (emotional) and reflex activities.

Viewing the central nervous system as a whole, it is evident that on the afferent side there is a differentiation or diffusion of stimuli which reaches its ultimate radiation in the suprasegmental centers. On the efferent side, beginning with the suprasegmental centers, there is a progressive integration or fusion until the ultimate concentration into the final common path is reached.

Suprasegmental Structures

These are the pallium or cerebral hemispheres, the inferior and superior colliculi or corpora quadrigemina and the cerebellum.

They consist essentially of the endings and beginnings of their respective afferent and efferent paths and of their own association neurones, the bodies of which lie in their respective cortices.

The development of the three great suprasegmental mechanisms of the brain was originally correlated with the development in the head of the two distance receptor organs, the nose (pallium) and eye (colliculi), and the head proprioceptor organ, the vestibulo-semicircular canal portion of the ear (cerebellum). Each of these suprasegmental centers, however, soon, or possibly from the beginning, received other stimuli, *e.g.*, the pallium received taste and tactile stimuli, especially those from the head involved in feeding; the colliculi received tactile and other stimuli from the body, thus being an exteroceptive coördinating center,; and the cerebellum received proprioceptive stimuli from the body. Later, proprioceptive, visual, and tactile-pressure stimuli were transmitted to the pallium, and the colliculi were reduced to a subsidiary reflex visual (and tactile?) center. The pallium received also the sound stimuli from the newer (cochlear) portion of the ear, developed in the land vertebrates, receiving air vibrations. From the reptilia up, especially in the mammals, there was a more or less continuous development of the pallium, culminating in man, and correlated with important changes in the effector apparatus necessary for standing, for skilled acts (the hand) and speech. The development of the pallium (neopallium) has two aspects: (*a*) The bringing together in association of many kinds of stimuli from all parts of the body. The pallial associative mechanism not only associates many stimuli previous to the performance of the act but also dissociates, *i.e.* discriminates, and thereby enables the act, by inhibition, to be more narrowly limited to the movements necessary for its performance. (*b*) The plasticity of the pallial associative mechanism whereby it is changed in some way by its activities. Whether this plasticity is due simply to a summation of the modifiability possessed by all neurones, or whether it is preëminently an attribute of the cortical elements due to their prolonged post-natal development, or to some specially evolved qualities is not known. Whatever its basis, the acquired changes of the pallium, due to its plasticity and consequent capacity of "learning," alter the action of subsequent stimuli reaching the pallial cortex and furnish the basis of conscious and unconscious memory, of personal experience and of individually acquired neural mechanisms, as opposed to germinal, inherited, and slowly evolved racial neural mechanisms. In the acquisition of skilled voluntary acts (speech, writing, etc.) proprioceptive stimuli from the muscles involved and their "memories" play an especially important rôle. The neurological basis for the distinction between voluntary acts (with "effort" as distinguished from involuntary cortical reactions such as blushing, etc.) lies apparently in the presence of proprioceptors in the "voluntary" muscles and in the fact that stimuli from them reach the cerebral cortex. The pallial neural mechanisms increase efficiency by giving the act greater precision and thus avoiding waste of energy, by utilizing past individual experience and thereby increasing the efficiency and adaptability of the neural reaction to present and future situations. Finally, by transmitting, by means of complex symbols, this acquired experience to the plastic pallia of other individuals, it may be of

subsequent generations, they constitute an abbreviated *neopallial* evolution as compared with the slow process of *germinal* evolution. It has been estimated that the pallial cortex contains 9,280,000,000 neurone bodies, by far the greater number being the associative neurones required for the above activities.

The great addition to the pallium (neopallium) in mammals has either necessitated, so to speak, great additions to various other structures, tracts and nuclei, in most immediate connection with the neopallium or even determined the appearance of new parts of the brain (and cord). These have already been mentioned in connection with the ontogeny of the nervous system (p. 425). These newer parts, together with the neopallium itself, have been comprised in the term *neëncephalon* in contrast with the older parts of the brain, the *palæëncephalon* (Edinger). The neëncephalic parts of the brain and cord are the neopallium, *i.e.*, the greater part of the cerebral hemispheres (excepting the olfactory basal and hippocampal archipallial portions), the nucleus caudatus and putamen of the corpus striatum (neo-striatum); a portion of the dorsal columns of the cord, of the nuclei of the columns, of the medial lemniscus and a great part of the thalamus (neo-thalamus) and thalamic radiations to the neopallium; the corona radiata, pes, pyramids, pons, middle cerebellar peduncle, and the larger part of the hemispheres of the cerebellum (neo-cerebellum); a considerable portion of the nucleus dentatus, superior cerebellar peduncles and nucleus ruber (neo-ruber); the greater part of the principal inferior olivary nucleus (neo-olive) and restiform body.

The cerebellum may be regarded probably as the great unconscious proprioceptive coördinating mechanism (Sherrington). Receiving proprioceptive stimuli from voluntary striated muscles and ear it synthesizes them and by acting on the muscles secures their proper coäction (synergy) in the performance of various movements and is probably also one of the centers regulating their tone and, consequently, posture. It also receives stimuli from the pallium and by means of these two (proprioceptive and pallial) connections is secured the proper performance of movements of voluntary muscles. This is seen in the lack of coördination in the muscles performing a movement or act when the cerebellum or some of its connections are damaged, giving rise to the picture of cerebellar ataxia and possibly other abnormalities of movement. It is seen also in the diminished tone (hypotonia) and slight diminution of strength (asthenia) often observed. These phenomena are not attended by any loss of sensation—even of proprioceptive sensation (position and movement)—the pathways for such to the pallium not passing through the cerebellum. It is possible however that the sensations of vertigo in certain vestibular and cerebellar disturbances do pass from cerebellum to pallium by a cerebello-pallial path.

RÉSUMÉ

In accordance with the above there are usually to be distinguished in transverse sections of the brain at various levels the following:

A. *Peripheral* (*segmental*) *neurones.* (1) *Efferent* (motor and sympathetic nuclei and their root fibres).

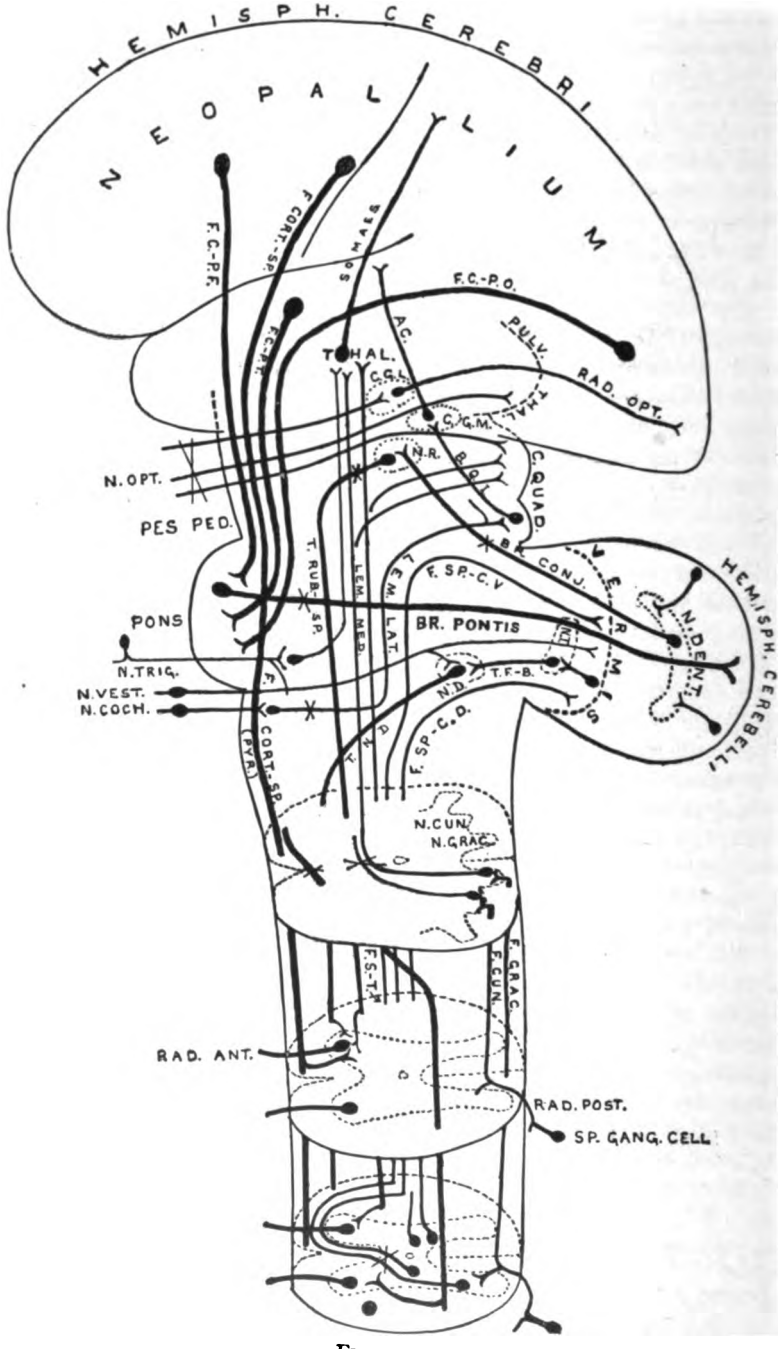
HEMISPH. CEREBRI
NEOPALLIUM
F.C.-P.F.
F. CORT.-SP.
STRIAE
F.C.-P.O.
AC.
PULV.
RAD. OPT.
T. HAL.
C.G.M.
N.R.
C. QUAD.
N. OPT.
PES PED.
T. RUB.-SP.
LEM. MED.
LEM. LAT.
F. SP.-C.V
BR. CONJ.
BR. PONTIS
PONS
N. TRIG.
N. VEST.
N. COCH.
F. CORT.-SP. (PYR.)
T.T.-P.
F. SP.-C.D.
N.D.
T.F.-B.
N. DENT.
HEMISPH. CEREBELL.
N. CUN.
N. GRAC.
F.S.-T.
F. CUN.
F. GRAC.
RAD. ANT.
RAD. POST.
SP. GANG. CELL

FIG. 342.

(2) Central continuations of *afferent neurones* (afferent roots). (*a*) Those entering at and therefore belonging to the segment involved, (*b*) Those entering above or below the segment and represented in the segment by descending or ascending (overlapping) tracts formed by the descending or ascending arms of the afferent root fibres.

B. *Terminal nuclei* of (2) and the *secondary tracts* originating from them. These may fall under category C or D (below).

C. *Intrasegmental and Intersegmental nuclei* and *tracts* of the segmental brain, consisting principally of the gray reticular formation and long descending tracts (arrangement much modified in forebrain). These represent the reflex apparatus of the segmental brain. They may also, as already pointed out, form portions of D.

D. Nuclei and tracts forming parts of *afferent* and *efferent suprasegmental paths.* The afferent paths include some of the nuclei and tracts under B, and their continuations, and the efferent include some of the longer systems under C, together with efferent suprasegmental tracts to them.

E. *Suprasegmental structures* (not present in many transections).

The general histology of the brain is similar to that of the cord. Cells of the motor cranial nuclei have an arrangement of chromophilic substance similar to their analogs in the cord, while cells of afferent cranial ganglia present a chromophilic picture similar to their cord analogs. Certain cells whose axones act directly upon motor cells

---

FIG. 342.—Principal afferent and efferent suprasegmental pathways (excepting the rhinopallial connections, the efferent connections of the midbrain roof and the olivocerebellar connections). Efferent peripheral neurones of cranial nerves are omitted. Each neurone group (nucleus and fasciculus) is indicated by one or several individual neurones. Decussations of tracts are indicated by an X. *ac*, Acoustic radiation, from medial geniculate body to temporal lobe; *br. conj*, brachium conjunctivum (superior cerebellar peduncle); *br. pontis*, brachium pontis, from pons to cerebellum; *b.q.i*, brachium quadrigemi inferius; *c.g.l*, lateral or external geniculate body; *c.g.m.* medial or internal geniculate body; *c.quad*, corpora quadrigemina; *f. cort.-sp*, pallio-spinal fasciculus (pyramidal tract); *f.c.-p.f*, frontal pallio-pontile fasciculus (from frontal lobe); *f.c.-p.l*, temporal pallio-pontile fasciculus (from temporal lobe); *f.c.-p.o*, occipital pallio-pontile fasciculus (from occipital lobe); *f.cun*, fasciculus cuneatus (column of Burdach); *t.f.-b*, fastigio-bulbar tract; *f. grac*, fasciculus gracilis (column of Goll); *f.s.-t*, spino-thalamic fasciculus; *f.sp.-c.d*, dorsal spino-cerebellar fasciculus(tract of Flechsig); *f.sp.-c.v*, ventral spino-cerebellar fasciculus; *lem. lat*, lateral lemniscus or lateral fillet; *lem, med*, medial lemniscus or fillet; *n. coch*, cochlear nerve; *n. cun*, (terminal) nucleus of the column of Burdach; *n.d*, nucleus of Deiters; *n. dent*, nucleus dentatus; *n. grac*, nucleus of the column of Goll; *n. opt*, optic nerve; *n.r*, nucleus ruber; *n.t.* nucleus tecti (or fastigii); *n. trig*, trigeminal nerve; *n. vest*, vestibular nerve; *pes. ped*, pes pedunculi (crusta); *pulv thal*, pulvinar thalami; *pyr*, pyramid; *rad. ant*, ventral spinal root; *rad. post*, dorsal spinal root; *rad. opt*, optic radiation (from lateral geniculate body to calcarin region); *somæs.* bundles from thalamus to postcentral region of neopallium; *sp. gang*, spinal ganglion; *t.f.-b.*, tractus fastigio-bulbaris; *thal*, thalamus; *t.n.d*, tract from the nucleus of Deiters; *t.rub.-sp*, rubro-spinal tract (vonMonakow). (Lateral view of brain.)

(*pre-motor* cells) in cord and brain (certain cells in motor central cortex, corpus striatum, hypothalamus, reticular formation, nucleus ruber, nucleus of Deiters and dentate and fastigial nuclei of cerebellum) resemble motor cells, in arrangement of chromophilic substance, while certain cells in close connection with afferent peripheral neurones resemble the latter (Jacobsohn and Malone). The neuroglia cells and fibres also present the same general characteristics as those in the cord, with variations peculiar to certain localities (*e.g.*, parts of the cerebellum).

Hindbrain or Rhombencephalon

This includes the medulla, cerebellum and part of the tegmentum and pons. Its peripheral nerves are the V, VI, VII, VIII, IX, X, and XII.[1]

The MEDULLA OBLONGATA OR BULB is the continuation upward of the spinal cord and extends from the lower limit of the pyramidal decussation below to the lower margin of the pons above.[2]

Externally, the medulla shows the continuation upward of the anterior fissure and posterior septum of the cord. On either side of the anterior fissure is a prominence caused by the *anterior pyramid*, and to the outer side of the pyramid the bulging of the *olivary body*, due to the presence of the inferior olivary nucleus, may be seen. The antero-lateral surface of the medulla is also marked by the exit of the fifth to the twelfth (inclusive) cranial nerves. Nerves VI and XII (somatic motor) emerge near the mid-ventral line, the others, including the splanchnomotor portions of V, VII, IX and X, emerge more laterally. The posterior surface shows two prominences on either side. The more median of these, known as the *clava*, is caused by the underlying nucleus gracilis, or nucleus of the column of Goll; the other, the *cuneus*, lying just to the outer side of the clava, is due to the nucleus cuneatus or nucleus of the column of Burdach. Lateral to this is a third eminence, the *tuberculum cinereum* (tubeiculum Rolandoi or tuberculum trigemini), due in part to the descending root of the V and its underlying terminal nucleus, the continuation of the dorsal gray column of the cord. This eminence merges cephalad with the eminence of the *restiform*

[1] It is better probably to reckon the so-called medullary or bulbar part of nerve XI with nerve X.

[2] It would be better to include in the term medulla oblongata what here falls under pontile tegmentum of the hindbrain.

body. The central canal of the cord continues into the medulla, where it gradually approaches the dorsal surface and opens into the cavity of the fourth ventricle. The floor of the fourth ventricle exhibits on each side a *medial eminence* occupied caudally by the nucleus hypoglossi (*trigonum hypoglossi*). Lateral to this is a triangular area, the *ala cinerea* (*trigonum vagi*), surrounded by furrows. This is partly occupied by nuclei of the vagus. The medial eminence is bounded laterally by the *sulcus limitans.*

Lateral to the sulcus limitans, a broader triangular area, with an angle directed into the lateral recess, is the area occupied by the

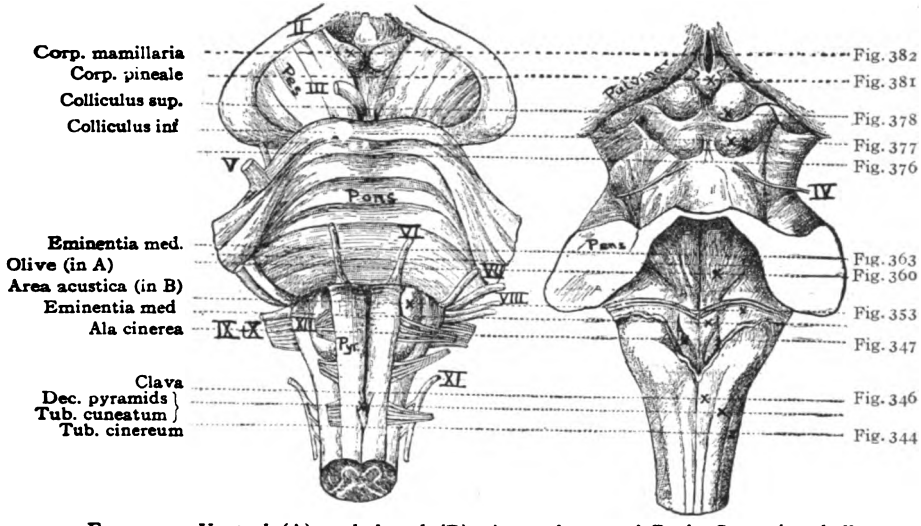

FIG. 343.—Ventral (A) and dorsal (B) views of part of Brain Stem (cerebellum removed). Structures named at the left are indicated by their reference lines running to an X. On the right are named the figures showing transverse sections through the brain at the levels indicated by the reference lines. The level for Figs. 360 and 382 are not accurately indicated. (Rauber-Kopsch, Modified).

nuclei of the acoustic nerve (*area acustica*), especially of its vestibular portion. Still further cephalad near the median line are eminences indicating the positions of the nucleus abducentis and genu facialis (*eminentia abducentis*). The roof of the fourth ventricle is formed by the thin *tela* and *plexus chorioideus*, the *inferior medullary velum*, the *cerebellum* and the *superior medullary velum.* (Fig. 343).

The PONS is a mass of fibres and gray matter extending across the ventral surface of portions of mid- and hindbrain. The term is often used to include the whole of the basal part of the brain thus covered by the pons. It is better, however, to restrict it to the pons itself.

The part of the hindbrain dorsal to the pons, which is the continuation forward of the medulla, may be included in the term *tegmentum* of the hindbrain.

The CEREBELLUM is described on p. 513.

The bulb and pontile tegmentum contain the lower or segmental centers for (*a*) speech (articulation and phonation), an acquired, voluntary, neopallial act; (*b*) for eating (tasting, chewing and swallowing), an acquired, voluntary act but probably involving more segmental reflex mechanisms than the preceding and terminating in a purely involuntary activity; (*c*) for sucking, a voluntary act but with a segmental mechanism capable of independent activity early and possibly throughout life; (*d*) for breathing, an activity under partial pallial voluntary control and influenced by thalamo-pallial emotional activities but with an independent segmental mechanism; (*e*) for the regulation of cardiac and other visceral motor (peristaltic, vasomotor) and secretory activities, involuntary but influenced by thalamo-pallial emotional activities; (*f*) for various reflexes (some of which are under partial voluntary control) such as vomiting, retching, gulping (pharyngeal), palatal, coughing, salivary, stapedial, tensor tympani, jaw, corneal, winking, blinking, lacrimal, turning of eyes to sound, closure of eyes and other movements to loud noise, and also the vestibular reflex control of eye and body musculature. It also contains a portion of the reflex and voluntary eye-moving mechanism (lateral eye movements). The bulb and pontile tegmentum also contains the continuations of the various spinal paths to and from cerebellum, midbrain and forebrain including various masses of gray (nuclei) at their relays as well as the afferent bulbar and tegmental paths to and from cerebellum, midbrain and forebrain. These latter are obviously also partly identical with portions of the segmental mechanisms enumerated first.

The pons is a relay in the crossed pallio-ponto-cerebellar path, added ventrally to the older pontile tegmentum and probably bringing the cerebellum under pallial control.

For the general nature of cerebellar activities, see pp. 499 and 521.

TECHNIC

The technic of the medulla (and the rest of the segmental brain) is the same as that of the cord (page 477). Transverse sections should be cut through the following typical levels, stained by Weigert's method (page 33), and mounted in balsam:

1. Through the pyramidal decussation.
2. Through the sensory decussation.
3. Through the lower part of the olivary nucleus.
4. Through the middle of the olivary nucleus.
5. Through the entrance of the cochlear nerve.
6. Through the entrance of the vestibular nerve.
7. Through the roots of the sixth and seventh cranial nerves.
8. Through the roots of the fifth cranial nerve.

The methods of Nissl, Cajal and glia stains should also be used when practicable.

PRACTICAL STUDY

1. Transverse Section of the Medulla through the Decussation of the Pyramidal Tracts (Motor Decussation) (Figs. 343, 344 and 345)

(For the various paths involved see pp. 507–519)

The most conspicuous features of this section are the decussation of the pyramids, the larger size of the dorsal horn and the beginning of the gray reticular formation. Surrounding the central canal is the *central gray.*

The *Spinal Accessory* or cranial nerve XI, some of the roots of which are present at this level, is often divided into bulbar and spinal portions, the former innervating the sterno-mastoid and portions of the trapezius muscles. The bulbar portion is probably to be regarded as simply the caudal part of the vagus. The spinal portion originates from cells in the lateral or central part of the ventral horn. The root fibres emerge on the lateral aspect of the cord, thus forming a third series of roots extending as low as the fifth or sixth cervical segment. Some of the root fibres pass from their cell-bodies dorsally and then laterally to reach the surface. Others pass upward in the cord just dorsal to the ventral horn for some distance before turning outward to emerge from the cord. The cervical roots unite to form a trunk (external branch) which makes its cranial exit with the vagus but does not join it. (Fig. 345).

Efferent Peripheral Neurones.—Nuclei of first cervical spinal nerve in ventral gray, and root fibres passing out to emerge on ventral aspect. *Nuclei of XI*, in mesial position in central gray, or in ventral gray. Axones pass out laterally from latter and emerge on the lateral surface. The mesial or deep nuclei are best reckoned with nerve X.

Afferent Roots, their Terminal Nuclei and Secondary Tracts.—Some afferent fibres of the first cervical spinal nerve are still entering at this level.

Ascending afferent roots: The dorsal funiculus comprising the fasciculus cuneatus and fasciculus gracilis remain as in the cord. Collaterals and terminals from them can be seen entering the subjacent gray. (Fig. 345).

Descending afferent roots: Some of the fine fibres between the enlarged dorsal horn and the periphery, occupying the position of the zone of Lissauer in the cord, are descending afferent root fibres of cranial nerve V or *tractus spinalis trigemini* (*spinal V*). Collaterals and terminals from these fibres terminate in the gelatinous substance of Rolando and also traverse it to form a plexus of medullated fibres in its inner side very similar to the cord. The axones of these dorsal horn cells (or *terminal nucleus of the spinal V*) form the secondary tracts of the V, which cannot be distinguished (p. 562 and Fig. 367), giving off collaterals to the nucleus XII (tactile-lingual reflex). The secondary tracts (contact, pain and temperature from face and mouth) probably are crossed, lying near the lateral spino-thalamic tracts. (Figs. 349, 352, 358, 365 and 366).

Secondary tracts, forming parts of afferent suprasegmental paths: These form a mass of fibres along the ventro-lateral periphery of the medulla which

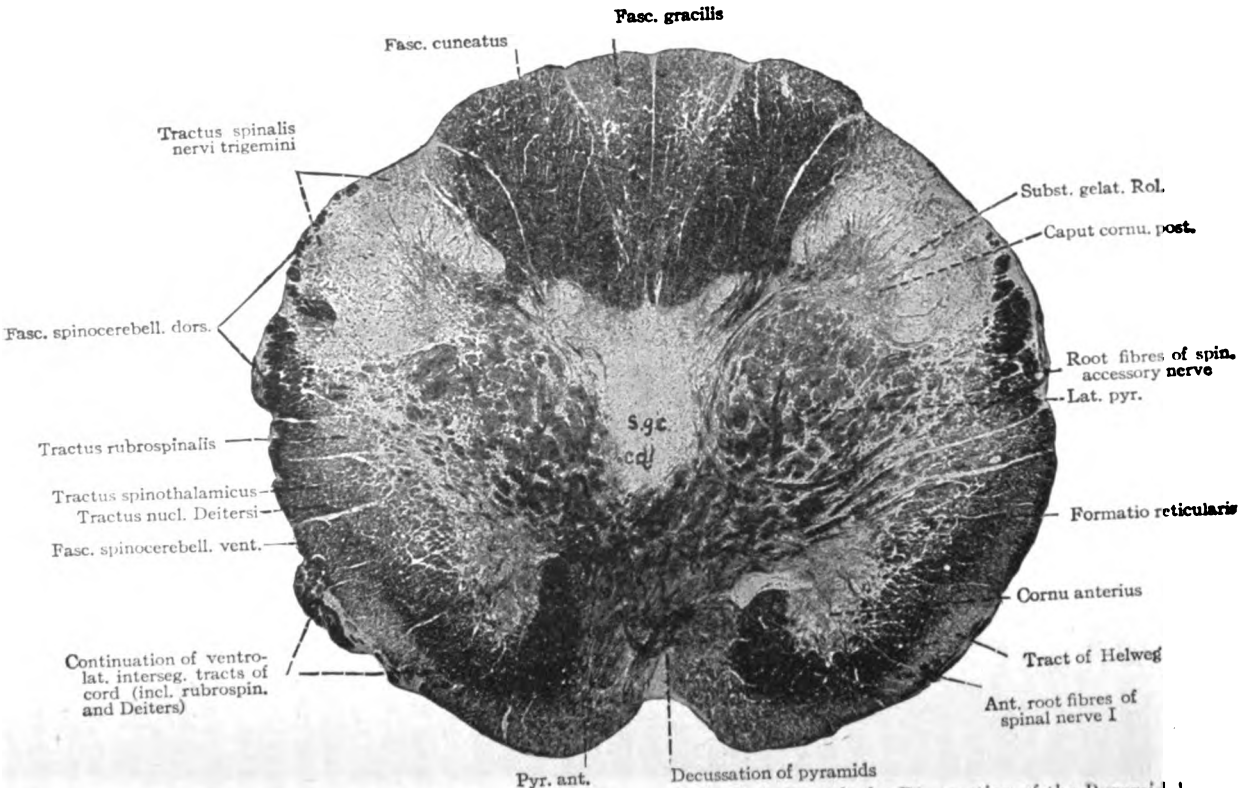

FIG. 344.—Transverse Section of the Medulla of a Five Weeks' Infant through the Decussation of the Pyramidal Tracts. Photograph. Weigert preparation. *c.c.*, central canal; *s.g.c.*, central gelatinous substance. (×14.)

consists of (*a*) the dorsal spino-cerebellar (*b*) the ventral spino-cerebellar and (*c*) the lateral spino-thalamic tracts; also others more mesial ("mesial spino-thalamic" tract, see p. 489 and path 1).

Intersegmental Neurones.—The neurone bodies are, as in the cord, scattered throughout the gray. The continuation of the ventro-lateral intersegmental tracts of the cord (and the colliculo-spinal tract) is the U-shaped mass of fibres around the ventral gray. This mass consists of the long descending, the shorter

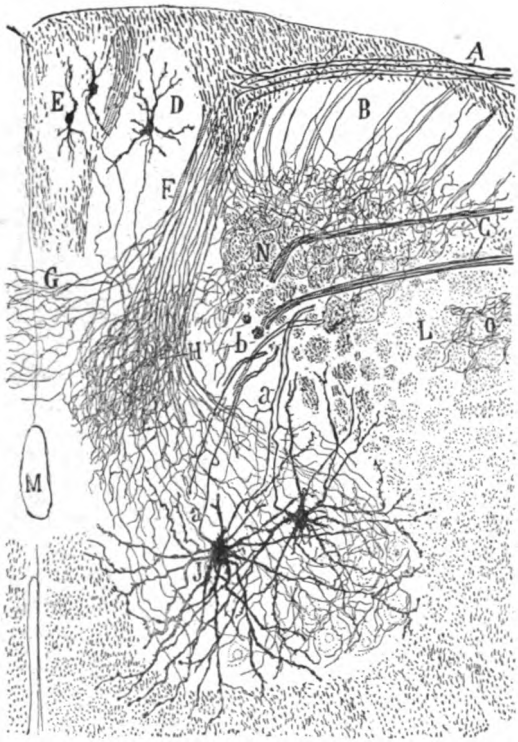

Fig. 345.—Portion of a Transverse Section of the Medulla of a fœtal cat below the Decussation of the Pyramids. (The topography is not quite the same as in the human medulla). Chrome-silver impregnation of Golgi. (Cajal). *A*, dorsal root fibres; *B*, gelatinous substance of Rolando (traversed by collaterals from dorsal root and dorsal column); *C*, root fibres of the spinal accessory nerve near their emergence; at *b* is seen the longitudinal part of their course and at *a* their origin as axones of the cells of the spinal accessory nucleus (*J*). Collaterals are shown given off from these axones. *D*, a cell of the nucleus of the column of Burdach; *E*, a cell of the nucleus of the column of Goll. Their axones (medial lemniscus fibres) are shown. *F*, collaterals ("reflex collaterals") from the fibres of the dorsal column to the intermediate gray (*H*) and the nucleus of the spinal accessory. *G*, collaterals from the fibres of the dorsal column crossing in the dorsal commissure; *L* and *N* are in the region of the processus reticularis and displaced longitudinal fibres of the lateral column; *M*, central canal.

ascending and descending intersegmental tracts, and the colliculo-spinal; *i.e.*, (*a*) rubro-spinal (in lateral arm of U), (*b*) vestibulo-spinal (lateral and mesial), (*c*) tract from interstitial nucleus of medial longitudinal fasciculus (mesial), (*d*) colliculo-spinal (mesial), (*e*) shorter descending and ascending tracts which may

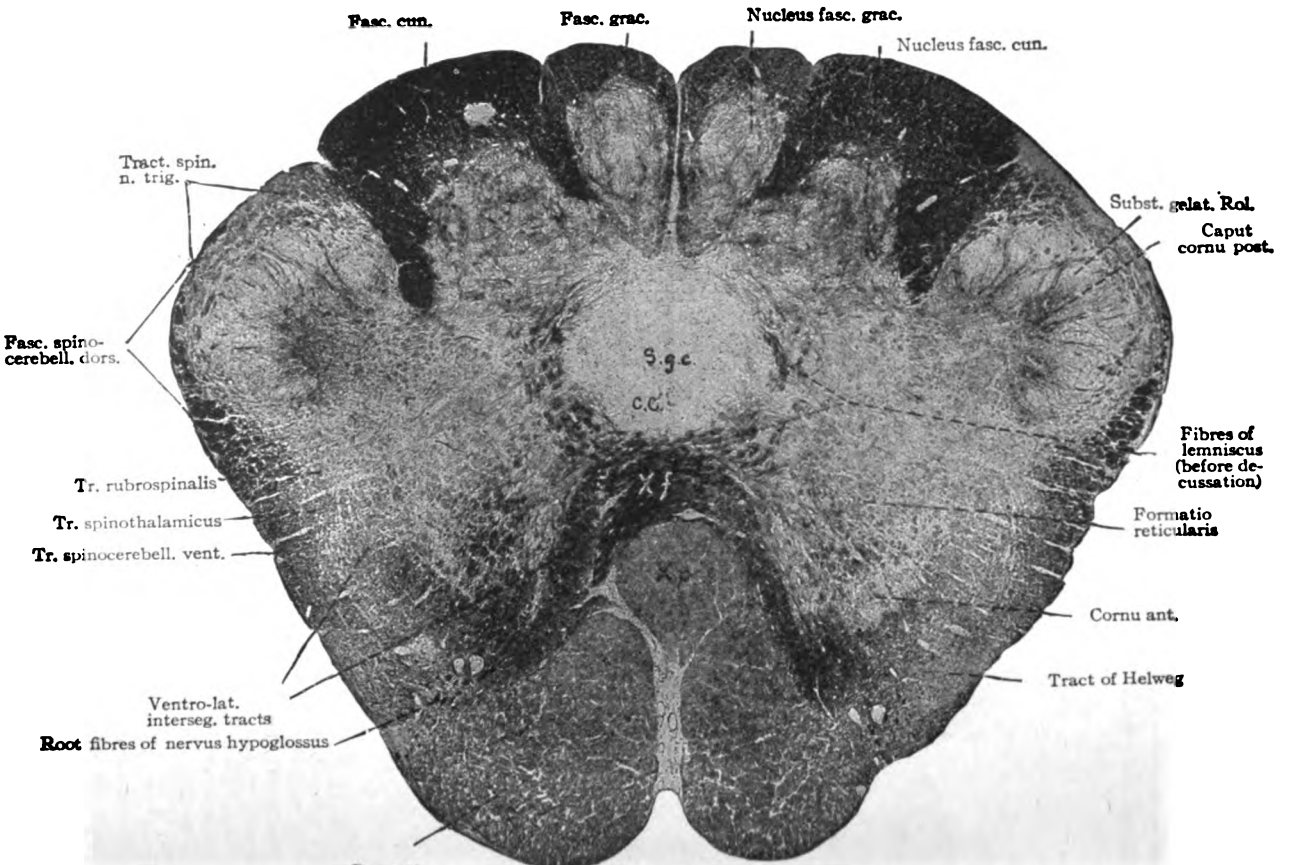

FIG. 346.—Transverse Section of the Medulla of a Five Weeks' Infant through the Decussation of the Fillet. Photograph. Wiegert preparation. *Xf*, decussation of fillet; *Xp*, decussation of pyramida; *c.c*, central canal; *s.g.c*, central gray. (X14).

be regarded as the equivalent of the ground bundles of the cord comprising shorter reticulo-spinal and spino-reticular fibres. The shortest of these fibers, which in the cord were next the lateral gray, are now mingled with the gray, the combination constituting the *gray reticular formation.* Other short intra- and intersegmental tracts lie in and adjoining the dorsal horn, as in the cord.

Descending suprasegmental paths include certain of the above long descending intersegmental tracts as previously explained. Besides these there are the *efferent suprasegmental neurones* known as the pallio-spinal or pyramidal tracts and the colliculo-spinal tracts. Bundles of fibres are seen crossing (*pyramidal decussation*) from the anterior pyramid of one side to the opposite dorso-lateral column, where they turn downward as the crossed pyramidal tract. In their passage through the gray matter, they cut off the ventral horn from the rest of the gray matter. These fibres, as already noted in the cord, are descending axones from motor cells situated in the precentral cerebral cortex. In the pyramidal decussation most of these fibres cross to the opposite dorso-lateral region to pass down the cord as the crossed pyramidal tract (p. 492, and Fig. 333; Fig. 341, F.) The remaining fibres stay in their original ventral position and continue down the cord as the direct pyramidal tract (p. 493, and Fig. 333; Fig. 341, F). A few pass to the ventral tract on the same side, thus becoming uncrossed fibres in the lateral tract. The bundles of fibres do not cross in a transverse plane, but take a downward direction at the same time. For this reason transverse sections show these fibres cut rather obliquely. Because of the fact that the fibres cross in alternate bundles, the number of decussating fibres seen in any one section is greater on one side than on the other, at higher levels of the decussation the fibres are more interwoven. (Fig. 343).

2. Transverse Section of the Medulla through the Decussation of the Fillet or Lemniscus (Sensory Decussation) (Figs. 343 and 346)

(For the Various Paths Involved see pp. 507–519)

The most conspicuous features are the appearance of the nuclei cuneatus and gracilis, the decussation and formation of the medial lemniscus or fillet, and the increase of the gray reticular formation. The nerves of this level are XII and X (best studied in detail in the next level).

Peripheral Efferent Neurones.—In the lateral part of the central gray is the *dorsal motor nucleus of the X* (*nucleus alæ cinereæ*) (see next section). In the ventral part of the central gray is the *nucleus hypoglossi* (see next section) and, passing ventrally and emerging lateral to the pyramids, may be seen the axones of its cells—the *root fibres of the XII.*

Afferent Roots, their Terminal Nuclei and Secondary Tracts.—Entering afferent root fibres are usually not present.

The funiculi or fasciculi cuneatus and gracilis have diminished, and internal to them have appeared large masses of gray. These are the nuclei of the columns, and are known, respectively, as *the nucleus of the column of Goll* or *the nucleus gracilis*, and *the nucleus of the column of Burdach* or *the nucleus cuneatus.* In the higher sensory decussation levels there is usually a lateral cuneate uncleus.

These nuclei serve as nuclei of termination for the fibres of the dorsal fun-

iculi. Their termination in these nuclei is the ending of that system of fibres which has been traced upward from their origin in the cells of the spinal ganglia; the completion of the course of the spinal peripheral afferent neurones with long ascending arms. As the fibres of the dorsal columns are constantly terminating in these nuclei, there is, in passing from below upward, a constant increase in the size of the nuclei and a corresponding decrease in the size of the columns, until, just below the olive, the whole of the column of Goll and most of the column of Burdach are replaced by their respective nuclei (pp. 485, 507).

Study the plexus of fine fibres in these nuclei, formed by the terminals of the column fibres, also the coarser fibres (axones of the cells of the nuclei) gathered in the ventral part of the nuclei, whence they emerge and curve[1] around the central gray, cross to the opposite side ventral to it and dorsal to the pyramids, and then turn upward forming the bundle of fibres known as the *medial lemniscus* or *medial fillet*.

What is apparently the lateral part of the nucleus cuneatus has a different, lighter appearance in Weigert preparations. This is composed of larger cells (*nucleus magnocellularis funiculi dorsalis*, or lateral nucleus of the column of Burdach, better seen in somewhat higher levels). It probably does not send fibres to the medial fillet and was formerly thought to send them to the restiform body but this now seems improbable. Its connections are thus not known.

The spinal V has increased and also its terminal nucleus, the dorsal horn. Besides sending fibres to the opposite lateral spino-thalamic tract it probably also sends fibres conveying proprioceptive and tactile discriminative impulses to the opposite medial fillet. The spino-cerebellar and lateral spino-thalamic tracts occupy about the same positions. (Figs. 349 and 358).

In the central gray dorsal to the central canal is a nucleus representing a union of the caudal ends of the terminal nuclei of the fasciculi solitarii (see next section)—the *nucleus commissuralis*. Fibres of the fasciculi solitarii also decussate here (see next section) and terminate in this nucleus. (Fig. 350).

Intersegmental Neurones.—The rubro-spinal and vestibulo-spinal tracts and the tract from the interstitial nucleus of the medial longitudinal fasciculus occupy about the same positions. The reticular formation has increased, the whole of the ventral horn and intermediate gray containing bundles of longitudinal fibres. The formation is also traversed by transverse fibres, representing the beginnings or terminations of various longitudinal fibres. In the region occupied by the continuations of the lateral columns have appeared the *nuclei funiculi lateralis*, sometimes called the lateral nuclei of the reticular formation, forming partial relays in the spino-cerebellar path and possibly other ascending paths of this region. For the nuclei reticularis see next section.

Efferent Suprasegmental Neurones.—The decussation of the pyramids has now nearly or entirely ceased. The lateral pyramidal tracts are no longer in the lateral columns but are parts of the anterior pyramidal tracts which form two large masses of fibres one on each side of the ventral sulcus. The colliculo-spinal tract occupies the same position.

[1] Fibres having a transverse curved or arched course are in general termed *arcuate fibres*. If they are deeply located, they are *internal arcuate fibres*, if near the periphery, they are *superficial* or *external arcuate fibres*. Obviously the same fibre may be, in different parts of its course, internal arcuate, external arcuate, and longitudinal.

3. Transverse Section of the Medulla through the Lower Part of the Inferior Olivary Nucleus (Figs. 343, 347 and 348).

(For the various paths involved see pp. 507–519.)

The central canal has opened into the *fourth ventricle*, the central gray (including the central gelatinous substance) now being spread out on its floor. On the latter can be seen the *medial eminence* (here the *trigonum hypoglossi*), occupied by the nucleus XII, the *trigonum vagi* (*ala cinerea*) occupied by certain vagus nuclei (therefore a splanchnic area) and the beginning of the *area acustica* (better vestibularis) occupied by the *nucleus medialis vestibularis*. The roof of the ventricle is formed by its *chorioid plexus*. The most conspicuous new feature is the *olive*, a swelling occupied by the *nucleus olivaris inferior*. The olive may be regarded as added externally to the continuations of the ventro-lateral cord structures.

The *Hypoglossus*, *Vagus* and *Glossopharyngeus* (the latter entering somewhat higher) are the nerves of this level. The hypoglossus is efferent to the tongue musculature. The vagus and glossopharyngeus are both afferent and efferent. Their afferent fibres include (*a*) a few medullated *cutaneous* fibres (auriculo-temporal nerve of Arnold), (*b*) medullated *proprioceptive* fibres from the striated voluntary muscles of pharynx and larynx, (*c*) fine medullated and non-medullated *mucosal* fibres from the alimentary tract and (*d*) fine medullated and non-medullated *taste* fibres, principally in nerve IX. The efferent fibres are (*a*) to the *striated voluntary muscles* of pharynx and larynx, (*b*) preganglionic to *cardiac muscles*, (*c*) preganglionic to *smooth muscles* of blood vessels and walls of respiratory and alimentary tracts and (*d*) preganglionic to *glands* of stomach and pancreas (X) and parotid (IX). According to some authorities a portion at least of the efferent preganglionic fibres (*b*) and (*c*) are relayed in the ganglion nodosum (ganglion trunci vagi). It is not improbable that the proximal ganglia of nerves IX and X (jugular ganglia) are the ganglia of the afferent cutaneous and proprioceptive fibres, while the distal ganglia (petrosum and nodosum give rise to the splanchnic mucosal and gustatory fibres (Winkler).

Efferent Peripheral Neurones.—The nucleus of the XII is large and occupies the central gray of the medial eminence. In the nucleus XII can be distinguished (Weigert and Cajal stains) coarse fibres which are the root fibres from the motor cells of the nucleus and fine fibres which are terminals of other fibres ending in the nucleus. The fine fibres come from fibres encircling the nucleus. On its dorsal side are fibres from the central gray: secondary vagus and vestibular fibres (? vomiting?), fibres from nucleus intercalatus, nucleus prepositus and bundle of Schütz, representing reflex taste, vestibular and olfactory tongue reflexes. On its ventro-lateral side are collaterals from the arcuate fibres of the secondary vagal and trigeminal tracts representing tactile (and taste?) tongue reflexes and also fibres from the reticular formation possibly representing proprioceptive reflex and cerebellar control of the tongue. On its medio-ventral side are fibres from the pyramidal tract causing voluntary movements of the tongue (path 18 *b*). The root fibres of the XII pass lateral to the medial lemniscus, between the olive and pyramid, and then emerge at the groove between olive and pyramid. (Figs. 348, 349 and 350).

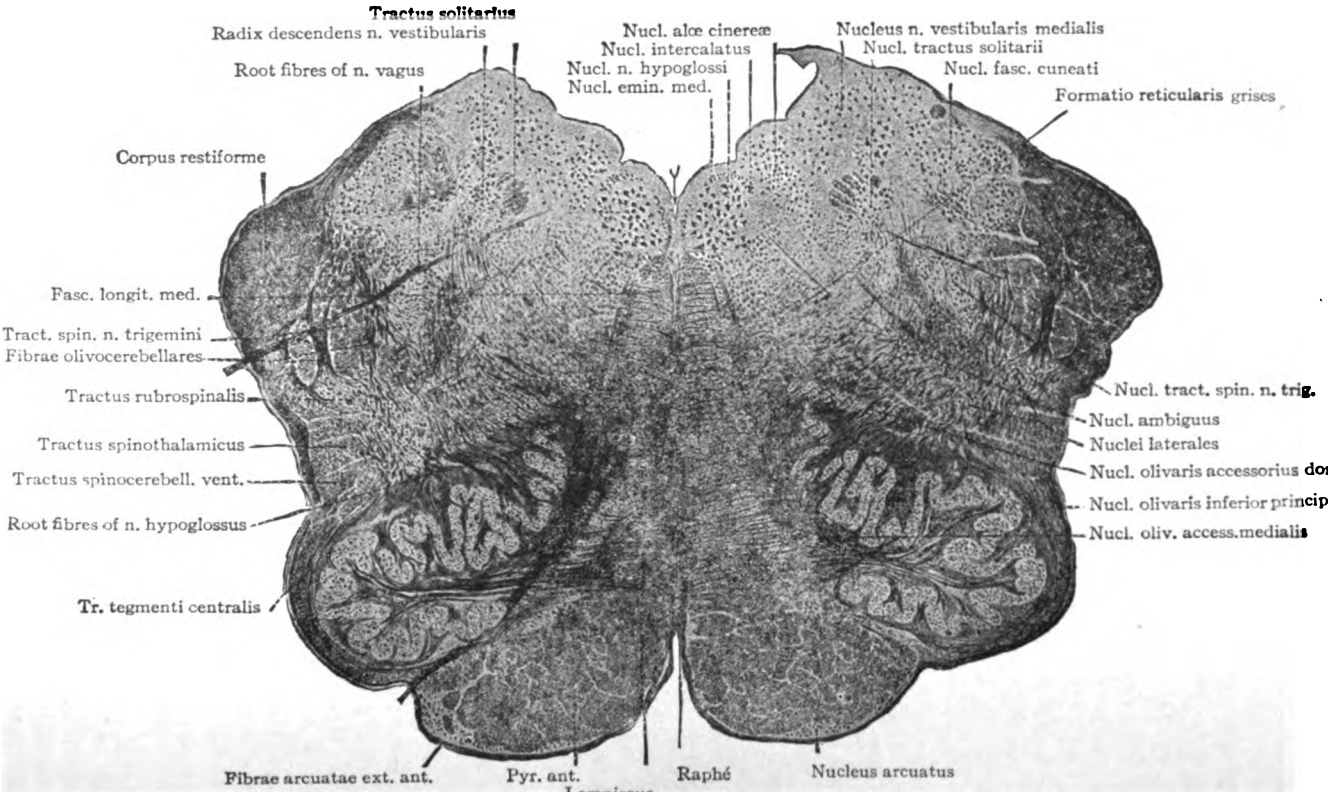

FIG. 347.—Transverse Section of the Medulla through the Lower Middle Part of the Inferior Olivary Nucleus. Weigert preparation (counterstained with carmine to show cell bodies). (Rauber-Kopsch.) The arrow indicates the median sulcus of the rhomboid fossa or fourth ventricle.

The *dorsal preganglionic sympathetic* (*dorsal motor*) *nucleus* of X occupies a part of the central gray of the trigonum vagi. Its axones are probably those vagus root fibres which innervate (*via* sympathetic ganglia) smooth and cardiac muscle. In this nucleus can be distinguished (Nissl stain) a large-celled (magnocellular) and a small-celled (parvocellular) portion (Fig. 348). Views differ as to the structures innervated by each. According to one view (Winkler), the large celled portion innervates the smooth muscle of the walls of

FIG. 348.—Portion of a Transverse Section of the Medulla at the Level of the Nucleus Hypoglossi, showing the Nuclei in the Floor of the Fourth Ventricle (Winkler). *ar. acc.*, area acclinis; *f. arc. int.*, fibræ arcuatæ internæ; *fibr. d.*, *fibr. lat.*, *fibr. med.*, fibræ circulares nuclei N. hypoglossi dorsales, laterales, mediales; *f. gr.*, fasciculus gracilis; *f. l. p.*, fasciculus longitudinalis posterior (or medialis); *n. XII*, nucleus N. hypoglossi; *n. c.*, nucleus cuneatus; *n. d. VIII*, nucleus triangularis (medialis) N. octavi; *n. d. m. X*, *n. d. p. X*, nucleus dorsalis magnocellularis, parvocellularis N. vagi; *n. grac.*, nucleus gracilis; *n. int.*, nucleus intercalatus (Staderini); *n. Ro.*, nucleus Roller; *n. rot. X*, nucleus dorsalis rotundus N. vagi; *n. sens. X*, nucleus dorsalis sensibilis N. vagi; *n. te.*, nucleus teretis; *n. v. tr. s.*, nucleus ventralis tractus solitarii; *r. XII*, radix N. hypoglossi; *tr. d.V*, tractus spinalis N. trigemini (spinal V); *tr. d. VIII*, tractus descendens N. octavi (descending root of vestibular nerve); *tr. d. t.*, tractus dorsalis tegmenti (dorsal longitudinal bundle of Schütz); *tr. sol.*, tractus solitarius; *v. IV*, ventriculus quartus. The left border of the figure is the meridian line.

the viscera, especially of the stomach (and probably, respiratory tract) and the small-celled portion blood-vessels (of the mucosa of the head) and heart. The nucleus contains very few medullated fibre showing the terminals entering it to be largely non-medullated. These are probably (*a*) secondary vagoglossopharyngeal fibres from the terminal nuclei (see below) of the mucosal fibres, (vomiting, modification of respiratory passages by stimuli from respiratory tract); (*b*) terminals from secondary vestibular fibres, probably from the medial nucleus (vomiting due to excessive vestibular stimuli); (*c*) terminals from the efferent

splanchnic pallial path (path 28) (changes in heart beat and nausea and vomiting due to emotional states, perceptions with strong feeling tone etc.). It may

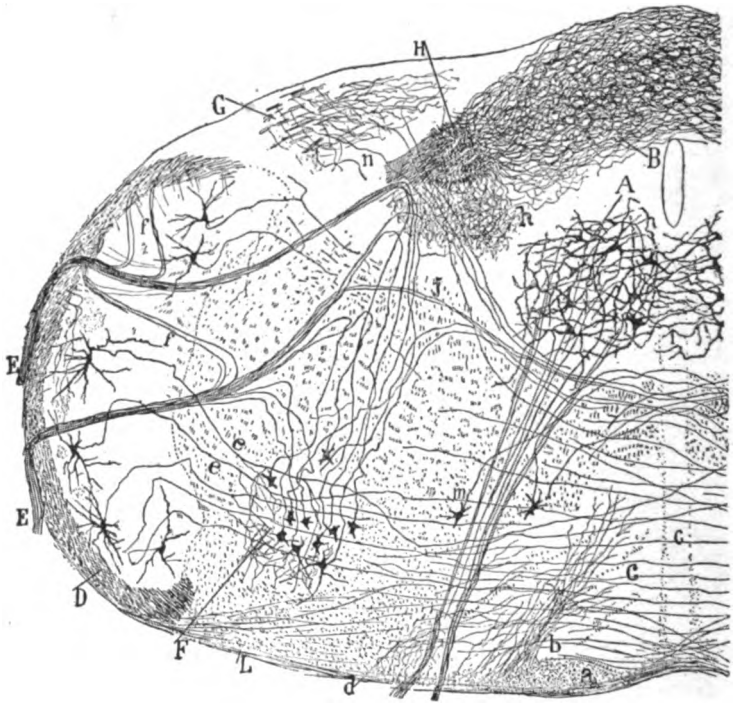

FIG. 349.—One Side of a Transverse Section of the Medulla of a Mouse Four Days Old, at the Level of the Nucleus Ambiguus and Nucleus Hypoglossi. Chrome-silver impregnation of Golgi. (Cajal.) The different appearance of the section as compared with the human medulla is principally due to the small size of the pyramids (due to small neopallium), to the small size of the inferior olivary nuclei (smaller neo-olives to smaller neocerebellum) and the large spinal V. *A*, nucleus of the hypoglossus; *a* pyramid; *B*, commissural nucleus; *b*, collaterals from the white matter near the pyramid and from the pyramid itself; *C*, inferior olivary nucleus; *c*, the median line and the fibres crossing it (raphé); *D*, descending root of the trigeminus (spinal V); *d*, collaterals from the continuation of the lateral column of the cord; *E*, efferent roots of the vago-glossopharyngeus; *e*, secondary fibres from the terminal nucleus of the spinal V passing transversely to the opposite half of the medulla and giving off collaterals, near *e*, to the nucleus ambiguus; *F*, nucleus ambiguus, from which efferent (motor) vagus root fibres are shown passing dorsally and then turning laterally and emerging at *E*, some of them are shown passing to the other side; collaterals from the adjacent continuation of the lateral column are also shown terminating in the nucleus; *f*, fibres from the vago-glossopharyngeus roots passing to the spinal V; *G*, caudal extremity of the descending vestibular root, its nucleus and the medial vestibular nucleus; *H*, solitary fasciculus; *h*, collaterals from the solitary fasciculus to one of its terminal nuclei; *j*, vagus root fibres from the other side of the medulla, probably from the opposite nucleus ambiguus; *L*, external arcuate fibres; *m*, cell of nucleus reticularis in gray reticular formation, its axone is shown crossing to the opposite medial longitudinal fasciculus; *n*, decussating probably secondary, vestibular fibres.

also perform the involuntary completion of the act of swallowing, initiated voluntarily.

The *nucleus salivarius inferior*, of nerve IX, is located in the reticular formation medial to the nucleus ambiguus (see below). It is of scattered cells not easily distinguished. Its preganglionic axones pass to the ganglion oticum whence they are relayed to the parotid gland. The *glandular nucleus* of the vagus has not been well located but is probably in a similar position further caudad. These secretory nuclei and the nucleus salivarius superior of nerve VII probably receive olfactory (path 27) and gustatory impulses *via* the tracts from the glossopharyngeal nucleus gustatorius (see below), nuclei prepositus and intercalatus and dorsal longitudinal bundle of Schütz (tractus dorsalis tegmenti). To this may be added probably fibres from the medial vestibular nucleus (tractus reuniens of Fuse). These nuclei must also receive fibres from

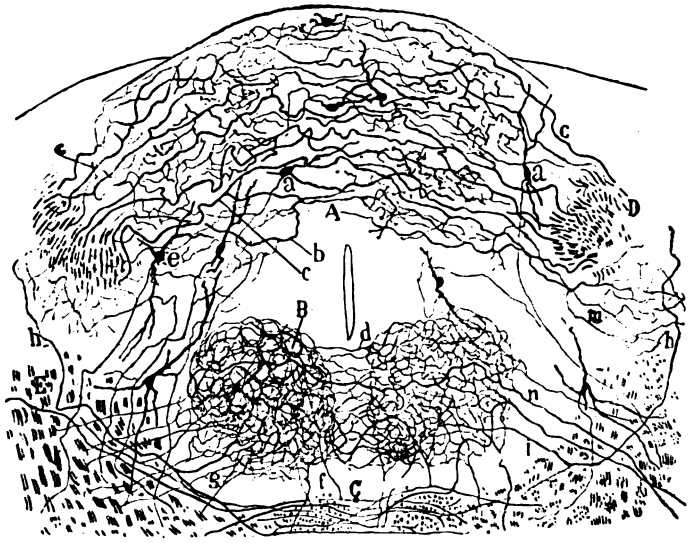

FIG. 350.—Portion of a Transverse Section of the Medulla of a Mouse at the level of the Commissural Nucleus. Chrome-silver impregnation of Golgi. (Cajal.) *A*, commissural nucleus; *a*, cells of the commissural nucleus; *c*, fibres of the solitary fasciculus terminating in the commissural nucleus; *b*, fibre of the solitary fasciculus crossing; *B*, nucleus of the hypoglossus; *f*, *g* and *i*, collaterals from the secondary trigeminal and vago-glossopharyngeal tracts terminating in the nucleus of the hypoglossus (comp. Fig. 349); *n*, collaterals from the gray reticular formation terminating in the nucleus of the hypoglossus; *d*, commissure of collaterals crossing between the nuclei of the hypoglossi; *C*, decussating fibres of the medial lemniscus; *h*, transverse secondary vago-glossopharyngeal fibres; *E*, secondary trigeminal and vago-glossopharyngeal tracts.

the efferent pallial splanchnic path (path 28) representing food perceptions and memories, acting in coöperation with splanchnic sensations (hunger, etc.) as well as more generalized emotional states, all of which may modify secretion. This path probably lies deep in the reticular formation near the vagus apparatus.

The bodies of another group of peripheral efferent neurones form the *nucleus ambiguus* (*ventral motor*) of nerves IX and X in the reticular formation. Their axones pass obliquely dorsally and mesially, join the other root fibres of the X, and then bending abruptly, pass with them to the lateral surface of the medulla. Some pass across the median line and leave by the root of the opposite side.

They probably innervate the striated muscles of the pharynx, larynx (and œsophagus ?). The nucleus receives various terminals, some at least appearing to come from the secondary trigeminal tracts and from the lateral columns and reticular formation (Fig. 336.) The nucleus should receive fibres of reflex proprioceptive control (tonus, etc.) by stimuli from the muscles themselves, cerebellar impulses, secondary or tertiary vago-glossopharyngeal and trigeminal fibres, conveying stimuli from the pharyngeal and respiratory mucosa (*e.g.*, palatal and pharyngeal reflexes, coughing, vomiting), also terminals from the voluntary motor pallial path (the part of path 18 involved in phonation).

Afferent Peripheral Roots, their Terminal Nuclei and Secondary Tracts.—The afferent roots of the IX and X enter along with efferent root fibres and either

FIG. 351.—Portion of a Transverse Section of the Medulla of a New-born Cat showing the various Vagus Nuclei in the Floor of the Fourth Ventricle. Chrome-silver impregnation of Golgi. (Cajal.) *A*, internal or descending nucleus of the solitary fasciculus (dorsal sensory vagus nucleus); *a*, axis-cylinders or axones; *B*, external or interstitial (ventral?) nucleus of the solitary fasciculus; *b*, motor (preganglionic sympathetic) cell of the vagus; *c*, *d*, small cells of the dorsal motor nucleus of the vagus; *C*, solitary fasciculus; *D*, dorsal motor (preganglionic sympathetic) nucleus of the vagus; *E*, root fibres (preganglionic sympathetic from *D*) of the vagus; *F*, axis-cylinders of the central (secondary) vago-glossopharyngeal tract (from *A*); *G*, fourth ventricle.

end immediately in terminal nuclei or descend forming the long descending bundle known as the *fasciculus solitarius* which gives off collaterals and terminals *en route* and finally decussates dorsal to the central canal just caudad to the fourth ventricle. The following are the terminal nuclei of the afferent fibres (Winkler):

(*a*) The terminal nucleus of nerve V probably also receives the few cutaneous fibres of IX and X (see above).

(*b*) The *nucleus ventralis fasciculi solitarii*, closely adjacent ventro-laterally to the fasciculus. It probably receives the proprioceptive fibres and sends its axones (internal arcuate fibres) to the medial lemniscus.

(*c*) The *dorsal sensory nucleus* lying in the central gray medial to the fasciculus solitarius; (*d*) the *nucleus rotundus* in the central gray lateral to (*c*); and (*e*) the *nucleus commissuralis* (previous section) lying dorsal to the central canal just caudad to the fourth ventricle. Nuclei (*c*), (*d*) and (*e*) contain few medullated fibres and probably receive the mucosal fibres. They give rise to second-

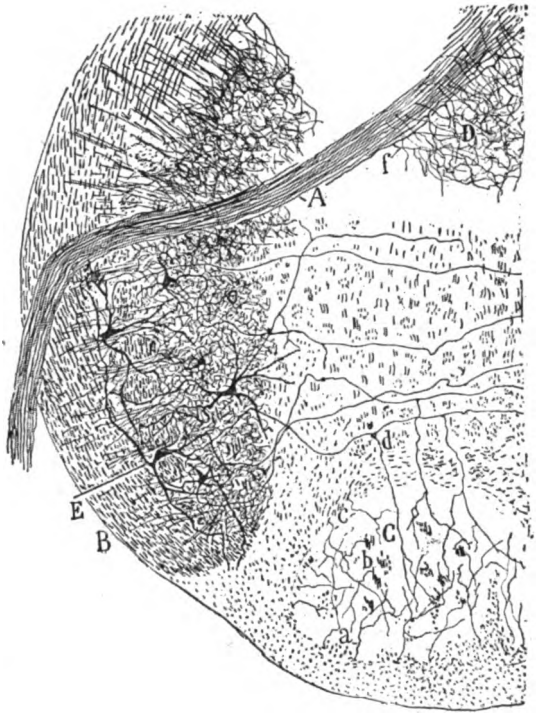

FIG. 352.—Portion of a Transverse Section of the Medulla of a Mouse Several Days Old, at the Level of the Nucleus of the Facial Nerve. Chrome-silver impregnation of Golgi. (Cajal.) *A*, afferent root of the glossopharyngeus; *B*, spinal root of the trigeminus (spinal V), cut transversely. Collaterals from its fibres are shown passing inward and forming a plexus (*e*) which terminates in the terminal nucleus of the spinal V. From the larger (marginal and deep) cells (*E*) of this nucleus secondary trigeminal fibres are shown passing transversely through the reticular formation and giving off collaterals (*d*) to the nucleus of the facial; *C*, nucleus of the facial which is shown receiving collaterals also from the continuation of the lateral column passing by (*a*) or through (*b*) it; *D*, collaterals from the afferent fibres of the glossopharyngeus terminating one of the terminal nuclei (superior, gustatory?) of the glossopharyngeus and vagus. Compare Figs. 365 and 366.

ary tracts to the nucleus ambiguus (palatal and pharyngeal reflexes), to the dorsal preganglionic nucleus, phrenic nucleus in the cervical cord, and the nuclei of the costal muscles in the thoracic cord, involved in coughing, vomiting and respiration. Probably still other intermediate reticulo-spinal neurones are also involved. It is probably these secondary neurones forming portions of the respiratory circuits whose bodies or synapses are affected by changes in the blood (CO_2, etc.) in such manner as to cause changes in respiration.

(*f*) The *nucleus dorsalis fasciculi solitarii*, dorsal and closely adjacent to the fasciculus solitarius; (*g*) the prevagal *nucleus gustatorius* occupying a space just cephalad of the fasciculus solitarius and adjacent and medial to the nucleus terminalis of the spinal V. Nuclei (*f*) and (*g*) probably receive taste fibres and give rise to the reflex fibres which proceed directly or *via* nuclei prepositus and intercalatus and bundle of Schütz to tongue and secretory nuclei. They also give rise to fibres forming a part of the afferent pallial taste path (see path 7). (Figs. 348, 349, 350, 351 and 356).

If the roots of the X do not show well in the section, defer their study until the following section where the IX shows similar relations.

The spinal V is partly pierced and partly covered by transverse fibres, principally olivo-cerebellar fibres (see below). Its terminal nucleus is less conspicuous.

Another bundle composed of descending afferent root fibres is the *descending vestibular root.* It lies lateral to the fasciculus solitarius. Accompanying it are cells which constitute its terminal nucleus, *nucleus of the descending vestibular root.* Occupying the floor of the ventricle medial to the descending vestibular root is another terminal nucleus of the vestibular nerve, the *nucleus mediatis vestibularis* (triangular or chief nucleus). Internal arcuate fibres emerging from those regions represent secondary tracts (probably reflex) from these nuclei. It would seem probable that those from the descending root nucleus are those conveying vestibular (and cerebellar) impulses to the voluntary muscles regulating posture (tone), while those from the medial nucleus form part of the paths of the vestibular visceral reflexes (nausea, vomiting, secretory changes etc. after excessive vestibular stimulation). In some sections a conspicuous bundle can be seen emerging from the medial nucleus and passing across the central gray of the vagus region to the nucleus intercalatus and beyond. This is the *tractus reunions of Fuse.* (P. 544; Figs. 348, 349, 361, 356, 357 and 358).

The nucleus gracilis has disappeared. The nucleus cuneatus may be present, much diminished, and give rise to some internal arcuate fibres to the medial lemniscus. The lemniscus is now a tract which has become built up on each side of the median line. This latter is known as the raphé (*i.e.*, "seam," stitched by the decussating fibres).

The ventral spino-cerebellar tract and lateral spino-thalamic tract are in about the same lateral position, but the dorsal spino-cerebellar tract has moved dorsally and together with olivo-cerebellar fibres (see below) begins to form the *restiform body* (see below). The other ascending spino-bulbar and spino-tegmental etc. fibres, lying mesial to the lateral spino-thalamic tract in the ventro-lateral white column and called the medial spino-thalamic tract, now lie dorsal to the inferior olivary nucleus so that the latter may be regarded as a new structure added ventrally to the continuations of the spinal cord structures.

In the lateral part of the reticular formation, between spinal V and olive are seen the *nuclei funiculi lateralis.* In these nuclei some of the spino-cerebellar fibres end. The axones of these nuclei partly enter the restiform body on the same side and partly cross to the opposite restiform body (p. 541; Fig. 368). They form some of the *ventral external arcuate fibres* seen in the section. The lateral nuclei are thus partial interruptions in the spino-cerebellar path and possibly other ascending paths in this region. The *nuclei arcuati* or *arciformes*,

external to the pyramids, are well marked. They send crossed fibres to the cerebellum *via* the restiform body.

Other Afferent Cerebellar Neurones.—A new and important convoluted mass of gray is the *inferior olivary nucleus*, forming the bulge of the lateral surface of the medulla known as the olive. It is composed of three distinct parts: the *principal inferior olivary nucleus* comprising the much largest convoluted portion, the *medio-ventral accessory inferior olivary nucleus* and the *dorsal accessory inferior olivary nucleus*. The axones of the olivary cells are the *olivo-cerebellar fibres* distributed to all parts of the opposite half of the cerebellar cortex. The accessory portions are the oldest (palaeo-olive) and send their fibres to the vermis (palaeo-cerebellum). The principal portion (neo-olive) sends the bulk of its fibres to the hemispheres of the cerebellum (neo-cerebellum). The olivo-cerebellar fibres cross through the fillets, pass through or around the opposite olivary nucleus, thence proceed dorso-laterally, being gathered into more compact bundles, traverse or surround the spinal V and, dorsal to it, bend longitudinally, forming a great part of the restiform body. The latter produces an eminence on the dorso-lateral surface of the medulla. The restiform body, thus formed by these spino-cerebellar and olivo-cerebellar fibres, together with certain others, passes into the cerebellum higher up, forming the major part of the inferior cerebellar arm or peduncle. According to many authorities fibres from the columns and nuclei of Goll and Burdach of the same side (dorsal external arcuate fibres) and opposite side (ventral external arcuate fibres) may join the restiform body. This however is quite uncertain. (Comp. p. 567.)

Fibres appearing on the external surface of the olivary nucleus are the termination of a large tract descending to the olivary nucleus, the *central tegmental tract*. Its origin in higher levels is not accurately known. The tract of Helweg has apparently disappeared. According to some authorities it terminates in the inferior olivary nucleus.

Intersegmental Neurones.—The reticular formation is now still more extensive.

The rubro-spinal tract lies dorso-mesial to the lateral spino-thalamic and ventral spino-cerebellar tracts. The Deitero-spinal and other vestibulo-spinal fibers lie partly dorsal to the inferior olivary nucleus and partly more mesial in or near the medial longitudinal fasciculus. The latter vestibulo-spinal fibres together with fibres from other nuclei in the reticular formation, of fibres from the interstitial nucleus of the medial longitudinal fasciculus, and probably uncrossed fibres from the superior colliculus, now form the *medial longitudinal fasciculus* dorsal to the fillet. Near this bundle, or united with it, is the crossed colliculo-spinal tract (*predorsal tract*). When these tracts have passed down to below the formation of the fillet and the olives, they assume the positions noted in the lower levels of the medulla.

In this section, and others below and above through the midbrain, are to be seen various ill defined cell groups in both gray and white (near raphé) reticular formation the *nuclei reticularis*. Some lie in or very near the median line or raphé (*nuclei raphes*), others in the adjacent white (*nuclei reticularis albae*), others in the gray reticular formation (*nuclei reticularis griseae*). Most of them are composed of medium or large cells and among them are very large cells (*nuclei gigantocellulares*). Some cells resemble motor cells in arrangement of

Nissl bodies (*pre-motor* cells). The axones of reticular cells are in general crossed and uncrossed and, by splitting or bending, become ascending and descending fibres. Collaterals of secondary afferent neurones terminate among them and many are probably to be regarded as tertiary afferent, or as premotor neurones, completing reflex circuits by acting upon lower motor neurones. (*e.g.* reticulo-spinal fibres of the respiratory circuit). Others (or the same?) are possibly neurones receiving pyramidal terminals (path 18) and distributing their motor impulses to the appropriate lower motor (peripheral) neurones. The vestibulo-spinal, rubro-spinal and other medial longitudinal fasciculus neurones may belong in the same general category though their nuclei are not usually included in the nuclei of the reticular formation.

In the central gray are to be seen the *nucleus intercalatus of Staderini* in the medial eminence just dorsal to the nucleus XII, merging cephalad into the *nucleus prepositus* (Fig. 353) and the *nucleus eminentiæ medialis* or *nucleus funiculi teretis*. As already pointed out these are probably intersegmental neurones belonging to certain reflex (and other?) gustatory (and olfactory) paths to tongue and to secretory nuclei. Some authorities, however, assert that the nucleus intercalatus is a sympathetic vagus nucleus sending preganglionic fibres to innervate, with sympathetic ganglionic relays, the involuntary muscles.

Efferent Suprasegmental Neurones.—The pyramids are the same. Small bundles of more lightly stained fibres, present in the fillet here and in higher levels (Weigert stain, not indicated in the figures), are efferent pallial fibres detached from pes or pyramids. They are aberrant fibres which innervate the more caudal motor cranial nuclei or rejoin the pyramids lower down (see path 18). The colliculospinal tract (see above).

4. Transverse Section of the Medulla through the Middle of the Olivary Nucleus

Such a section is so similar to 3 and 5 that its detailed description may be omitted. The fourth ventricle is wider; the nucleus cuneatus has disappeared; the fillet increased somewhat; fasciculus solitarius and descending vestibular root have increased; also their terminal nuclei. The olivary nucleus, olivocerebellar fibres, and the restiform body have greatly increased. The formatio reticularis has increased in extent.

5. Transverse Section of the Medulla through the Entrance of the Cochlear Root of Nerve VIII (Figs. 343 and 353)

(For the various paths involved see pp. 507–519)

In addition to the changes enumerated under the preceding section, the fourth ventricle has now attained its maximum width and in favorable sections can be seen its lateral extensions, the *lateral recesses*, passing external to the tuberculum acusticum (see below) and just caudad to where the latter fuses with the cerebellum. The trigonum vagi has disappeared and with it the greater part of the vagus nuclei in the central gray. The nerves of this level are the glossopharyngeus (see section 3) and the cochlear portion of nerve VIII.

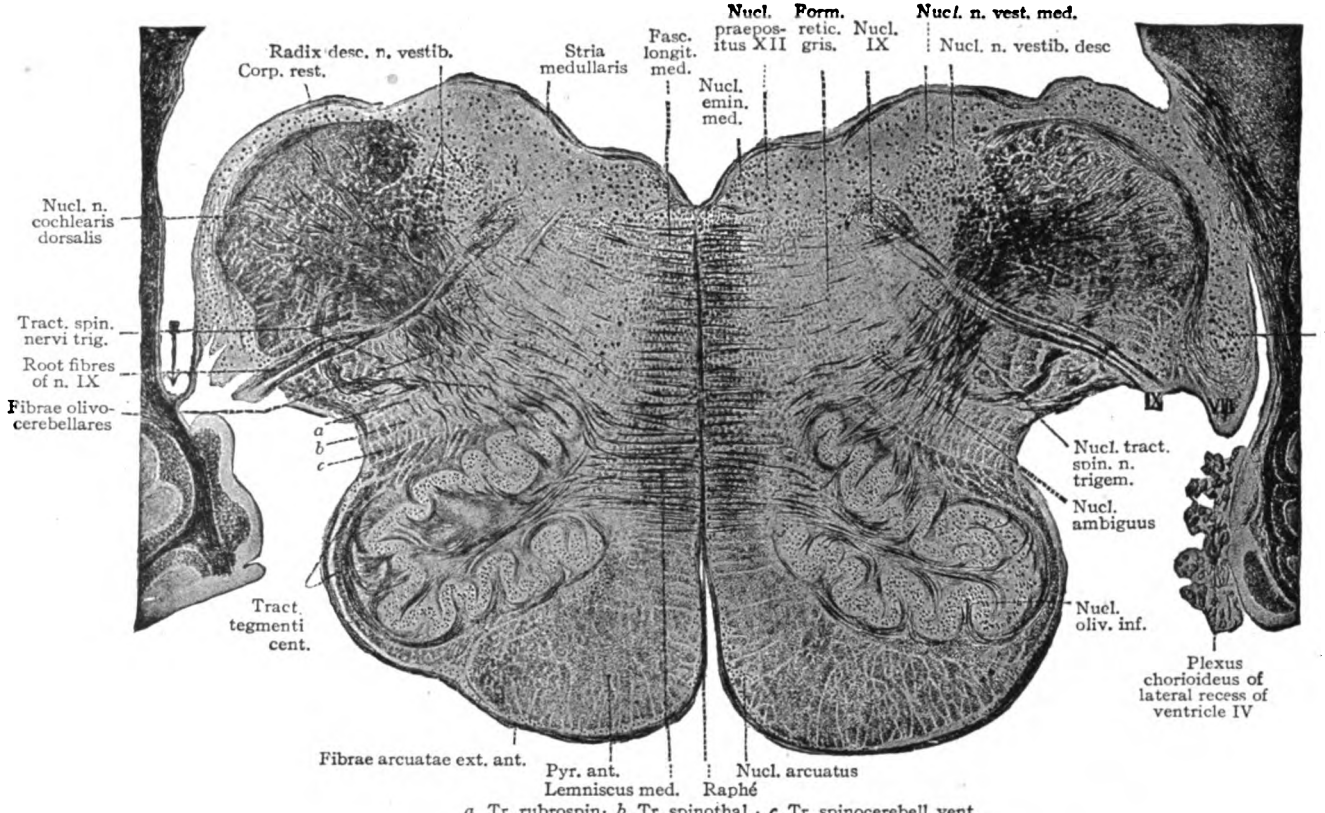

FIG. 353.—Transverse Section of the Medulla through the Entrance of the Cochlear Nerve. Weigert preparation. (Rauber-Kopsch.) The arrow on the left is directed into the lateral recess of the fourth ventricle.

The *Acusticus* is divided into two parts: the *cochlear nerve* (ganglion spirale) and the vestibular nerve (ganglion of Scarpa). The fibres of the cochlear root enter at a lower level than those of the vestibular. Some of them enter the *ventral cochlear nucleus;* the remainder pass dorsalward to the *dorsal cochlear nucleus*, or *nucleus of the acoustic tubercle.* According to some authorities. some root fibres pass to the *superior olivary* and *trapezoid nuclei* of the same and opposite sides. The axones of the cells of the ventral and dorsal nuclei form the secondary cochlear tract (*lateral fillet*). The majority of these fibres decussate and send collaterals to, or are partially interrupted in, the nucleus olivaris superior, trapezoideus, nucleus of lateral fillet and inferior colliculus (posterior corpus quadrigeminum). According to some authorities the fibres of the lateral lemniscus terminate in the inferior colliculus. From the inferior colliculus the path is formed by the arm or brachium of the latter to the medial geniculate body and thence to the temporal cortex cerebri. It is thus not possible to state definitely how many neurone systems are involved, but the principal ones are: (1) ganglion spirale, (2) dorsal and ventral nuclei and (decussation) lateral lemniscus, (3) posterior corpus quadrigeminum and its brachium, (4) medial geniculate body of the thalamus and geniculo-cortical fibres. f the lateral lemniscus fibres be regarded as simply passing by the posterior corpus quadrigeminum. giving collaterals to it (Cajal), the path would in part consist of three neurone systems analogous to those of the paths from the cord, trigeminus and eye. (Figs. 342, 359.)

The root fibres of the *vestibular nerve* (see next section) enter higher and mesial to those of the cochlear, passing dorsally along the inner side of the restiform body to four terminal nuclei, which cannot all be clearly seen in any one section; (*a*) *Deiters nucleus* (*lateral vestibular nucleus*) situated at the end of the main bundle of root fibres, just internal to the restiform body; (*b*) *von Bechterew's nucleus* (*superior vestibular nucleus*) situated higher and somewhat dorsal to Deiters' nucleus in the lateral wall of the fourth ventricle; (*c*) the *medial vestibular nucleus* (*principal nucleus, triangular nucleus, Schwalbe's nucleus*) occupying a considerable part of the floor of the fourth ventricle; (*d*) the *nucleus* of the *descending vestibular root* (spinal eighth). Fibres also pass to the *cerebellum.* The axones of the cells of the terminal vestibular nuclei form the secondary vestibular tracts, some axones going to (*a*) the cerebellum, (*b*) the midbrain, especially to the nuclei of nerves III and IV (*via* Deiters, medial and von Bechterew, by the medial longitudinal fasciculus, crossed and uncrossed), (*c*) the medulla and cord, to various motor nuclei, *via* the medial longitudinal fasciculus (uncrossed and crossed, principally uncrossed), lateral tract from Deiters' nucleus (uncrossed) and possibly other tracts in the reticular formation. (Figs. 342, 361, 368 and 358).

According to some authorities, the separation centrally of the continuations of the cochlear and vestibular divisions of nerve VIII is not so complete as indicated above and some of the roots fibres may pass still further inward along with the various secondary tracts (Winkler). The cochlear nerve is the nerve of hearing with extensive pallial representation and a conspicuous afferent pallial path. Its reflex connections are not so important (tensor tympani, stapedius, turning eyes to sound, reflex reaction to loud noise). The vestibular

nerve, on the other hand, brings in stimuli from the vestibule and semicircular canals which do not appear to have an extensive pallial representation and the afferent pallial path of which is not well known. These stimuli exert however, a strong reflex influence upon the postural musculature of the body, which maintains the position of body, head and eyes in standing, locomotion, etc. Disturbances of the peripheral apparatus, nerve, central nuclei and further

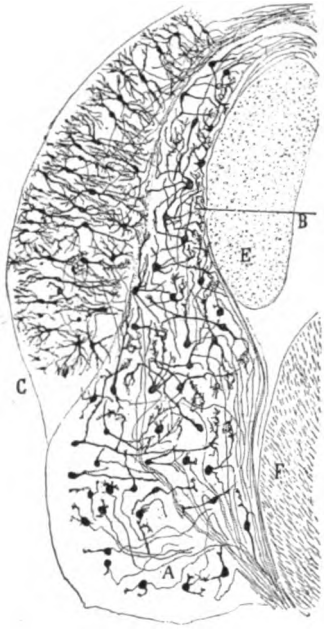

FIG. 354.—Lateral Portion of a Transverse Section of the Medulla of a Rabbit Eight Days Old, at the Level of the Lower Border of the Pons. *A*, ventral (or "accessory") cochlear nucleus; *B*, the "tail" of the ventral cochlear nuclieus; *C*, the dorsal or lateral cochlear nucleus (acoustic tubercle); *E*, restiform body; *F*, spinal V. Axones from the ventral nucleus and some axones from the dorsal nucleus are shown passing inward ventrally to the spinal V to become trapezius fibres (ventral secondary cochlear tract). From the dorsal nucleus and the dorsal part, or tail, of the ventral nucleus axones are shown passing inward dorsally and adjacent to the restiform body. These fibres pass ventrally medial to the restiform body and spinal V and join the trapezius fibres (bundle of Held, not present in man; compare Fig. 358). The bulk of the fibres of the dorsal nucleus shown passing around the restiform body dorsally to the bundle of Held form the striæ acusticæ (dorsal secondary cochlear tract, well-marked in man). The dorsal nucleus is, relatively to the ventral, less important in man. The ventral cells of the ventral nucleus have fewer and shorter dendrites than the dorsal cells of the ventral nucleus. The former receive the terminals of the cochlear root fibres with bulbous enlargements (see Fig. 355).

connections *via* medial longitudinal fasciculus result in disturbances in standing and locomotion, deviations of head and eyes (nystagmus) and vertigo. How far the cerebellum participates in the vestibular reactions is somewhat uncertain. In addition the vestibular nerve has important visceral reflex connections, seen in nausea, vomiting and the accompanying secretory and vasomotor changes due to vestibular irritation. As already mentioned (p. 535) these visceral con-

nections may be partly by fibres from the medial vestibular nucleus lying close to the splanchnic bulbar (vagus) area.

Efferent Peripheral Neurones.—The dorsal vagus nuclei may not be present, but the nucleus ambiguus is usually present and probably sends some axones to nerve IX, passing out with the afferent fibres (see below). The nucleus XII has disappeared and also its root fibres.

Afferent Roots, their Terminal Nuclei and Secondary Tracts.—Usually the afferent root fibres of nerve IX are present. They enter on the lateral aspect

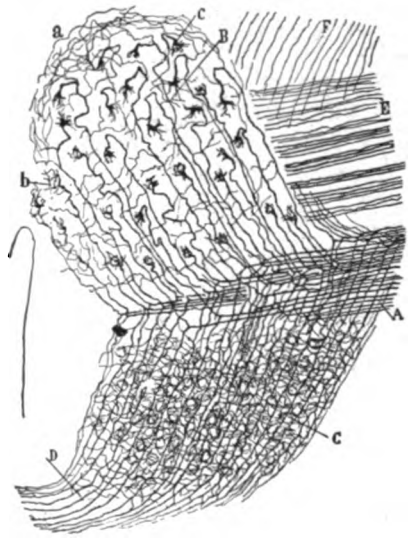

FIG. 355.—Longitudinal, dorso-ventral Section through the Ventral (accessory) Nucleus of the Cochlear Nerve, Showing the Entrance and Bifurcation of the fibres of the Cochlear Root. New-born cat. Chrome-silver impregnation of Golgi. (Cajal.) *A*, cochlear nerve root; *B*, superior (cephalic) portion of the ventral nucleus, in which the ascending arms of the cochlear root fibres terminate; *C* (lower part of figure), inferior (caudal) portion of the ventral nucleus, in which the descending arms of the cochlear root fibres terminate; *D*, continuation of the descending arms which terminate in the dorsal nucleus (acoustic tubercle) and the dorsal portion (tail) of the ventral nucleus, and some of which possibly pass beyond (into the bundle of Held?); *a*, marginal plexus formed by collaterals from ascending arms; *b*, terminal arborization of ascending arm; *c* (upper part of figure), terminal arborization of ascending arm with bulbous enlargement. These terminate around the cells of the ventral nucleus with few dendrites (see Fig. 354); *C* (lower part of figure), pericellular nests formed by collaterals from descending arms.

of the medulla ventral to the restiform body, traverse the spinal V, and pass to the fasciculus solitarius or to the nucleus gustatorius which is usually visible. The fasciculus solitarius is smaller, and just above the entrance of IX consists of only a comparatively few descending afferent root fibres of nerve VII.

The fibres of the *cochlear nerve* enter the extreme lateral angle of the medulla, where many or, according to some, all of them terminate in two masses of cells enveloping externally the restiform body and known as the *ventral* (or *accessory*) and *dorsal* (or *lateral*) *cochlear nuclei*. Most of the axones of the dorsal nucleus pass across in the floor of the ventricle (*striæ acusticæ*) to form a part of the

opposite secondary tract (*lateral lemniscus*) of the cochlear nerve. The axones of the ventral nucleus also decussate, but by a more ventral route (*trapezius*),

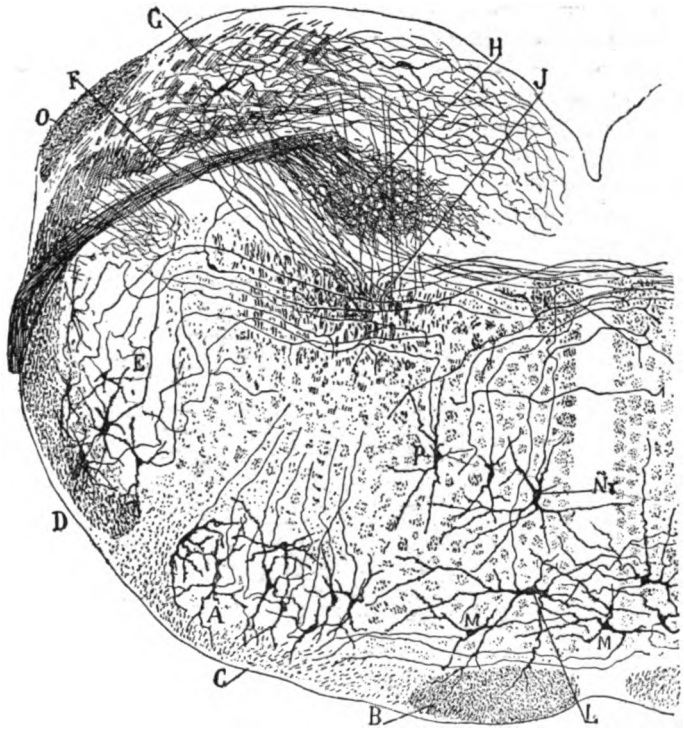

FIG. 356.—One half of a Transverse Section of the Medulla of a New-born Mouse, at the Level of the Nucleus Facialis. Chrome-silver impregnation of Golgi. (Cajal.) The different appearance of the section, as compared with the human medulla is principally due to the small size of the pyramids (arising from the smaller neopallium), to the absence at this level of the small pons (connecting neopallium and neocerebellum), to the small size of the medial lemniscus (path to the smaller neopallium), to the small size of the restiform body (passing partly to the smaller neocerebellum) and to the large spinal V. *A*, motor nucleus of the facial nerve, its axones are shown passing dorsally (motor root fibres of facial); *B*, pyramid; *C*, continuation of the remnant of the lateral column of the spinal cord; *D*, spinal *V*; *E*, terminal nucleus of the spinal *V*, axones from its cells are shown forming a secondary, principally uncrossed, tract (*J*) in the dorsal part of the gray reticular formation; *F*, root of vagus passing to solitary fasciculus; *G*, descending vestibular root fibres and their terminal nucleus, their collaterals are also shown terminating more medially in the medial vestibular nucleus; *H*, terminal nucleus of solitary fasciculus, collaterals of which are shown terminating within it; *J*, secondary trigeminal tract previously mentioned; *L* and (medial) *M*, cells of nucleus raphés (one of the nuclei reticularis); *M* (lateral) and *Nr*, cells of nucleus reticularis in white reticular formation; *O*, restiform body; *p*, cell of nucleus reticularis in gray reticular formation. The axones of the cells of the nuclei reticularis are shown forming longitudinal fibres (by turning or splitting) in the reticular formation of the same and opposite side.

and also form a part of the lateral lemniscus. This latter decussation takes place at a higher level (see next section). (Figs. 358 and 359).

The descending vestibular root, its nucleus and the medial vestibular nucleus are large in this section.

The spinal V is unchanged, its terminal nucleus being rather indistinct. Secondary trigeminal tracts cannot be distinguished. The fillet is about the same positions. Part of the medial spino-thalamic tract is still dorsal to the inferior olivary nucleus or may have joined the fillet.

Other Afferent Cerebellar Neurones.—The olives are still larger and send many bundles of olivo-cerebellar fibres to the opposite restiform body which has still further increased in size. External arcuate fibres may be present and probably contain fibres to the restiform body and possibly fibres from the cerebellum, which end in the reticular formation. The arcuate nuclei are present. The central tegmental tract is larger.

Intersegmental Neurones.—The reticular formation is very extended. Its composition (longitudinal and transverse fibres, and cells) should be examined carefully. The nucleus prepositus is large and occupies the area occupied by

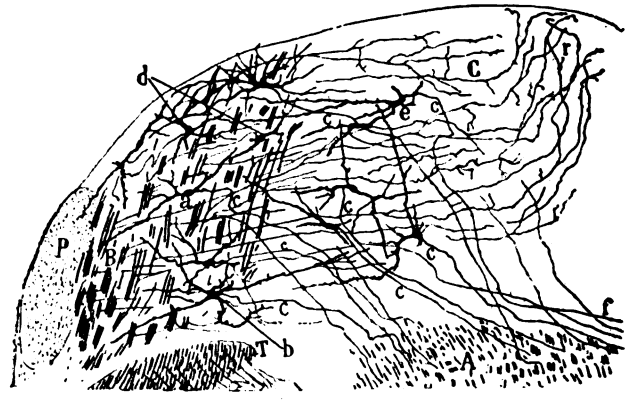

FIG. 357.—Portion of a Transverse Section of the Medulla of a Mouse four Days Old at a Level below the Genu Facialis. Chrome-silver impregnation of Golgi. (Cajal) *A*, dorsal part of the gray reticular formation, containing the uncrossed, or direct, vestibular tract; *B*, descending vestibular root and its terminal nucleus; *C*, medial terminal nucleus of vestibular nerve; *a* and *b* ,cells whose axones are passing to the uncrossed secondary vestibular tract; *c*, axones or axis-cylinders; *d*, cells whose axones are directed laterally; *e* and *f*, cells whose axones pass toward the raphé (to the crossed secondary vestibular tract); *P*, restiform body; *T*, spinal V.

the nucleus of nerve XII in the preceding sections. The rubro-spinal tract is in the same position, but the lateral vestibulo-spinal tract is now more internally located. Its fibres cannot usually be distinguished, but are bending dorsally toward its nucleus of origin (located somewhat higher). The *medial longitudinal fasciculus* may be partially separated from the medial lemniscus. It is a complex bundle and contains at various levels (*a*) descending and ascending fibres from vestibular nuclei, (*b*) descending fibres from the interstitial nucleus and the nucleus of the posterior commissure, in the tegmentum of the midbrain, and probably uncrossed descending collicular fibres, (*c*) internuclear fibres connecting the nuclei of nerves III, IV, and VI ,(*d*) possibly secondary trigeminal fibres; (*a*) terminate on motor nuclei of nerves III, IV, VI and motor spinal nuclei and exert the vestibular influence upon the muscles of eyeball, neck and

body (compensatory eye and head movements, etc.), (*b*) is probably part of an optic reflex path to eye muscles and possibly to the head-turning muscles of the neck, (*c*) secures those conjugate movements of eyes involving the external recti muscles. According to some authorities this last connection is by means

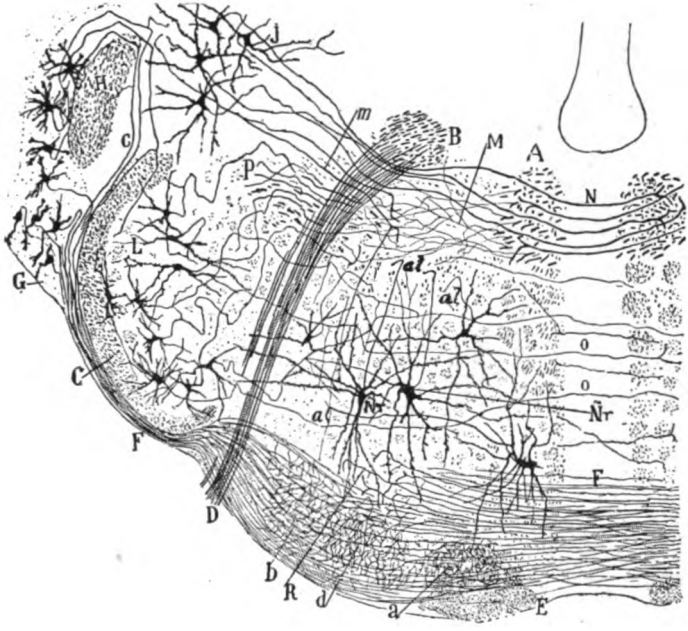

FIG. 358.—One Side of a Transverse Section of the Medulla of a New-born Mouse at the Level of the Emergence of the Facial Nerve. Chrome-silver impregnation of Golgi. (Cajal.) *A*, posterior or medial longitudinal fasciculus, traversed by the crossed secondary vestibular tract (from Deiters' nucleus); *B*, facial nerve (genu); *C* (outside the drawing), spinal V; *D*, emerging root of facial nerve; *a*, (on lower edge of figure), collaterals from trapezius fibres (secondary cochlear tract) terminating in the nucleus of the trapezoid body; *b*, collaterals from the trapezius fibres terminating in the superior olivary nucleus; *d*, fibres from the trapezius fibres terminating in the parolivary nucleus; *c*, (near *H*), fibres passing from the ventral (and dorsal) cochlear nucleus to the trapezius (bundle of Held); *E*, pyramid; *F* (outside the drawing), trapezius fibres passing along the surface outside the spinal V; *F* (median line), decussating trapezius fibres, the more dorsal ones are from the opposite side; *G*, ventral cochlear nucleus; *H*, restiform body; *J*, nucleus of Deiters; *L*, terminal nucleus of spinal *V*; *M*, nucleus of abducens nerve, in which collaterals from the medial longitudinal fasciculus are shown terminating; *N*, decussating fibres of the secondary vestibular tract (from Deiters nucleus); *Nr*, large cells of the nuclei reticularis lying in the gray reticular formation, their axones (uncrossed) are shown bending or splitting (*al* and *a*) into longitudinal fibres of the gray reticular formation; *o* (in median line) decussating fibres of secondary trigeminal tract; *P*, uncrossed and crossed secondary (short?) trigeminal tract in dorsal part of gray reticular formation; *R*, trapezius fibres from the opposite side splitting or bending into longitudinal fibres.

of collaterals from the root fibres of the abducens to the nucleus of nerve III instead of by internuclear neurones. Further probable connections mediated by fibres of the medial longitudinal fasciculus are: (*e*) Connections between nucleus III and the nucleus of the upper facial, providing for the associated

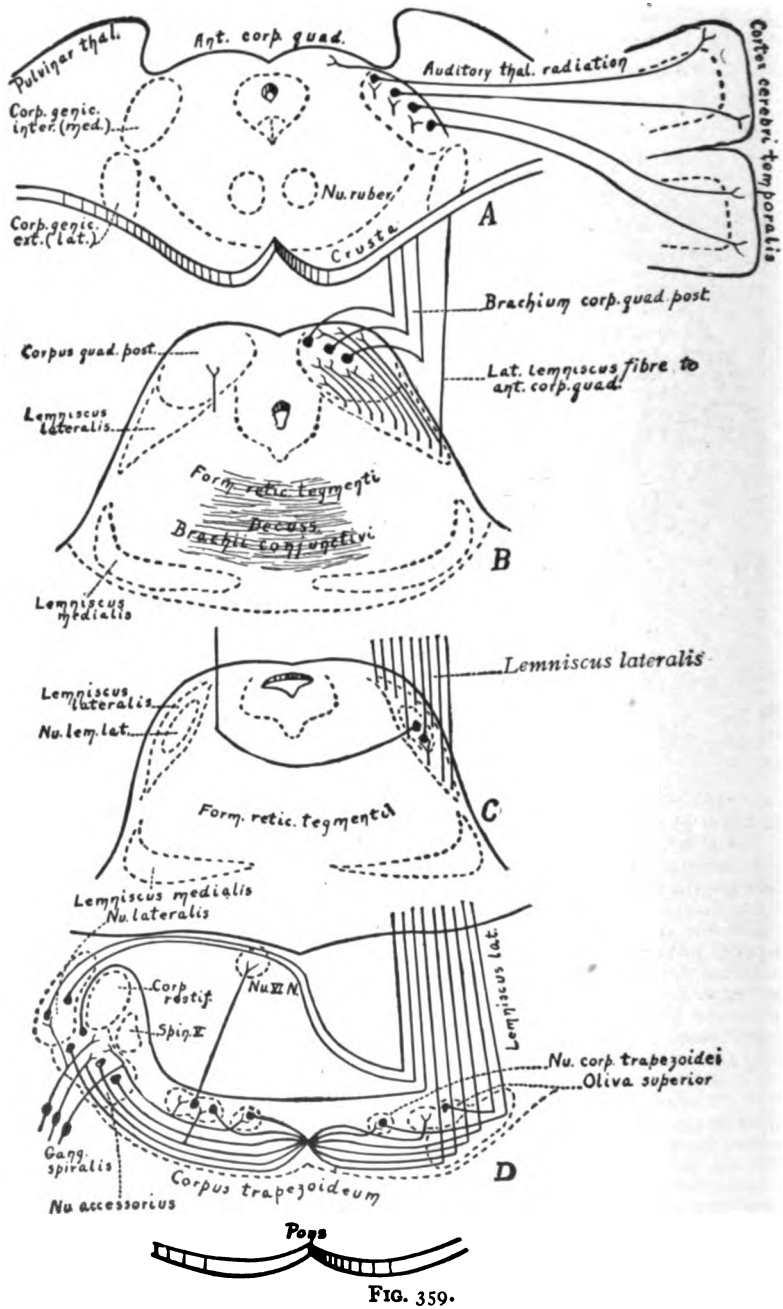
Pulvinar thal.
Ant. corp. quad.
Auditory thal. radiation
Cortex cerebri temporalis
Corp. genic. inter. (med.)
Nu. ruber
Corp. genic. ext. (lat.)
Crusta
A
Brachium corp. quad. post.
Corpus quad. post.
Lat. lemniscus fibre to ant. corp. quad.
Lemniscus lateralis
Form. retic. tegmenti
Decuss. Brachii conjugativi
B
Lemniscus medialis
Lemniscus lateralis
Lemniscus lateralis
Nu. lem. lat.
Form. retic. tegmenti
C
Lemniscus medialis
Nu. lateralis
Corp restif.
Nu. VI N.
Spin. V
Lemniscus lat.
Nu. corp. trapezoidei
Oliva superior
Gang. spiralis
Corpus trapezoideum
D
Nu accessorius
Pons

FIG. 359.

EXPLANATION OF FIG. 359

FIG. 359.—Diagram showing Connections of the Cochlear Portion of the Auditory (VIII) Nerve. *A*, Section at level of superior colliculi (*Ant. corp. quad.*) and red nucleus; *B*, through level of inferior colliculi (*Corpus. quad. post.*); *C*, through level of nucleus of lateral lemniscus (*Nu. lem. lat.*); *D*, through pons at level of VIII nerve. Spacing between the different levels is not proportionate. In *B* and *C* the basis pedunculi is omitted. Each neurone group is indicated by one or several individual neurones.

Neurone No. 1.—Cell bodies in spiral ganglion (*gang. spiralis*); peripheral processes end in organ of Corti; central processes terminate principally in ventral or accessory nucleus (*Nu. accessorius*) and lateral nucleus (*Nu. lateralis*) or tuberculum acusticum; some also terminate in superior olives (*Oliva superior*), and nuclei of trapezoid body (*Nu. corp. trapezoidei*) of same and opposite sides.

Neurone No. 2. (and 3?).—Axones of cells in accessory nucleus, in superior olives, and in nuclei of trapezoid body, constitute a ventral path in the lower border of the tegmentum, and form the lateral part of the lateral lemniscus (*Lemniscus lateralis*) or lateral fillet on the opposite side. Axones of cells in the lateral nucleus traverse the floor of the fourth ventricle as the striæ medullares, forming a dorsal pathway, decussate and then turn ventrally to a point dorsal to the superior olive and join the lateral lemniscus as its mesial part. Some axones also of cells in the accessory and lateral nuclei pass dorsally, looping around the restiform body, and then proceed ventrally (bundle of Held) to join the opposite lemniscus. The lateral lemniscus passes upward to the inferior colliculus, some of the axones terminating *en route* in the nucleus of the lateral lemniscus. From cells in this nucleus some axones again join the lateral lemniscus, and a few decussate and then pass upward to the inferior colliculius. The axones of the lateral lemniscus terminate in the inferior colliculus, or pass on to terminate in the internal geniculate body, merely giving off collaterals to the superior colliculus. Some fibres of the lateral lemniscus probably go to the superior colliculus.

Neurone No. 3 (and 4?).—Axones of cells in the gray matter of the inferior colliculus form its brachium (*Brachium corp. quad. post.*) and ascend to terminate in the internal or medial geniculate body (*Corp. genic. inter.*).

Neurone No. 4 (and 5?).—Axones of cells in the internal geniculate body pass as a part of the thalamic radiation *via* the posterior part of the internal capsule to the cortex of the temporal lobe of the cerebrum.

The axones which constitute the ventral path (Neurones 1 and 2) form a bundle of fibres known as the trapezoid body (*Corpus trapezoideum*) or trapezius. The decussation of these is peculiar in that the dorsal axones of the bundle on one side become the ventral ones on the opposite side; this accounts for the convergence of the axones at the median raphé.

Axones of cells in the superior olive pass to the nucleus of VI nerve (reflex). There is possibly also a descending path from the lateral nucleus to the spinal cord (not indicated).

elevation of forehead and eyelids in opening the eyes widely, also closure of the eyes to certain visual and auditory stimuli. The closure of the eyes to strong light, blinking reflex, is more probably by colliculo-bulbar fibres to nucleus VII (orbicularis oculi). (*f*) Fibres connecting nuclei XII and VII, providing for the associated movements of tongue and lips. According to one view these fibres may be root fibres of nerve XII (on account of labial weakness observed in lesions of XII). (Comp. Figs. 361, 368 and 383.)

Efferent Suprasegmental Neurones.—The pyramids and colliculo-spinal tracts are in the same positions. The aberrant efferent pallial fibres already noted (p. 542) may be seen in the lemniscus.

6. Transverse Section of the Hindbrain at Level of Junction of Pons and Cerebellum and Entrance of Vestibular Nerve (Figs. 343 and 360).

(For the various paths involved see pp. 507–519.)

The most conspicuous features are the nuclei and fibres of the *pons*, added ventrally to the preceding structures, which latter are now collectively known as the *tegmentum;* the *cerebellum*, enclosing dorsally the *fourth ventricle;* and the connections (*inferior* and *middle peduncles, arms*, or *brachia*) of the cerebellum with the rest of the brain. The greater part (restiform body) of the inferior peduncle represents ascending cerebellar connections from all parts below this level, and the unknown inferior olivary connections; the middle peduncle (from the pons) is the second link in the descending connection from the pallium to the cerebellum (pallio-cerebellar path). The superior peduncle (efferent cerebellar) is not fully formed at this level. (Comp. p. 567.)

The nerves appearing at this and somewhat higher levels are the VII and VI. The *Facialis* is divided into a large *motor portion* innervating the facial musculature and a smaller *portio intermedia* (*nerve of Wrisberg, glosso-palatine nerve*) which is afferent and efferent. The latter nerve resembles the IX and X. It has a cerebrospinal ganglion (ganglion geniculi) and is connected with the sympathetic ganglion sphenopalatinum. Its afferent fibres are taste fibres to the anterior portion of the tongue (ganglion geniculi—chorda tympani), possibly a few cutaneous fibres to the external auditory meatus (J. Ramsay Hunt), proprioceptive (and mucosal?) fibres to the palate and anterior tongue (Winkler). It is suggested (Winkler) that the sphenopalatine ganglion also contains ganglion cells originating these latter and is thus a mixed cerebrospinal and sympathetic ganglion, possibly similar to the distal (petrosal and nodose) ganglia of IX and X. The efferent fibres are secretory (lacrimal, mucosal) and vasomotor fibres, relayed in the sphenopalatine ganglion; secretory to the submaxillary and sublingual glands, relayed through the submaxillary and sublingual ganglia; and possibly fibres to palatal muscles (Winkler). The intermedia is thus the older, reduced, branchial portion of the VII, comparable to IX and X, while the larger motor facial represents, in greater part at least, the newer part to the newer facial musculature of expression (see p. 504, Footnote).

Efferent Peripheral Neurones.—In this level and that of the next section are present the *nuclei* and *root fibres* of *nerves VII and VI.*

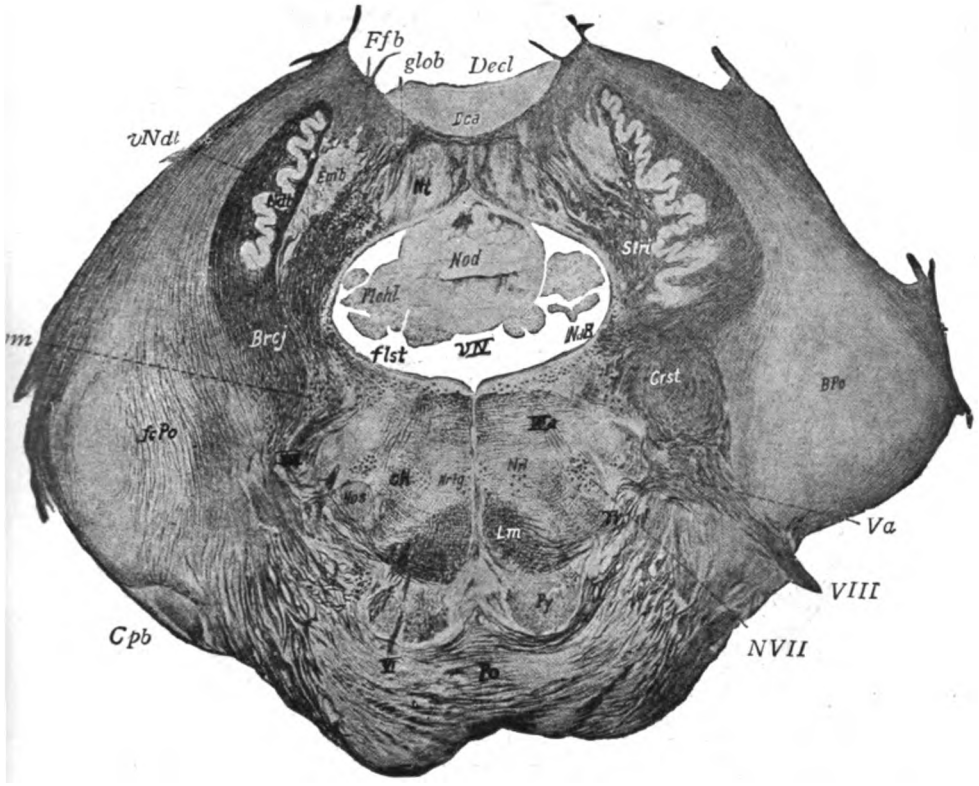

FIG. 360.—Section through the Hindbrain at the Level of the Junction of Pons and Cerebellum and the Entrance of the Vestibular Part of the Eighth Nerve. Weigert preparation. (Marburg.) *Va*, Radix spinalis trigemini (spinal root of the fifth); *VI*, nervus abducens (external eye muscle nerve); *VIIa*, pars nuclearis nervi facialis (pars prima, crus of origin or ascending facial root); *VIII*, nervus acusticus (eighth, vestibular part); *BPo*, brachium pontis (middle cerebellar peduncle); *Brcj*, brachium conjunctivum (superior cerebellar peduncle); *cH*, fasciculus tegmenti centralis; *Cpb*, corpus pontobulbare (Essick); *Crst*, corpus restiforme; *Dca*, decussatio cerebelli anterior; *Decl*, declive; *Emb*, embolus (nucleus emboliformis); *fc Po*, fibræ pontocerebellares; *Ffb*, fasciculus fastigiobulbaris (uncinate bundle of Russell); *flst*, pedunculus flocculi; *glob*, nucleus globosus; *Lm*, Lemniscus medialis (mesial fillet tract); *NVII*, nucleus facialis (motor nucleus of facial nerve); *NaB*, nucleus angularis, or superior, vestibularis (Bechterew); *Ndt*, nucleus dentatus cerebelli; *Nod*, nodulus cerebelli; *Nos*, nucleus olivaris superior; *Nrl*, nucleus reticularis lateralis (nucleus of the lateral column); *Nrtg*, nucleus reticularis tegmenti; *Nt*, nucleus tecti (nucleus fastigii); *Nvm*, nucleus vestibularis magnocellularis or lateralis (Deiters) (large-celled nucleus of vestibular nerve); *Plchl*, plexus chorioideus lateralis; *Po*, pons; *Py*, pyramid; *Stri*, stratum intermedium (pedunculi); *Tr*, corpus trapezoides; *vIV*, ventriculus quartus; *vNdt*, vellus nuclei dentati cerebelli (fleece of the cerebellar olive).

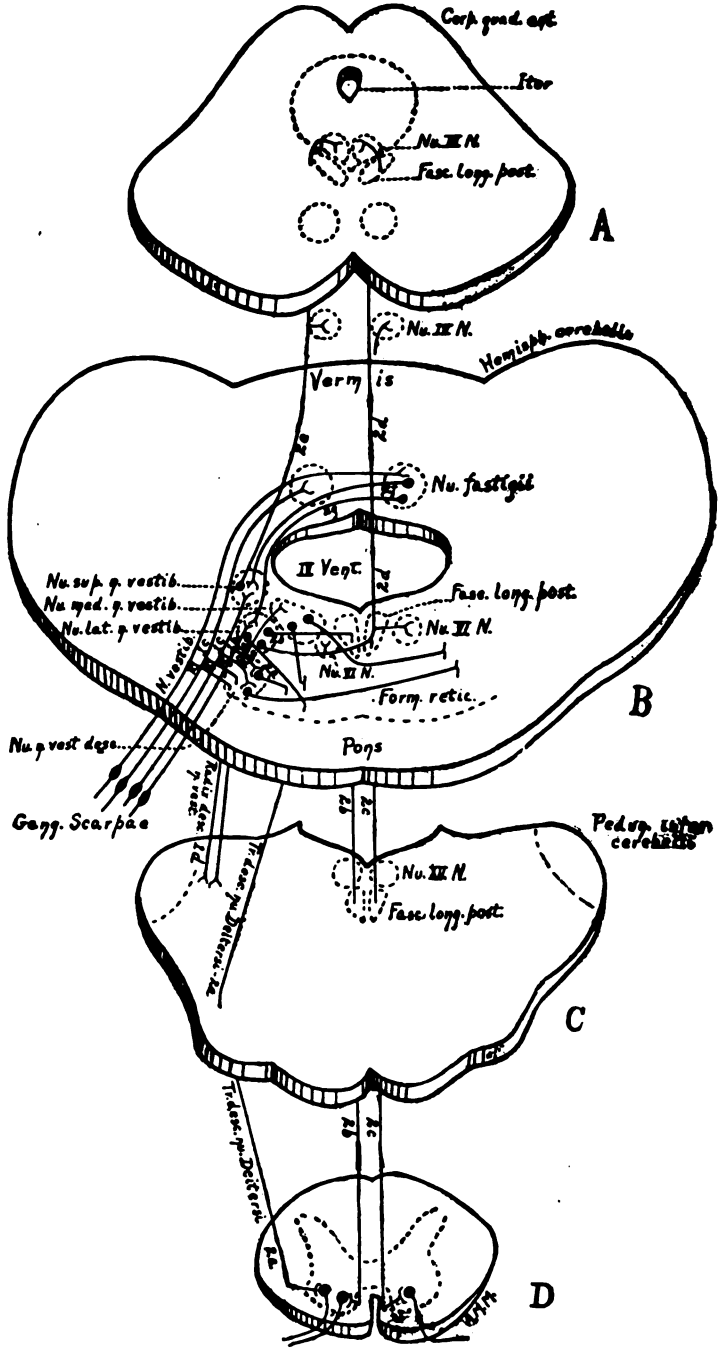
Corp. quad. ant.
Itor
Nu. III N.
Fasc. long. post.
A
Nu. IV N.
Hemisph. cerebelli
Vermis
Nu. fastigii
IV Vent.
Nu. sup. q. vestib.
Nu. med. q. vestib.
Nu. lat. q. vestib.
Fasc. long. post.
Nu. VI N.
Nu. VI N.
Form. retic.
B
Nu. q. vest. desc.
Pons
Gang. Scarpae
Nu. XII N.
Fasc. long. post.
C
D

FIG. 361.

EXPLANATION OF FIG. 361

FIG. 361.—Principal Connections of the Vestibular Portion of the Auditory (VIII) Nerve. *A*, Section at level of oculomotor (III) nerve; *B*, section through pons and cerebellum; *C*, through inferior olives; *D*, through spinal cord. Each neurone group is indicated by one or several individual neurones.

Neurone No. 1.—Cell bodies in ganglion of Scarpa; peripheral processes end in semicircular canals; central processes bifurcate, and ascending arms go to Deiters' nucleus (*Nu. lat. n. vestib.*) (1 *a*), to von Bechterew's nucleus (*Nu. sup. n. vestib.*) (1 *b*), and to nuclei fastigii and cortex of vermis of cerebellum (1 *c*), descending arms go to nucleus of descending root (*Nu. n. vestib. desc.*) (1 *d*) and (collaterals?) to principal or median nucleus (*Nu. med. n. vestib.*) (1 *e*).

Neurone No. 2.—Axones of some cells in Deiters' nucleus descend (*Tr. desc. nu. Deitersi*) uncrossed to antero-lateral column of the cord, axones of other cells enter the posterior longitudinal fasciculus (*Fasc. long. post.*, 2 *b*) of same side and descend to anterior column of the cord, others pass to the medial longitudinal fasciculus of opposite side whence some (2 *c*) descend to anterior column of the cord, occupying a position near the anterior median fissure, while some (2 *d*) ascend in the medial longitudinal fasciculus and terminate principally in the nuclei of VI, IV, and III nerves. Axones of cells in von Bechterew's nucleus ascend (2 *e*), joining lateral part of medial longitudinal fasciculus of same side, and terminate in nuclei of IV and III nerves. Axones of cells in the nucleus of the descending root probably pass in part to lateral part of reticular formation of same and opposite sides, ascending and descending (to other motor nuclei?). Axones of cells in the median nucleus probably pass largely into the reticular formation, possibly also to the medial longitudinal fasciculus (not indicated). Axones of cells in the nuclei fastigii of the cerebellum pass to von Bechterew's nucleus (2 *f*) and to Deiters' nucleus (2 *g*). The cerebellar associations intercalated between these (2 *f*, 2 *g*) and the vestibular fibres to the cerebellum (1 *c*) are not known. (It is evident that impulses other than vestibular ones entering the cerebellum may also by 2 *f* and 2 *g* act indirectly upon the motor nuclei innervated by axones of the cells in Deiters' and von Bechterew's nuclei. Compare Figs. 331 and 345.)

The nucleus of nerve VII, or *nucleus facialis* is seen occupying a lateral position in the reticular formation similar to that of the nucleus ambiguus. In it may be made out the usual plexus of fine terminals and the coarser root fibres which proceed dorso-mesially to the floor of the ventricle, where they partially envelop the nucleus of the VI (usually not present in this level). They then turn cephalad, forming a compact longitudinal bundle (next section) mesially to the nucleus of the VI, then turn outward passing just cephalad of the nucleus VI, and finally turn ventro-laterally and caudally to emerge on the lateral aspect at the caudal border of the pons. They thus practically loop around the nucleus VI. The bend is known as the *genu facialis*. According to some authorities, some of the fibres cross and pass out in the root of the opposite side.

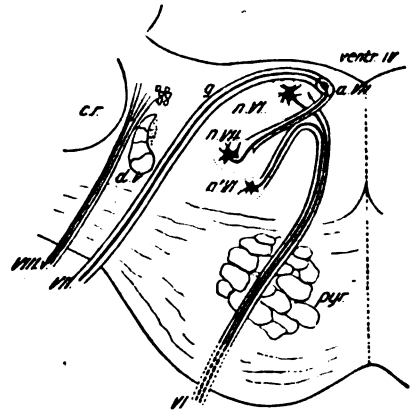

FIG. 362.—Diagram of Origin of Sixth and Seventh Cranial Nerves. (Schäfer). *pyr*, pyramid; *cr*, restiform body; *dV*, spinal root of fifth nerve; *Ventr. IV*, fourth ventricle; *VIII.v*, vestibular root of eighth nerve; *n.VI*, chief nucleus of sixth nerve; *n'VI*, accessory nucleus of sixth nerve; *VI*, sixth nerve; *n.VII*, nucleus of seventh nerve, from which the axones pass dorso-mesially to the floor of the ventricle, where they turn brainward, appearing as a bundle of transversely cut fibres, *aVII*, and ascend to the "genu," *g*, where they turn and pass ventro-laterally and somewhat caudally to the surface as the seventh nerve, *VII*.

Four groups of cells composing the nucleus facialis have been distinguished: three ventral groups which, passing from the most mesial to the most lateral group, innervate respectively the muscles of tympanum, of pinna and of mouth and face. The dorsal group (to superior branch of facial) innervates the frontalis, corrugator supercilii and orbicularis palpebrarum. Among the terminals in the nucleus have been distinguished collaterals (reflex) from the lateral part of the reticular formation, from the secondary acoustic (reflex movements of ears to sound? practically absent in man, and stapedius reflex) and trigeminal tracts (corneal reflex; also other trigemino-facial reflexes?) and other adjacent fibres; also terminals of the colliculo-spinal tract (blinking reflex). Whether the nucleus receives direct terminals from the pyramids or whether fibres of the latter are only connected with it *via* intercalated neurones is uncertain. Directly caudal to the motor nucleus of the VII is a small nucleus similar in character, the *retrofacial nucleus* (Jacobsohn). It perhaps sends fibres to some of the older muscles (stylohyoid, posterior digastric, stapedius?) innervated by the VII.

It is regarded by Winkler as belonging to the portio intermedia. The *nucleus salivarius superior* which furnishes the preganglionic secretory fibres for the submaxillary and sublingual glands (relayed in ganglion sphenopalatinum) cannot usually be distinguished. It occupies a position similar to the inferior salivary nucleus IX but lies more cephalad. The position of the lacrimal nucleus has not been determined. The exact connections of these nuclei with the afferent fibres eliciting salivary and lacrimal (trigemino-facial) reflexes is naturally not well known on account of the obscurity of the secretory nuclei. The same applies to the connection with the thalamo-pallial apparatus (efferent splanchnic path, 27) for the important emotional reaction.

Some of the *root fibres of the VI* are usually seen in the ventral border of the tegmentum. For nucleus see next section.

Afferent Roots, their Terminal Nuclei and Secondary Tracts.—The *afferent vestibular root fibres* enter at the caudal border of the pons and pass lateral to the spinal V, mesial to the ventral cochlear nucleus and restiform body, and enter the field previously occupied by the descending vestibular root, the fibres of which are a continuation of the root. Scattered large cells in this region form the *nucleus of Deiters*. Dorso-mesial to this is still the medial vestibular terminal nucleus, and, dorsal to Deiters', at the external angle of the fourth ventricle, is the *superior vestibular terminal nucleus* (von Bechterew). Fibres seen passing from the vestibular region to the cerebellum and lying near the ventricle are partly vestibular root fibres to the cerebellum (especially to the nucleus tecti, or fastigii, see below) and partly descending fibres from cerebellar nuclei (especially from the nuclei fastigii, forming *fastigio-bulbar* fibres) to Deiters' nucleus, other vestibular nuclei, and other reticular (and spinal cord?) cells. It is thus evident that such nuclei as Deiters' may act as parts of vestibular bulbo-spinal reflex arcs and also as parts of efferent and possibly afferent cerebellar paths. Internal arcuate fibres from the vestibular area are probably principally fibres (secondary tracts) from the various vestibular nuclei to the medial longitudinal fasciculus, and other tracts in the reticular formation (vestibulo-ocular and vestibulo-spinal fibres). (Comp. pp. 517, 544, 548, Figs. 361, 368.)

The *nucleus olivaris superior* lies ventral to the nucleus facialis and lateral to the central tegmental tract. This nucleus together with several other small nuclei in its immediate vicinity (preolivary nucleus, semilunar nucleus, trapezoid nucleus) is one of the nuclei intercalated in the cochlear path (Fig. 338) which also provides reflex connections (*e.g.*, with the VI and VII motor nuclei). Lateral to it is seen a mass of fibres which pass by it toward the median line through the medial lemniscus, and decussate, finally turning longitudinally dorso-lateral to the opposite superior olive. These are fibres of the *trapezius*, and together with the more dorsal secondary cochlear fibres (p. 546) form the *lateral lemniscus* (See Fig. 359 and page 544). The lateral lemniscus is thus one of the links in the cochlear or auditory pathway. Fibres pass from superior olive to nucleus of nerve VI (reflex turning of eyes to sound) and also, together with the above-mentioned trapezius collaterals, to nucleus VII (stapedius reflex) and other nuclei (? movements to loud noise?).

In some cases the slender afferent root of the *portio intermedia* or *nerve of Wrisberg* may be seen entering between the vestibular and main facial roots.

Its fibres proceed to a gray mass or masses which may be regarded as the nucleus gustatorius, receiving taste fibres, and as a continuation of the nucleus ventralis fasciculi solitarii, receiving the proprioceptive fibres, and there probably partly terminate and partly send descending arms to join the fasciculus solitarius. The secondary tracts from these nuclei have not been made out but they should pass in part to the gustatory path and to the medial lemniscus respectively and have connections similar to the corresponding nuclei of IX and X.

The spinal V occupies the same position though separated from the surface by the pontile fibres; internal to it is its terminal nucleus. Note the change in the shape of the lemniscus. The ventral spino-cerebellar and lateral spino-thalamic tracts are in the same position though here separated from the surface by the added pontile fibres.

Other Afferent Cerebellar Neurones.—The inferior olives are not present, and the olivo-cerebellar fibres are here entering the cerebellum as a part of the restiform body. The central tegmental tract (to the olives) occupi es the ventral part of the reticular formation. The restiform body is entering the white matter of the cerebellum. It has been seen to be composed of the dorsal spino-cerebellar tract, olivo-cerebellar fibres and fibres from the lateral and possibly other nuclei in the reticular formation. The dorsal spino-cerebellar tract terminates in the cortex of the vermis or middle lobe of the cerebellum, the olivo-cerebellar fibres terminate in all parts of the cerebellar cortex. The fibres mesial to the restiform body, consisting of ascending vestibular fibres to the cerebellum and descending fibres to vestibular and other nuclei (see cerebellum), are sometimes called the *internal* or *juxta-restiform* body. This and the restiform body proper constitute the *inferior cerebellar peduncle.* The *pons* consists of gray matter—the *pontile nuclei* —and of *transverse* and *longitudinal fibres.* The longitudinal fibres include the pyramids which pass through to the medulla and cord, and other fibres from the pallium (pallio-pontile or cerebro-pontile) which terminate in the pontile nuclei. The axones of the latter form the transverse pontile fibres (ponto-cerebellar fibres) which cross and pass to the cortex of the opposite cerebellar hemisphere. They constitute the *middle cerebellar peduncle* or *brachium pontis.* (Comp. p. 567.)

The pallio-pontile and ponto-cerebellar neurones constitute the pallio-ponto-cerebellar path connecting one cerebral with the opposite cerebellar hemisphere (p. 513, path 19). There are probably also transverse fibres in the pons connecting cerebellum and reticular formation. Fibres passing vertically in the raphé from pons to reticular formation (*perpendicular fibres of pons*) may be in part continuations of these and in part efferent pallial fibres from pes to tegmentum. The latter are fibres innervating directly or indirectly motor cranial nuclei.

Intersegmental Neurones.—The reticular formation is extensive. In it there may be distinguished, besides the nuclei already mentioned, the various more or less well-defined reticular nuclei (see Fig. 360). The fibres of the lateral vestibulo-spinal tract (not distinguishable) are here emerging from Deiters' nucleus. The medial longitudinal fasciculus occupies the same position, but is here well separated from the fillet. Some of the internal arcuate fibres in the dorsal part of the reticular formation may be fibres from Deiters' or other

vestibular nuclei to the medial longitudinal fasciculus. They may be crossed or uncrossed, and may descend in it as already mentioned (pp. 544 and 548, or ascend (see Fig. 361). Other internal arcuate fibres here, as elsewhere, pass from the various terminal nuclei to form secondary tracts. Other transverse fibres are axones of cells of reticular nuclei or collaterals and terminals ending in them.

Efferent Suprasegmental Neurones.—The colliculo-spinal tract lies ventral to the medial longitudinal fasciculus. The pyramids are in the same position, but are partly surrounded by pontile fibres and nuclei. (See also pons, above.)

The Cerebellum (p. 566).—The gray matter consists of the external gray or *cortex*, and *internal nuclei* forming interruptions or relays in paths from the cortex. The white matter consists of the fibres of various afferent and efferent cerebellar paths and possibly association fibres of the cerebellum. The cortex is studied elsewhere. The internal nuclei can usually be distinguished. They are the *nucleus dentatus cerebelli* (*corpus dentatum*), a convoluted mass of gray resembling the inferior olives (and sometimes called the cerebellar olives), and mesial to this the *nucleus globosus*, *nucleus emboliformis* and the *nucleus tecti* or *fastigii*. The nucleus fastigii receives fibres from various parts of the cerebellar cortex and also vestibular root fibres (p. 557). Its axones, in part at least, pass to Deiters' nucleus and other nuclei in the reticular formation (*fastigio-bulbar tract*). This forms a link of the cortico-fastigio-vestibulo-spinal path (p. 517, path 32). The nucleus dentatus, nucleus globosus, and nucleus emboliformis also receive fibres from the cerebellar cortex, principally from the hemispheres. Their axones form the *superior cerebellar peduncle* (*brachium conjunctivum*), cross and pass to the red nucleus, reticular formation, nucleus of nerve III, and thalamus. At the level of the section the superior peduncle is not yet fully formed. This forms links in both the cortico-dentato-rubro-spinal and the cerebello-pallial paths (paths 12, 31 and 32. See also p. 567.)

Note where possible the structure of the *plexus chorioideus* of the fourth ventricle. It consists of a layer of cuboidal epithelial cells next the ventricle which are ectodermic, and an outer mesodermic part consisting of connective tissue and blood-vessels. For the structure of the cerebellar cortex see p. 568 *et seq.*

7. Transverse Section of the Hindbrain through the Roots of Nerves VI (Abducens and VII (Facial) (Figs. 343 and 363)

(For the various paths involved see pp. 507–519.)

At this level the pons and superior peduncle (not shown in Fig. 342) have increased in size, the nucleus dentatus diminished.

The *Abducens*, the nucleus and deep root fibres of which are present, innervates the external rectus muscle of the eyeball. Whether it contains also proprioceptive fibres to this muscle (compare nerve III and mesencephalic nucleus of nerve V) is not certain.

Efferent Peripheral Neurones.—The nucleus facialis is usually not present, but various portions of the root fibres may be present (see preceding section), especially the longitudinal part.

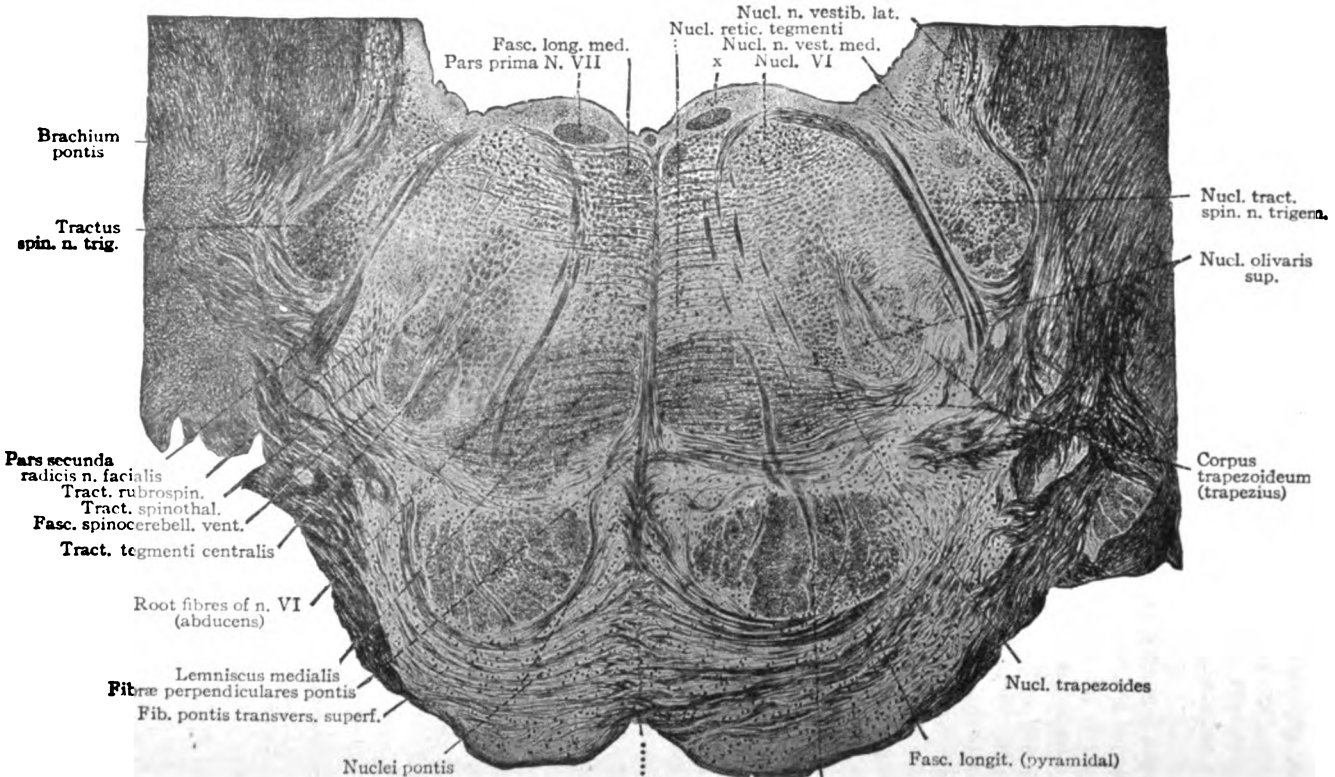

FIG. 363.—Transverse Section of Hindbrain at Level of Nerves VI and VII. Weigert preparation. (Rauber-Kopsch.) x = Nucleus eminentiæ medialis.

The *nucleus of the VI* or *nucleus abducentis* is present in the lateral part of the medial eminence of the floor of the ventricle and just beneath the central gray or partly within it. Its fibres, the *root fibres of the abducens*, are seen passing ventrally. The nucleus receives collaterals from the axones of Deiters' nuclei (vestibular control of lateral eye movements) on the same and opposite sides, collaterals or terminals from the superior olive (tertiary cochlear, turning eyes laterally to sound) and from the medial longitudinal fasciculus (internuclear fibres from III and IV for conjugate movements and other fibres from midbrain for optic-oculomotor reflexes). Small groups of cells in the reticular formation cephalad and lateral to nucleus VI send internuclear fibres *via* the medial longitudinal fasciculus to the nuclei of III and IV (securing conjugate lateral movements of eyes). The exact mode of connection with the pyramidal fibres is not well known (see path 18).

Afferent Roots, Their Terminal Nuclei and Secondary Tracts.—Whether the VI also contains afferent proprioceptive fibres to the external recti muscles of the eye is uncertain (see also p. 559). The lateral (Deiters') and medial vestibular nuclei are usually still present, also possibly fastigio-bulbar fibres. The ventral cochlear nucleus has disappeared, but other cochlear nuclei (superior olivary and trapezoid) are usually present. Often fibres can be seen passing from the superior olive to the nucleus VI.

Fibres of the secondary cochlear tract (corpus trapezoideum) are still traversing the medial lemniscus, and decussating. The tract they are forming (lateral lemniscus) is not yet very distinct.

The spinal V is in the same position, but it and its terminal nucleus tend to separate into groups of fibres and cells, and to change their relative positions. The medial lemniscus is more flattened in cross section, extending transversely instead of dorso-ventrally, being no longer compressed between the two inferior olivary nuclei. The ventral spino-cerebellar tract and lateral spino-thalamic tract are in the same positions in the external part of the tegmentum ventral to the spinal V and external to the superior olive.

Other Afferent Cerebellar Connections.—The restiform body has now merged with the white matter of the cerebellum. The nuclei and transverse fibres of the pons (ponto-cerebellar neurones) have increased. The longitudinal fibres in the pons at this level are principally the pyramids, but some are pallio-pontile fibres which terminate in the nuclei pontis. Perpendicular fibres are present.

Intersegmental Neurones.—The reticular formation is practically unchanged. One of its nuclei (*nucleus reticularis tegmenti*) can be seen as a lighter area (Weigert) in the medial part, dorsal to the medial lemniscus. The rubro-spinal tract is in the same position near or mingled with the spino-thalamic and ventral spino-cerebellar tracts. These fibres are not easily distinguished among the various fibres of the cochlear tract which cross them. The medial longitudinal fasciculus is now a well-marked tract occupying the same position. From now on, it contains ascending fibres from vestibular nuclei and perhaps other reticular nuclei, and internuclear fibres connecting the nuclei of nerves VI, IV and III, besides the descending fibres from the various midbrain nuclei (see p. 548).

Efferent Suprasegmental Neurones.—The pyramids and colliculo-spinal tract (predorsal fasciculus) occupy the same positions. The fastigio-bulbar fibres have been mentioned. The superior cerebellar peduncle is now more distinct as it is being formed by fibres from the dentate nucleus. It lies near the dorso-lateral part of the ventricle.

8. Transverse Section of the Hindbrain Through the Roots of Nerve V (Trigeminus) (Figs. 343 and 364)

(For the various paths involved see pp. 507–519.)

The nerve of this level is the *Trigeminus*. It is afferent and efferent and has a cerebrospinal ganglion, the Gasserian ganglion. The afferent fibres (somatic) are cutaneous and oral (stomodæal) for general superficial sensibility (touch, pain and temperature) and proprioceptive from jaw and part of the tongue. Its efferent fibres (branchio-motor) innervate the jaw musculature. They arise from the *motor nucleus V*. The afferent fibres arise from the *Gasserian ganglion* and possibly also (proprioceptive fibres) from the *mesencephalic nucleus V*. From the terminal nuclei (*principal sensory nucleus* and *nucleus of spinal V*) arise the secondary reflex and sensory trigeminal tracts, the latter terminating in the thalamus. Many of the reflex connections have been mentioned. The secondary sensory tracts are rather obscure but the following are probable: (*a*) Crossed fibres to the lateral spino-thalamic tract, (pain, temperature, contact?) (*b*) Crossed fibres to the medial lemniscus or its vicinity (proprioceptive and tactile discrimination?). The latter are especially numerous at the level of entry of the V roots, arising from the principal sensory nucleus, and sometimes called the pontile lemniscus. (*c*) Crossed and uncrossed fibres to the dorsal part of the reticular formation. Some authorities describe root or secondary fibres to the cerebellum.

Efferent Peripheral Neurones.—*Motor nucleus of V*. This is mesial to the terminal nucleus of the V and its coarse efferent root fibres may be seen, in favorable levels, passing out just internal and somewhat cephalad to the entering afferent fibres. It is possible that some of the fibres cross and pass out in the opposite motor root. Some of the finer terminal fibres present in the nucleus are afferent root fibres of the V (two-neurone arc for reflex proprioceptive control of jaw muscles?) and collaterals of secondary tracts of V (three-neurone arc for reflex control of jaw muscles by superficial stimuli, especially from tongue?). Many collaterals are also received from the mesencephalic root. (Fig. 367.) The connections for the tensor tympani reflex have not been determined. The nucleus also receives pyramidal fibres directly or indirectly (mastication, part of the act of speech and other voluntary movements see path 18) and fibres, probably, exercising cerebellar regulation whose course is not known.

Afferent Roots, their Terminal Nuclei and Secondary Tracts.—The afferent fibres of the V pass through the pons and enter the tegmentum where they divide into short ascending and long descending arms. The former, together with collaterals, terminate in the cephalic end of the terminal nucleus of the V.

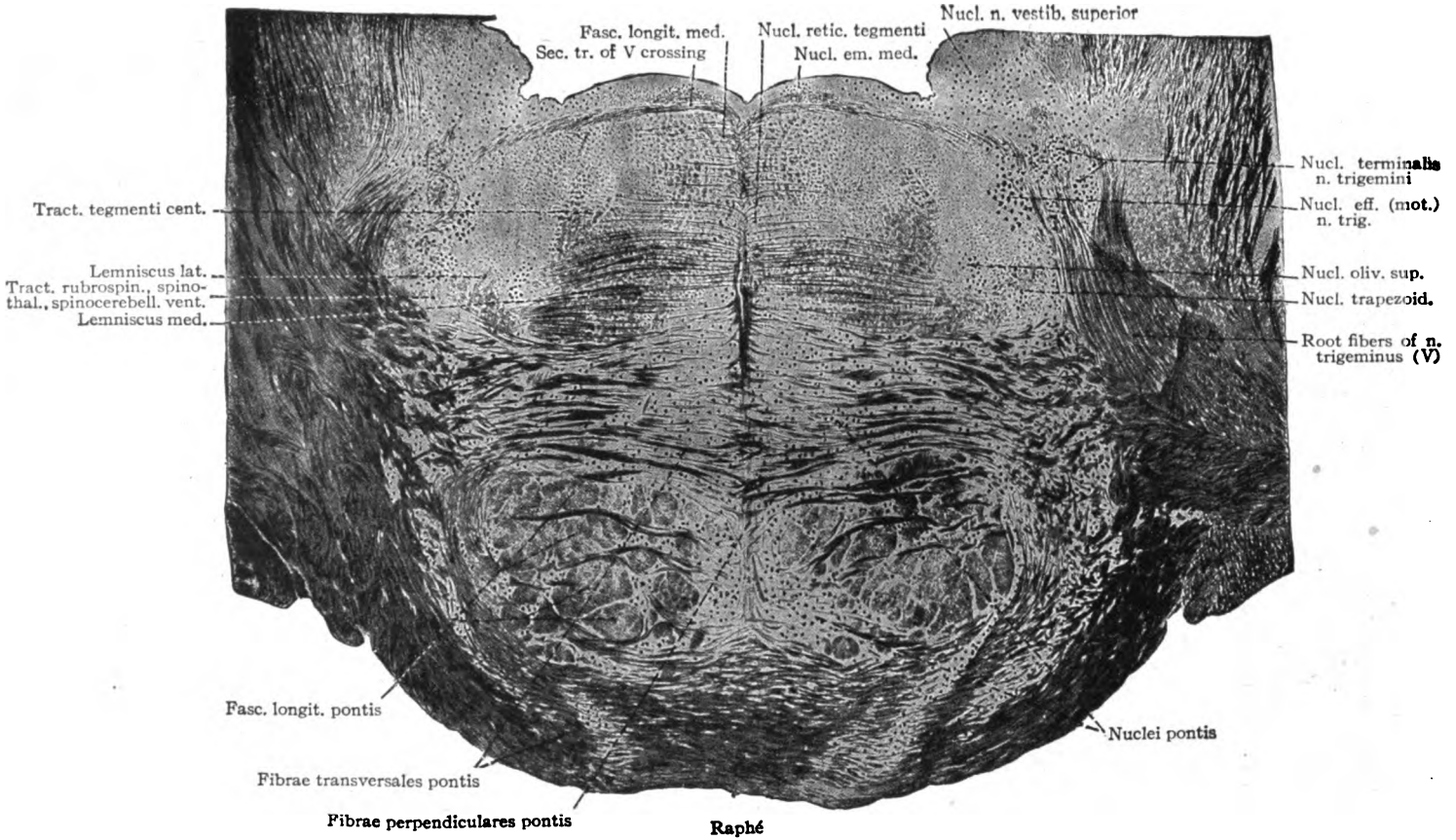

FIG. 364.—Section through Hindbrain at about the Exit of Nerve V. Weigert preparation. (Rauber-Kopsch.)

This is broken up into groups of cells which lie dorso-lateral to the entering fibres and is sometimes known as the "*principal sensory*" *nucleus* of the V. The long descending arms pass down to the cord as the spinal V, giving off collaterals and terminals to the terminal nucleus of the spinal V *en route* (Fig. 367.) A third source of fibres of the V is a series of cells extending upward into the roof of the mesencephalon. The axones of these cells form the *mesencephalic root* of the V. There is reason to suppose, from their peculiar location and for other

FIG. 365.—Transverse Section of the Descending Spinal Root of the Trigeminus (Spinal V) and Its Terminal Nucleus. New-born rabbit. Chrome-silver impregnation of Golgi. (Cajal.) *A*, ventral portion of spinal V; *a*, interstitial cells of the terminal nucleus, their axones are shown entering the adjoining longitudinal fibres or passing inwards through the nucleus to form a part of the secondary trigeminal tracts; *C*, marginal cells of the nucleus whose axones may send collaterals into the nucleus and then pass inward to form a part of the secondary trigeminal tracts; *d* and *e*, clumps of the small, deeply located cells of the nucleus. Their axones give off collaterals terminating in the nucleus; their further course is doubtful; *f*, large, deep, stellate cells whose axones give off collaterals into the nucleus and then form part of the crossed and uncrossed secondary trigeminal tracts; *g*, isolated cell; *h*, marginal cell whose axone passes outward into the white matter. Compare Figs. 366 and 352.

reasons, that these are *afferent* peripheral neurones which have remained within the neural tube in which case, as they pass to the mandibular branch, they would be probably proprioceptive. There is reason to believe, however, that there are also proprioceptive neurones in the Gasserian ganglion. Another view, more recently advocated, is that they are sympathetic neurones (Winkler).

From the region of the terminal nucleus of the V, a transverse bundle passes to the opposite side in the floor of the fourth ventricle. This is probably part of tracts (*b*) and (*c*) mentioned above (p. 562). Fibres of secondary tracts give

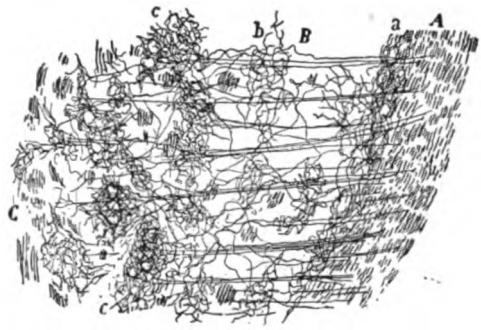

FIG. 366.—Portion of a Transverse Section of the Descending Spinal Root of the Trigeminus (Spinal V) and Its Terminal Nucleus. New-born cat. Chrome-silver impregnation of Golgi (here only fibres are impregnated). (Cajal.) *A*, spinal V; *B*, gelatinous substance of Rolando (part of terminal nucleus of spinal V); *C*, deep descending trigeminal root fibres; *A*, superficial or marginal collaterals (terminating superficially around interstitial and marginal cells, compare Fig. 365); *b* and *c*, clumps of fibres formed by terminations of the deeper or radial collaterals, probably in especial relation with the clumps of small deep cells (compare with Fig. 365).

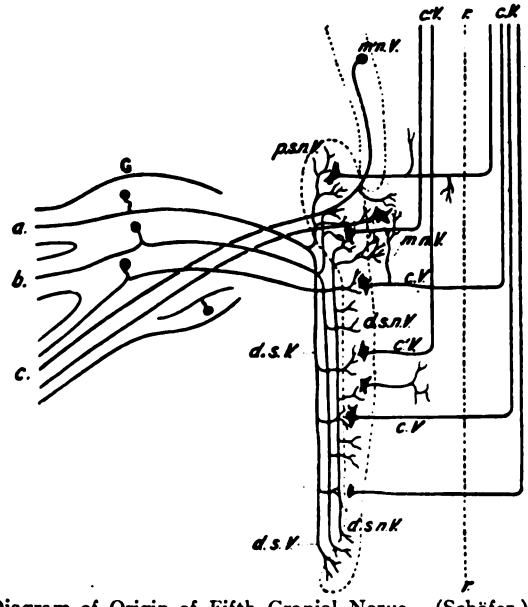

FIG. 367.—Diagram of Origin of Fifth Cranial Nerve. (Schäfer.) *G*, Gasserian ganglion; *a*, *b*, *c*, the three divisions of the nerve; *m.n.V*, principal motor nucleus; *p.s.n.V*, principal terminal "sensory" nucleus; *d.s.n.V*, terminal nucleus of spinal root; *d.s.V*, descending or spinal root; *c.V* and *c'.V*, secondary trigeminal tracts (axones of cells in terminal nuclei); *r*, median raphe'; *m'.n.V*, mesencephalic nucleus.

off collaterals to various efferent nuclei and probably axones of some cells of the terminal nuclei become intersegmental fibres in the reticular formation. These supply the connections for the various reflexes initiated by stimulation of the skin and mucosa of face and mouth and of the bones and tendons of face and jaw such as the jaw reflex (motor nucleus V), the corneal reflex (motor nucleus VII), the lacrimal reflex (lacrimal nucleus VII, undetermined), sneezing (nucleus XII, nucleus ambiguus X and associated respiratory nuclei), sucking (nuclei XII and VII) and possibly palatal (nucleus ambiguus), pharyngeal (nucleus ambiguus) and vomiting (dorsal preganglionic nucleus X, nucleus ambiguus and other nuclei including motor nucleus V) reflexes due to pharyngeal stimulation. The afferent portion of the latter are probably, however, more by way of nerves IX and X. Connections with the dorsal preganglionic vagus nucleus would also provide for the oculo-cardiac reflex. Secondary trigeminal fibers probably also pass to the medial longitudinal fasciculus. The collaterals of secondary trigeminal fibres to nucleus XII probably also provide for reflex tongue movements following stimulation of the tongue and possibly a reflex trigeminal control of tongue movements during the act of eating.

The superior terminal vestibular nucleus (of von Bechterew) may still be present. The superior olivary and trapezoid nuclei may be present. The secondary (and tertiary (?), see Fig. 359) cochlear tract or lateral lemniscus is now well formed and may be seen lying dorso-lateral to the superior olivary and trapezoid nuclei.

The medial lemniscus is still more flattened. The lateral spino-thalamic and ventral spino-cerebellar tracts occupy the same positions.

Other Afferent Cerebellar Neurones.—The transverse pons fibres are the same, but the longitudinal fibres have increased owing to the presence of more pallio-pontile fibres. The perpendicular pontile fibres are seen passing dorsally in the raphé into the tegmentum.

The central tegmental tract is in nearly the same position.

Intersegmental Neurones.—The reticular formation is somewhat diminished. In it is the nucleus reticularis tegmenti. The rubro-spinal tract is in the same position, mingled with the spino-thalamic and ventral spino-cerebellar tracts. The medial longitudinal fasciculus is unchanged.

Efferent Suprasegmental Neurones.—The pyramids now occupy the central part of the pons, and are broken up into a number of bundles. In the dorsal part of the pons fibres pass obliquely dorsally. These are probably efferent pallial fibres which act directly or indirectly on some of the efferent nuclei of cranial nerves (motor path to cranial nerves, see path 18). The pallio-pontile fibres have been mentioned.

The superior peduncle is now a large bundle of fibres flattened against the ventricular surface of the dorso-lateral brain wall.

The colliculo-spinal tract is in the same position.

Cerebellum

The cerebellum, connected with the rest of the brain by its three peduncles, consists of two lateral lobes or hemispheres connected by a

median lobe, the vermis. These are divided into various lobules, the surfaces of which are marked by parallel transverse folds or laminæ. When these are cut across it is seen that they give off secondary or tertiary laminæ, the whole producing the appearance known as the arbor vitæ. The surface of the cerebellum is composed of gray matter, the cortex, enveloping the white matter.

The *afferent* fibres passing to the cerebellar cortex from other parts of the nervous system and terminating there are: (*a*) The fibres of the restiform portion of the inferior peduncle These fibres comprise, as already described, the dorsal spino-cerebellar tracts to the cortex of the vermis, fibres from the nucleus of the lateral columns, the external arcuate nuclei, possibly fibres from the nuclei graciles and cuneati of the same and opposite sides and the crossed olivo-cerebellar fibres, the last to all parts of the cerebellar cortex. All of these, excepting, perhaps, the olivo-cerebellar fibres, are probably to be regarded as carrying proprioceptive impulses from the body. To this group should be added the aberrant ventral spino-cerebellar tract, to the vermis. (*b*) The afferent fibres of the juxtarestiform portion of the inferior peduncle. These are either vestibular root fibres or fibres from vestibular nuclei, and convey vestibular impulses to the cerebellum. (*c*) The middle cerebellar peduncle, composed of crossed ponto-cerebellar fibres. These convey to the cerebellum impulses from the opposite pallial hemisphere.

The *efferent* fibres from the cerebellar cortex are all relayed in the internal nuclei. These are: (*a*) Fibres from many parts of the cerebellar cortex passing to the nuclei fastigii which send fibres to vestibular nuclei and possibly other parts of bulb and cord. The latter are the efferent juxtarestiform fibres of the inferior peduncle and carry cerebellar impulses via the vestibular paths to the muscles especially of the eyes and body. (*b*) Fibres from the cortex of the cerebellar hemispheres passing to the nuclei dentati and probably fibres from the vermis passing to the nuclei globosi and emboliformes, all of which send crossed fibres to the red nuclei, reticular formation, thalamus and probably nucleus of nerve III. These fibres constitute the superior peduncles and convey cerebellar impulses partly to the voluntary muscles of body and head and partly to the pallium.

It is obvious that the inferior (excepting efferent juxtarestiform portion) and middle cerebellar peduncles are afferent to the cerebellum, and that the superior peduncles are efferent from the cerebellum. There are views making exceptions to this, *e.g.* affirming afferent

fibres in the superior peduncle and efferent fibres in the restiform body and middle peduncle but even if present they would constitute a small minority of the fibres. (Fig. 342, p. 522 and Fig. 368.) See also pp. 511 and 516.

In general the lateral lobes represent the newer portion of the cerebellum (neo-cerebellum) with extensive afferent and efferent pallial connections (dentato-rubro-thalamo-pallial and pallio-ponto-cerebellar) and also the connection with the principal olivary nucleus. The vermis, the older portion (palaeo-cerebellum), receives general

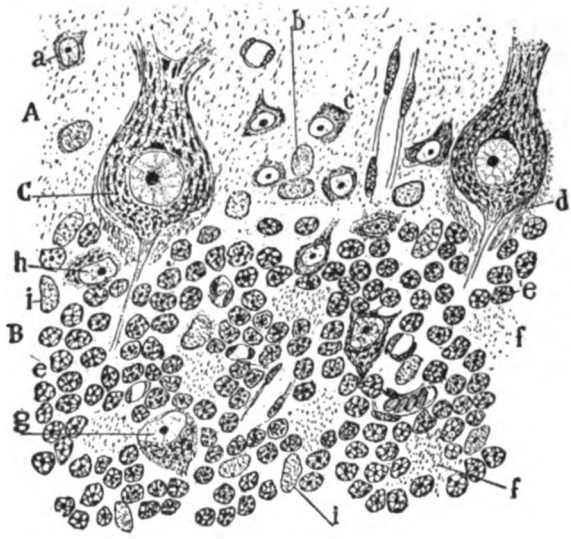

FIG. 369.—Part of a Vertical Section through the Adult Human Cerebellar Cortex. Nissl Method. (Cajal.) *A*, Inner portion of the molecular layer; *B*, granular layer; *C*, body of a Purkinje cell; *a*, stellate cell of the molecular layer; *b*, nuclei of the epithelial-like neuroglia cells (cells of the fibres of Bergmann); *c*, stellate cell with marginal chromophilic substance; *d*, fibrillar mass corresponding to the baskets; *e*, nuclei of the granule cells; *f*, islands or glomeruli in the granular layer; *g*, *h*, Golgi cells in the granular layer; *i*, nuclei of neuroglia cells.

bodily proprioceptive impulses, the special or vestibular proprioceptive impulses and those from the accessory olives. The two main outlets *via* the nucleus ruber and the vestibular nuclei etc. appear to come from both portions of the cerebellum, the former perhaps principally from the hemispheres.

In the **cortex** can be distinguished an outer or ***molecular layer*** with few cells and few medullated fibres, an inner, *granular* or *nuclear layer*, and between the two a single row of large flask-shaped cells, the *cells of Purkinje* (Figs. 369, 370). These latter give off several

main dendrites, which enter the molecular layer and form a remarkably rich arborization extending to the surface. The Golgi method shows the larger and medium branches smooth, but the terminal branches thickly beset with "gemmules." The dendritic arborization is flattened, extending at right angles to the laminæ. The axone is given off from the end opposite to the dendrites and passes through the granular layer into the white matter, either to one of the internal cerebellar nuclei where it terminates, or to some other part of the cortex. The Purkinje cells are almost the only cells the axones of

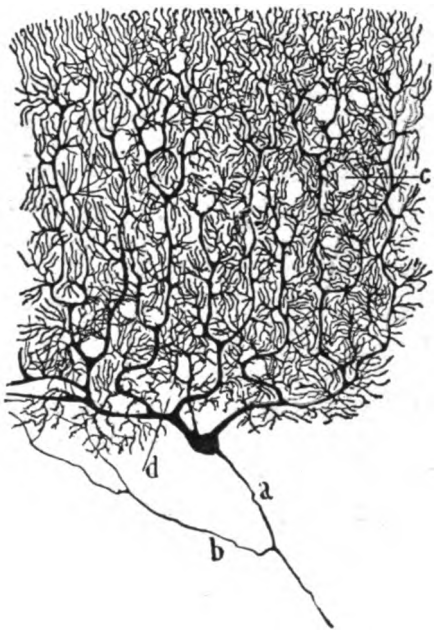

FIG. 370.—Purkinje Cell of Adult Human Cerebellum. Golgi preparation. (Cajal.) *a*, Axone; *b*, recurrent collateral; d, spaces occupied by basket cells; *c*, spaces occupied by blood-vessels.

which enter the white matter. It is evident that all intracortical connections must ultimately converge on these cells to reach the efferent cerebellar paths. The axones of the Purkinje cells give off collaterals not far from their origin, which pass into the molecular layer and appear to terminate there in end "buttons" upon the bodies of adjacent Purkinje cells. The medullated axones form the coarser fibres traversing the granular layer. The cell body is fairly well filled with small chromophilic bodies of uniform size, often showing a slightly concentric arrangement (Fig. 369).

The cells in the molecular layer (stellate cells) are either *superficial stellate cells* with irregular branching dendrites and a short axone, or *deep stellate* (*basket*) *cells*. These latter are cells the axones of which (apparently non-medullated) have a narrow neck and unusual thickening beyond the neck. They extend at right angles to the laminæ for a distance of several Purkinje cells, giving off to each Purkinje cell one or more collaterals which pass toward the granular layer and envelop, with their terminal arborizations, the body and proximal, non-medullated portion of the axone of the Purkinje cell. Collaterals of other basket cell axones may terminate around the same Purkinje cell, forming the "basket" (Fig. 371). The dendrites

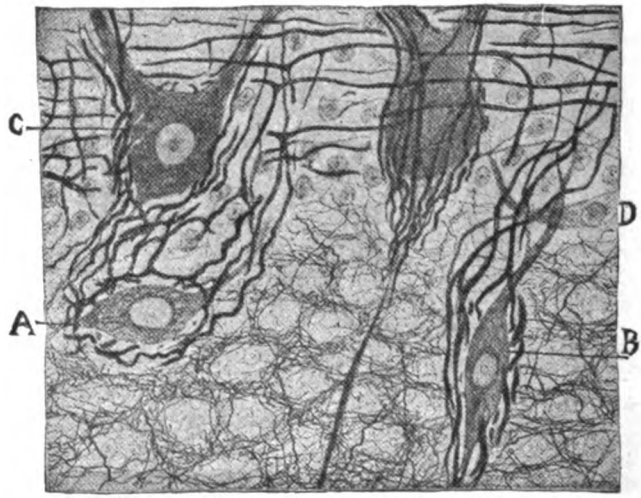

FIG. 371.—Section of Adult Human Cerebellum. Silver Method of Cajal. (Cajal.) *A*, *B*, Cells in the granular layer enveloped by basket fibres; *C*, cell of Purkinje. The axone of one of the cells of Purkinje is shown.

of the basket cells ramify throughout the molecular layer. Besides the cells contained in it, and the dendritic arborizations of the Purkinje cells, the molecular layer contains the axones of the granule cells and the terminations of the climbing fibres (see below). In ordinary stains it presents a general punctate appearance, with only scattered nuclei of the short axone and basket cells ,and the coarser dendrites of the Purkinje cells distinguishable (Fig. 369).

The granular layer with ordinary stains presents the appearance of closely packed nuclei with clear spaces here and there ("*islands*" or "*glomeruli*") and also a few larger cells (Fig. 369). Most of these nuclei belong to the *granule cells*, which are caryochrome cells. The

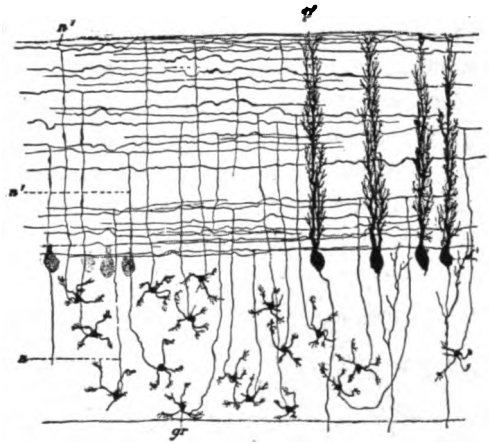

FIG. 372.—Diagram of Longitudinal Section of Cerebellar Lamina. Golgi method. (Kölliker.) *gr*, Cell of the granular layer; *n*, axone of granule cell; *n'*, the same in molecular layer where it branches and runs in long axis of lamina; *p*, Purkinje cell showing how much less extensively its dendrites (*p'*) branch in long axis of lamina. (Compare Fig. 372.)

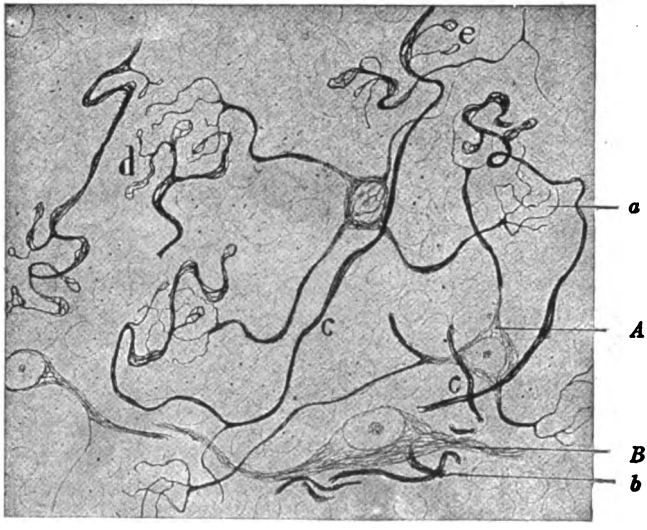

FIG. 373.—Granule Cells and Mossy Fibres in the Cerebellum of Adult Cat. Silver method of Cajal. (Cajal.) *A*, Granule cell; *B*, Golgi cell; *a*, dendritic arborization of granule cell; *b*, mossy fibres passing by Golgi cell; *c*, mossy fibre; *d*, termination of a mossy fibre; *e*, terminal processes given off from a thickening in a mossy fibre.

granule cells are small and possess three to six dendrites which are comparatively short and terminate in the glomeruli with a compact arborization, each branch of which ends in a small varicosity. The axones of the granule cells, which are non-medullated, ascend into the molecular layer where each divides into two branches running longitudinally along the laminæ and terminating in varicosities (Figs. 372, 374). These are the *parallel fibres* of the molecular layer. They

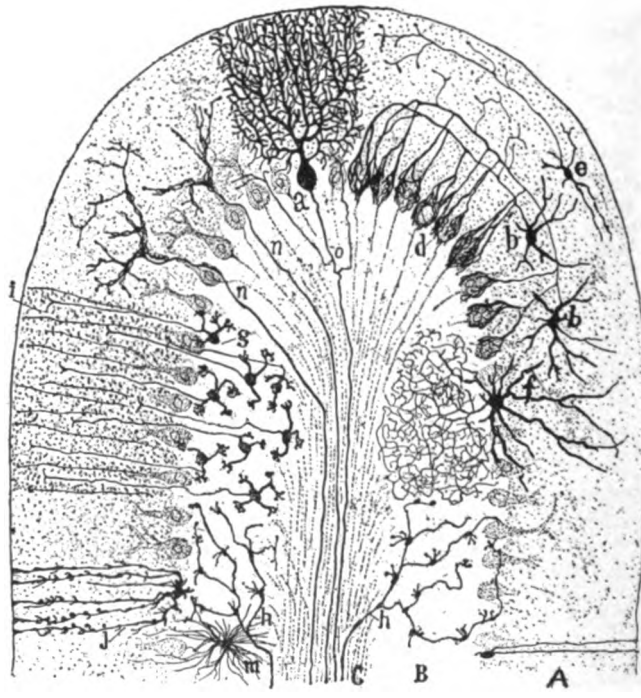

FIG. 374.—Semi-diagrammatic transverse Section of a Cerebellar Lamina of a Mammal, as shown by the Golgi Method. (Cajal.) *A*, Molecular layer; *B*, granular layer; *C*, white matter; *a*, Purkinje cell, seen flat; *b*, basket cells of the molecular layer; *d*, their terminal arborizations which envelop the bodies of the Purkinje cells; *e*, superficial stellate cells; *f*, Golgi cell; *g*, granule cells with their axis-cylinders ascending and bifurcating at *i*; *h*, mossy fibres; *j*, neuroglia cell; *m*, neuroglia cell in granular layer; *n*, climbing fibres.

thus run at right angles to and through the dendritic expansions of the Purkinje cells and their cross sections together with the terminal dendritic arborizations of the Purkinje cells give the molecular layer its punctate appearance. The scattered larger cells in the granular layer are principally *short axone* or *Golgi cells*, whose main dendrites usually penetrate and branch within the molecular layer. Their axones often form very extensive and complicated arborizations in

the granular layer, the terminations of which are concentrated in the glomeruli (Fig. 374, *f*). Dislocated cells of this type may have their cell bodies in the molecular layer. They are also sometimes called the *cells of van Gehuchten*.

In the cortex there are also the terminations of the afferent cerebellar fibres already mentioned (p. 567). These are of two types, *mossy fibres* and *climbing fibres*. The mossy fibres, so called from the appearance of their terminations in embryos, are the coarsest fibres of the white matter. While in the latter they bifurcate,

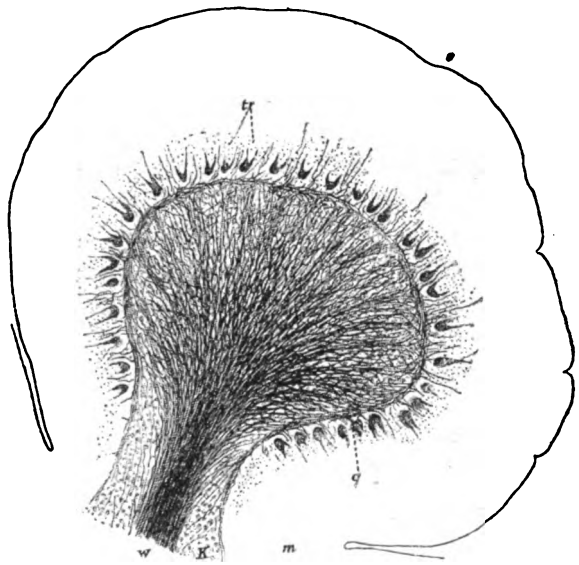

FIG. 375.—Cross Section of a Cerebellar Convolution Stained by Weigert's Method. (Kölliker.) *m*, Molecular layer; *K*, granular layer; *w*, white matter; *q*, fine fibres passing from white matter into the molecular layer; *tr*, dots represent longitudinal fibres of molecular layer among bodies of Purkinje cells.

branches going to different laminæ. These main branches give off secondary branches which enter the granular layer and there arborize. During their course, and also at their terminations, these branches are thickened in places and there give off short, thick, terminal branches which end in varicosities. These terminal branches are located within the glomeruli. The glomeruli thus contain the dendritic terminations of the granule cells, the axonal terminations of the Golgi cells, and the terminations of the mossy fibres. (Figs. 374 and 373.)

The climbing fibres pass from the white matter, through the granular layer to the cells of Purkinje. Passing by the bodies of the

latter they arborize into terminals which envelop the smooth dendritic branches of the Purkinje cells; *i.e.*, all but the terminal dendritic arborizations. (Fig. 374, *n*). Three kinds of fibres thus terminate around the Purkinje cells; the granule axones, probably in contact with its terminal dendritic arborizations; the climbing fibres around its coarser dendritic branches; and the basket fibres around its body. The respective sources of the mossy and climbing fibres are unknown. There is some evidence that the climbing fibres are from the pons.

It is evident from the above that all of the cells of the cerebellar cortex except the Purkinje cells are *association cells* of the cortex.

The medullated fibres of the cerebellum (Fig. 375) pass from the white matter into the granular layer and ramify throughout the latter, forming quite a dense plexus separating groups of granule cells. Sometimes straight fibres can be seen passing through toward the molecular layer which are probably either the climbing fibres or axones of the Purkinje cells. Beneath and between the bodies of the Purkinje cells is a plexus of fibres extending into the deeper part of the molecular layer, the remainder of this layer containing few or no medullated fibres. These fibres in the vicinity of the Purkinje cells are probably principally formed by the recurrent collaterals of the Purkinje cells already mentioned. The remaining fibres of the granular plexus would apparently consist of the arborizations of mossy fibres and of the Golgi cells. Whether the former are medullated is, however, somewhat uncertain.

Most of the neuroglia cells in the cerebellum are of the same general type as seen elsewhere, but in the Purkinje cell layer are apparently epithelial-like cells which send vertical processes to the periphery. Some of these processes, as seen in the Golgi methods are rough and branched, others are smooth. In ordinary stain, these processes are sometimes visible and are known as the *fibres of Bergmann.* (Figs. 369, 374.)

Isthmus

PRACTICAL STUDY

9. **Transverse Section of the Isthmus at the Exit of Nerve IV (Trochlearis)** (Figs. 343 and 376)

(For the various paths involved see pp. 507–519.)

In this there are to be distinguished three parts, the thin *roof* (superior medullary velum), the *tegmentum* and, ventral to the latter, the *pons*. The tegmentum

consists essentially of the reticular formation, efferent cerebellar and midbrain connections, and externally the afferent pallial connections. The pons contains the efferent pallial paths to the cerebellum and to parts of the nervous system caudal to it. The cavity is the *iter* or *aquæductus Sylvii*. Next to this is the *central gray* of the brain wall.

Efferent Peripheral Neurones.—*The root fibres of nerve IV* are seen in the roof. They originate from nuclei lying further forward in the ventral part of the central gray. The fibres pass from the nuclei dorsally and caudally in the outer part of the central gray and finally decussate in the roof and emerge. It is only the latter part of this course which is seen in this level.

Afferent Roots, their Terminal Nuclei and Secondary Tracts.—The mesencephalic root of the V lies in the lateral part of the central gray. Mingled with its fibres may be seen the rounded cells, the axones of which form these fibres. The *locus cæruleus*, a group of cells lying near the mesencephalic root, is not improbably a trigeminal connection. Its exact nature is not certain.

The lateral lemniscus occupies part of the lateral swelling on the surface of the tegmentum, forming the major part of the external structure known as the trigonum lemnisci. Groups of cells among its fibres constitute the *nucleus of the lateral lemniscus*. The medial lemniscus is now still more flattened. The lateral spino-thalamic tract is in about the same position, between the two lemnisci. Thus at this level, the principal afferent suprasegmental paths form an L-shaped mass, enveloping the rest of the tegmentum and representing general body sensation and hearing. There are also cranial nerve ascending paths lying probably within the reticular formation and fillet (secondary vago-glossopharyngeal and trigeminal tracts, representing visceral, taste, and general head sensation). These cannot be distinguished in the section.

The ventral spino-cerebellar tract is on the surface, and now comes to lie external to the superior cerebellar peduncle. At about this point it turns caudally, and passes back into the cerebellum, accompanying the superior peduncle.

Other Afferent Cerebellar Connections.—The central tegmental tract occupies the same position. (For the pallio-cerebellar connection see "Efferent Suprasegmental Neurones" below.)

Intersegmental Neurones.—The reticular formation is dimished in extent. One of its nuclei, the *nucleus centralis superior*, lies near the raphé. The rubrospinal tract has moved somewhat mesially. It is dorsal to the medial lemniscus. The medial longitudinal fasciculus is in the same position, and is a well-marked bundle lying at the boundary between the ventral part of the central gray and the reticular formation.

Efferent Suprasegmental Neurones.—The pyramids are now broken up into bundles which may show a tendency to gather in the ventral part of the pons (distinguishable in one-month infant, where they are medullated while the pallio-pontile system is not). Bundles apparently forming lateral and mesial portions of the medial lemniscus and imbedded in it (not indicated in the figure) are aberrant efferent pallial fibres (pes-lemniscus fibres, see path 18). In the one month infant they can be distinguished in Weigert myelin preparations by their lighter stain, when present.

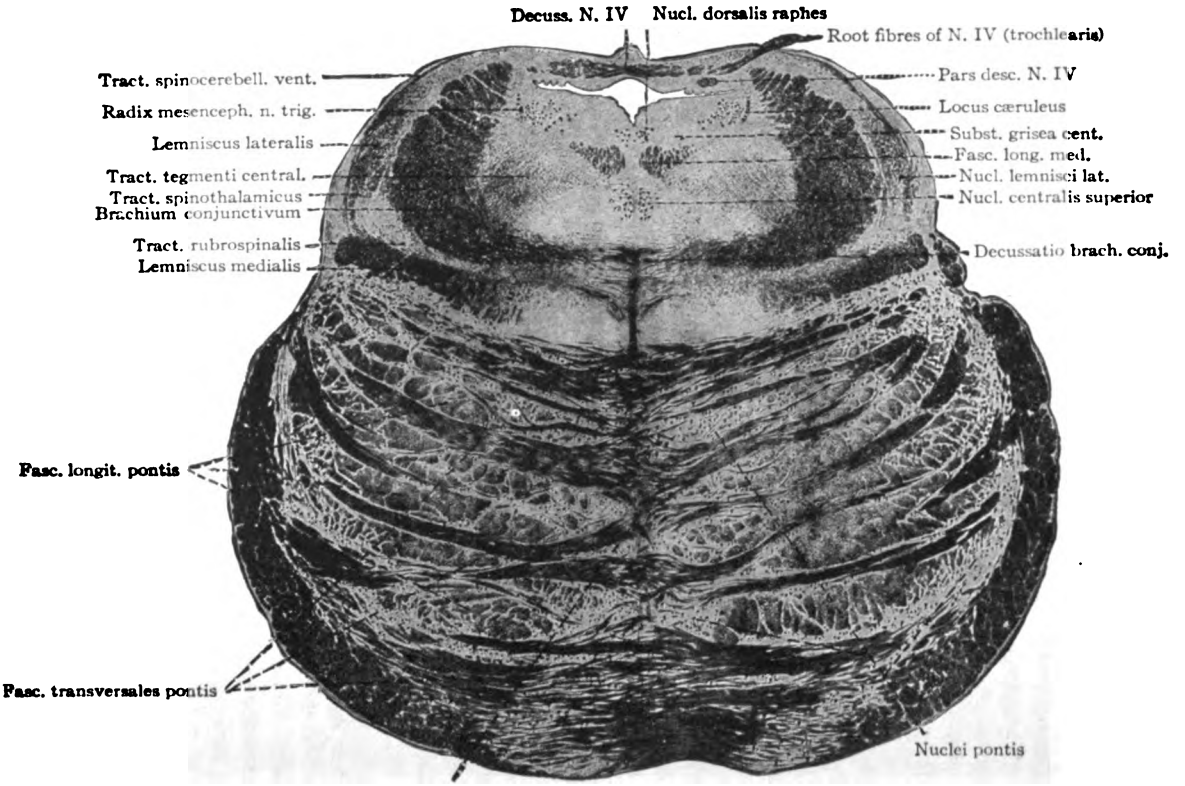

FIG. 376.—Transverse Section through the Isthmus at the Exit of Nerve IV. Weigert preparation. (Rauber-Kopsch.)

The pallio-pontile fibres are still more numerous. The gray matter in the pons (nuclei pontis) is very extensive. The transverse fibres of the pons no longer pass at this level into the cerebellum, but are collected at the sides of the pons to pass backward to the cerebellum (compare with an external view of the brain).

The superior cerebellar peduncles or brachia conjunctiva are two large crescentric bundles of fibres in the lateral part of the reticular formation. Some of their fibres have begun to decussate in the ventral part of the reticular formation.

The colliculo-spinal tract or predorsal fasciculus lies ventro-lateral to the medial longitudinal fasciculus.

Midbrain or Mesencephalon

The dorsal surface of the midbrain presents four rounded prominences, the two inferior and two superior colliculi (posterior and anterior corpora quadrigemina). Ventrally are seen two diverging masses of longitudinal fibres, the pes pedunculi, separated by a deep groove or sulcus. In the midbrain are to be distinguished, (*a*) the expanded roof, the *colliculi* or *corpora quadrigemina*, (*b*) the *tegmentum* containing the segmental (cranial nerves IV and III) and intersegmental apparatus and the afferent suprasegmental paths, and (*c*) the *basis pedunculi*, ventral to the tegmentum and comprising the principal efferent pallial paths (*pes pedunculi*) and the *substantia nigra*.

The cavity of the midbrain is the *aqueductus Sylvii* or *iter*.

The principal segmental or intrinsic mechanisms of the midbrain are those of the various eye reflexes and eye movements. Besides this the midbrain contains various paths to and from cerebellum, pallium, striatum and other forebrain structures, including certain masses of gray forming their relay stations, the most conspicuous of which is the nucleus ruber.

PRACTICAL STUDY

10. Transverse Section of Midbrain at Level of Inferior Colliculi (Posterior Corpora Quadrigemina) (Figs. 343 and 377)

(For the various parts involved see pp. 507–519.)

Compared with the preceding section, the following are the most conspicuous changes: The roof has enlarged into the *inferior colliculi*, a great part of the tegmentum is occupied by the decussating fibres of the superior cerebellar peduncle (*decussatio brachii conjunctivi*), the pons is still present but the section shows the transition to the pes pedunculi, a great mass of longitudinal, pallio-pontile fibres being added to the pyramidal fibres. The cavity of the midbrain is the *aquæductus Sylvii* (or *cerebri*) or *iter*.

The *Trochlearis*, the nucleus of which is present at this level, is efferent to the superior oblique muscle of the eyeball. Whether the nerve also contains afferent proprioceptive fibres to this muscle is not known.

Efferent Peripheral Neurones.—The *nucleus of nerve IV* or *trochlear nucleus* is located in the ventral part of the central gray, partly indenting the dorsal aspect of the medial longitudinal fasciculus. It is practically a caudal appendage of the nucleus of nerve III (next section). The root fibres may be seen in some sections emerging from the nucleus whence they curve around dorsally in the outer part of the central gray, following its contour, at the same time trending caudally until they reach the superior medullary velum (preceding section) in which they decussate and then make their exit. For further details concerning its connections, see nerve III.

Afferent Roots, their Terminal Nuclei and Secondary Tracts.—The mesencephalic root of nerve V and locus caeruleus are in the same positions as in the preceding section.

The fibres of the lateral lemniscus are apparently either entering or enveloping the nucleus colliculi inferioris which forms, in part at least, their termination (see below). The lateral spino-thalamic and spino-collicular or -tectal tracts and the medial lemniscus are in their previous positions.

Afferent Cerebellar Connections.—The central tegmental tract occupies the same position but can hardly be distinguished among the decussating fibres of the superior cerebellar peduncle.

Intersegmental Neurones.—Two new nuclei present at about this level are the *ganglion interpedunculare* lying near the median ventral surface of the tegmentum, between the peduncles, and the *nucleus dorsalis tegmenti* lying in the ventral part of the central gray just caudally and dorsally to the nucleus of nerve IV. The former receives habenulo-interpeduncular fibres (fasciculus retroflexus of Meynert, see higher levels) from the nucleus habenulæ and sends fibres to the latter. The latter, besides receiving the interpeduncular fibres, also receives fibres, probably, from the mammillary body, and participates in the formation of the tract in the central gray known as the dorsal longitudinal of Schütz. It possibly also sends fibres into the medial longitudinal fasciculus. These nuclei are thus apparently parts of descending paths (reflex?) from olfactory centers (see path 27).

The rubro-spinal tract, not easily distinguished, has moved further mesially and now occupies a position near the medial part of the medial lemniscus. The medial longitudinal fasciculus occupies its previous position.

Efferent Suprasegmental Neurones.—The pyramids and a large mass of pallio-pontile fibres are now gathered together to form the *pes pedunculi* (see next section). There are still some transverse pontile fibres present. The pontile nuclei are much diminished or even absent according to the level. In some preparations (not constant) may be seen the *superficial* or *medial pes-lemniscus bundle* lying medial to the medial lemniscus. It is one of the aberrant cortico-nuclear, pyramidal bundles (see path 18*b*).

The decussating fibres of the superior cerebellar peduncles, or brachia conjunctiva, occupy a large part of the reticular formation.

The colliculo-spinal or predorsal bundle occupies its previous position.

The Posterior Corpora Quadrigemina or Inferior Colli culi.—(Fig. 377). This consists of a large oval mass on each side, the *nucleus colliculi inferioris* and a thin *cortex* on the surface external and mesial to the nucleus. Golgi preparations appear to show that many of the fibres of the medial lemniscus

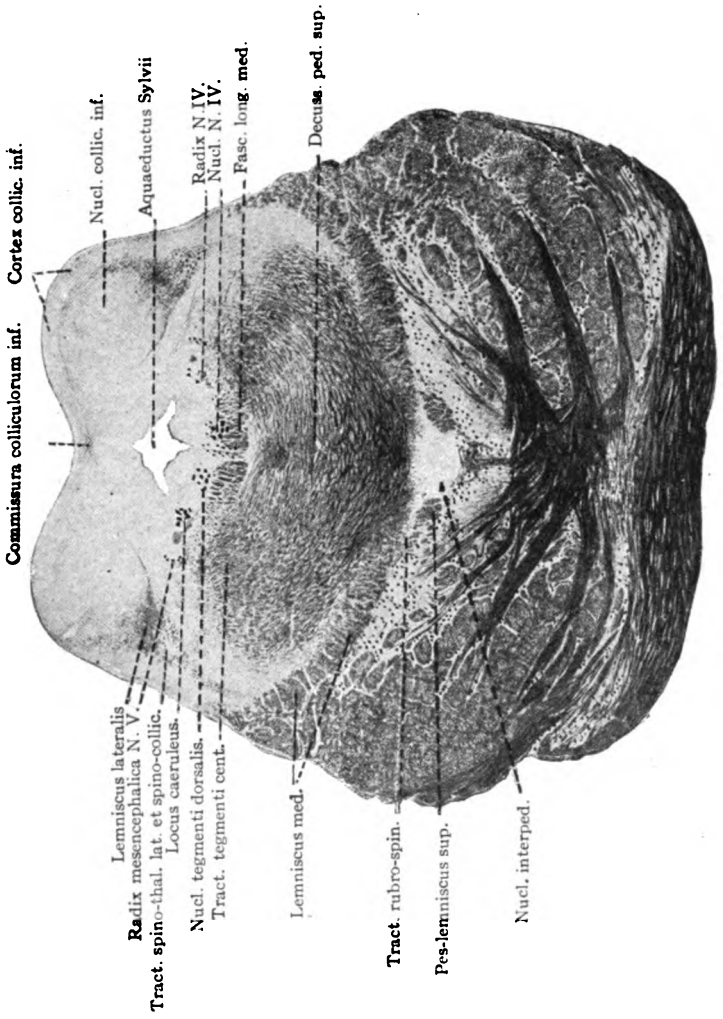

FIG. 377.—Transverse Section of Midbrain at Level of Inferior Colliculus. Weigert preparation. (Raubet-Kopsch.)

send collaterals to the nucleus and also some terminals to it and the cortex, the main fibres passing by (brachium of inferior colliculus) to terminate in the medial geniculate body (see below). Degeneration experiments indicate that most of the fibres of the brachium originate from the cells of the colliculus. Besides sending fibres *via* brachium to the medial geniculate body, the cells of the inferior

colliculus also send fibres passing to the tegmentum and probably forming descending collicular tracts similar to those from the superior colliculus. These probably are reflex and the inferior colliculus is thus both a relay in the path of hearing (path 9) and a reflex acoustic center. The possibility of vestibular tracts forming a small part of this path has been mentioned. In the section, the fibres of the lateral lemniscus can be seen entering into relation with the colliculus. At higher levels the fibres of its brachium can be seen lying on its lateral aspect. A *commissure of the inferior colliculi*, formed largely by axones or collaterals of axones of collicular cells unites the two colliculi.

The inferior colliculi are largely newer parts of the brain due to the advent of the cochlear apparatus and the projection of its stimuli upon the neopallial cortex.

11. Transverse Section of Midbrain at Level of Superior Colliculi (Anterior Corpora Quadrigemina) and Exit of Nerve III (Oculomotor)

(Figs. 343 and 378)

(For the various paths involved, see pp. 507–519.)

Compared with the preceding section, the following are the most conspicuous changes: The roof now forms the *superior colliculi;* the tegmentum now contains the *nuclei* and *roots of nerve III* and the *red nucleus;* instead of the pons, the ventral part of the brain is now composed of the *basis peducnuli*, consisting of a mass of efferent pallial fibres and the *substantua nigra*. The term *crura cerebri* or *cerebral peduncles* is loosely used to include all except the roof of the brain at this level, *i.e.*, tegmentum and basis pedunculi.

The nerve of this level, the *Oculomotorius*, is probably both afferent and efferent, the latter portion being both somatic and splanchnic. The afferent portion appears to consist of proprioceptive fibres to the external eye muscles the source of which is unknown but which, inasmuch as the nerve has no ganglion of the cerebro-spinal type, must be central. The somatic efferent portion is composed of the fibres to those voluntary striated external muscles of the eyeball innervated by nerve III and also to the levator palpebræ. The splanchnic efferent portion is composed of preganglionic fibres to the ciliary (sympathetic) ganglion whose postganglionic fibres (ciliary nerves) innervate smooth, internal muscles (ciliary and sphincter iridis) of the eyeball. The nerve thus controls the vertical and converging movements of the eyeballs, participates in the lateral movements, contracts the pupil and alters the convexity of the lens (accommodation of lens). (Fig. 379).

Efferent Peripheral Neurones.—The *nucleus of nerve III* or *oculomotor nucleus* is located in the ventral part of the central gray in a V-shaped trough formed by the fibres of the medial longitudinal fasciculus. The nucleus is divided into large and small-celled groups. The large-celled groups are two lateral groups subdivided into anterior and posterior dorso-lateral and anterior and posterior ventro-mesial, and a central or median group—nine in all. Between the cephalic or anterior groups are on each side a small-celled group known as the Edinger-Westphal nucleus, and still further forward are two small-celled anterior

median nuclei. The connections of these groups with the extrinsic muscles of the eye innervated by nerve III (internal, superior and inferior recti, and inferior oblique) and the levator palpebræ superioris and intrinsic eye muscles (ciliary and sphincter pupillæ, *via* ciliary sympathetic ganglion) are uncertain. From *a priori* grounds, the innervation of the intrinsic muscles by the small-celled groups and the other muscles by the large-celled groups would seem probable. Some of the fibres, usually stated to be from the posterior dorso-lateral group, decussate. Recent observations (Cajal) would indicate that the decussating fibres come from the ventro-mesial lateral groups. What is perhaps the prevailing view as to these relations is shown in Fig. 379. The various fibres pass ventrally in a number of bundles, some passing mesial to, some traversing, and some passing lateral to the superior cerebellar peduncle and red nucleus. Ventral to these the root fibres come together and emerge on the ventral aspect of the midbrain (Figs. 378 and 381).

The nucleus of nerve III receives terminals and collaterals from the medial longitudinal fasciculus (ascending axones from vestibular nuclei and from internuclear neurones whose bodies lie near nucleus VI and descending axones from the nucleus of the medial longitudinal fasciculus), possibly collaterals from the colliculo-spinal tract, collaterals or terminals from the superior cerebellar peduncle and from the reticular formation. The vestibular fibres correlate, reflexly, the positions of the eyes with the positions of the head (compensatory eye movements), the internuclear fibres associate nuclei VI and III in performing the lateral eye movements, the fibres from the colliculi, etc., put the eye movements under the control of the collicular reflex center and thereby, indirectly, under one of the pallial eye-movement centers (see paths 29, 30 and 22). The Edinger-Westphal nucleus receives collaterals from the curved fibres of the superior colliculus which terminate in the central gray. *A priori* these should be pupillary reflex fibres but this is not proven. The nucleus receives pallial (voluntary) stimuli *via* the pes-lemniscus bundles (see path 18) but whether directly or through the intermediation of reticular intrasegmental neurones is uncertain.

Immediately caudal to the nucleus of nerve III is the nucleus of nerve IV occupying a position similar to the lateral groups of the nerve III nucleus. The course of the root fibres of IV has been mentioned (preceding section). It receives terminals similar to those received by III.

Afferent Roots, their Terminal Nuclei and Secondary Tracts.—The mesencephalic trigeminal root is sometimes distinguishable on the lateral border of the central gray.

The lateral lemniscus has partly or wholly terminated in the inferior colliculus at a lower level. Fibres from the latter and possibly lateral lemniscus fibres (see preceding section) form its arm or brachium, representing another link of the cochlear path. In the present section the fibres of the *brachium of the inferior colliculus* are seen entering the *medial geniculate body* (which is a part of the thalamus). Axones of the cells of this body constitute the last relay of the cochlear path (path 9, p. 510) to the temporal cortex cerebri (not present in this section). (See also p. 594).

The medial lemniscus is now a laterally placed, curved bundle, displaced

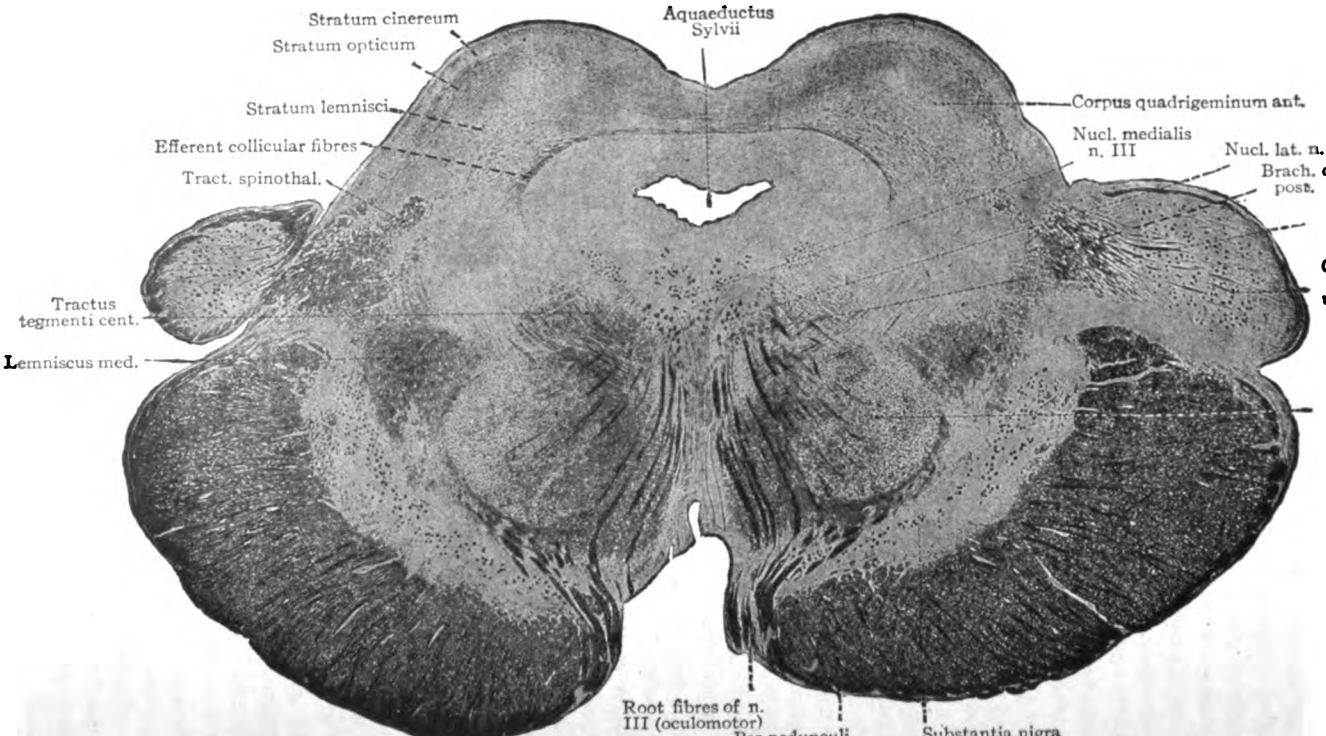

Fig. 378.—Transverse Section through Midbrain at Level of Superior Colliculus and Exit of Nerve III. Weigert preparation. (Rauber-Kopsch.)

laterally by the red nucleus. According to some authorities, some of its fibres terminate in the superior colliculus. The lateral spino-thalamic tract is plainly distinguishable as a bundle dorsal to the dorsal edge of the medial lemniscus. At this level, then, the afferent paths from cord to pallium are in close contiguity.

In the superior colliculus are terminations of the *optic tract* (the continuation past the optic chiasma of the so-called *optic nerve*) (see below).

The central tegmental tract is displaced dorsally by the red nucleus.

Intersegmental Neurones.—The reticular formation is smaller. The rubro-spinal tract (not distinguishable) is emerging from its nucleus of origin, the nucleus ruber. Just below this level its fibres decussate (*ventral decussation of Forel*) and pass to the location they have been seen to occupy in preceding levels. The *nucleus ruber* or *red nucleus* is very conspicuous, occupying a large part of the reticular formation. It consists of a large-celled part which gives rise to the rubro-spinal tract and to rubro-bulbar fibres, and a smaller-celled portion. The latter sends fibres to the thalamus and thence to the pallium. The nucleus ruber, probably the first named part, also receives fibres from the corpus striatum and probably from the pallium. According to this it will be seen that the nucleus ruber is a part of the descending cerebello-rubro-bulbar and spinal path (path 31, p. 516), of the cerebello-pallial path (path 12, p. 511), of the strio-rubro-spinal path (path 21), and of the pallio-rubro-bulbar and spinal path (path 20, p. 514). The red nucleus probably also receives collaterals from the colliculo-spinal tract, possibly even from the medial lemniscus.

The medial longitudinal fasciculus is diminished, some of its descending fibres having been formed from reticular formation nuclei below this level. Many of its fibres, both ascending and descending, send collaterals and terminals to the cells of the oculomotor nucleus. The function of the internuclear fibres of the medial longitudinal fasciculus connecting nuclei of nerves III, IV and VI in enabling the conjugate lateral movements of the eyes has been mentioned. The mechanisms of the vertical and converging movements are obscure.

Efferent Suprasegmental Neurones.—The ventral part of the brain is composed of a mass of efferent pallial fibres, the *pes pedunculi*. The pyramidal fibres from the precentral area of the cerebral hemisphere (pallio-spinal and some pallio-bulbar fibres) occupy about the middle three-fifths, but may be scattered through other parts of the pes, especially the mesial part. The leg fibres are probably more numerous laterally, the arm fibres in the middle, and the face fibres mesially. In the lateral part of the pes are pallio-pontile fibres from the temporal and possibly parietal and occipital lobes of the cerebral hemispheres (occipito-temporal pallio-pontile fibres). In the mesial part are efferent pallial fibres from the frontal lobe to the pons nuclei (frontal pallio-pontile) and also, possibly, from the lower frontal region to the motor nuclei of cranial nerves VII and XII. Besides the above pallio-pontile and pallio-spinal fibres in the pes (see path 19) there are the aberrant medial and lateral pes-lemniscus bundles which contain efferent pallial fibres which act, probably indirectly through intercalated neurones, upon the motor nuclei of nerves III, IV, VI and XI. These bundles detach themselves from the pes higher up, and below this level come to lie in the vicinity or mingled with the medial lemniscus (see path 18).

Dorsal to the pes and constituting the remainder of the basis pedunculi is a mass of gray matter which, on account of the pigmentation of its cells, is known as the *substantia nigra*. The substantia nigra receives collaterals from the adjoining pes fibres. These are probably fibres from the motor cortex but according to some may be from the corpus striatum or corpus subthalamicum. The axones of the cells of the substantia nigra enter the tegmentum. Their destination is unknown.

The superior cerebellar peduncle has completed its decussation below this level and its fibers are seen surrounding or within the nucleus ruber which is one of their terminal nuclei. Other fibres of the superior cerebellar peduncle terminate in the thalamus and some are stated to terminate in the nucleus of nerve III.

Internal arcuate fibres from the gray matter of the superior colliculus pass through the reticular formation, and form an oblique decussation. This decussation is the *dorsal*, or *fountain-like decussation of Meynert*. The fibres originate from cells in the superior colliculus (tectum opticum), and after decussation form the descending *colliculo-bulbar* and *spinal-tract* (tecto-spinal or predorsal tract) (see also below). Other fibres from the superior colliculus, uncrossed, probably enter the medial longitudinal fasciculus.

The Anterior Corpus Quadrigeminum or Superior Colliculus.—In this four principal alternating layers of white (medullary) and gray layers may be distinguished besides the usual covering of neuroglia cells and fibres: (1) An outer white layer, *stratum zonale*. This consists of fine nerve fibres coming from the superior brachium, probably fibres from the occipital cerebral cortex. Among them are small nerve cells, mostly horizontal and with tangential or centrally directed axones. (2) A gray layer, the *stratum cinereum* or *stratum griseum superficiale*. This consists of radially arranged nerve cells with their larger dendrites proceeding outward, and their axones inward. The largest cells lie deepest. In this layer the above zonal fibres and optic fibres terminate. (3) The *stratum opticum* or *stratum medullare superficiale* consists of optic fibres which send their terminals mostly into the preceding layer, but also into the deeper layers, and fibres from the cerebral cortex (pallio-collicular fibres, path 22), which terminate in the deeper layers. It also contains cells whose axones pass into the next layer. (4) *Deep gray-white layer*, or *stratum lemnisci* (subdivided into (*a*) stratum griseum mediale, (*b*) stratum medullare mediale, (*c*) stratum griseum profundum and (*d*) stratum medullare profundum). This layer receives the spino-collicular fibres. It contains large and medium stellate cells whose axones, together with axones from cells in the more superficial layers, either pass across to the opposite colliculus (commissura colliculi superioris), pass into the lateral part of the reticular layer (colliculo-reticular fibres) in the middle white layer (4*b*) or pass radially to the deep white layer (4*d*) and sweep ventrally around the central gray, decussate in the raphé (dorsal tegmental decussation of Meynert) and proceed caudally as the colliculo-bulbar and (spinal?) tract (predorsal bundle). The cells of this layer may also send fibres to the cerebral cortex. The superior colliculus also possibly receives fibres from the lateral lemniscus.

Belonging to the midbrain is the posterior commissure (not in the section) the fibres of which cross in the roof just anterior to the superior colliculus. Its

fibres originate from collicular cells (in turn receiving optic fibres), decussate and terminate in the nucleus of the medial longitudinal fasciculus and other nuclei in the reticular formation.

The superior colliculus thus consists essentially of (*a*) afferent fibres from the retina (optic tract), the pallium and possibly other parts of the nervous system, and (*b*) efferent neurones to other parts of the brain and cord brought into various

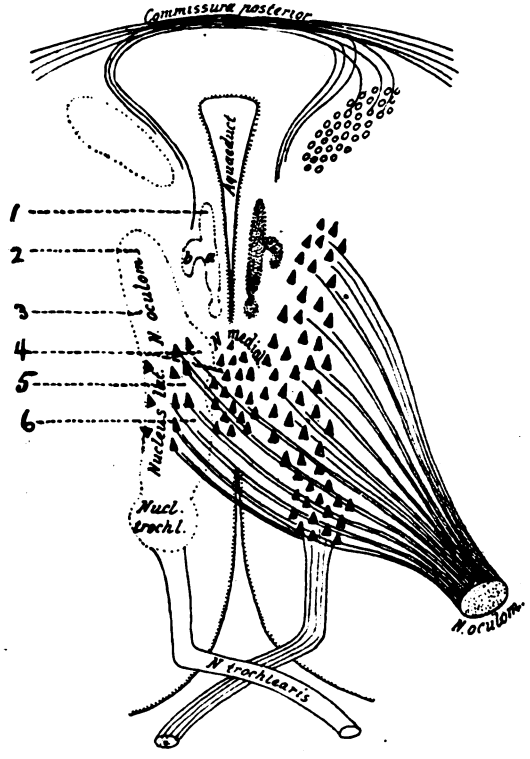

FIG. 379.—The region of the aquæductus Sylvii seen from above. Schema showing the position of the nuclei of nerves III and IV and their subdivisions. (Edinger.) 1. The small-celled nucleus (here represented as one on each side) *a*, its ciliary, *b*, its pupillary portion. 2, The portion of the large-celled nucleus sending uncrossed fibres to M. levator palpebræ; 3, portion sending uncrossed fibres to M. rectus superior; 4 and 5, portions sending crossed and uncrossed fibres to Mm. rectus internus and obliquus inferior; 6, portion sending crossed fibres to M. rectus inferior. The nucleus trochlearis sends crossed fibres to M. obliquus superior.

relations with each other in the colliculus either directly or by (*c*) the association cells of the colliculus, the axones of which do not leave the latter. The efferent fibres are collected in the deeper medullary layers and probably their most important connections are, by way of the medial longitudinal fasciculus and predorsal bundle, with the various oculomotor and facial nuclei and possibly with the body. (The older connections with retina and motor apparatus of head and body are reduced in man. The pallial connections are new.)

The central gray receives many radial fibres, probably collaterals from the fibres in the medullary collicular layers.

Forebrain or Prosencephalon

Interbrain (diencephalon or thalamencephalon)

In the interbrain or diencephalon, three parts may be distinguished; the *thalamus*, *epithalamus*, and *hypothalamus*. The epithalamus consists principally of the pineal body, the habenulæ, and striæ thalami. The hypothalamus consists mainly of the structures in the ventral expansion of the interbrain, such as the corpora mamillaria, tuber cinereum, infundibulum and posterior lobe of the hypophysis. The epithalamus and hypothalamus are principally connected with olfactory and visceral paths (see p. 597, paths 11, 27 and 28 and Fig. 384).

The Thalamus.—The thalamus comprises the great bulk of the interbrain. It consists of a *dorsal* part and a *ventral* part, the *subthalamus*. The most important subthalamic structure is the corpus subthalamicum of Luys lying just cephalad to the substantia nigra and dorsal to the pes pedunculi. It receives fibres from the dorsal part of the thalamus, from the globus pallidus (Forel's field H_2), and possibly from the pallium. Its efferent connections are not well known, they may be to the substantia nigra or to the cerebral peduncle.

The dorsal part of the thalamus is subdivided into two portions or segments, usually separated by a sheet of medullated fibres, the lamina medullaris medialis. These two portions are an internal or medial portion and an external or lateral portion.

Of these three portions the subthalamus and internal segment of the dorsal thalamus represent the older connections found in forms without a well developed pallium and constitute the *palæothalamus*. The subthalamus is efferent or motor, the medial thalamus sensory. The external or lateral segment has massive direct connections with the neopallium and is the *neothalamus*. It is also intimately connected with the internal or medial thalamus. Its nuclei and fibres may be regarded as newer structures added to the older thalamic mechanisms and adjusting the older with the newer, neopallial, afferent apparatus. In the internal segment are usually distinguished (*a*) the anterior nucleus which receives the mamillo-thalamic tract and sends fibres to, or interchanges fibres with the corpus

striatum. (*b*) The medial nucleus which interchanges fibres with the olfactory area, corpus striatum (part of the ansa lenticularis *via* inferior thalamic radiation) and, indirectly (*via* the neothalamus) also directly (?), with the pallium. It probably receives a part at least of the secondary trigeminal tracts and sends fibres to the subthalamus. (*c*) The "median center" of Luys, possibly to be regarded as a part of (*b*). (*d*) The nucleus arcuatus, probably belonging to the external segment of the thalamus. See also p. 588.

The external segment consists of a dorso-lateral, an external ventro-lateral, an internal ventro-lateral, and a ventral nucleus. To the external segment should be added the arcuate nucleus, lateral and medial geniculate bodies (metathalamus) and part at least of the pulvinar. Various nuclei of this external segment receive the fibres of the *afferent pallial paths* and complete the paths by sending fibres to the cortex pallii. These paths are (1) the medial lemniscus, spino-thalamic, and secondary trigeminal tracts (general sensory from body and face) to the ventro-lateral nuclei and thence to the cortex of the central region of the pallium; (2) the lateral fillet or brachium of inferior colliculus (hearing) to the medial geniculate body, and thence to the temporal region of the pallium; (3) the optic tract to the lateral geniculate body and thence to the occipital pallial cortex; (4) part of the superior cerebellar peduncle (also said to be distributed to nuclei of inner segment). The visceral (including gustatory) and vestibular paths to the pallium are not definitely known. The former has especially intimate relations, probably, with the medial thalamus, see below. (See also p. 591.) As the olfactory nerve belongs to the endbrain, its path to the pallium does not traverse the thalamus. Besides the above thalamo-cortical fibres, the external thalamic segment sends many other fibres to the cortex pallii and receives many fibres from the latter. The various fibres connecting thalamus and cortex constitute the *thalamic radiations*. They radiate from the thalamus forward, upward, backward and downward passing obliquely through the various portions of the internal capsule, of which they form a part. The thalamic radiations fall into four parts or subradiations: (1) The anterior or frontal thalamic radiation, connecting the frontal convolutions with the anterior and medial, and possibly anterior portion, of the lateral, thalamic nuclei. Its fibres occupy the anterior corona radiata and anterior or lenticulo-caudate segment of the internal capsule (p. 606). (2) The superior or parieto-central thalamic

radiation, connecting the Rolandic area and adjacent portions of the frontal and parietal lobes with the lateral and medial thalamic nuclei. The medial lemniscus radiation forms part of this radiation. The fibres of the superior thalamic radiation occupy the upper portion of the corona radiata and the posterior or lenticulo-thalamic segment of the internal capsule. (3) The posterior thalamic radiation, connecting the occipital and adjacent parietal convolutions (cuneus, lingualis, fusiformis, occipitalis, angularis and supramarginalis) with the caudal portions of the thalamus, especially the pulvinar. It includes the optic radiation (of Gratiolet) from pulvinar, lateral corpus geniculatum (metathalamic) (and superior colliculus, non-thalamic). The posterior radiation occupies the retrolenticular segment of the internal capsule. (4) The inferior thalamic radiation, connecting the temporal lobe with the medial and lateral thalamic nuclei, entering the thalamus on its ventral side. It probably includes the acoustic, geniculo-temporal radiation. This radiation occupies the sublenticular and part of the lenticulo-thalamic segments of the internal capsule. From the preceding it is evident that in general the anterior parts of the cortex are connected with the anterior part of the external thalamic segment, the middle with the middle, and the posterior with the posterior. It is also probable that the thalamo-cortical fibres from the various lateral nuclei are arranged dorso-ventrally, so that the fibres from the ventral parts pass to the ventral part of the central region of the pallium, dorsal to dorsal, etc. (E. Sachs.)

In the metathalamus and thalamus, the following nuclei, according to the types of cells, can be distinguished (Fig. 380) (Malone). (1) Nucleus magnocellularis corporis geniculati lateralis, the larger-celled part of the lateral geniculate body, and (2) the nucleus principalis corporis geniculati lateralis composed of cells about half the size of (1) and principally the external part. (3) the nucleus ventralis and (4) nucleus dorsalis corporis geniculati medialis. The nucleus ventralis is composed of the larger cells. (5) The nucleus communis thalami. This nucleus is so called because it is composed of a type of cells found nearly throughout the thalamus and may be regarded as a fundamental nucleus in which the other cell groups are imbedded. It is divided into (*a*) a lateral part comprising all the above mentioned lateral or external segment of the thalamus, (*b*) a medial part which corresponds to the above medial nucleus and (*c*) a dorsal part corresponding to the above anterior or dorsal nucleus. The cells of this nucleus are rounded, polygonal cells, of varying sizes, with little chromophilic substance and containing a moderate amount of yellow pigment. They stain rather dark with the Nissl stain. (6) The nucleus magnocellularis thalami lies in the ventral and medio-ventral part of the thalamus and may be

divided into a pars arcuata, corresponding to the above nucleus arcuatus, and a pars principalis. The cells of the nucleus magnocellularis are the largest in the thalamus. The cytoplasm contains yellow pigment, the rest of it taking a homogeneous blue stain. This nucleus is one which receives the medial lemniscus (and spino-thalamic?) fibres. It would seem probable that the large cells are at least a part of those which send fibres to the somæsthetic area of the cortex pallii. The nucleus arcuatus merges to some extent with the adjoining more medial and dorsal nuclei. (7) The nucleus parvocellularis thalami or small-celled nucleus of the thalamus. The cells are round or oval and very small with a large pigment content. This nucleus corresponds to the median center of Luys plus a small portion of the nucleus reuniens (see below). It is nearly free from cells of the nucleus communis type. (8) The nucleus reuniens thalami, so called because the massa (or commissura) intermedia uniting the two sides of the thalamus is composed of the cells of this type. The cells are inclined to be arranged in compact bands and clumps which tend to run between or around the other medial nuclei (see Fig. 389). They are for the most part fusiform, stain intensely and contain little pigment. They show transition forms to the nucleus communis type but most resemble those of the Edinger-Wesphal nucleus and are possibly sympathetic in character. (9) The nucleus paramedianus thalami is a thin band of cells lying close to the third ventricle dorsal to the massa intermedia. The cells are among the smallest cells of the thalamus. They are fusiform, stain deeply and are closely packed together. They are smaller than the cells of the nucleus reunions, which they otherwise resemble and consequently may also be of a sympathetic character.

There are no cells of the motor (premotor) type in the thalamus and metathalamus such as the cells of Betz in the motor cortex pallii, certain cells in the globus pallidus, hypothalamus, formatio reticularis, nucleus ruber, substantia nigra and superior colliculi and the cells of the nucleus fastigii and nucleus of Deiters (Jacobsohn and Malone).

It is evident from the above that the thalamus is more than a mere relay station for the various sensory paths to the pallium. Such stations appear to be adequately provided for in the geniculate bodies and certain ventro-lateral thalamic nuclei. There remains unaccounted for the greater part of the thalamo-cortical fibres of the thalamic radiations, all of the cortico-thalamic fibres, and the bulk of the thalamic nuclei. Clinical observations (Head and others) with autopsies have thrown considerable light upon the interpretation of these thalamic connections, though their nature has not yet been made entirely clear. The observations referred to show that in certain thalamic lesions there is a sensory loss consisting preëminently in a loss of the sense of position and movement and of touch discrimination, with a blunting of touch and without loss of pain. On the other hand there may be pains, apparently felt in various parts of the body, and an increase of "feeling tone" or "affect" *e.g.*, various tactile stimuli previously not disagreeable evoke various disagreeable sensations, not always easily characterized by the patient. The patient cannot endure innocuous cutaneous stimuli and yet cannot tell what the stimulus is which produced the disagreeable sensations.

It has already been seen that there are two aspects to sensation, the dis-

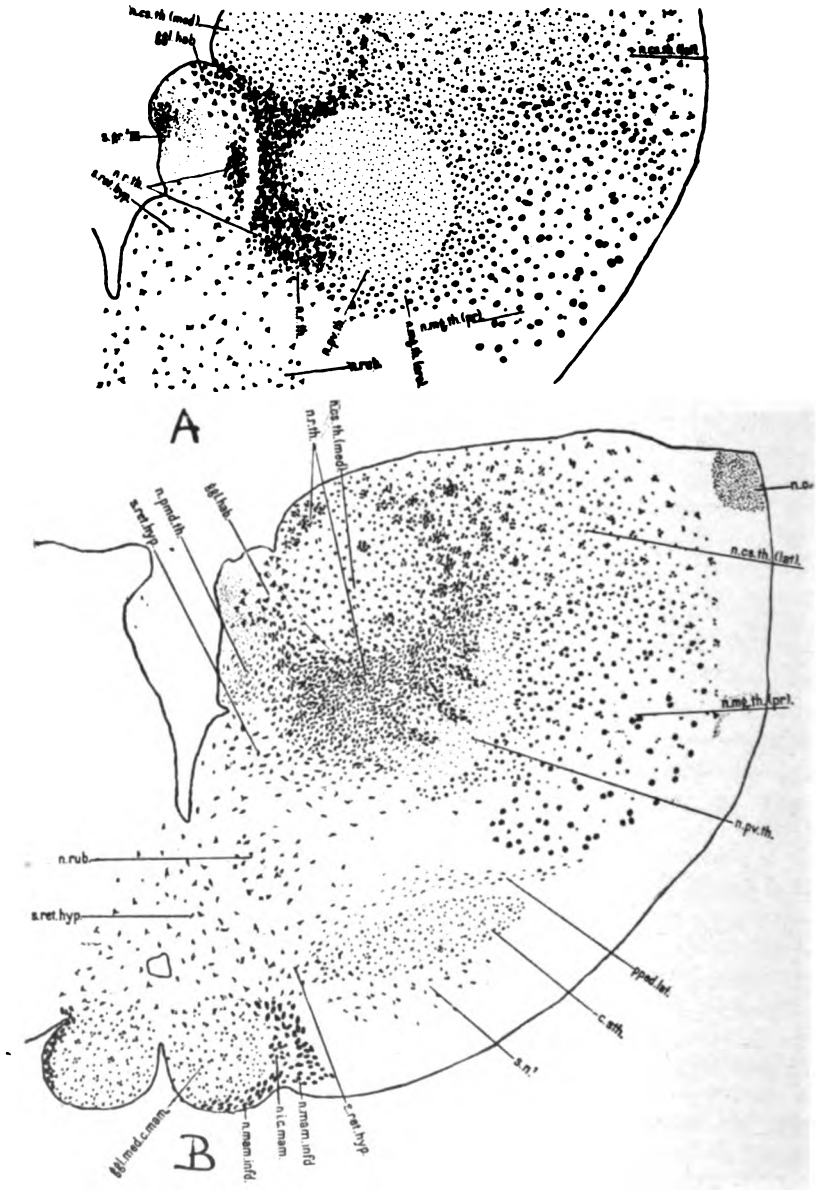

FIG. 380.—*A* and *B*. Two Transverse Sections of the Diencephalon, Showing the Cell Groups. Nissl's stain. (Malone.) *c. sth.*, corpus subthalamicum of Luys; *ggl. hab.*, ganglion (or nucleus) hebenulæ; *ggl. med. c. mam.*, ganglion (or nucleus) mediale corporis mammillaris; *n.c.*, nucleus caudatus; *n. cs. th. (lat).*, nucleus communis thalami, pars lateralis; *n. cs. th. (med.).*, nucleus communis thalami, pars medialis; *n. i. c. mam.*, nucleus intercalatus corporis mammillaris; *n. mam. infd.*, nucleus mammillo-infundibu-

criminative side by which stimuli are compared as to intensity, locality and time *e.g.*, they are localized, discriminated and integrated into perceptions of form, size and texture, movements are judged as to extent and direction by comparison with previous poses, etc. It is this kind of sensory phenomena which is affected by cortical lesions and by lesions of certain paths (especially the medial lemniscus path) and their particular thalamic nuclei. On the other hand there is the "affective" side of sensation: pain, agreeableness or disagreeableness. It is evident that pain is nearly all "affect," except perhaps its localization and intensity, that temperature and many tactile sensations have marked affective tone while discriminations and perceptions of intensity, form, size, position and movement do not. All visceral sensations have a strong affective tone. This affective quality of sensation is thalamic rather than cortical.

There are, besides, the emotional states aroused by certain perceptions: fear, desire, etc. These are usually aroused by perceptions previously associated with affective sensations *e.g.*, the sight of something dangerous, sight of food. Where the emotion is one of desire for the satisfaction of a bodily need, the coöperation of visceral stimuli is often necessary *e.g.*, the sight of food will not arouse desire with a full stomach. Pain cannot be re-represented or imaged mnemonically, emotion can very readily be aroused by appropriate images. It is obvious that emotion is largely a cortical affair.

Viewed on the effector side affective reactions are characterized by immediate and excessive movement, secretory, vasomotor and other visceral changes; discriminative reactions are precise, not excessive and often delayed. Purely affective reactions are purposeless and excessive; purely non-affective, discriminative reactions probably do not exist. Where even interest fails and there is complete apathy, the individual remains motionless.

The best neurological explanation of the above phenomena appears at present to be afforded by certain peculiarities of thalamo-pallial relations. On the afferent side there is apparently a dividing of the pathways. One path, after a simple relay in certain ventro-lateral and metathalamic nuclei, proceeds to the various sensory pallial areas already mentioned. This path conveys to the associative-memory apparatus of the pallium the stimuli with which it performs its discriminative and recognitive functions. Other stimuli reaching the thalamus are diffused in the thalamus, probably by the shorter associative neurones mentioned above, in lateral and especially in medial nuclei. Here certain somatic are probably brought into relation with visceral impulses, a blending which probably results in the thalamus being a special center for the general bodily feeling of well-being or ill-being which plays such an important part in the emotional life of the individual. Finally by this indirect route impulses reach the pallium by thalamo-cortical neurones. The impulses following this path are the affective ones. Crude, undefined, uncharacterized pain and other affective states may perhaps be "felt" by the thalamus, excessive pain may give

---

laris; *n. mg. th.* (*arc.*), nucleus magnocellularis thalami, pars accuata; *n. mg. th.* (*pr.*)., nucleus magnocellularis thalami, pars principalis; *n. pmd. th.*, nucleus paramedianus thalami; *n. pv. th.*, nucleus parvocellularis thalami; *n. r. th.*, nucleus reuniens thalami *n. rub.*, nucleus ruber; *pped. lat.*, nucleus peripeduncularis lateralis (Jacobsohn); *s. gr.*[2] *III*, substantia grisea ventriculi tertii, pars superior; *s.n.*[1], substantia nigra, pars parvocellularis; *s. ret. hyp.*, substantia reticularis hypothalami.

rise to generalized convulsive movements and various visceral changes in which the cortex may be involved but if so it may be overstimulated. The normal thalamo-cortical reaction (*e.g.*, consulting a doctor in case of pain) involves elaborate, complicated, learned activities of a highly cortical character. In this case the cortex has been stimulated, reinforced or energized by the somatic-splanchnic thalamic diffusion. It would seem probable, too, that by this diffusion there becomes attached, as it were, to other preceptions at first associated with the painful stimulus an affect tone so that when the perception is repeated (*e.g.*, sight of an object which previously caused pain and is "recognized" by the cortical apparatus) there is an affective state which gives the impulse to a cortically directed purposeful pain-avoiding reaction. It is possible also that the thalamic diffusion by carrying *e.g.*, two sensory stimuli into overlapping intermediate areas, helps to activate the other associative-memory processes of the cortex.

The cortico-thalamic fibres are usually considered as acting in an inhibitory way upon the thalamic activities and their interruption is evidenced by the increased "affect" mentioned above. It would seem however that an additional more positive function should be assigned them. For example the perception of emotion-arousing objects exerts an influence upon visceral structures. The efferent pathway for this probably involves cortico-thalamic neurones.

The pallial apparatus is thus in a certain sense an elaborate mechanism, based, primarily, upon the distance receptors and developed so as to enable the individual to satisfy bodily needs (nutrition, protection, reproduction) in more effective and far-reaching "intelligent" ways than would be possible otherwise. Its great elaboration, however, has given rise to activities in which these ends are often not obvious.

In brief the above thalamo-pallial mechanism is the one largely involved in the affective, emotional and instinctive reactions.

As has been noted, in the various sensory paths to the pallium there are thus two points where there are important redistributions in the gray: First where the ganglionic neurones enter and terminate and where each afferent nerve is distributed into tracts representing mere contact, position and movement, tactile discrimination, pain and temperature and visceral sensation; second in the thalamus where there is a final cleavage into the thalamic affective and the cortical discriminative portions. (See also p. 517 *et seq.*)

PRACTICAL STUDY

12. Transverse Section of Midbrain and Thalamus at Their Junction (Figs. 332 and 381).

(For the various paths involved see pp. 507–519.)

The most conspicuous change from the last section is the appearance, or increase, of the geniculate bodies and pulvinar, and the thalamic radiations.

Efferent Peripheral Neurones.—The nuclei and root fibres of the III nerve are still present.

Afferent Roots, their Terminal Nuclei, Secondary Tracts, and Tertiary Neurones.—The fibres of the *optic tract* (optic "nerve") are seen entering the

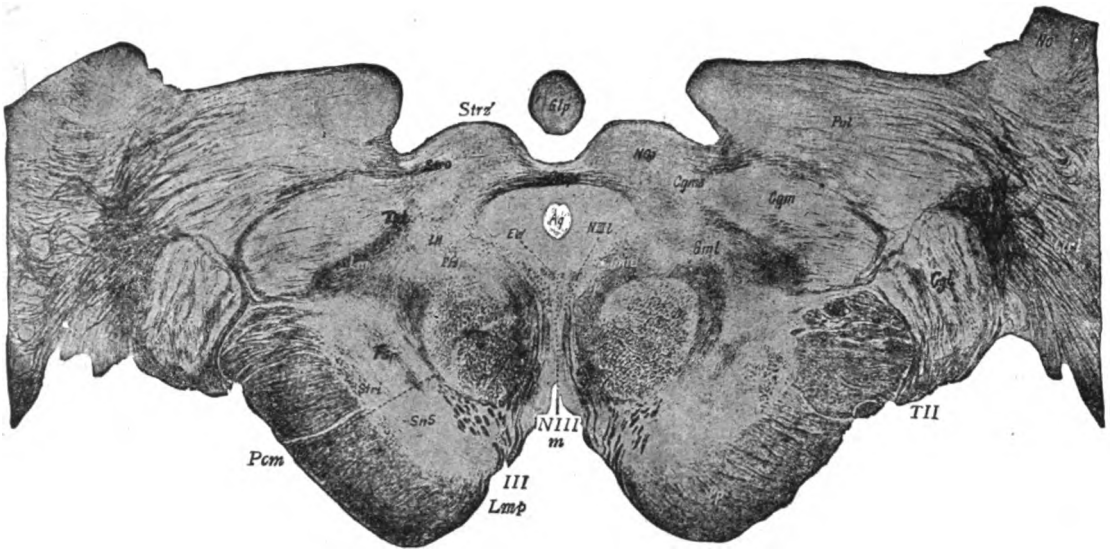

FIG. 381.—Transverse Section through the Junction of Midbrain and Thalamus. Weigert preparation. (Marburg.) *III*, Nervus oculomotorius. *Aq*, Aquæductus Sylvii; *Cgl*, corpus geniculatum laterale (or externum), *Cgm*, corpus geniculatum mediale (or internum); *Cgma*, ganglion accessorium corp genicul. med.; *Cirl*, pars retrolenticularis capsulæ internæ; *EW*, Edinger-Westphal nucleus; *FH*, fasciculi tegmenti of Forel; *Flp*, fasciculus longitudinalis medialis (posterior); *Glp*, glandula pinealis; *Gmd*, ganglion mesencephali dorsale; *Gml*, ganglion mesencephali laterale; *lH*, fasciculus tegmenti lateralis; *Lm*, lemniscus medialis; *LmP*, fasciculus lemnisci ad pedunculum; *Nc*, nucleus caudatus. *NIIIl*, nucleus oculomotorii lateralis; *NIIIm*, nucleus oculomotorii medialis (centralis); *NQa*, nucleus corporis quadrigemini anterioris; *Ntg*, Nucleus ruber tegmenti; *Pcm*; pedunculus corporis mammillaris; *Pp*, pes pedunculi; *Pul*, pulvinar (thalami); *Sn.S*, substantia nigra; *Stri*, stratum intermedium (pedunculi); *Stro*, stratum opticum; *Strz'*, stratum zonale corp. quadrigemini; *TII*, tractus opticus; *Tst*, Tractus spino-thalamicus; *Fsp*. fasciculus subthalamico-peduncularis.

ventral surface of one of their terminal nuclei, the *lateral* or *external geniculate body*. Other optic fibres (not entirely traceable) enter the pulvinar thalami and the superior colliculus (*Stro*) (see also preceding section). On the dorso-lateral surface of the lateral geniculate body, a bundle of fibres accumulates which represents the beginning of the geniculo-calcarine tract to the occipital cortex, thereby completing the *visual path*.

Internal to the lateral geniculate body is the medial (internal) geniculate body which now contains the terminals of the brachium of the inferior colliculus. Fibres from its cells gather on its lateral surface. These represent the beginning of the geniculo-temporal tract to the temporal cortex, thereby completing the *auditory path*.

Internal and ventral to the medial geniculate body are the medial lemniscus (bulbo-thalamic) and spino-thalamic tracts about to terminate in the ventro-lateral thalamic nuclei whose axones complete the *general sensory path* by passing to the central cortex.

The central tegmental tract can hardly be distinguished.

Intersegmental Neurones.—The nucleus ruber is still large, but the remainder of the reticular formation has nearly disappeared. The medial longitudinal fasciculus is much diminished as its ascending fibres terminate in the nucleus of nerve III and many of its descending fibres originate from cells below this level.

Efferent Suprasegmental Neurones.—The pes pedunculi occupies the same position, and dorsal to it is the diminished substantia nigra. Along the ventro-mesial border of the pes a bundle of fibres can sometimes be distinguished (Fig. 381, *Lmp*), which at lower levels comes to lie mesial to the medial lemniscus (aberrant peduncular fibres, see path 18). Descending pallial fibres (not distinguishable) also probably form part of the thalamic radiations (pp. 587, 588).

Fibres of the superior cerebellar peduncle may be seen within and around the nucleus ruber. Some of these terminate in the latter, some pass further forward to end in the thalamus (compare pp. 567, 595).

The Superior Colliculus is somewhat diminished. The *posterior commissure* passes across in the roof dorsal to the central gray (see preceding section).

The Thalamus (can hardly be included under the preceding structures).—The corpora geniculata have been mentioned. The *pulvinar* thalami is a large gray mass dorsal to the medial geniculate body. Fibres passing laterally from it contribute to the *retrolenticular portion of the internal capsule* (*Cirl*). These fibres are a part of the *thalamic radiations*.

The *nucleus caudatus* (a portion of the corpus striatum of the endbrain) is present (see p. 601).

13. Transverse Section of the Interbrain at the Level of the Optic Chiasma (Figs. 343 and 382).

(For the various paths involved, see pp. 507–519.)

Efferent Peripheral Neurones.—None are present.

Afferent Roots, their Terminal Nuclei, Secondary Tracts, and Tertiary Neurones.—Fibres of the optic nerve are seen decussating and forming the *optic*

chiasma. The further continuation of the optic fibres to their termination is called the *optic tract.* Both nerve and tract constitute the secondary optic tract, the optic chiasma being analogous to the decussation of the medial lemniscus and of the lateral lemniscus (trapezius). The fibres of the optic tract pass to the superior colliculus (*via* its brachium) to the medial geniculate body and to the pulvinar. Another bundle passes around the pes and apparently terminates in the tegmentum (tractus peduncularis transversus). Just dorsal to the chiasma can usually be seen another bundle of crossing medullated fibres (not shown in the figure). This is the commissure of Meynert and does not belong to the optic systems. It probably contains decussating fibres of the ansa lenticularis (see later) and may be connected with the neighboring basal "optic" ganglion. (Another commissure apparently forming part of the chiasma is a light-staining bundle, not conspicuous in man, the commissure of Gudden. It is not optic and may be connected with the medial geniculate bodies). (For further description of optic paths see Fig. 383 and path 10).

The medial lemniscus, spino-thalamic, and secondary trigeminal tracts are now lost in the ventro-lateral thalamic nuclei, cells of which constitute the tertiary neurones of the various afferent pallial paths (see pp. 507 and 587. For their further continuations, see below under Thalamus (thalamic radiations).

Intersegmental Neurones.—The cephalic end of the nucleus ruber is still present on the right (*Ntg*). On the left are seen some fibres in its place, lateral to which are two transverse bundles enclosing a strip of gray matter. These are known as the *area tegmenti* or *field of Forel* and represent a subthalamic forward extension of the tegmentum. The gray or *zona incerta* may be regarded as representing a continuation of part of the reticular formation. The ventral bundle of fibres (*HII*) are probably fibres from the nucleus lenticularis (*glp* and *Pu*, right) passing through the pes (or rather through the posterior part of its continuation—the internal capsule) as perforating fibres (*fp* on right) to the corpus subthalamicum (*Csth*, left) and other subthalamic regions, possibly also to the nucleus ruber. Some of these fibres are collaterals of pes fibres and may consequently come directly from the pallium. The dorsal bundle (*HI*) probably contains fibres connecting red nucleus and pallium. Other fibres in this region are probably fibres of the superior cerebellar peduncle which have passed by the nucleus ruber to the lateral nucleus and median center of the thalamus (see also p. 587) and possibly also fibres of the secondary trigeminal tract. The nucleus of the medial longitudinal fasciculus falls in the level between this and the preceding section. In general it seems probable that portions of the corpus striatum, the corpus subthalamicum and certain other subthalamic nuclei, the substantia nigra and part of the nucleus ruber represent certain phylogenetically old, rather obscure, efferent forebrain paths (see pp. 514 and 602). Many of the above structures obviously hardly come under the category of intersegmental neurones.

Efferent Suprasegmental Neurones.—The pes pedunculi now lies partly between the thalamus and nucleus lenticularis (see p. 601) constituting the greater part of the *internal capsule* (see p. 606). The parts of the internal capsule as shown in horizontal sections of the hemispheres are shown in Fig. 386. The most dorsal part is here passing into the corona radiata (p. 605) of the cerebral

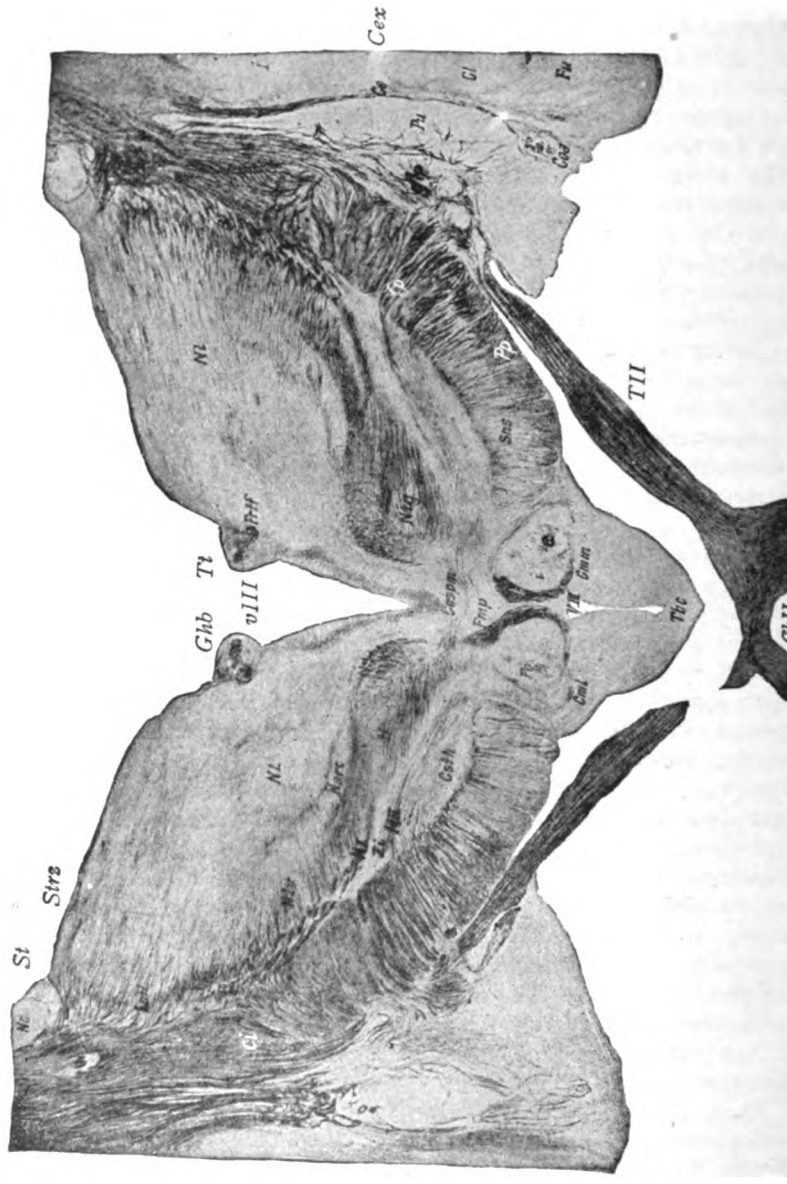
Cex
Cl
Fu
Cod
Pu
Fp
Pp
Nl
TII
Sns
Ntq
Prtf
Tt
Ghb
vIII
Gmm
Tbc
ChII
Cml
Nl
Cstb
Nl
Zi
Nlt
Strz
St
Nc
Cl

FIG. 382.

hemispheres (not included in the section). These fibres lie in the most posterior part of the capsule and are the same as the most lateral fibres of the pes, *i.e.* the occipito-temporal pallio-pontile fibres (see path 19*b*).

Dorsal to the mesial part of the pes is the *corpus subthalamicum* which has replaced the substantia nigra. It receives collaterals from the pes and is said to contribute fibres to the latter. It also appears to be connected by fibres with the nucleus lenticularis (see above). Superior cerebellar peduncle (see Intersegmental Neurones above).

Thalamus.—At this level the *ventro-lateral nucleus*, the *nucleus arcuatus*, and the *median center of Luys* can usually be distinguished. At the outer border of the thalamus, fibres accumulate forming the *lateral medullary lamina*. These fibres continue outward as *thalamic radiations* (see p. 587), entering the internal capsule which they may follow a distance, or cross obliquely and enter the corona radiata. At this level the afferent, thalamo-pallial fibres probably represent both the direct and indirect (thalamic diffusion) sensory paths.

Epithalamic and Hypothalamic Structures and their Connections.—The *ganglia habenulæ* are two small masses of gray matter occupying eminences on the mesial walls of the thalamus. A bundle of fibres near each is the *stria medullaris* (near the *tænia thalami*) consisting of fibres from the olfactory bulb and trigonum and representing olfactory connections (p. 601 and paths 11 and 27). The ganglion habenulæ contains a mesial small-celled and a lateral large-celled nucleus. Their axones form the *fasciculus retroflexus* of Meynert to the interpeduncular ganglion, situated more caudally (Fig. 377). There is also a *commissura habenularis* connecting the two ganglia. The *stria terminalis* (*stria cornea*, *stria semicircularis*), another olfactory connection, lies in the groove between the ventricular surfaces of nucleus caudatus and thalamus. The *tuber cinereum* is seen projecting ventrally. Dorsal to this are seen the *corpora mammillaria* containing lateral and mesial nuclei. The mammillary body receives some fibres of the *fornix* (from the rhinopallial cortex, see below) and also possibly fibres from the medial fillet and other ascending tracts in the reticular formation. It gives rise to the bundle of Vicq d'Azyr (mammillothalamic tract) to the dorsal nucleus of the thalamus, and mammillo-tegmental fibres to the nucleus of Gudden (Fig. 384) and red nucleus. The fibres entering

---

FIG. 382.—Section through the Interbrain at the Level of the Optic Chiasma. (The chorioid plexus of the third ventricle has been removed.) Weigert preparation. (Marburg) *Ce*, capsula externa; *Cex*, capsula extrema; *ChII*, chiasma nervorum opticorum (or optic chiasma); *Ci*, capsula interna; *Cl*, claustrum; *Cml*, ganglion laterale corp. mammillaris; *Cmm*, ganglion mediale corp. mammill.; *Coa*, commissura anterior; *Cospm*, commissura supramammillaris; *Csth*, corpus subthalamicum; *e*, nucleus externus gangl. med. corpor. mammillaris; *Fmp*, fasciculus mammillaris princeps; *Fo*, fornix; *Fp*, fibræ perforantes (pedunculi); *frlf*, fasciculus retroflexus (Meynert); *Fsp*, fasciculus subthalamico-peduncularis; *Fu*, fasciculus uncinatus; *Ghb*, ganglion habenulæ; *glp*, globus pallidus; *H*, area tegmenti Forel; *HI*, pars dorsalis areæ tegmenti; *HII*, pars ventralis areæ tegmenti; *I*, insula Reillii; *i*, nucleus internus gangl. medial. corp. mammillaris; *Lml*, lamina medullaris lateralis; *Narc*, nucleus arcuatus thalami; *Nc*, nucleus caudatus; *NL*, nucleus Luysii (nucleus centralis, or median centre, thalami;) *Nl*, nucleus lateralis thalami; *Nlv*, nucleus lateralis ventralis thalami; *Ntg*, nucleus ruber tegmenti; *Pp*, pes pedunculi; *Pu*, putamen; *SnS*, substantia nigra; *St*, stria cornea; *Strz*, stratum zonale thalami; *TII*, tractus opticus; *Tbc*, tuber cinereum; *Tt*, tænia thalami; *VIII*, ventriculus tertius; *Zi*, zona incerta.

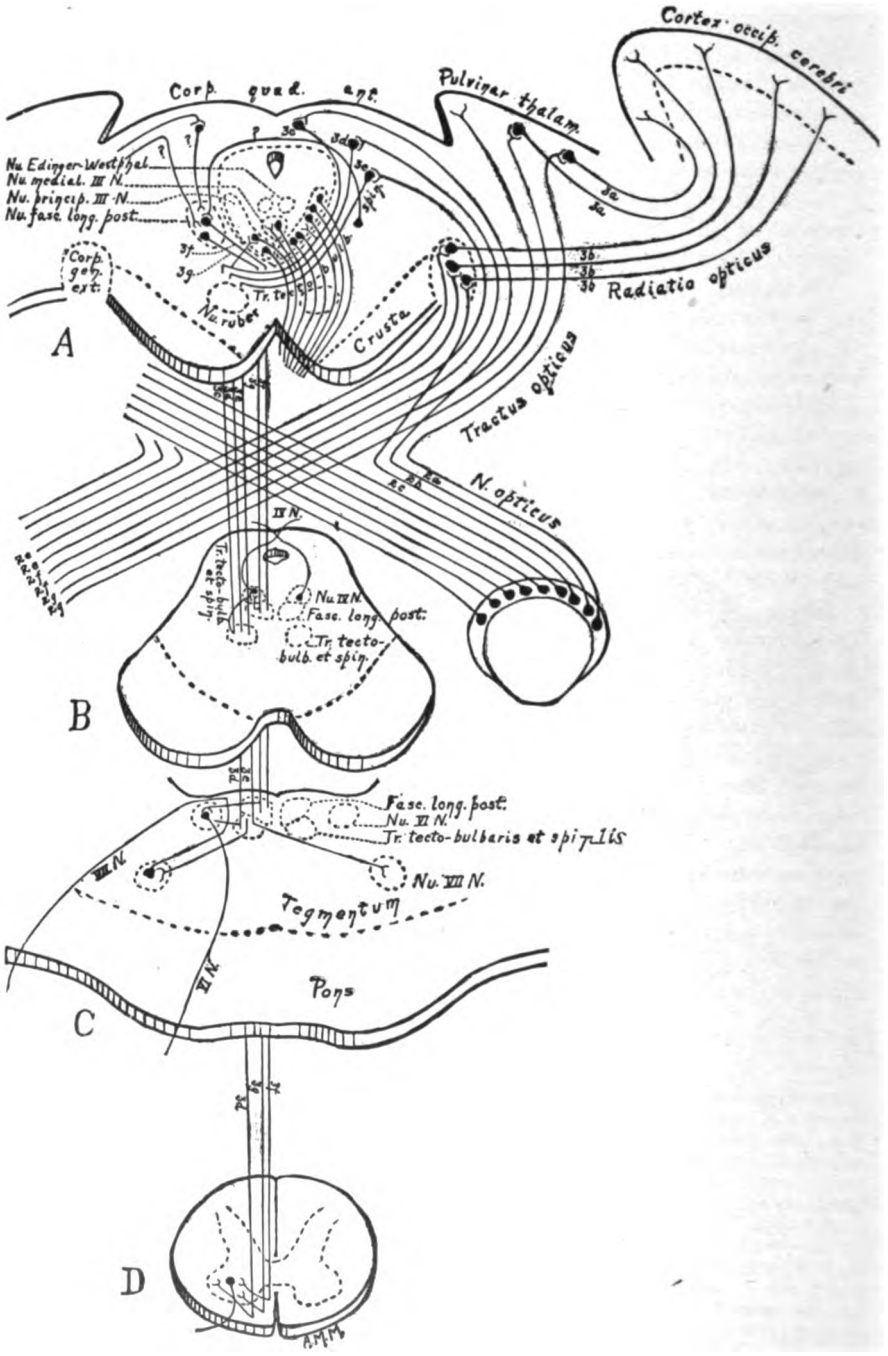
Cortex occip. cerebri
Corp. quad. ant.
Pulvinar thalam.
Nu. Edinger-Westphal
Nu. medial. III N.
Nu. princip. III N.
Nu. fasc. long. post.
Corp. geb. ext.
Nu. ruber
Crusta
Radiatio opticus
Tractus opticus
N. opticus
A
B
C
D
Nu. III N.
Fasc. long. post.
Tr. tecto-bulb. et spin.
Tegmentum
Pons

FIG. 383.

EXPLANATION OF FIG. 383.

FIG. 383.—Diagram of the Optic (II) Nerve and some of its Principal Connections. *A*, Level of nerves II and III; *B*, level of nerve IV; *C*, level of nerves VI and VII; *D*, spinal cord. Neurone groups are represented by one or several individual neurones.

The rods and cones (receptors) and the bipolar cells (=Neurone No. 1) of the retina are not indicated.

Neurone No. 2.—*2a*, Axones of ganglion cells in temporal part of retina pass to pulvinar of thalamus of same side; *2 b*, axones of ganglion cells in temporal retina pass to superior colliculus of same side; *2 c*, axones of ganglion cells in temporal retina pass to external geniculate body of same side; *2 e*, axones of ganglion cells in nasal side of retina cross in optic chiasma and pass to external geniculate body of opposite side; *2 f*, axones of ganglion cells in nasal side of retina cross in optic chiasma and pass to superior colliculus of opposite side; *2 g*, axones of ganglion cells in nasal side of retina cross in optic chiasma and pass to pulvinar of thalamus of opposite side. Macular fibres are partly crossed and partly uncrossed.

Neurone No. 3.—*3a*, Axones of cells in pulvinar to cortex of occipital lobe of cerebrum (this connection is disputed); *3 b*, axones of cells in external geniculate body to cortex of occipital lobe of cerebrum; *3 a* and *3b* constitute the primary optic radiation; *3 c*, *3 d* and *3 e*, axones of cells in deep (fourth) layer of superior colliculus (see p. 522) decussate ventral to medial longitudinal fasciculus (dorsal tegmental decussation or decussation of Meynert) and form the tractus colliculo-bulbaris et spinalis or predorsal bundle. (*Tr. tectobulb. et spin.*) to bulb (medulla) and anterior column of cord, innervating by collaterals and terminals, directly or indirectly, chiefly the nuclei of III, IV, VI, and VII cranial nerves and motor nuclei of spinal nerves. *3 f* and *3 g* (possibly another neurone intercalated between these and optic terminals), axones of cells in interstitial nucleus of Cajal (*Nu. fasc. long. post.*) form part of medial longitudinal fasciculus and descend on same side to anterior column of cord next to anterior median fissure, innervating nuclei of III, IV, and VI cranial nerves and motor nuclei of spinal nerves.

Neurone No. 4.—Axones of cells in above-mentioned motor nuclei. Axones from cells in median nucleus of nerve III (*Nu. med. N. III*) and possibly in Edinger-Westphal nucleus, probably innervate the intrinsic muscle of eyeball (ciliary and pupillary reflex path).

Pallio-tectal fibres, by means of which the collicular reflex centre is brought under the control of the cerebral cortex, are not indicated.

It is evident from the diagram that the cerebral pathway of the optic nerve is *via* the external geniculate body (and pulvinar of thalamus?), and the reflex pathway is *via* the superior colliculus.

the mammillary body from the fillet and other ascending tracts, together with the mammillo-tegmental tract, constitute its *peduncle* or *fasciculus princeps*. It is not improbable that the mammillary body is a link in the afferent gustatory path (paths 7). (See also Endbrain.)

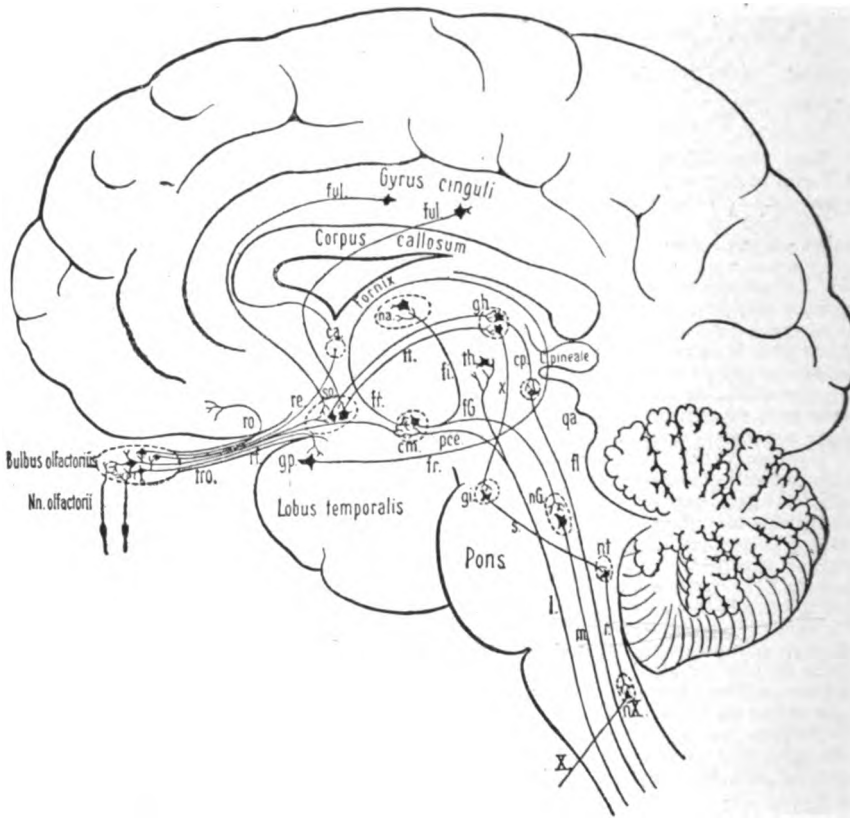

FIG. 384.—Diagram of Olfactory Paths (von Bechterew.) *X*, Root fibres of vagus; *ca*, commissura anterior; *cm*, corpus mammillare; *cp*, fibres from nucleus habenulæ to posterior commissure; *fG*, tract from corpus mammillare to Gudden's nucleus; *fi*, fasciculus mammillo-thalamicus; *fl*, fasciculus longitudinalis medialis; *fr*, fornix; *ful*, fibres of fornix longus; *gh*, nucleus habenulæ; *gi*, ganglion interpedunculare; *gp*, gyrus pyriformis; *l*, lemniscus medialis; *m*, fibres from Gudden's nucleus to substantia reticularis grisea; *na*, nucleus anterior thalami; *nG*, Gudden's nucleus; *nt*, nucleus tegmenti (v. Gudden); *nX*, nucleus motorius nervi vagi; *pcE*, pedunculus corporis mammillaris from fillet; *qa*, corpora quadrigemina; *r*, fibres from nucleus tegmenti (v. Gudden) to nuclei of cranial nerves; *re*, radix lateralis tractus olfactorii; *rf*, fibres of tractus olfactorius to trigonum olfactorium; *ro*, radix medialis tractus olfactorii; *s*, fibres from ganglion interpedunculare to nucleus tegmenti; *so*, area of trigonum olfactorium; *th*, thalamus; *tro*, tractus olfactorius; *tt*, tænia thalami; *x*, fasciculus retroflexus.

On the right is seen the caudal part of the *nucleus lenticularis* of the corpus striatum.

THE ENDBRAIN OR TELENCEPHALON

The endbrain consists of *pallium* (dorsal expanded part), *corpus striatum*, and *rhinencephalon*. Two principal parts of the pallium

may be distinguished; the olfactory pallium or rhinopallium (archipallium), including principally the cornu ammonis and gyrus dentatus; and the neopallium including the greater part of the cerebral hemispheres.

The Rhinencephalon.[1]—The rhinencephalon includes the olfactory nerves and bulb, the primary cortical areas of the anterior (tuberculum and trigonum olfactorium) and posterior (anterior perforated space or olfactory area, gyrus semilunaris and gyrus ambiens) olfactory lobes and the unciform gyrus (part of pyriform lobe). The secondary cortical areas of the lamina terminalis, gyrus subcallosus, area of Broca (not the one of similar name in the frontal lobe), induseum, gyrus dentatus, cornu ammonis and, probably, nucleus amygdalæ belong to the pallium, and constitute the archipallium, sometimes included in the term rhinencephalon. Of these latter all except the gyrus dentatus and cornu ammonis have been much reduced by the great development of the neopallium and its commissure, the corpus callosum, to vestigial structures lying near the latter. For the various olfactory connections see paths 11 and 27 and Fig. 384. The principal commissure of the rhinencephalon is the anterior cerebral commissure, of the archipallium is the fornix commissure.

The Corpus Striatum.—The corpus striatum consists of two principal parts, the *nucleus caudatus* and *nucleus lenticularis*, separated from each other by the anterior or lenticulo-caudate limb of the internal capsule. The lenticular nucleus is divided by a sheet of medullated fibres into an external part containing comparatively few medullated fibres, the *putamen*, and an inner or medial part, with many medullated fibres, the *globus pallidus*. The medullated fibres dividing the lenticular nucleus into segments are principally fibres passing through and not connected with it. There are also many fibres traversing it radially (latero-mesially) and giving it a striated appearance. These are the afferent and efferent fibres of the lenticular nucleus.

The cells of the corpus striatum may be considered as falling into two classes: Medium and small cells, and large cells of a motor appearance (pre-motor cells). Nearly all of the latter are found in the globus pallidus and are to be regarded, probably, as the cells giving rise to the efferent fibres of the lenticular nucleus (*ansa lenticularis* system).

[1] The term rhinencephalon is often used to include also the olfactory pallium.

The connections of the corpus striatum are still obscure but the following are quite established: (*a*) Lenticulo-caudate fibres traversing the anterior or lenticulo-caudate limb of the internal capsule and connecting the lenticular and caudate nuclei. They possibly pass in both directions. (*b*) Lenticulo-thalamic fibres connecting the lenticular nucleus with anterior (and medial?) thalamic nuclei. These fibres pass around ventral to the internal capsule and are mingled with the inferior thalamic radiation. They may pass in both directions. (*c*) Lenticulo-subthalamic fibres to the corpus subthalamicum of Luys. These fibres pass through (fibræ perforantes) the posterior or lenticulo-thalamic limb of the internal capsule, form a capsule around the ventral part of the corpus subthalamicum and probably terminate in the latter. (*d*) Lenticulo-hypothalamic fibres passing, in company with (*c*), through the internal capsule, dorsally to the corpus subthalamicum and thence medially and ventrally (field H_2 of Forel) to the tuber cinereum. (*e*) Lenticulo-rubral fibres to the nucleus ruber. (*f*) Lenticulo-nigral fibres to the substantia nigra. The prevailing opinion is that there are no fibres directly connecting pallium and corpus striatum though perhaps the view of Cajal that the projection fibres of the pallium give off collaterals to the striatum as they pass by has not been excluded. Connections (*b*), (*c*) (*d*), (*e*?) and (*f*?), collectively form the ansa lenticularis system in the broader sense.

The globus pallidus represents the older portion (palæo-striatum) of the corpus striatum while the caudate nucleus and putamen are more recent additions (neo-striatum) and should represent neopallial connections.

The functions of the corpus striatum are still not clear but considerable light has been thrown upon them. According to one view (J. Ramsay Hunt, based upon clinical and autopsy evidence and comprising the work also of Vogt and Wilson) destruction of the small cells of the neostriatum results in choreiform movements, destruction of the large cells of the pallidus results in the rigidity, loss of associated movements and tremor seen in paralysis agitans, while destruction in varying degrees of the two types may result in the more spastic type of involuntary movements known as athetosis. Extensive destruction of the lenticular nuclei results in rigidity and tremor with a tendency to tonic or clonic spasms and sometimes choreo-athetoid movements (Wilson's progressive lenticular degeneration). The small cells of the neostriatum represent an inhibiting mechanism acting upon the motor globus pallidus. According to this view the palæostriatum was formerly an important center for complicated, generalized and automatic movements. The advent of the discriminative mechanism of the neopallium and its resulting capacity for performing isolated

movements (by the pyramidal system) has necessitated the development of the neostriatal mechanism regulating the older generalized movements. Lesion of the motor pyramidal system results in paralysis of voluntary movements, excessive associated movements and spasticity; lesion of the motor striatal system results in paralysis of associated movements and a generalized rigidity; lesion of the "inhibiting" neostriatum results in the choreiform involuntary movements in some ways similar to the associated movements. It is not to be inferred that lesions elsewhere, *e.g.*, in superior cerebellar peduncle or cortex pallii, may not also produce similar movements. While the above view is open to criticism in certain respects, especially in its neurological explanations, it is still a valuable step in the elucidation of the corpus striatum.

One gap is our defective knowledge of the afferent striatal path or paths. The striatum is a part of the end brain and might well have the same general relation to the thalamus that its outgrowth, the pallium, has. This might furnish a lower thalamo-striate arc acted upon by the pallio-thalamic fibres (pallio-thalamo-striate etc. paths, see paths 20 and 21). Impulses passing along such a path might, when the pallial "inhibition," or regulation or influence (acting on the neo-striatum) is removed, produce the abnormal involuntary movements mentioned above. These are, in a general way, allied to infantile, emotional and associated movements—all movements in which cortical control has not yet been fully developed or is weakened. In this connection it may be recalled that lesions of other portions of the nervous system, *e.g.*, the superior peduncle, may produce such movements and that the cerebellum probably has important thalamic connections. It is also significant that the temporo-parietal pallio-pontile system of fibres arises probably from Flechsig's late myelinating posterior "association" area. The connections and integrations in the region of thalamus, internal capsule, and striatum are so complex that all such suggestions must be regarded as highly speculative.

Injury to the *efferent* pallial path would naturally result in loss or diminution of the movements in question.

14. Transverse Section of Thalamus and Corpora Striata at the Level of the Anterior Commissure. (Fig. 385).

(For the various paths involved see pp. 507–519.)

Efferent Peripheral Neurones.—None are present.

Afferent Roots, their Terminal Nuclei, Secondary Tracts, add Tertiary Neurones.—None of the terminal nuclei of the medial lemniscus and spino-thalamic tracts are present and the thalamic radiations at this level probably only carry indirect sensory impulses to the cortex pallii (see pp. 589 and 591).

Thalamus.—The thalamus shows clearly the division by the fibres of the *lamina medullaris medialis* into the *medial* and *lateral thalamic nuclei.* Fibres from the thalamus, especially the lateral nucleus can be seen accumulated at the lateral border of the thalamus into the lateral medullary lamina, whence they pass as thalamic radiations, through or with the dorsal part of the peduncular fibres of the internal capsule, into the corona radiata. The thalamic radiations at this point constitute a part of the middle or superior thalamic

radiation. Dorsally to the medial thalamic nucleus is seen the *dorsal* or *anterior thalamic nucleus*. Some of its fibres appear to join the thalamic radiation. Fibres can also be seen apparently connecting the medial thalamic nucleus with the globus pallidus and nucleus caudatus. These are fibers of the inferior part of the thalamic radiations connecting with the temporal lobe but also include fibres connecting the thalamus with the corpus striatum. At the boundary

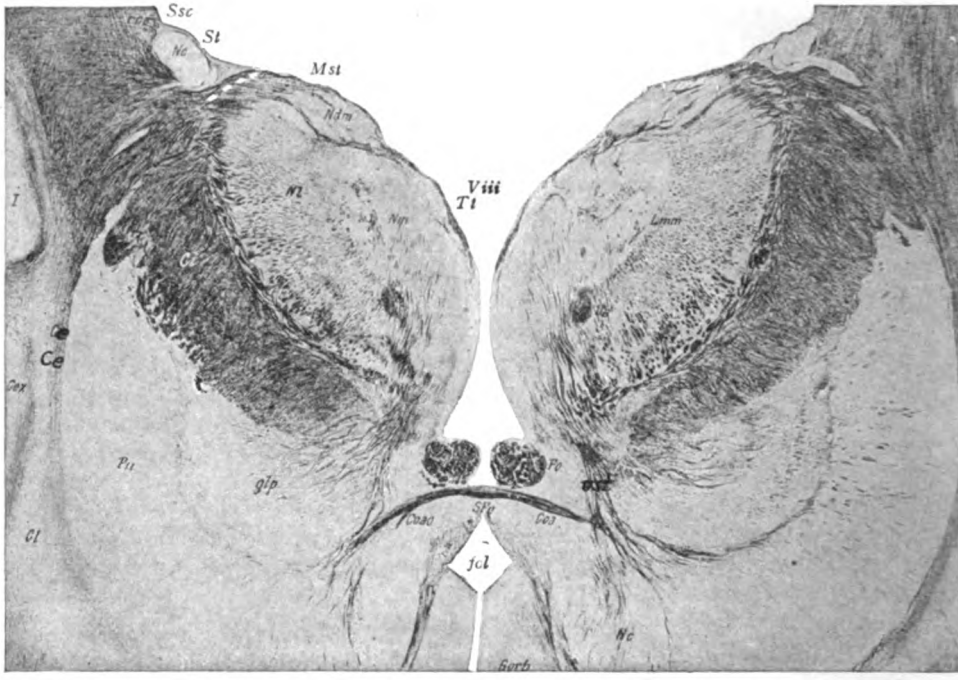

FIG. 385.—Transverse Section of Thalamus and Corpora Striata at the Level of the Anterior Commissure. *Ce*, capsula externa; *Cex*, capsula extrema; *Ci*, capsula interna; *Cl*, *Coa*, commissura anterior; *Coao*, fasciculus olfactorius commissuræ anterioris; *Fo*, fornix (anterior pillar); *fol*, fasciculus olfactorius proprius et hippocampi (olfactory bundle of Zuckerkandl); *glp*, globus pallidus; *Gorb*, gyri orbitales, *I*, insula Reillii; *Lml*, lamina medullaris lateralis; *Lmm*, lamina medullaris medialis; *mst*, radiatio medialis thalamica; *nc*, nucleus caudatus; *Ndm*, nucleus dorsalis magnus thalami (anterior nucleus): *Nl*, nucleus lateralis thalami; *Nm*, nucleus medialis thalami; *Pu*, putamen; *rcc*, stratum reticulatum coronæ radiatæ; *SFo*, fibræ substantiæ perforatæ ad fornicem; *ssc*, stratum subcallosum, subependymale, tapetum; *St*, stria cornea; *Tt*, tænia thalami (and stria medullaris); *Va*, fasciculus mammillo-thalamicus (bundle of Vicq d'Azyr); *VIII*, ventriculus tertius; *vst*, radiatio anterior inferior thalamica.

between the medial and lateral thalamic nuclei is seen the *mammillo-thalamic bundle* (*of Vicq d'Azyr*). In the lateral walls of the third ventricle, just dorsal to the anterior commissure are the *anterior pillars of the fornix* which contain fibres from rhinopallium to mammillary body.

Epithalamus.—The fibres of the stria medullaris near the taenia thalami are still present.

Corpus Striatum.—The lenticular nucleus is now very large and shows clearly the division into globus pallidus and putamen. The caudate nucleus is about the same as in the preceding section. Besides the fibre connections already noted, the *anterior cerebral commissure* is seen, connecting the two corpora striata.

Internal Capsule.—The section passes through the lenticulo-thalamic segment of this important mass of fibres at about the point where the fibres which constituted the middle portion of the pes (pyramidal fibres) are now in the dorsal part of the capsule and are passing into the corona radiata. The ventral (medial) portion at this level consists largely of frontal pallio-pontile fibres. Sections considerably further forward, cephalad to the thalamus, would pass through the lenticulo-caudate segment of the capsule, the head of the caudate nucleus replacing the thalamus. The capsule there consists principally of frontal pallio-pontile fibres and fibres of the anterior thalamic radiation. The fibres connecting corpus striatum and thalamus pass around the medial border of the capsule instead of perforating it as did the fibres from globus pallidus to corpus subthalamicum.

Lateral to the putamen may been seen the *capsula externa*, the *claustrum* (probably detached cortex) and the *capsula extrema* (subcortical white matter). The capsula externa consists of cortical association fibres of claustrum, and insula, commissural fibres from genu and rostrum of corpus callosum, and projection fibres from inner inferior thalamic peduncle.

The Pallium.—The pallium consists of an extensive external convoluted sheet of gray matter (*cortex pallii* or *cortex cerebri*) and of white matter underlying the gray. In the white matter may be distinguished the *corona radiata* composed of the afferent and efferent pallial fibres connecting the pallium with other parts of the brain (*projection fibres*). The remaining fibres of the white matter are *association fibres* of the pallium and are either crossed or commissural, connecting the two hemispheres (*corpus callosum* and *fornix commissure*), or are uncrossed. The term association fibres is often restricted to the uncrossed fibres.

The afferent connections of the neopallium (p. 521) and rhinopallium (p. 601 and path 11) have been summarized and also the efferent connections of the rhinopallium (path 27).

The efferent pallial fibres have already been described (paths 18 to 28). Those fibres going beyond the thalamus (*i.e.*, all except the pallio-thalamic fibres) constitute the *peduncular* fibres which on their course from corona radiata to pes pedunculi pass between the lenticular nucleus externally and either caudate nucleus or thalamus mesially, while others pass caudally or ventrally to the lenticular nucleus. This mass of fibres is also traversed by portions of the thalamic radiations and other fibres representing connections

of the corpus striatum. The above mass of fibres constitutes the important *internal capsule*. That anterior portion lying between the lenticular and caudate nuclei is the *anterior* or *lenticulo-caudate* limb or portion, that portion lying between the lenticular nucleus and thalamus is the *posterior* or *lenticulo-thalamic* portion, those fibres

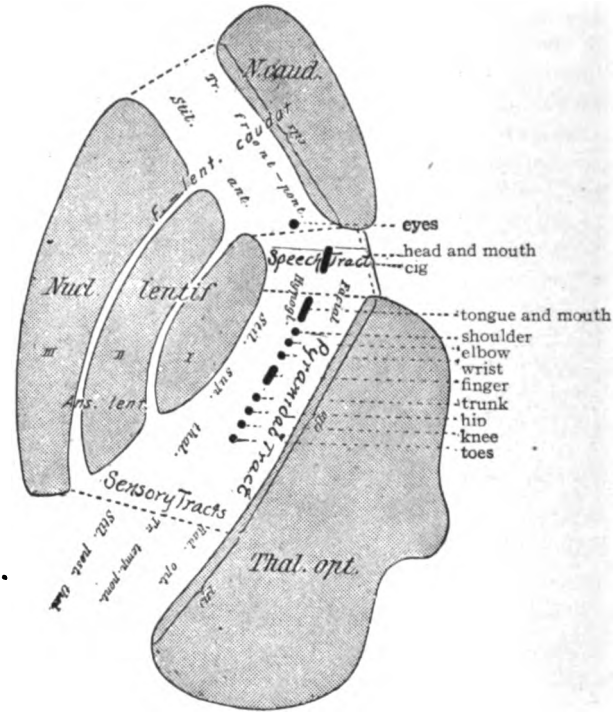

FIG. 386.—Schematic Representation of the Various Segments of the Internal Capsule with the Fibre Tracts. The arrangement of the motor tracts is according to the stimulation experiments of Beevor and Horsley. (Brodmann.) *Thal. opt.*, thalamus opticus; *N. caud.*, nucleus caudatus; *Nucl lentif.*, nucleus lentiformis or lenticularis (segments I, II and III, the latter = the putamen); *cils*, capsula interna, pars lenticulo-caudate; *cig*, capsula interna, pars geniculata; *cilo*, capsula interna, pars lenticulo-thalamica; *cirl*, capsula interna, pars retrolenticularis; *Ans. lent.*, ansa lenticularis; *F. lent. caudat.*, fasciculi lenticulo-caudati; *Rad. opt.*, radiatia optico; *Stil. ant.*, anterior stalk or radiation of the thalamus; *Stil. sup. thal.*, superior radiation of the thalamus; *Stil. post. thal.*, posterior radiation of the thalamus; *Tr. front-pont.*, tractus fronto-pontilis (frontal pallio-pontile fibres); *Tr. temp. pont.*, tractus temporo-pontilis (temporo-parieto-occipital pallio-pontile fibres).

passing caudally to the lenticular nucleus constitute the *retrolenticular* portion and those passing beneath the lenticular nucleus constitute the *sublenticular* portion. The anterior and posterior portions form an obtuse angle, the genu, and this is known as the *geniculate* portion. This portion lies more caudally in the deeper,

more ventral levels of the capsule. The lenticulo-caudate portion (with fibres passing more horizontally) contains anterior thalamic radiation (see thalamic radiations, p. 587) and the frontal pallio-pontile fibres (see path 19*a*, p. 513). It is crossed by fibres connecting the caudate and lenticular nuclei. Its deeper portions are traversed by the anterior commissure and the ansa lenticularis. The geniculate portion contains pallio-nuclear fibres to motor nuclei of cranial nerves (see path 18, p. 512). The lenticulo-thalamic portion contains the pallio-spinal or pyramidal fibres, the superior thalamic radiation, pallio-rubral and pallio-subthalamic fibres. In its caudal portion are the thalamo-pallial fibres of the superior thalamic radiation representing the medial lemniscus radiation ("carrefour sensitif"). The lenticulo-thalamic portion is also crossed by the ansa lenticularis fibres. The retrolenticular portion contains the fibres of the posterior thalamic radiation including the optic radiation (p. 587) (and pallio-collicular fibres) and the acoustic radiation (p. 587). The sublenticular portion, not sharply separable from the retrolenticular portion, contains fibres of the inferior thalamic radiation (temporo-thalamic) and the temporo-parieto-occipital pallio-pontile fibres (see path 19*b*).

The crossed *association fibres of the neopallium* (corpus callosum) connect principally corresponding parts of the hemispheres. The long uncrossed association fibres (furthest from the gray matter) form certain more or less well-defined bundles among which are the following: (1) The cingulum, a longitudinal bundle near the corpus callosum; also contains projection fibres and belongs to the olfactory part of the brain as well as to the neopallium. (2) The superior longitudinal fasciculus or fasciculus arcuatus; connects frontal with occipital and part of temporal lobes. (3) The inferior longitudinal bundle connecting temporal and occipital lobes. It may, however, be a projection bundle. (4) The uncinate fasciculus connecting frontal and temporal lobes. (5) The perpendicular fasciculus of Wernicke connecting inferior parietal and fusiform lobules. Projection fibres may form portions of these bundles.

Besides the above long association fibres there are shorter association fibres nearer the gray matter which connect adjoining convolutions (fibræ propriæ of Meynert).

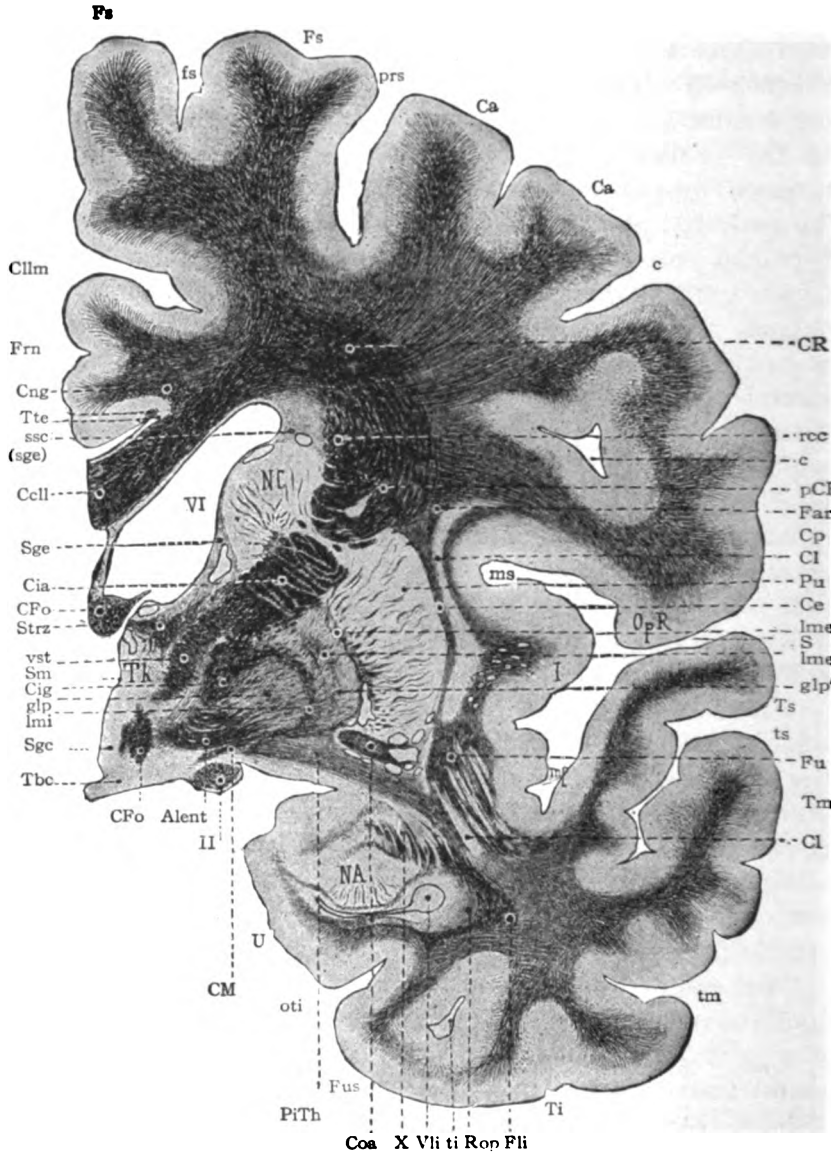

FIG. 387.—**Transverse Section through the Cerebral Hemispheres, Corpora Striata and Thalamus.** Weigert preparation. (Dejerine.) *II*, Tractus opticus; *Alent*, ansa lenticularis; *c*, sulcus centralis (Rolandicus); *Ca*, gyrus centralis anterior; *Ccll*, corpus callosum; *Ce*, capsula externa; *CFo*, columna fornicis; *Cia*, crus anterior capsul. int.; *Cig*, genu capsul. int.; *Cl*, claustrum; *cllm*, sulcus callosomarginalis; *Cng*, cingulum; *Coa*, commissura anterior; *Cp*, gyrus centralis posterior (ascending parietal convolution); *CR*, corona radiata; *Far*, fasciculus arcuatus; *Fli*, fasciculus longitudinalis inferior, *Frn*, gyrus fornicatus; *fs*, sulcus frontalis superior; *Fs*, gyrus frontalis superior; *Fu*; fasciculus uncinatus; *Fus*, gyrus fusiformis; *glp*, globus pallidus (inner segment); *glp'*, globus pallidus (outer segment); *I*, insula; *lme*, lamina medullaris externa nuclei lenticularis; *lme'*, supplementary lamina of the outer segment of the globus pallidus; *lmi*.

PRACTICAL STUDY

15. Transverse Section of the Cerebral Hemispheres, Corpora Striata and Thalamus (Fig. 387)

(For the various paths involved see pp. 507–519.)

First distinguish in general (1) the *pallium*, its cortex and white matter, (2) the *corpus striatum* and its divisions, *i.e.*, the *caudate nucleus* and the *lenticular nucleus*, the latter being subdivided into the *putamen* and *globus pallidus* and (3) the thalamus and other structures of the interbrain.

Afferent Roots, their Terminal Nuclei, Secondary Tracts, and Tertiary Neurones.—The optic tract here forms a part of the ventral surface of the brain. The geniculo-cortical portion of the optic path forming a part of the optic radiation may be seen. Other afferent pallial connections are hardly distinguishable among the fibres connecting thalamus and pallium.

Efferent Suprasegmental Neurones.—A great part of the pes has now entered the corona radiata. The part now about to enter the corona is the anterior limb of the internal capsule (Fig. 386). The *ansa lenticularis* (efferent striatal fibres, see p. 602) is shown. The fibres of the *anterior and inferior radiations of the thalamus* are evident (p. 587). The *anterior pillars of the fornix* (efferent rhinopallial) are shown cut through twice, the upper section shows its earlier course emerging from the fimbria, the lower section is near its termination in the mammillary body.

For other structures of thalamus, epithalamus, and hypothalamus see Fig. 387.

The Pallium.—In the white matter distinguish as far as possible the *corona radiata*, the *corpus callosum*, and the long association bundles (*inferior longitudinal fasciculus*, *fasciculus uncinatus*, and *fasciculus arcuatus*) (see p. 607). Note the *nucleus amygdalæ*, the *anterior perforated space* and the *anterior commissure*, belonging to the rhinencephalon. For *cerebral cortex*, see below.

The other details shown in Fig. 387 should be studied.

The Cerebral Cortex

The following types of cells are found in the cerebral cortex: (1) *Pyramidal cells.* This is the prevailing type and is characterized by a long apical dendrite usually directed toward the surface of the

---

lamina medullaris interna nuclei lenticularis; *mp* and *ms*, sulcus circularis (Reili); *NA*, nucleus amygdaliformis; *NC*, nucleus caudatus; *OpR*, operculum; *oti*, sulcus occipitotemporalis inferior; *pCR*, pes coronæ radiatæ; *PiTh*, pedunculus inferior thalami; *prs*, sulcus præcentralis; *Pu*, putamen; *rcc*, stratum reticulum coronæ radiatæ; *Rop*, radiatio optica; *S*, fissura Sylvii (posterior branch); *Sgc*, substantia grisea centralis; *Sm*, sulcus Monroi; *Sge*, substantia grisea subependymalis; *ssc*, stratum subcallosum: *Strz*, stratum zonale thalami; *Tbc*, tuber cinereum; *Th*, thalamus opticus; *ti*, sulcus temporalis inferior; *Ti*, gyrus temporalis inferior; *tm*, sulcus temporalis medius; *Tm*, gyrus temporalis medius; *ts*, sulcus temporalis superior; *Ts*, gyrus temporalis superior; *Tte*, tænia tecta; *U*, uncus; *Vl*, ventriculus lateralis; *Vli*, ventriculus lateralis (cornu inferius); *vst*, pedunculus anterior thalami; *X*, pedunculus putaminis; *CM*, Commissure of Meynert.

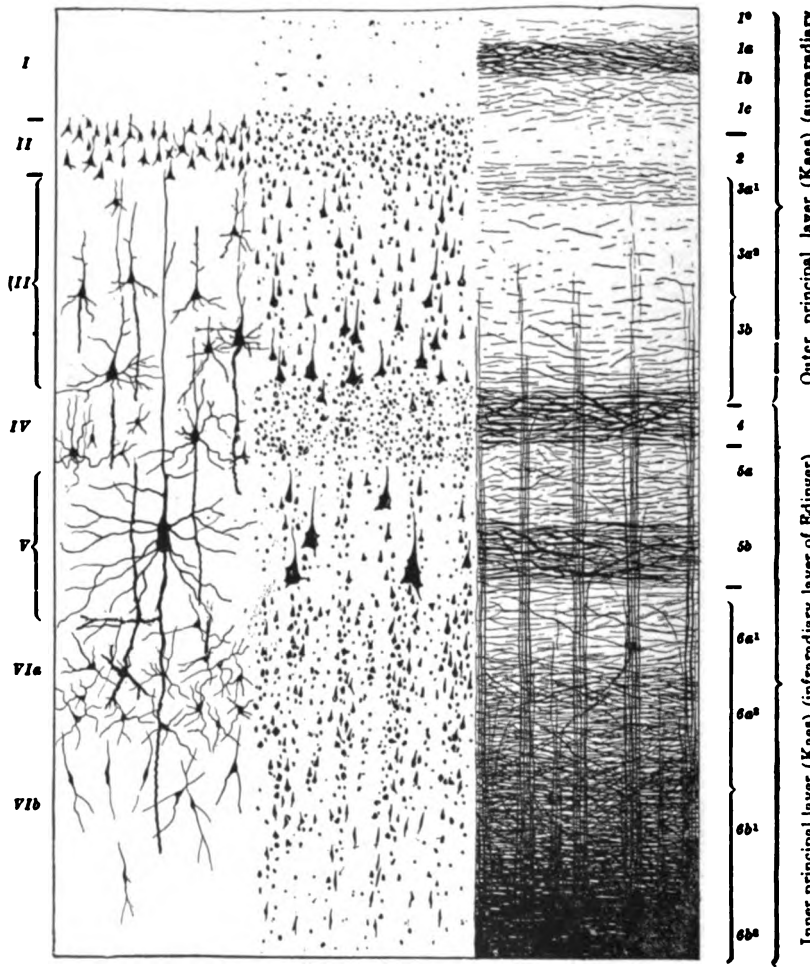

FIG. 388.—Relation of the Cell and Fibre Layers of the Human Cerebral Cortex. Schematic. Combined from (*a*) Golgi, (*b*) Nissl and (*c*) Weigert pictures. (Brodmann, slightly modified).

Cell Layers (Brodmann): *I*, Lamina zonalis; *II*, lamina granularis externa; *III*, lamina pyramidalis (small, medium and large sublayers); *IV*, lamina granularis interna; *V*, lamina ganglionaris; *VI*, lamina multiformis: *VIa*, sublamina triangularis; *VIb*, sublamina fusiformis.

Medullated fibre Layers (O. Vogt): 1, Lamina tangentialis; 1°, pars supratangentialis (afibrosa) laminæ tangentialis; 1*a*, pars superficialis lam. tang.; 1*b*, pars intermedia lam. tang.; 1*c*, pars profunda lam. tang.; 2, lamina dysfibrosa; 3, lamina suprastriata; 3*a*, pars superficialis lam. suprastr., 3*a*¹, stria Kaes-Bechterewi; 3*a*², pars typica lam. suprastr. (or pars intermedia); 3*b*, pars. profunda lam. suprastr.; 4, stria Baillargeri externa; 5*a*, lamina interstriata; 5*b*, stria Baillargeri interna; 6, lamina infrastriata; 6*a*¹, lamina substriata; 6*a*², lamina limitans externa; 6*b*¹, lamina limitans interna; 6*b*², lamina corticalis albi gyrorum.

brain. This dendrite gives off branches, and usually reaches the outer cortical layer, there to break up into a number of branches. From the cell body are also given off a number of basal dendrites. By the Golgi and Ehrlich methods, gemmules can be demonstrated

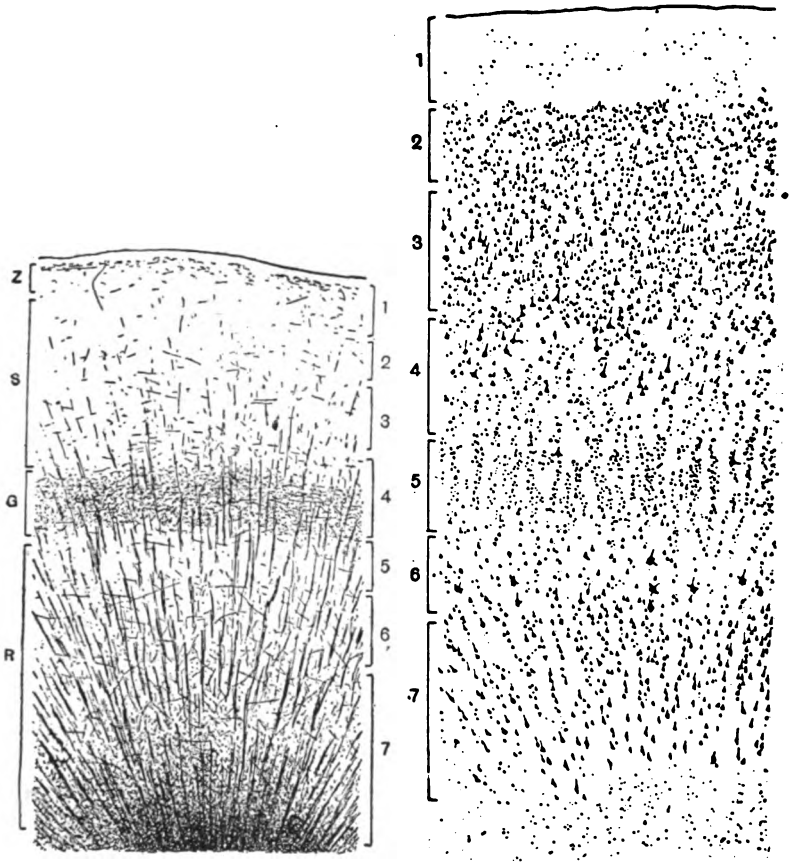

FIG. 389.—Vertical Sections of Calcarine Area of Adult Human Cortex. *Left.* Weigert preparation showing fibre arrangement. *Right,* Arrangement of Cells. (Campbell.) *G*, Line of Gennari; *R*, radiary layer; *S*, supraradiary layer; *Z*, Layer of superficial tangential fibres in molecular layer; 1, zonal layer; 2, external granular (small pyramid) layer; 3, pyramid layer; 4, (large granules) and 5 (small granules), internal granular layer; 6, ganglionic layer (containing solitary cells of Meynert); 7, multiform layer.

on the dendrites. The axone proceeds from the base of the cell (opposite to the apical dendrite) and usually passes into the white matter. It gives off several collaterals on its way to the white matter. (2) *Stellate cells.* These have dendrites passing in various

directions. Many, especially the smaller (granules), may have short axones (Golgi's second type). (3) *Polymorphous cells* of a triangular or spindle shape are usually found in the deepest layers of the cortex and send their axones into the white matter. (4) *Horizontal cells* (of Cajal), found in the outer layer, with long horizontal dendrites and axones confined to the outer layer. (5) *Inverted pyramidal cells* (of Martinotti) with axones directed toward the surface. (Fig. 390.)

The largest cells of the cortex (giant cells of Betz) are very rich in chromophilic substance arranged similarly to that in the efferent root cells of cord and brain. The medium and small cells have fewer chromophilic bodies which are often in the shape of irregular masses, either near the periphery of the cell or around the nucleus. The neurofibrils vary in their arrangement according to the shape of the cell.

The neuroglia cells and fibres are in general similar to those in other parts of the nervous system.

The cells of the cortex are arranged in layers which have the same general character throughout, but in various regions exhibit variations such as suppression, diminution, enlargement, or subdivision of certain layers. The cell layers of the cortex are: (1) *Zonal layer* (molecular layer, plexiform layer of Cajal). This contains the horizontal cells, other cells with short axones, and also receives the axones of the Martinotti cells. Besides this, it contains the terminal branches of the apical dendrites of the pyramidal cells. (2) *External granular layer*, very often termed the layer of small pyramids. The dendrites of the cells of this layer mostly enter the first layer, their axones pass downward into the white matter. (3) *Pyramidal layer*, often called the layer of superficial medium and large pyramids. This is composed principally of typical pyramids sending dendritic branches into the first layer and axones into the white matter. The larger cells are in the deeper part (sublayer of large pyramids). This layer also contains many granule cells with short axones and cells of Martinotti, (4) *Internal granular layer*. Here the predominating elements are stellate cells, the larger usually sending their axones into the white matter. Among these are many short axone granules, the axones of which end in the same layer or in more superficial layers. (5) *Ganglionic layer* or deep layer of large and medium sized pyramids. These send their axones into the white

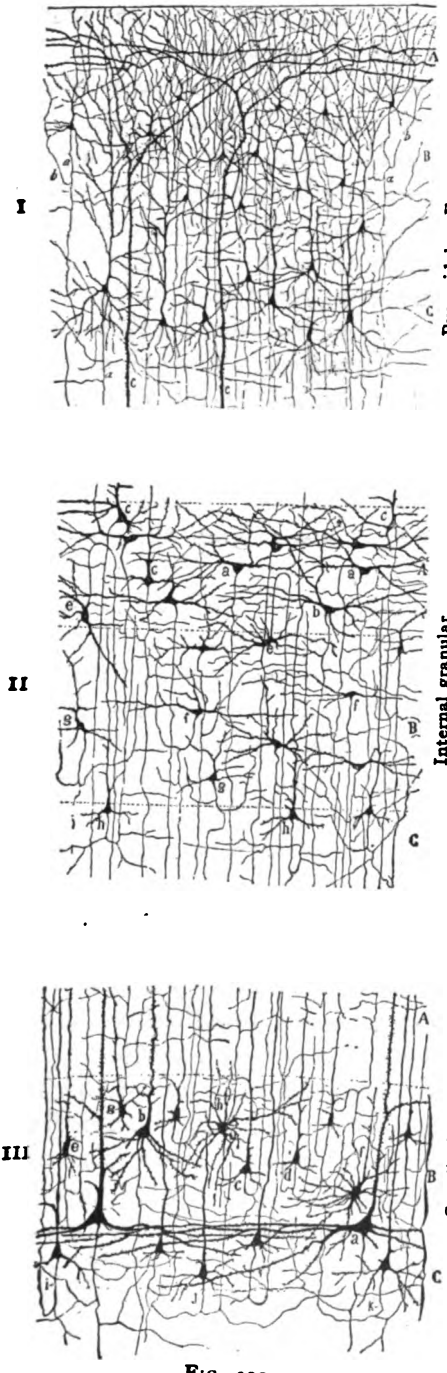

FIG. 390.

matter. Mingled with them are short axone and Martinotti cells. (6) *Multiform layer* or layer of polymorphous cells. These usually send their axones into the white matter. This layer is subdivided into the triangular and fusiform sub-layers according to the shape of the

---

FIG. 390.—Vertical section of Calcarine Area of Cortex of an Infant 15–20 days old. (Cajal, combined from three, *I*, *II*, and *III*, somewhat overlapping figures. The multiform layer is not included). Golgi's method.

I.—*A*, Zonal layer; *B*, external granular layer (of small pyramids); *C*, pyramidal layer (of medium pyramids); *a*, descending axones; *b*, ascending collaterals; *c*, apical dendrites of large pyramidal cells in ganglionic layer.

II.—*A*, Sublayer of large stellate cells; *B*, sublayer of small stellate cells; *C*, outer part of ganglionic layer; *a*, crescentic stellate cells; *b*, and *f*, horizontal, spindle-shaped stellate cells; *c*, medium-sized pyramidal cells; *e*, stellate cells with arched axones; *g*, triangular stellate cells with stout, arched collaterals; *h*, pyramidal cells with arched axones.

III.—*A*, Part of internal granular layer; *B*, sublayer of small pyramidal cells with arched ascending axones; *C*, sublayer of large pyramids; *a*, large pyramidal cell; *b*, medium-sized pyramidal cell with long descending axone; *c*, small pyramidal cell with arched ascending axone; *d*, pyramidal cell with axone split into two arched ascending branches; *e*, pyramidal cells whose axone sends out various ascending branches; *f*,*g*,*h*, stellate cells with ascending axones which branch in *B* and in the sublayer of small stellate cells; *i*, *j*, *k*, pyramidal cells with arched ascending axones which send branches into the ganglionic layer.

cells of which they are composed. Mingled with them are short axone and Martinotti cells. (Figs. 388, 389, 390 and 391.)

Each of the above layers, as mentioned above, may vary in different regions in its thickness and in the spacing (density), size and arrangement (regular, irregular, radial) of the cells composing it. Using these criteria, a number of areas have been distinguished from about twenty (Campbell) to about fifty (Brodmann) or even two hundred (C. and O. Vogt). In certain areas there may be a diminution in the number of layers, due to disappearance or fusion of layers, or an increase in the number of layers through a division of one or more layers. Such areas are termed *heterotypic* (Brodmann) as opposed to the six-layered *homotypic* cortex. The most important example of heterotypic areas are the calcarine type (area striata, "visual" or visuo-sensory cortex, see Figs. 392 and 389), characterized especially by a subdivision of the internal granular layer into three sublayers; the gigantopyramidal type (precentral, "motor" area, see Figs. 392 and 391), characterized by the presence of the giant cells of Betz in the ganglionic layer and the absence of the internal granular layer (agranular type); the agranular frontal type, anterior to the preceding (corresponding to the greater part of the intermediate precentral, Fig. 392) and characterized simply by the absence of the internal granular layer. The insular cortex (island of Reil) has a division of the multiform layer into three sublayers, an inner layer (claustrum) being separated from the rest of the cortex by the fibres of the capsula extrema (increase of layers). Besides this the insular cortex is divided by practically a continuation of the central fissure (of Rolando) into an anterior agranular and a posterior granular portion (Brodmann). The numerous cortical areas above alluded to may be combined into the following principal zones (Brodmann): A frontal region (corresponding to the prefrontal and frontal, Fig. 392, I and II), an inferior frontal subregion (the inferior frontal portion of the intermediate precentral Fig. 392, I and II), a precentral (corresponding nearly to the precentral and intermediate precentral, excepting the inferior frontal portion, Fig. 392, I and II), a postcentral (postcentral and intermediate postcentral), a parietal, an occipital, an area striata (visuo-sensory), a temporal, a supratemporal (audito-sensory and auditopsychic, approximately), an insular, a cingularis (limbic), a hippocampal (olfactory) and a retrosplenial (*B*, Fig. 392).

In the above, the layers and areas of the cortex have been distinguished on the basis of the arrangement, etc. of the nerve cell bodies (cytoarchitecture). Instead, the direction, number and size of the medullated or myelinated nerve fibres may be used as a basis (myeloarchitecture). According to their direction the fibres of the cortex fall into three classes, the *radiary fibres* running vertically to the periphery of the cortex, usually in bundles (radiations of Meynert, the *tangential* or *horizontal fibres* running approximately parallel with the periphery and *oblique fibres*. The latter may be regarded as belonging to the same category as the radiary fibres, produced by the bending of some of the latter. *Single* fibres often stand out, on account of their greater size, from the general mass of fibres. According to the varying number and sizes of the radiary and horizontal fibres, the following layers may be distinguished (C. and O. Vogt) (Fig. 388):1, The *tangential layer*, corresponding to the zonal layer and consisting of superficial tangential fibres and subdivided into several sublayers. 2, The *dysfibrous layer*, so named on account of its poverty of medullated fibres. This layer corresponds to the external granular layer. 3, The suprastriate layer, subdivided into several sublayers and often containing in its outer or superficial part a greater number of tangential fibres, constituting the band of Kaes-Bechterew. This layer corresponds to the pyramidal layer. 4, The *layer of the external band of Baillarger*, characterized by its greater number of tangential fibres. These produce the horizontal white streak or stripe (stria) visible in sections of the fresh brain even to the naked eye. This layer corresponds to the internal granular layer. 5, This layer is composed of the *inter-* or *intrastriate* sublayer and the *internal band of Baillarger*. This layer corresponds to the ganglionic layer. 6, The *infrastriate layer*, below the above striae, is subdivided into several sublayers.

The radiations may end at various levels, or in various layers, of the cortex and several cortical types may be distinguished according to these variations (C. and O. Vogt). They usually terminate at the boundary between the intermediate and deep sublayers of the pyramidal layer. This type is termed the euradiate or medioradiate type. In some parts of the cortex the radiations may only reach the outer part of the internal band of Baillerger (infraradiate type) or they may reach the dysfibrous or even the zonal layer (supraradiate type). Cortical areas may be further characterized according to the number of sublayers which can be distinguished in the zonal

layer, as bizonal, trizonal or quadrizonal. They may be further characterized, according to relations of the striæ of Baillarger, as bistriate (two striæ), unitostriate (one broad stria due to the fusion of the two striæ), unistriate (only the external stria present) and the astriate types. Further distinctions are based upon the thickness, number (density), arrangement and size of the fibres composing each layer.

The myeloarchitectural cortical areas distinguished in this way appear to coincide fairly well in many cases with the cytoarchitectural areas. As mentioned above, by some investigators (C. and O. Vogt) as many as two hundred areas have been distinguished by these two methods. The attempt has been made (C. and O. Vogt), using refined methods of electrical cortical stimulation in apes, combined with partial isolation of various regions, to ascertain whether these correspond to physiological areas. The results obtained by stimulation of the precentral ("motor") area are well known but these further investigations appear to yield results showing functional differences in non-motor areas corresponding to some of the principal areas alluded to above.

Comparing with the results obtained by the method of Golgi, it would appear that the radiations are composed principally of the axones of the pyramidal cells in that part of the cortex. The horizontal fibres of the zonal layer appear to be the axones of the horizontal cells of the layer itself and terminals of cells whose bodies are located more deeply, especially the cells of Martinotti. Many of the terminals of axones from cell bodies located elsewhere are probably oblique fibres and, according to some authorities (Cajal), the band of Baillarger is especially rich in these terminals of fibres from the white matter. The collaterals of the axones of the cells in the locality probably furnish many of the tangential and oblique fibres.

Another method by which cortical areas have been distinguished is the myelogenetic method of Flechsig (method VI, p. 622) in which the criterion is the order of myelination. The myelogenetic areas of Flechsig do not entirely agree with the adult cytoarchitectural and myeloarchitectural areas of other observers and it appears probable from the observations and criticisms of others that the myelogenetic process is one of continuous differentiation and therefore does not exhibit the discontinuous areas shown in the cell and fibre arrangements of the developed cortex. It is agreed, however, that

myelination begins in the primary motor (precentral) and sensory (postcentral, calcarine, superior temporal and rhinopallial)areas and spreads from these centers (see below).

All cells of the cortex obviously fall into two classes: *efferent projection cells* and *association cells*. Which cells are projection cells is not definitely known, except in the case of the precentral motor cortex where it has been established that these cells are the cells of Betz, the axones of which form the pyramidal tracts and the fibres to motor cranial nerve nuclei. An examination of this area shows that the association cells must enormously outnumber the efferent projection cells in the cortex. The association cells comprise the short axone cells and cells the fibres of which enter the white matter, but terminate in some other part of the cortex, forming the association fibres of the white matter. (Compare p. 605).

It is thus evident that every part of the cortex contains terminations of association fibres. The areas containing the terminations of afferent projection fibres are those which receive the thalamocortical continuations of the afferent pallial paths and the continuations of the olfactory paths. From observations made with the Golgi method it seems probable that the afferent projection fibres are coarse fibres which may ramify throughout the greater part of the thickness of the cortex, but are confined mainly to the third and fourth layers. The principal areas of the cortex receiving the afferent projection fibres are the hippocampal area (olfactory), the calcarine area (visual, fibres from lateral geniculate body), the transverse temporal gyri of Heschl (auditory, fibres from medial geniculate body), and the pre- and postcentral areas (only postcentral, according to some authorities, area of general sensation from body and head, fibres from ventrolateral thalamic nuclei). (Fig. 392.)

According to Flechsig, certain temporo-parietal and frontal areas which myelinate last are not connected directly with other parts of the brain by projection fibres and are to be regarded as purely association areas. While it is true that the primary afferent (sensory) and efferent (motor) projection areas above enumerated only occupy a small portion of the cortex, the other portions of the cortex are by no means destitute of projection fibres, for there still remain to be accounted for the afferent projection fibres of the more diffuse thalamo-cortical radiations and the efferent projection fibres to thalamus, pons and probably to a number of other structures (see paths 18 to 28 and p. 587). It is probable, in fact, that the late myelinating

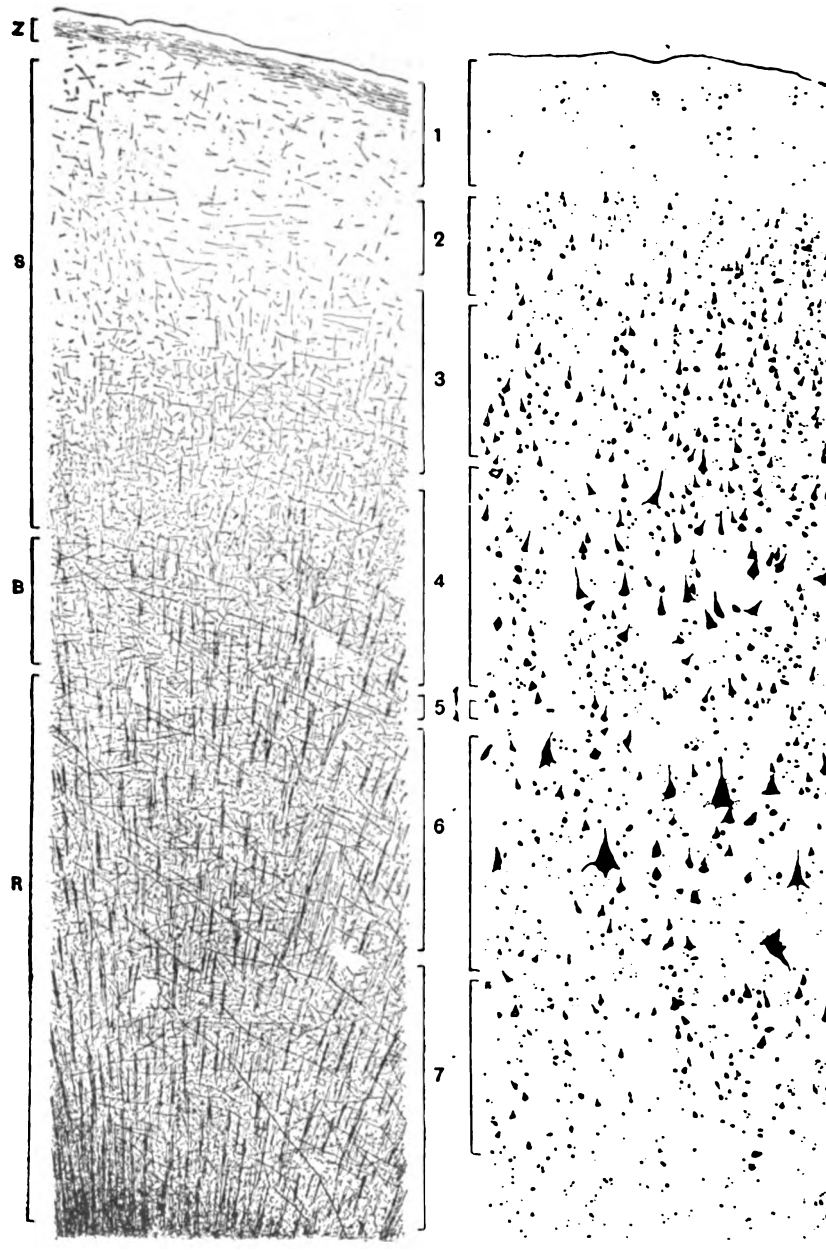

FIG. 391.—Vertical Sections of Precentral or Motor Area of Adult Human Cortex. *Left*, Weigert preparation showing fibre arrangement. *Right*, Arrangement of cells. (Campbell.) *B*, Position of line of Baillarger, its position obscured by surrounding wealth of fibres; *R*, radiary layer; *S*, supraradiary layer; *Z*, layer of superficial tangential fibres in molecular layer, dense and well defined; 1, zonal layer; 2, external granular layer (small pyramids), 3 (medium-sized) and 4 (large), pyramid layer; 5, internal granular layer, indistinct and with scattered granule or stellate cells; 6, ganglionic layer (large, deep pyramids); 7, multiform layer.

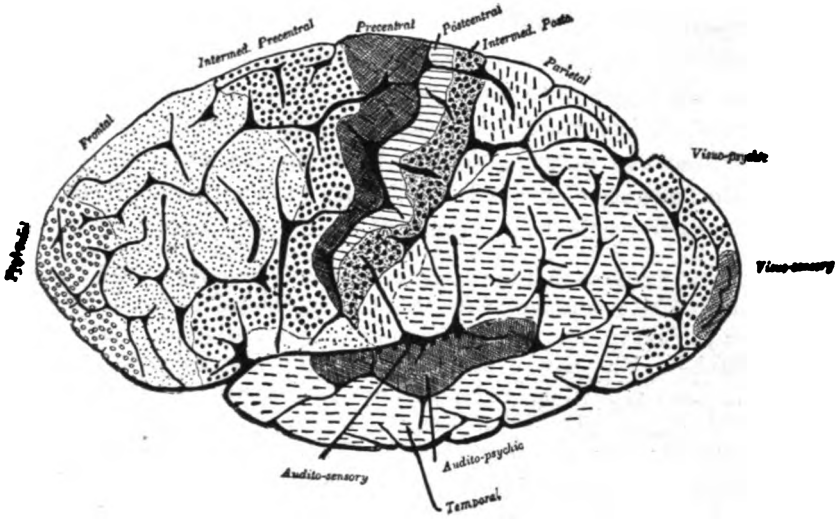

I

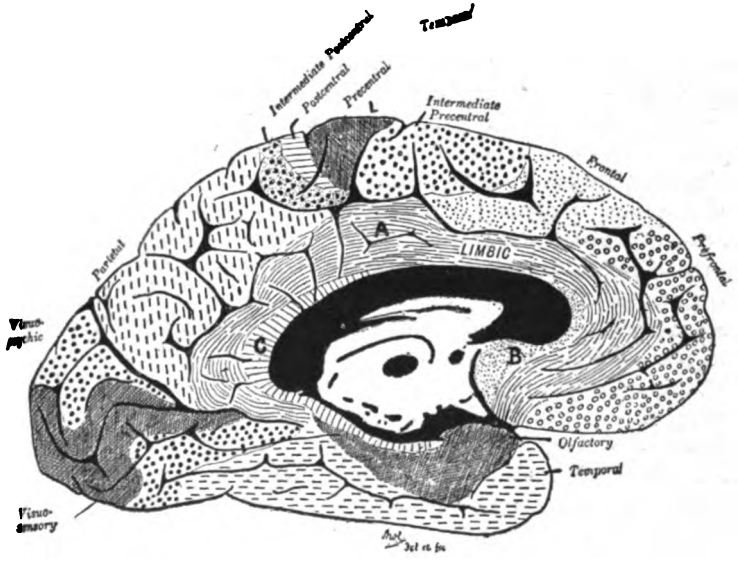

II

FIG. 392.—Diagram (orthogonal) showing Cortical Areas as determined by the Arrangement and Distribution of Fibres and Cells (A. W. Campbell). Large portions of important areas are concealed within fissures, *e.g.*, the calcarine or visual (*visuo-sensory*, within the calcarine fissure) *precentral* (motor) and *postcentral* (within the fissure of Rolando) and especially the acoustic (*audito-sensory*) which is almost completely hidden within the Sylvian fissure. *A*, *B* and *C*, parts of the limbic lobe.

temporo-parieto (-occipital?) pallio-pontile fibres originate in Flechsig's posterior (parieto-temporal) association area which suggests the probability that the frontal pallio-pontile system may originate from a part at least of his anterior (frontal) association area. In spite of these and other criticisms, however, the order of cortical myelination as above outlined is evidently both very important and suggestive as to cortical functions and their development.

The general significance of the pallium has already been mentioned (p. 520) and also the general significance of the thalamus in securing the proper coöperation of the pallium in carrying out the fundamental, instinctive, visceral and bodily impulses. The nature of the complicated associative mechanisms involved in language reactions and mental processes cannot be dealt with here. It seems reasonable to suppose that the areas in the neighborhood of the primary sensory areas are those containing especially the associative systems involved in the recognition of the nature of the impulses received by the primary areas when repeated, and that longer association neurones secure the coöperation of other sensory mnemonic areas. The importance of previous proprioceptive stimuli in the building up of skilled acts by association of the motor pyramidal system with conscious motor images or unconscious motor memories has been referred to (p. 520). While area localization on this basis becomes less possible in the more general diffuse, conscious pallial activities, it must be remembered that each reaction insomuch as it differs from others must require a somewhat different cortical activity. The question of layer localization also must be kept in mind. The external granular and external pyramidal layers are the youngest layers, the deeper layers the older, and it has been suggested that the latter especially deal with the more fundamental instinctive reactions.

The question of cerebral localization is obviously closely connected with the nature of thalamic localization and the relations of thalamus to pallium.

On the efferent side the pyramidal system is so important in carrying out the characteristic pallial voluntary acts that sight is lost of the fact that the voluntary act is always a group of muscular contractions which alter a previously existing posture or pose. Lesions undoubtedly cortical and non-pyramidal, or only slightly so, result in tonic muscular changes. The efferent path for this cortical regulatory influence is not definitely known but *a priori* considerations and certain clinical and physiological observations point to the massive pallio-ponto-cerebellar path as being involved. Whether the olivary connection may prove to represent another pallio-cerebellar control is not known. Besides this there are also cortical (emotional) activities (and sometimes cortical irritations) which find an outlet, partly at least, in movements of a non-pyramidal character, and also changes in the involuntary musculature of viscera, blood-vessels and heart and in the secretory apparatus. This outlet most probably, it would seem, would be by a portion at least of the cortico-thalamic system. This has been regarded as inhibitory but it would appear probable that it is also regulative in function. Many of the associated movements have to do with emotional states, nor are the choreo-athetoid movements very dissimilar. They are in turn similar to the generalized infantile movements before associative-

memory pyramidal and pallio-cerebellar control is established. It is possible that a portion at least of this path is *via* the cortico-thalamo-pallidal path suggested above.

As a result of the above, if we view the cortex on the efferent side, there should emerge from it at least three streams of impulses, one which actively contracts groups of muscles in such a way as to produce definitely limited, purposeful, skilled acts; another which acts upon the general postural, tonic muscular mechanism; and a third which regulates the affective, including splanchnic, as distinguished from discriminative, reactions. The first would be largely the pyramidal system, the second largely the pallio-ponto-cerebellar, and the third the cortico-thalamic. The coöperation of all three is probably necessary for the properly balanced and properly executed pallial reaction.

GENERAL METHODS USED IN THE INVESTIGATION OF THE ARCHITECTURE OF THE NERVOUS SYSTEM

While the special methods of fixing, staining, etc. are described elsewhere, there are more general methods used especially in the analysis of the nervous system which may be better presented here.

I. Dissection or Dissociation.—Teasing apart the larger bundles of fibres and masses of gray in the nervous system. This was a method early employed. It obviously cannot give insight into the finer relations but gives the larger relations.

II. Comparison of Serial Sections.—Here various structures are followed in section after section. Microtomes have made this method of very great value but it obviously has to be combined with various of the methods mentioned below.

III. Reconstruction of Serial Sections.—This is usually done by putting together wax or glass plates on which the structures (bundles of fibres, masses of gray, etc.) have been cut out or drawn.

IV. Stained Sections.—By selective stains certain structures are brought out more clearly. Some of these stains are (*a*). *The chrome-silver method* of Golgi which displays in black individual nervous elements with their finest processes. Fibres cannot be followed far but the shorter connections between individual neurones can be ascertained. (*b*) *The intra vitam methylene blue method of Ehrlich.* This gives similar results to (*a*). It is less useful in the central nervous system but very useful for nerve terminations. (*c*) *The neurofibrillar silver methods of Cajal and of Bielschowsky.* These give pictures of neurofibrils and also very good pictures of individual neurones, not showing ultimate ramifications as (*a*) but more uniform. (*d*) *The myelin stain of Weigert.* This is a hæmatoxylin stain of the myelin sheaths alone. It is a very precise method and probably in use more than any other. It is used to trace the course of myelinated fibres but, naturally, does not give their connections with neurone bodies. (*e*) *The method of Marchi.* This is an osmic stain of degenerating myelin. Fibres undergoing secondary degeneration can be followed for the whole of their course. (*f*) *The method of Nissl.* This stains the chromatin of the nucleus and the chromophilic substance in the cytoplasm of the neurones.

It is used to study pathological cell changes and may be used to ascertain thereby what cells are connected with fibres which may be experimentally or accidentally injured. All these methods may of course be combined with II and III. There may also be mentioned Weigert's glia stain which stains neuroglia fibres and the gold chloride methods of staining nerve endings.

V. Comparative Anatomy.—This has a number of applications. The correlation between the development of various sense organs or effectors and their nerves and central connections may be studied. The progressive development of certain parts of the nervous system, *e.g.*, the pallium, and the correlated development of other parts in especial connection with it may be studied; also the simpler nervous systems of lower forms aids in the comprehension of the more complicated higher nervous systems. Combined with I, II, III and IV.

VI. Embryological Method.—The study of the simpler embryonic nervous system and its development aids in understanding the adult. It is especially interesting when its results are compared with those obtained by IV. A special application is the myelogenetic method of Flechsig which consists in the study of the order of myelination of the various systems of myelinated fibres. In this way these systems can be distinguished. Weigert's myelin stain is used. V is combined with II, III and IV.

VII. Arrested Development or Atrophy (*von Guden's Method*).—This depends upon the fact that when a sense organ or nerve or part of the nervous system is removed in a young animal the parts connected with it either do not develop or diminish in size. This is not limited to the neurones directly injured. Combined with I, II, III and IV.

VIII. Secondary Degeneration.—This depends upon the fact that when a nerve fibre is cut, the part cut off undergoes secondary degeneration and the neurone body undergoes certain changes. By applying the Marchi stain to the former (in the proper stage of degeneration) a myelinated fibre can be traced. By applying the Nissl stain to the latter the cell body connected with the cut fibre can be identified. Degenerating axones can sometimes be identified by using the Cajal or Bielschowsky silver stains or gold chloride. This is usually combined with II also.

IX. Experimental Physiological Method.—(*a*) Stimulation of a part, *e.g.*, nerve or nerve center and observation of result. A reaction establishes the existence of *some* anatomical path. (*b*) Extirpation of a part and observation of consequent loss of function.

X. Pathological Physiological Method (*Clinical Autopsy Method*).—This consists in observation of disturbances of nervous function during life and of the pathological changes after death has occurred. It differs from IX in that the changes are here not experimentally produced. IX has the advantage that the changes can be made as desired, X has the advantage that it can be applied to human beings and the more precise language reactions enable us to make observations, *e.g.*, many sensory phenomena, which could not be made on animals. Likewise there are many important forms of nervous disturbance in man which are not present in other forms. Accidents are of course also available. IX and X may be combined with I, II, III and IV.

XI. Embryological Physiological Method (*von Bechterew*).—This consists of the application practically of IX to embryonic or very young animals. It can be correlated with the myelogenetic method.

SPECIAL TECHNIC

(1) The general structure of the cerebellum is well brought out by staining sections of formalin-Müller's fluid-fixed material with hæmatoxylin-picro-acid-fuchsin (technic 3, p. 24), and mounting in balsam.

(2) The arrangement of the cell layers of both cerebellum and cerebrum as well as certain details of internal structure of the cells, can be studied in sections of alcohol- or formalin-fixed material stained by the method of Nissl (technic, p. 39).

(3) The distribution of the medullated nerve fibres of either the cerebellar or cerebral cortex is best demonstrated by fixing material in Müller's fluid (technic 4, p. 7) or in formalin-Müller's fluid, and staining rather thick sections by the Weigert or Weigert-Pal method (technic, p. 33)

(4) The external morphology of the cerebellar and cerebral neurones and the relations of cell and fibre can be thoroughly understood only by means of sections stained by one of the Golgi methods (technic, pp. 36 and 37). Especially in the case of the cerebellum, sections should be made both at right angles, and longitudinal to the long axis of the convolution. Golgi preparations from embryonic material and from the brains of lower animals furnish instructive pictures.

(5) The silver method of Cajal should be used, especially with alcohol fixation (technic p. 39, No. 2), both for the neurofibrils and for the external morphology of the neurones. It is especially successful with the cerebellum.

(6) Neuroglia stains should also be used.

Table of Cranial and Spinal Nerves.

Nerve	Cells of origin	Distribution of peripheral processes	Cent. processes (root fibres and central tracts)	Terminal nuclei	Axones of terminal nuclei (secondary tracts) and their distribution	Tertiary tracts
I. Olfactorius.	Olfactory epithelial cells.	.....	Fila olfactoria.	Cells in bulbus olfactorius.	Tractus olfactorius, to various parts of rhinencephalon.	To rhinopallium.
II. Opticus.	Ganglion cells of retina.	.....	Nervus and tractus opticus.	Colliculus superior.	Tractus colliculo-bulb. et spin., fasc. long. med. to motor nuclei cerebro-spinal nerves (reflex).	
				Corpus geniculatum externum.	Optic radiations to occipital cortex cerebri.	
				Pulvinar thalami.....	Optic radiations to occipital cortex cerebri. (?)	
III. Oculomotorius.	Nucleus nerve III in midbrain.	4 eye musc., levator palpebræ sup., and radix brevis gang. ciliaris.				
IV. Trochlearis.	Nucleus nerve IV in midbrain.	Mus. obliquus superius.				
V. Trigeminus.						
(*a*) afferent.....	Ganglion Gasseri	Rami ophthal. max. and mandib. to skin of head and face, epithelium of mouth and nose, teeth, meninges.	Tractus spinalis V.	Sensory nucleus V and nucleus tractus spinalis (substan. gelat. Rolandi.	To motor nuclei (reflex). Uncrossed tract in dorsal part formatio reticularis to thalamus. Crossed tract *vis* lemniscus to thalamus..... ... To cerebellum?	Thal. rad. to cent. cortex cerebri. Thalamic radiations to centra cortex cerebri.
	Mesencephalic nucleus.	Muscle-tendon receptors of muscles of jaw.				
(*b*) efferent.....	Motor nucleus V.	Muscles of jaw, etc., (massetericus, temporalis, pterygoideus, digastricus, tens. veli pal., tens. tympani, mylohyoideus).				
VI. Abducens...	Nucleus VI in medulla.	Musc. rectus lateralis.				
VII. Facialis.						
(*a*) efferent.....	Nucleus VII in medulla.	Musc. of face, tymp., pinna, digast., stylohy.				
(*b*) afferent.....	Gang. geniculi....	Ant. part of tongue (taste), palate.	Fasc. solitarius	Nucleus fasciculi solitarii.	Not precisely known.	
VIII. Acusticus.						
(*a*) vestibularis.	Gang. of Scarpa..	Ampullæ semicirc. canals, utriculus, sacculus.	Tractus vestib. spinalis.	Nucl. tract. vestib. spinalis. Nucleus medialis ("principal"). Nucleus lateralis (Deiters'). Nucleus superior (von Bechterew's).	Crossed asc. in med. long. fasc. to midbrain and nucl. nerves VI, IV, and III (reflex). Crossed and uncrossed desc. in med. long. fasc. to vent. col. cord and motor spinal nerves (reflex). Uncrossed to ventro-lateral cols. cord and motor spinal nerves (reflex) (from Deiters'). Uncrossed to midbrain and nuclei nerves VI, IV, and III (reflex) (from von Bechterew's).	
				Cerebellum.....	Fastigio-bulbaris to Deiters', etc. (reflex).	

Table of Cranial and Spinal Nerves. Continued.

Nerve	Cells of origin	Distribution of peripheral processes	Cent. processes (root fibres and central tracts)	Terminal nuclei	Axones of terminal nuclei (secondary tracts) and their distribution		Tertiary tracts
(*b*) cochlearis...	Gang. spiralis....	Organ of Corti.....	.....	Nucl. accessorius.....	Corpus trapezoid. (collaterals to nucl. oliv. sup. [reflex]), crossing, forming lemniscus lateralis.	Nucl. lemniscus lat. (reflex).	
				Nucl. oliv. sup. (reflex) ..			
				Nucl. corporis trapezoidei.	Corpus trapezoid. forming opposite lemniscus lateralis.	Colliculus inferior (reflex).	
IX. Glossopharyngeus.				Tuberculum acusticum...	Striæ acusticæ crossing and forming lemniscus lateralis.	Corp. geniculatum internum.	Thalamic radiations to temporal cortex cerebri.
(*a*) afferent.....	Gang. jugulare sup. and gang. petrosum.	Post. part of tongue (taste), muc. memb. of pharynx, etc.	Fasc. solitarius	Nucleus fasc. solitarii....	Not precisely known.		
(*b*) efferent.....	Motor nucleus—ant. continuation nucl. ambig.	Muscles of pharynx. (stylopharyngeus).					
X. Pneumogastricus.							
(*a*) afferent.....	Gang. jugulare and gang. plexiform. or nodosum.	Visceral receptors of pharynx, œsophagus, lungs, heart, and other viscera.	Fasc. solitarius	Nucl. fasciculi solitarii...	Not precisely known.		
(*b*) efferent.....	(*a*) nucl. dorsalis (alæ cinereæ) in medulla.	Smooth muscles, heart, glands (*via* sympath.).					
	(*b*) nucl. ventralis (ambiguus) in medulla.	Muscles of pharynx and larynx.					
XI. Accessorius.							
(*a*) medullary portion.	= part of X b.						
(*b*) spinal portion.	Anterior horn cells, 1st to 5th or 7th cerv. segments.	Musc. sternocleido-mastoideus and trapezius.					
XII. Hypoglossus	Nucl. XII in medulla.	Muscles of tongue.					
Spinales.	Anterior horncells.	Vol. str. muscles.					
(*a*) efferent (som.) efferent (spl.)	Lat. and cent. gray	Sympath. gang.					
(*b*) afferent.....	Gang. spinales....	Receptors of body.....	Posterior root collaterals.	Motor spinal nuclei (reflex).	Motor nuclei spinal nerves (reflex).		
			Posterior root collaterals.	Tautomeric and heteromeric cells of cord.	Tractus spinocerebellaris dorsalis.		
			Posterior root collaterals.	Column of Clarke.....	Tractus spinocerebellaris ventralis.		
			Posterior root collaterals.	Tautomeric and heteromeric cells of cord.	Tractus spinothalamicus.....		Thalamic rad.
			Posterior root, posterior columns of cord.	Nucl. columns Goll and Burdach.	Lemniscus medialis to thalamus.....		Thalamic radiations to centra cortex cerebri.

General References for Further Study

Bailey and Miller: A Text-book of Embryology, New York, 1909. Chaps. XVII and XVIII.

Barker: The Nervous System and its Constituent Neurones, New York, 1899.

Dejerine: Anatomie des centres nerveux, Paris, 1895.

Edinger L.: Vorlesungen über den Bau der nervösen Zentralorgane des Menschen und der Tiere, Leipsig, 1908 and 1911.

van Gehuchten: Anatomie du système nerveux de l'homme, Louvaine, 1906.

Herrick, C. J.: An Introduction to Neurology.

Johnston, J. B.: The Nervous System of Vertebrates, 1906.

Kölliker: Handbuch der Gewebelehre des Menschen, Leipsic, 1896.

Marburg: Atlas des menschlichen Centralnervensystems, Leipzig and Wein, 1910.

Meyer, Adolf: Critical Review of the Data and General Methods and Deductions of Modern Neurology. *Journ. of Comp. Neurol.*, Vol. VIII, Nos. 3 and 4, 1898.

Obersteiner: Anleitung beim Studieren des Baues der nervösen Centralorgane, Leipsic.

Quain's Elements of Anatomy, Vol. III, Neurology, Parts 1 and 2, 1908.

Ramón y Cajal: Beitrag zum Studium der Medulla Oblongata, etc., Leipsic, 1896.—Les nouvelles idées sur la structure du système nerveux chez l'hommé et chez les vertébrés, Paris, 1894.—Histologie du système nerveux de l'homme et des vertébrés, trad. par L. Azoulay, Tomes I and II, Paris, 1909.
Studien über die Hirnrinde des Menschen, Leipsig, 1900.

Spalteholz, W.: Handatlas of Human Anatomy (trans. by L. F. Barker) Vol. III, 1903.

CHAPTER XXIII

THE ORGANS OF SPECIAL SENSE

The Organ of Vision

THE eyeball and optic nerve constitute the organ of vision. To be described in connection with them are the eyelid and the lacrymal apparatus.

The Eyeball or Bulbus Oculi.—This is almost spherical, although slightly flattened antero-posteriorly. It consists of a wall enclosing a cavity filled with fluid.

The wall of the eyeball consists of three coats: (*a*) An external fibrous coat—the *sclera* and *cornea;* (*b*) a middle vascular—the *chorioid;* and (*c*) an internal nervous—the *retina* (Fig. 393).

THE SCLERA (Figs. 393 and 394).—This consists of dense fibrous tissue with some elastic fibres. The fibres run both meridionally and equatorially, the tendons of the straight muscles of the eyeball being continuous with the meridional fibres, those of the oblique muscles with the equatorial fibres. The few cells of the sclera lie in distinct, very irregular cell spaces, and frequently contain pigment granules. Pigmented cells in considerable numbers are regularly present near the corneal junction, at the entrance of the optic nerve, and on the inner surface of the sclera. Where the optic nerve pierces the sclera, the continuity of the latter is broken by the entering nerve fibres, forming the *lamina cribosa* (Fig. 402). The pigmented layer of the sclera next the chorioid is known as the *lamina fusca*, and is lined internally by a single layer of flat non-pigmented endothelium. Anteriorly a loose connective tissue attaches the sclera to the scleral conjunctiva.

THE CORNEA (Figs. 395 and 398).—This is the anterior continuation of the sclera so modified as readily to allow the light to pass through it. It is about 1 mm. thick and consists of five layers, which from before backward are as follows (Fig. 395):

(1) Anterior epithelium.

(2) Anterior elastic membrane or membrane of Bowman.

(3) Substantia propria corneæ.

(4) Posterior elastic membrane or membrane of Descemet.

(5) Posterior endothelium or endothelium of Descemet.

(1) The *anterior epithelium* (Fig. 395, 1) is of the stratified squamous type and consists of from four to eight layers of cells. The deepest cells are columnar and rest upon the anterior elastic membrane. The middle cells are polygonal and are connected by short

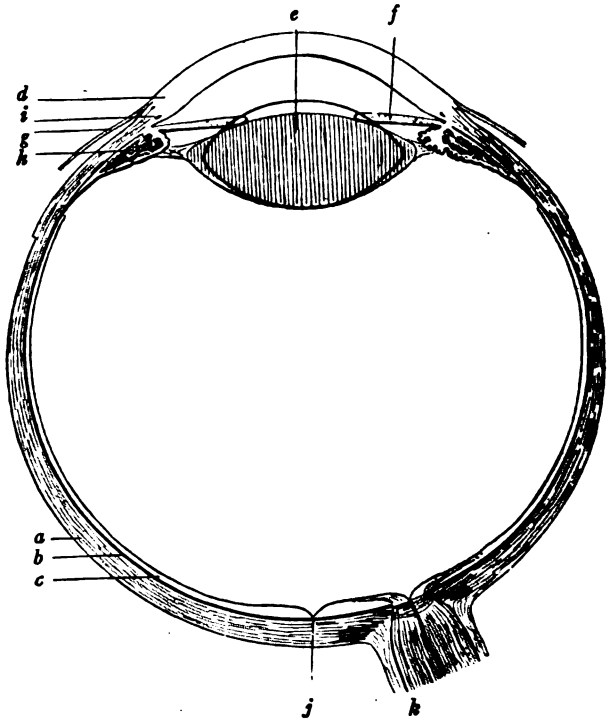

FIG 393.—Diagram of Eyeball showing Coats. (Merkel-Henle.) *a*, Sclera; *b*, chorioid; *c*, retina; *d*, cornea; *e*, lens; *f*, iris; *g*, conjunctiva; *h*, ciliary body; *i*, sclero-corneal junction and canal of Schlemm; j, fovea centralis; *k*, optic nerve.

intercellular bridges. The surface cells are flat. Along the margin of the cornea the epithelium is continuous with that of the conjunctiva (Fig. 398).

(2) The *anterior elastic membrane* (Fig. 395, 2) is a highly developed basement membrane, its anterior surface being pitted to receive the bases of the deepest epithelial cells. It is apparently homogeneous, and while called an elastic membrane, does not conform chemically to either fibrous or elastic tissue. By means of special technic, a fibrillar structure has been demonstrated.

(3) The *substantia propria* (Fig. 395, 3) constitutes the main bulk of the cornea. It consists of connective tissue the fibrils of which are doubly refracting and are cemented together to form bundles and lamellæ. In the human cornea the lamellæ are about sixty in number. The lamellæ are parallel to one another and to the surface of the cornea, but the fibres of adjacent lamellæ cross one another at an angle of about twelve degrees. The lamellæ are united by cement substance. Fibres running obliquely through the lamellæ from posterior to anterior elastic membranes hold the lamellæ firmly together. They are known as *perforating* or *arcuate fibres*.

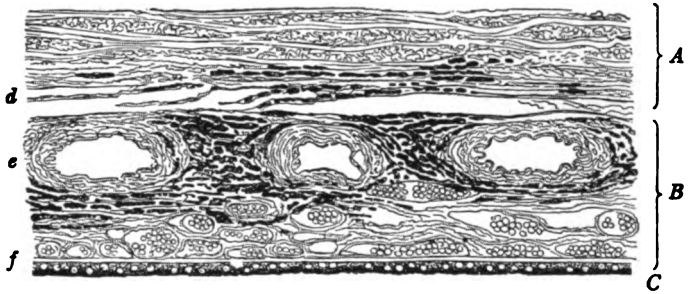

FIG. 394.—Vertical Section through Sclera, Chorioid, and Pigment Layer of Retina. (Merkel-Henle.) *A*, Sclera; *B*, chorioid; *C*, pigment layer of retina; *d*, lamina suprachorioidea; *e*, Haller's layer of straight vessels; *f*, choriocapillaris; *g*, vitreous membrane.

Between the lamellæ are irregular flat cell spaces which communicate with one another and with the lymph spaces at the margin of the cornea by means of canaliculi. Seen in sections vertical to the surface of the cornea, these spaces appear fusiform. In the spaces are the connective-tissue cells of the cornea or *corneal corpuscles*. These are flat cells corresponding in shape to the spaces and sending out processes into the canaliculi (Figs. 396 and 397).

(4) The *posterior elastic membrane* or *membrane of Descemet* (Fig. 395, 4) resembles the anterior, but is much thinner. Like the anterior, it does not give the chemical reaction of elastic tissue.

(5) The *posterior endothelium* or *endothelium of Descemet* (Fig. 395, 5) consists of a single layer of flat hexagonal cells, the nuclei of which frequently project slightly above the surface.

The cornea contains no blood or lymph-vessels.

The nerves of the cornea are branches from the ciliary. They form plexuses in the sclera, just under Bowman's membrane and between the latter and the anterior epithelium.

THE CHORIOID.—This is made up of four layers which from without inward are as follows (Fig. 394):

(1) The lamina suprachorioidea.
(2) The layer of straight vessels—Haller's layer.
(3) The capillary layer—choriocapillaris.
(4) The vitreous membrane—lamina citrea—membrane of Bruch.

(1) The *lamina suprachorioidea* (Fig. 394, *d*) is intimately connected with the lamina fusca of the sclera and consists of loosely arranged bundles of fibrous and elastic tissue among which are scattered pigmented and non-pigmented connective-tissue cells. Numerous lymph spaces are found between the bundles of connective tissue and between the lamina suprachorioidea and lamina fusca. The latter are known as the *perichorioidal lymph spaces* (Fig. 398).



FIG. 395.—Vertical Section of Cornea. (Merkel-Henle.) 1, Anterior epithelium; 2, anterior elastic membrane; 3, substantia propria corneæ; 4, posterior elastic membrane; 5, posterior endothelium.

(2) The *layer of straight vessels* (Fig. 394, *e*) consists of fibro-elastic tissue containing numerous pigmented and non-pigmented cells, supporting the large blood-vessels of the layer. The latter can be seen with the naked eye, and, as they are straight and parallel, give to the layer a striated appearance. The arteries lie to the inner side. The veins—*venæ vorticosæ*—are larger than the arteries and converge toward four points one in each quadrant of the eyeball.

A narrow boundary zone, rich in elastic fibres and free from pigment, limits this layer internally. It is much more highly developed in some of the lower animals than in man. Formed of connective-tissue bundles in ruminants and horses, it is known as the *tapetum fibrosum*, while in the carnivora its structure—several layers of flat cells—gives it the name of the *tapetum cellulosum*.

(3) The *choriocapillaris* (Fig. 394, *f*) consists of connective tissue supporting a dense network of capillaries, which is most dense in the region of the macula lutea. This layer is usually described as free from pigment, although it not infrequently contains some pigmented cells.

(4) The *vitreous membrane* (Fig. 394, *g*) is a clear, apparently structureless membrane about two microns thick. Its outer surface is grooved by the capillaries of the choriocapillaris, while its inner surface is pitted by the retinal epithelium.

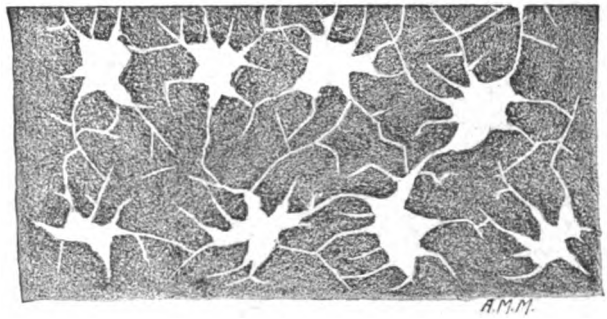

FIG. 396.—Section of Human Cornea cut Tangential to Surface—×350 (technic 9, p. 97)—showing corneal cell spaces (lacunæ) and anastomosing canaliculi.

THE CILIARY BODY.—This is the anterior extension of the chorioid and consists of the ciliary processes and the ciliary muscle (Fig. 398). It extends from the *ora serrata* (a wavy edge which marks the anterior

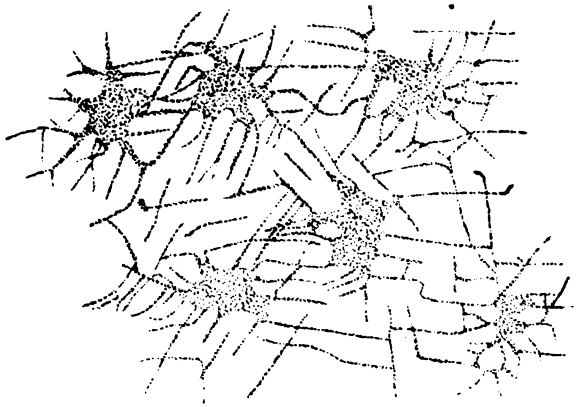

FIG. 397.—Section of Human Cornea cut Tangential to Surface—×350 (technic 8, p. 97)—showing corneal cells and their anastomosing processes.

limit of the nervous elements of the retina—see Retina) to the margin of the iris (see below).

The *ciliary processes* (Fig. 398), from seventy to eighty in number,

are meridionally-running folds of the chorioid from which are given off numerous irregular secondary folds. The processes begin low at the ora serrata, gradually increase in height to about 1 mm., and end abruptly at the margin of the iris. The ciliary processes consist of connective tissue containing many pigmented cells and supporting numerous blood-vessels. Invaginations lined with clear columnar epithelium have been described as ciliary glands. The ciliary folds

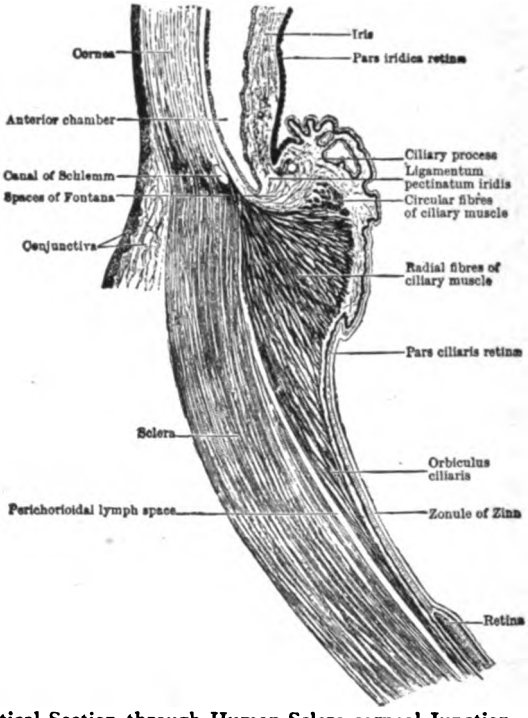

FIG. 398.—Vertical Section through Human Sclero-corneal Junction. (Cunningham.)

are covered by the *vitreous membrane*, and internal to the latter is a continuation forward of non-nervous elements of the retina—*pars ciliaris retinæ* (Fig. 398). This consists of two layers of columnar epithelial cells, the outer layer being pigmented, the inner non-pigmented.

The *ciliary muscle* (Fig. 398) is a band of smooth muscle which encircles the iris. It lies in the outer anterior part of the ciliary body, and on cross section has a generally triangular shape. It is divisible into three groups of muscle cells: (*a*) An inner circular group near the base of the iris—circular muscle of Müller; (*b*) an

outer meridional group lying next to the sclera and known as the tensor choroideæ, and (*c*) a middle radial group. The meridional and radial groups both take origin in the posterior elastic lamina of the cornea, the former passing backward along the margin of the sclera to its insertion in the ciliary body near the ora serrata, the lattersradiating fan-like to a broad insertion in the ciliary body and proceses.

The ciliary body is closely attached to the sclero-corneal junction by the *ligamentum pectinatum* (Fig. 398), a continuation of the posterior elastic lamina of the cornea. Within the ligament are spaces (*spaces of Fontana*) lined with endothelium. These are apparently lymph spaces, and communicate with each other, with similar spaces around the canal of Schlemm, and with the anterior chamber. The *canal of Schlemm* (Fig. 398) is a venous canal which encircles the cornea, lying in the sclera close to the corneal margin. Instead of a single canal there may be several canals.

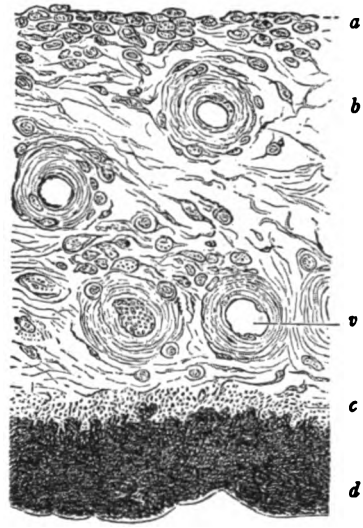

FIG. 399.—Vertical Section through Iris. (Merkel-Henle.) *a*, Anterior endothelium; *b*, stroma or substantia propria; *c*, vitreous membrane; *d*, pigment layer; *v*, blood-vessel.

THE IRIS (Fig. 399).—This represents a further continuation forward of the chorioid. Its base is attached to the ciliary body and ligamentum pectinatum. From this point it extends forward as a diaphragm in front of the lens, its centre being perforated to form the pupillary opening. It is deeply pigmented, and to its pigment the color of the eye is due. Four layers may be distinguished, which from before backward are as follows:

(1) The anterior endothelium.
(2) The stroma.
(3) The vitreous membrane.
(4) The pigmented epithelium.

(1) The *anterior endothelium* is a single layer of pigmented cells continuous with the posterior endothelium of the cornea (Fig. 391, *a*).

(2) The *stroma* is divisible into two layers: an anterior reticular layer, containing many cells, some of which are pigmented, and a vascular layer, the vessels of which are peculiar in that their walls contain almost no muscle, but have thick connective-tissue sheaths. In the posterior part of the stroma are bundles of smooth muscle. Those nearest the pupillary margin encircle the pupil, forming its sphincter muscle, while external are scattered radiating bundles forming the dilator muscle.

(3) The *vitreous membrane* is continuous with, and has the same structure as the membrane of Bruch.

(4) The *pigmented epithelium* (Fig. 399, *d*) consists of several layers of cells and is continuous with the pars ciliaris retinæ. Except in albinos, both layers are pigmented.

THE RETINA.—The retina is the nervous tunic of the eye. It lines the entire eyeball, ending only at the pupillary margin of the iris. Its nervous elements, however, extend only to the *ora serrata*, which marks the outer limit of the ciliary body (Fig. 398). The nervous part of the retina is known as the *pars optica retinæ*, the non-nervous extension over the ciliary processes as the *pars ciliaris retinæ*, its further continuation over the iris as the *pars iridica retinæ*. Modifications of the optic portion of the retina are found in the region of the macula lutea and of the optic nerve entrance.

The Pars Optica Retinæ.—This is the only part of the retina directly concerned in the reception of impulses, and may be regarded as the extremely complex sensory end-organ of the optic nerve. It is divisible into ten layers, which from without inward are as follows (Fig. 400):

(1) Layer of pigmented epithelium.	
(2) Layer of rods and cones.	Layer of neuro-epithelium.
(3) Outer limiting membrane.	
(4) Outer nuclear layer.	
(5) Outer molecular layer.	Ganglionic layer.
(6) Inner nuclear layer.	
(7) Inner molecular layer.	
(8) Layer of nerve cells.	
(9) Layer of nerve fibres.	
(10) Inner limiting membrane.	

The *layer of pigmented epithelium* (Fig. 400, *B*, 1) consists of a single layer of regular hexagonal cells (Fig. 27, p. 80). The nuclei

lie in the outer part of the cell, while from the inner side thread-like projections extend down between the rods and cones of the layer next internal. The pigment has the form of rod-shaped granules. Its distribution seems to depend upon the amount of light being admitted to the retina. When little or no light is being admitted, the pigment is found in the body of the cell, the processes being wholly or almost

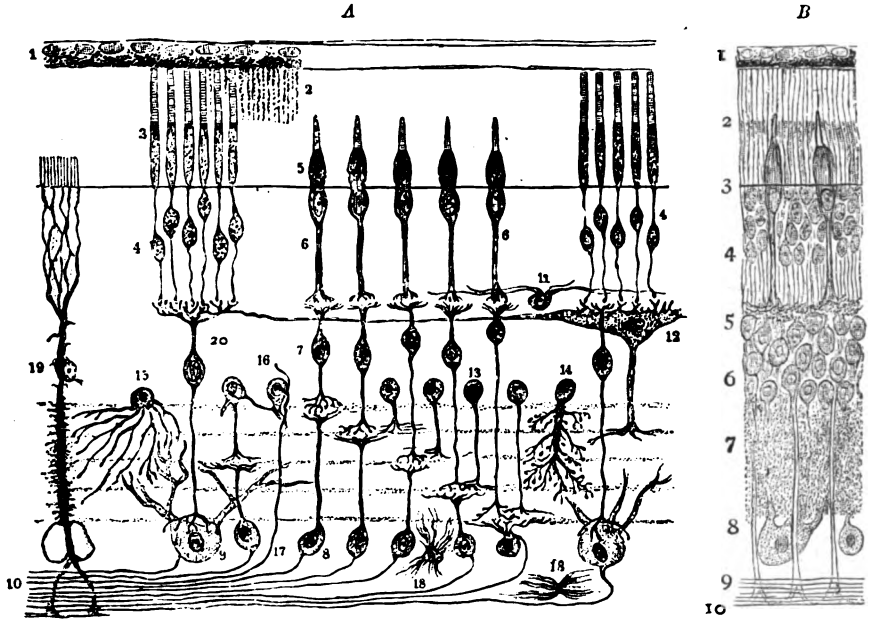

FIG. 400.—*A*, Scheme of retina as shown by the Golgi method. *B*, Vertical section of retina to show layers as demonstrated by the hæmatoxylin-eosin stain. (Merkel-Henle.) *B*.—1, Layer of pigmented epithelium; 2, layer of rods and cones; 3, outer limiting layer; 4, outer nuclear layer; 5, outer molecular layer; 6, inner nuclear layer; 7, inner molecular layer; 8, layer of nerve cells; 9, layer of nerve fibres; 10, inner limiting layer. *A*.—1, Pigment layer; 2, processes of pigmented epithelial cells extending down between rods and cones; 3, rods; 4, rod-cell nuclei and rod fibres; 5, cones; 6, cone fibres; 7, bipolar cells of inner nuclear layer; 8, ganglion cells of nerve-cell layer; 9, larger ganglion cells of nerve-cell layer; 10, fibres of optic nerve forming layer of nerve fibres; 11 and 12, types of horizontal cells; 13, 14, 15, and 16, types of cells the bodies of which lie in the inner nuclear layer; 17, efferent optic-nerve fibre ending around cell of inner nuclear layer; 18, neuroglia cells; 19, Müller's fibre; 20, rod-bipolar cell of inner nuclear layer.

free from pigment; when the retina is exposed to a bright light, some of the pigment granules pass down into the processes so that the pigment becomes more evenly distributed throughout the cell.

The *layer of rods and cones* and the *outer nuclear layer* (Fig. 400, *B*, 2, 4) are best considered as subdivisions of a single layer, the neuro-epithelial layer. This consists essentially of two forms of neuro-

epithelial elements, *rod visual cells* and *cone visual cells*. These, with supporting connective tissue, constitute the layer of rods and cones and the outer nuclear layer, the separation into sub-layers being due to the sharp demarcation between the nucleated and non-nucleated parts of the cells, and the separation of the two parts by the perforated *outer limiting membrane*.

The *rod visual cell* (Fig. 400, *A*, 4) consists of rod, rod-fibre, and nucleus. The rod (Fig. 400, *A*, 3) is a cylinder from 30 to 40μ in length and about 2μ in diameter. It is divisible into an outer clear portion, which contains the so-called "visual purple" and an inner granular portion. At the outer end of the latter is a fibrillated ellipsoidal body, much more distinct in some of the lower animals, the *ellipsoid of Krause*. At its inner end the rod tapers down to a fine fibre, the *rod fibre*, which passes through a perforation in the outer limiting membrane into the outer nuclear layer, where it expands and contains the nucleus of the rod visual cell. These nuclei are situated at various levels in the fibre and constitute the most conspicuous element of the *outer nuclear layer* (Fig. 400, *B*, 4).

The *cone visual cell* (Fig. 400, *A*, 5,6) consists of cone, cone-fibre, and nucleus. The cone (Fig. 400, *A*, 5) is shorter and broader than the rod, and like the latter is divisible into two parts. The outer part is short, clear, and tapering, the inner part broad and granular, and like the rod contains a fibrillated ellipsoid body. The cone fibre (Fig. 400, *A*, 6) is much broader than the rod fibre, passes completely through the outer nuclear layer and ends in an expansion at the margin of the outer molecular layer. The nucleus of the cone cell usually lies just beneath the outer limiting membrane.

The remaining layers of the retina must be considered in relation on the one hand to the neuro-epithelium, on the other to the optic nerve. The *inner nuclear layer* (Fig. 400, *B*, 6) and the *layer of nerve cells* (Fig. 400, *B*, 8) are composed largely of nerve-cell bodies, while the *two molecular layers* (Fig. 400, *B*, 5, 7) are formed mainly of the ramifications of the processes of these cells. In the inner nuclear layer are two kinds of nerve elements, *rod bipolar cells* and *cone bipolar cells*. The bodies of these cells with their large nuclei form the bulk of this layer. From the rod bipolars (Fig. 400, *A*, 20) processes (*dendrites*) pass outward to ramify in the outer molecular layer around the terminations of the rod fibres. From the cone bipolars (Fig. 400, *A*, 7) similar processes (*dendrites*) extend into the outer molecular layer where they ramify around the terminations of the

cone cells. Two other forms of nerve cells occur in the inner nuclear layer. One is known as the *horizontal cell* (Fig. 400, *A*, 12). Its processes ramify almost wholly in the outer molecular layer. The other lies along the inner margin of the inner nuclear layer and sends its dendrites into the inner molecular layer (Fig. 400, *A*, 13, 14, 15, and 16). Many of these latter cells appear to have no axone and are consequently known as *amacrine cells*.

The outer molecular layer is thus seen to be formed mainly of terminations of the rod and cone visual cells, of the dendrites of the rod and cone bipolars, and of the processes of the horizontal cells.

From the cone bipolar a process (*axone*) extends inward to ramify in the inner molecular layer, while from the rod bipolar a process (*axone*) passes inward through the inner molecular layer to terminate around the cells of the nerve-cell layer.

The *layer of nerve cells* (Fig. 400, *B*, 8) consists for the most part of large ganglion cells whose dendrites ramify in the inner molecular layer, and whose axones pass into the layer of nerve fibres and thence into the optic nerve. Some small ganglion cells are also found in this layer, especially in the region of the macula lutea (see page 638).

The inner molecular layer is thus seen to be composed mainly of the processes (*axones*) of the rod and cone bipolars and of the dendrites of the ganglion cells of the nerve-cell layer.

The *layer of nerve fibres* (Fig. 400, *B*, 9) consists mainly of the axones of the just-described ganglion cells, although a few centrifugal axones of brain cells (Fig. 400, *A*, 17) are probably intermingled.

The *outer and inner limiting layers or membranes* (Fig. 400, *B*, 3,10) are parts of the sustentacular apparatus of the retina, being connected with the *cells* or *fibres of Müller* (Fig. 400, *A*, 19 and Fig. 401). The latter form the most conspicuous elements of the supportive tissue of the retina. They are like the nerve elements proper, of ectodermic origin and are elongated cells which extend through all the retinal layers, excepting the layer of rods and cones and the pigment layer. The inner ends of the cells, which are conical and fibrillated, unite to form the inner limiting membrane (Fig. 401, 10). Through the inner molecular layer the cell takes the form of a narrow stalk with numerous fringe-like side fibrils (Fig. 401, 7). This widens in the inner nuclear layer, where cup-like depressions in the sides of the Müller's cell are caused by the pressure of the surrounding nerve cells (Fig. 401, *b*). This wide portion of the cell in the inner nuclear layer contains the nucleus (Fig. 401, *a*). In the outer molecular layer the

cell again becomes narrow (Fig. 401, 5) and in the outer nuclear layer broadens out into a sponge-like reticulum (Fig. 401, 4), which supports the rod and cone bipolars. At the inner margin of the layer of rods and cones the protoplasm of the Müller's cells spreads out and unites to form the so-called outer limiting membrane (Fig. 401, 3), from which delicate fibrils (*fibre baskets*) pass outward between the rods and cones. In addition to the Müller's cells, which are neuroglia elements, spider cells also occur in the retina (Fig. 400, *A*, 18).

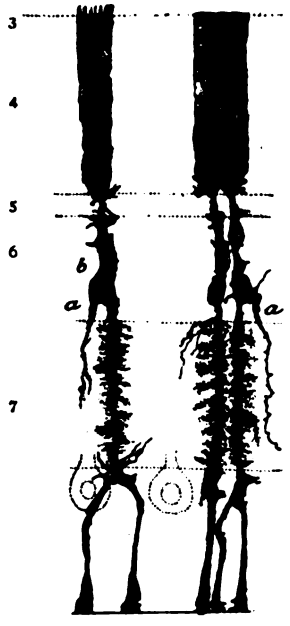

FIG. 401.—Two Müller's Fibres from Retina of Ox showing Relation to Layers of Retina. (Ramón y Cajal.) 3, Outer limiting layer; 4, outer nuclear layer; 5, outer molecular layer; 6, inner nuclear layer; 7, inner molecular layer; 8, layer of nerve cells; 9, layer of nerve fibres; 10, inner limiting layer; *a*, nucleus; *b*, cup-like depression caused by pressure from surrounding cells.

The retina of the *macula lutea* presents certain peculiarities. Its name is derived from the yellow pigment which is distributed diffusely through the inner layers, extending as far out as the outer molecular layer. The ganglion-cell layer and the inner nuclear layer are thicker than in other parts of the retina. In the layer of rods and cones there is a gradual reduction in the number of rods, while the number of cones is correspondingly increased.

In the centre of the macula is a depression, the *fovea centralis*. As the retina approaches this area it becomes greatly thinned, little remaining but the layer of cone cells and the somewhat thickened layer of pigmented epithelium.

At the ora serrata the nervous elements of the retina cease. The non-nervous retinal extension over the ciliary body (*pars ciliaris retinæ*) and over the iris (*pars iridica retinæ*) have been described in connection with the ciliary body and iris.

The Optic Nerve.—The optic nerve (Fig. 402, *d*) is enclosed by two connective-tissue sheaths, both of which are extensions of the brain membranes. The outer or *dural sheath*, (Fig. 402, *a*) is continuous with the dura mater of the brain posteriorly, while anteriorly it blends with the sclera. The inner or *pial sheath*, (Fig. 402, *b*) is an extension of the pia mater and is separated from the outer sheath by

the subdural space (Fig. 402, *c*). The pial sheath is divisible into two sub-layers: an outer fibrous layer (the so-called *arachnoid*), and an inner vascular layer. These two layers are separated by a narrow space, the *subarachnoid space*. The optic nerve fibres, in passing through the sclera and chorioid, separate the connective-tissue bundles so that they form a lattice-work, the already mentioned *lamina cribrosa* (Fig. 402, *h*). The optic nerve fibres are medullated, but have no neurilemma. As they pass through the lamina cribrosa the medullary sheaths are lost, the fibres reaching the retina as naked axones.

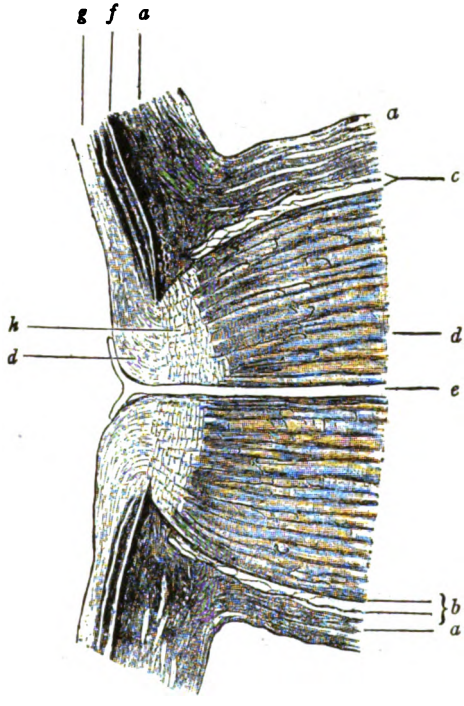

FIG. 402.—Section through Entrance of Optic Nerve into Eyeball. (Merkel-Henle.) *a*, Dural sheath; *b*, pial sheath, inner and outer layers; *c*, space between inner and outer layers of pia mater; *d*, optic nerve; *e*, central artery of retina; *a'*, sclera; *f*, chorioid; , retina; *h*, lamina cribrosa.

RELATIONS OF OPTIC NERVE TO RETINA AND BRAIN

The rod and cone visual cells are the neuro-epithelial beginnings of the visual tract (Fig. 400, *A*, 3, 4, 5, and 6). By their expanded bases in the outer molecular layer, the rod and cone cells communicate with the neurone system No. I. of the optic tract. This comprises (*a*) rod neurones, (*b*) cone neurones, (*c*) horizontal neurones.

NEURONE SYSTEM No. I.—(*a*) *Rod neurones*. The cell bodies of these neurones (Fig. 400, *A*, 20) lie in the inner nuclear layer. Their dendrites enter the outer molecular layer where they form networks around the expanded bases of the rod cells. Their axones pass through the inner molecular layer and end in arborizations around the bodies and dendrites of cells of the nerve-cell layer (neurone system No. II.). (*b*) *Cone neurones* (Fig. 400, *A*, 7). These have their cell bodies in the inner nuclear layer. Their dendrites pass to the outer molecular layer where they form networks around the expanded bases

of the cone cells. Their axones pass only into the inner molecular layer where they end in arborizations around the dendrites of neurones whose cell bodies are in the layer of nerve cells (neurone system No. II.). (*c*) *Horizontal neurones* (Fig. 400, *A*, 11 and 12). These serve as association neurones between the visual cells and may be divided into *rod association neurones* and *cone association neurones*. The cone association neurones are the smaller and more superficial, and both dendrites and axones end in the outer molecular layer around the terminal expansions of the cone visual cells (Fig. 400, *A*, 11). The rod association neurones are larger, more deeply seated, and behave in a similar manner toward the rod visual cells (Fig. 400, *A*, 12). Some of these cells send processes to the inner molecular layer.

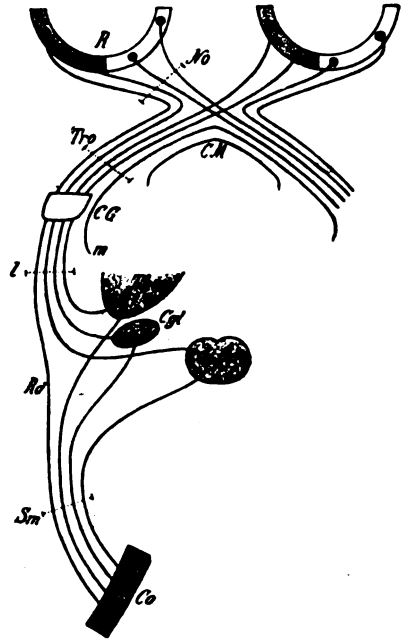

FIG. 403.—Diagram showing Main Relations of Optic Tract. (Testut.) *R*, Retina; *No*, optic nerve; *CM*, optic decussation or chiasma; *Tro*, optic tract; *Tho*, thalamus; *Cgl*, lateral geniculate body; *Qa*, anterior corpus quadrigeminum; *Rd*, fibre of optic tract passing directly to cortex; *Sm*, third neurone system of optic tract (excepting *Rd*) connecting thalamus, lateral geniculate body, and anterior corpus quadrigemnium with the cortex, *Co*.

NEURONE SYSTEM No. II.—This has been already partly described in connection with the axone terminations of neurone system No. I. The cell bodies of the second neurone system (Fig. 400, *A*, 8, 9) are in the layer of nerve cells and are, as above noted, associated either directly or by means of their dendrites with the axones of the first neurone system. Their axones pass into the layer of nerve fibres and ultimately become fibres of the optic nerve (Fig. 400, *A*, 10).

The optic nerves (Fig. 403, *No*) unite at the base of the brain to form the *optic decussation* or *chiasma* (Fig. 403, *CM*). Here the axones from the mesial part of the retina cross to the optic tract of the opposite side, while those from the lateral part of the retina remain in the optic tract of the same side. The axones of the optic tract

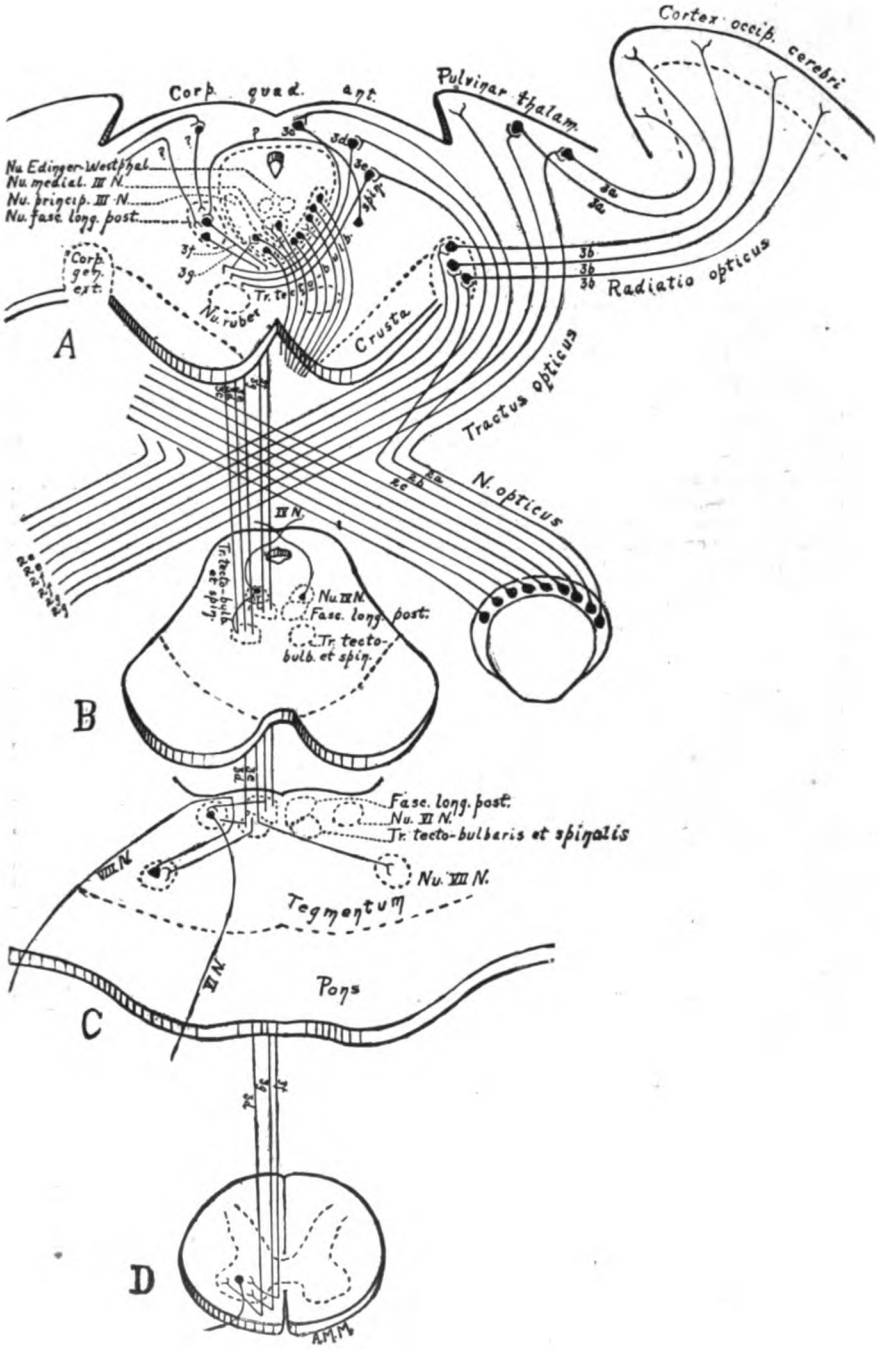
Cortex occip. cerebri
Corp. quad. ant.
Pulvinar thalam.
Nu. Edinger-Westphal
Nu. medial. III N.
Nu. princip. III N.
Nu. fasc. long. post.
Corp. gen. ext.
Nu. ruber
Crusta
Radiatio opticus
Tractus opticus
N. opticus
A
III N.
Nu. III N.
Fasc. long. post.
Tr. tecto-bulb. et spin.
B
Fasc. long. post.
Nu. III N.
Tr. tecto-bulbaris et spinalis
Nu. VIII N.
Tegmentum
Pons
C
D

FIG. 404.

EXPLANATION OF FIG. 404

FIG. 404.—Diagram of the Optic (II) Nerve and some of its Principal Connections. *A*, Level of nerves II and III; *B*, level of nerve IV; *C*, level of nerves VI and VII; *D*, spinal cord. Neurone groups are represented by one or several individual neurones.

The rods and cones (receptors) and the bipolar cells (=Neurone No. 1) of the retina are not indicated.

Neurone No. 2.—2*a*, Axones of ganglion cells in temporal part of retina pass to pulvinar of thalamus of same side; 2 *b*, axones of ganglion cells in temporal retina pass to superior colliculus of same side; 2 *c*, axones of ganglion cells in temporal retina pass to external geniculate body of same side; 2 *e*, axones of ganglion cells in nasal side of retina cross in optic chiasma and pass to external geniculate body of opposite side; 2 *f*, axones of ganglion cells in nasal side of retina cross in optic chiasma and pass to superior colliculus of opposite side; 2 *g*, axones of ganglion cells in nasal side of retina cross in optic chiasma and pass to pulvinar of thalamus of opposite side. Macular fibres are partly crossed and partly uncrossed.

Neurone No. 3.—3*a*, Axones of cells in pulvinar to cortex of occipital lobe of cerebrum (this connection is disputed); 3 *b*, axones of cells in external geniculate body to cortex of occipital lobe of cerebrum; 3 *a* and 3*b* constitute the primary optic radiation; 3 *c*, 3 *d* and 3 *e*, axones of cells in deep (fourth) layer of superior colliculus (see p. 522) decussate ventral to medial longitudinal fasciculus (dorsal tegmental decussation or decussation of Meynert) and form the tractus colliculo-bulbaris et spinalis or predorsal bundle. (*Tr. tectobulb. et spin.*) to bulb (medulla) and anterior column of cord, innervating by collaterals and terminals, directly or indirectly, chiefly the nuclei of III, IV, VI, and VII cranial nerves and motor nuclei of spinal nerves. 3 *f* and 3 *g* (possibly another neurone intercalated between these and optic terminals), axones of cells in interstitial nucleus of Cajal (*Nu. fasc. long. post.*) form part of medial longitudinal fasciculus and descend on same side to anterior column of cord next to anterior median fissure, innervating nuclei of III, IV, and VI cranial nerves and motor nuclei of spinal nerves.

Neurone No. 4.—Axones of cells in above-mentioned motor nuclei. Axones from cells in median nucleus of nerve III (*Nu. med. N. III*) and possibly in Edinger-Westphal nucleus, probably innervate the intrinsic muscle of eyeball (ciliary and pupillary reflex path).

Pallio-tectal fibres, by means of which the collicular reflex centre is brought under the control of the cerebral cortex, are not indicated.

It is evident from the diagram that the cerebral pathway of the optic nerve is *via* the external geniculate body (and pulvinar of thalamus?), and the reflex pathway is *via* the superior colliculus.

(Fig. 403, *Tro*) terminate in the thalamus, in the lateral geniculate body, and in the anterior corpus quadrigeminum (Fig. 403).

NEURONE SYSTEM No. III.—The neurones of this system have their cell bodies in the thalamus, lateral geniculate body, and anterior corpus quadrigeminum (Fig. 403). The axones of the two former terminate in the cortical visual centers in the occipital lobe (Fig. 403, *Co*). The axones of the latter form descending reflex paths (see Anterior Corpora Quadrigemina, p. 585).

Neurone system No. I is the analog of the primary afferent neurones (the cerebro-spinal ganglion cells). Neurone system No. II is the analog of the secondary afferent neurone system which receives the afferent root fibres and originates the secondary decussating tracts

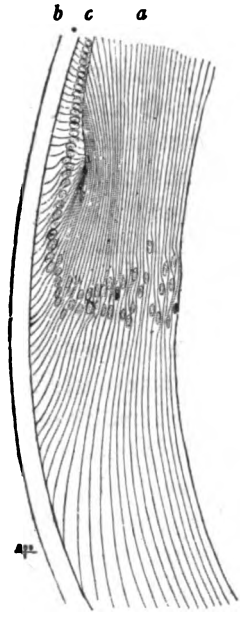

Fig. 405.

Fig. 406.

FIG. 405.—From Longitudinal Section through Margin of Crystalline Lens, showing longitudinal sections of lens fibres and transition from epithelium of capsule to lens fibres. (Merkel-Henle.) *a*, Lens fibres; *b*, capsule; *c*, epithelium.

FIG. 406.—From Cross Section of Crystalline Lens, showing transverse sections of lens fibres and surface epithelium. (Merkel-Henle.) *a*, Lens fibres; *b*, epithelium.

to the thalamus, such as the medial and lateral fillets. Neurone system No. III is the tertiary afferent neurone system or thalamo-cortical system. It will thus be seen that the optic chiasma is the analog of the decussations of the medial and lateral fillets. (See also pp. 505, 507 *A*.)

The Lens.—The lens is composed of lens fibres which are laid down in layers (Fig. 405, *a*). The lens fibre is a long hexagonal, flattened prism with serrated edges. Most of the lens fibres are nucle-

ated, the nucleus lying at about the centre of the fibre near the axis of the lens. The most central of the lens fibres are usually non-nucleated. The fibres extend meridionally from before backward through the entire thickness of the lens. They are united by a small amount of cement substance. The lens is surrounded by the lens capsule (Fig. 405, *b*), a clear homogeneous membrane which is about 12μ thick over the anterior surface of the lens, about half as thick over the posterior surface. Between the capsule and the anterior and lateral surfaces of the lens is a single layer of cuboidal epithelial cells (Fig. 405, *c*), the lens epithelium. Attached to the capsule of the lens anteriorly and posteriorly are membrane-like structures which constitute the *suspensory ligament* of the lens. These pass outward and unite to form a delicate membrane, the *zonula ciliaris* or *zonule of Zinn* (Fig. 398). This bridges over the inequalities of the ciliary processes and, continuing as the hyaloid membrane, forms a lining for the vitreous cavity of the eye. The triangular space between the two layers of the suspensory ligament and the lens is known as the *canal of Petit.*

The *vitreous body* is a semifluid substance containing fibres which run in all directions and a small number of connective-tissue cells and leucocytes. Traversing the vitreous in an antero-posterior direction is the so-called *hyaloid* or *Cloquet's canal*, the remains of the embryonic hyaloid artery (page 649).

Blood-vessels.—The blood-vessels of the eyeball are divisible into two groups, one group being branches of the central artery of the retina, the other being branches of the ciliary artery.

The central artery of the retina enters the eyeball through the centre of the optic nerve. Within the eyeball it divides into two branches, a superior and an inferior. These pass anteriorly in the nerve-fibre layer, giving off branches, which in turn give rise to capillaries which supply the retina, passing outward as far as the neuro-epithelial layer and anteriorly as far as the ora serrata. The smaller branches of the retinal arteries do not anastomose. In the embryo a third vessel exists, the hyaloid artery. This is a branch of the central retinal artery and traverses the vitreous to the posterior surface of the lens, supplying these structures. The hyaloid canal, or canal of Cloquet, of the adult vitreous, represents the remains of the degenerate hyaloid artery (page 649). The veins of the retina accompany the arteries.

The ciliary arteries are divisible into long ciliary arteries, short

ciliary arteries, and anterior ciliary arteries. The long ciliary arteries are two in number and pass one on each side between the chorioid and sclera to the ciliary body, where each divides into two branches, which diverge and run along the ciliary margin of the iris. Here the anastomosis of the two long ciliary arteries forms the *greater arterial circle* of the iris. This gives rise to small branches which pass inward supplying the surrounding tissues and unite near the margin of the pupil to form the *lesser arterial circle* of the iris. The branches of the short ciliary arteries pierce the sclera near the optic nerve entrance, supply the posterior part of the sclera, and terminate in the chorio-capillaris of the chorioid. The anterior ciliary arteries enter the sclera near the corneal margin and communicate with the chorio-capillaris and with the greater arterial circle of the iris. The anterior ciliary arteries also supply the ciliary and recti muscles and partly supply the sclera and conjunctiva. Small veins accompany the ciliary arteries; the larger veins of this area are peculiar, however, in that they do not accompany the arteries, but as venæ vorticosæ converge toward four centres, one in each quadrant of the eyeball. At the sclero-corneal junction is a venous channel, the canal of Schlemm, which completely encircles the cornea (Fig. 398).

Lymphatics.—The eyeball has no distinct lymph-vessel system. The lymph, however, follows certain definite directions which have been designated by Schwalbe "lymph paths." He divides them into anterior lymph paths and posterior lymph paths. The anterior lymph paths comprise (*a*) the anterior chamber which communicates by means of a narrow cleft between iris and lens with the posterior chamber; (*b*) the posterior chamber; (*c*) the lymph canaliculi of the sclera and cornea and the canal of Petit. The posterior lymph paths include (*a*) the hyaloid canal (see above); (*b*) the subdural and intra-pial spaces, including the capsule of Tenon; (*c*) the perichorioidal space, and (*d*) the perivascular and pericellular lymph spaces of the retina.

Nerves.—The nerves which supply the eyeball pass through the sclera with the optic nerve and around the eyeball in the suprachorioid layer. From these nerves, branches are given off as follows:

(1) To the chorioid, where they are intermingled with ganglion cells.

(2) To the ciliary body, where they are mingled with ganglion cells to form the *ciliary plexus*. The latter gives off branches to the ciliary body itself, to the iris, and to the cornea. Those to the

cornea first form a plexus in the sclera—the plexus annularis—which encircles the cornea. From this, branches pierce the substantia propria of the cornea, where they form four corneal plexuses, one in the posterior part of the substantia propria, a second just beneath the anterior elastic membrane, a third sub-epithelial, and a fourth intra-epithelial. The fibres of the last named are extremely delicate and terminate freely between the epithelial cells. Krause describes end-bulbs as occurring in the substantia propria near the margin of the sclera, while according to Dogiel some of the fibres are connected with end-plates.

The Lacrymal Apparatus

The lacrymal apparatus of each eye consists of the gland, its excretory ducts, the lacrymal canal, the lacrymal sac, and the nasal duct.

The *lacrymal gland* is a compound tubular gland consisting of two main lobes. Its structure corresponds in general to that of a serous gland. The excretory ducts are lined with a two-layered columnar epithelium which becomes simple columnar in the smaller ducts. The alveoli are lined with irregularly cuboidal serous cells, which rest upon a basement membrane beneath which is a richly elastic interstitial tissue.

The *lacrymal canals* have a stratified squamous epithelial lining. This rests upon a basement membrane beneath which is the stroma containing many elastic fibres. External to the connective tissue are some longitudinal muscle fibres.

The *lacrymal sac* is lined with a two-layered stratified or pseudo-stratified columnar epithelium resting upon a basement membrane. The stroma contains much diffuse lymphatic tissue.

The *nasal duct* has walls similar in structure to those of the lacrymal sac. In the case of both sac and duct the walls abut against periosteum, a dense vascular plexus being interposed.

The blood-vessels, lymphatics, and nerves of the lacrymal gland have a distribution similar to those of other serous glands.

The Eyelid

The eyelid consists of an outer skin layer, an inner conjunctival layer, and a middle connective-tissue layer.

The epidermis is thin and the papillæ of the derma are low. Small sebaceous glands, sweat glands, and fine hairs are present.

The *conjunctiva* (Fig. 407, *d*) is a mucous membrane consisting of a lining epithelium and a stroma. The epithelium is stratified columnar consisting of two or three layers of cells. Among these cells are cells resembling goblet cells. Although not always upon the surface, they are believed to be mucous cells, probably analogous to the so-called Leydig's cells found in the larvæ of amphibians and fishes. Diffuse lymphoid tissue is regularly present in the stroma, while lymph nodules are of rare occurrence. Small glands, similar to the lacrymal glands in structure, are usually present (Fig. 407, *k*).

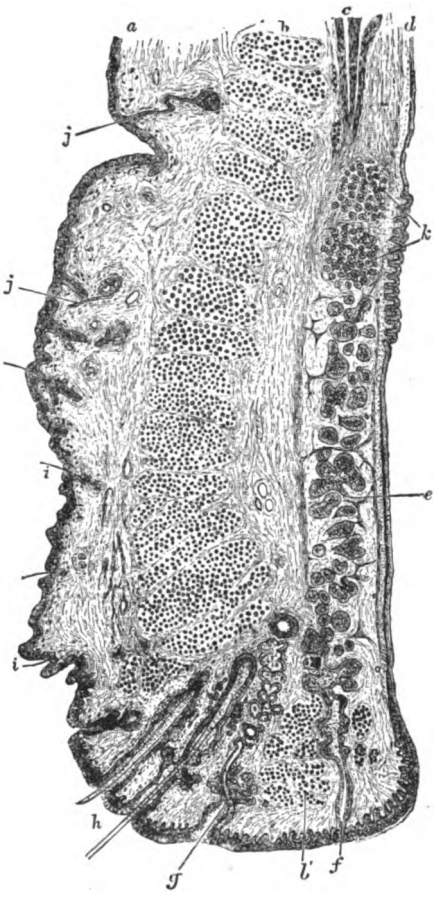

FIG. 407.—Vertical Section through Upper Eyelid. (Waldeyer.) *a*, Skin; *b*, orbicularis muscle; *b'*, ciliary bundle of muscle; *c*, involuntary muscle of eyelid; *d*, conjunctiva; *e*, tarsus containing Meibomian glands; *f*, duct of Meibomian gland; *g*, sebaceous gland with duct lying near eyelashes; *h*, eyelashes; *i*, small hairs in outer *skin*; *j*, sweat glands; *k*, posterior tarsal glands.

At the margin of the eyelid where skin joins mucous membrane are several rows of large hairs, the eyelashes (Fig. 407, *h*). Connected with their follicles are the usual sebaceous glands (Fig. 407, *g*) and the *glands of Mall*, the latter probably representing modified sweat glands.

The middle layer contains the tarsus (Fig. 407, *e*) and the muscular structure of the eyelid (Fig. 407, *b*). The tarsus is a plate of dense fibrous tissue which lies just beneath the conjunctiva and extends about two-thirds the height of the lid. It contains the tarsal or *Meibomian glands* (Fig. 407, *e*). These are from thirty to forty in number, each consisting of a long duct which opens externally on the margin of the lid behind the lashes (Fig. 407, *f*), and internally into a number of branched

tubules. The duct is lined with stratified squamous epithelium. The tubules resemble those of the sebaceous glands. Between the tarsus and the skin are the muscular structures of the eyelid in which both smooth and striated muscle are found.

Blood-vessels.—Two main arteries pass to the eyelid, one at each angle, and unite to form an arch, the tarsal arch, along the margin of the lid. A second arch, the external tarsal arch, is formed along the upper margin of the tarsus. From these arches are given off capillary networks which supply the structures of the lid.

Lymphatics.—These form two anastomosing plexuses, one anterior, the other posterior to the tarsus.

Nerves.—The nerves form plexuses in the substance of the lid. From these, terminal fibrils pass to the various structures of the lid. Many of the fibres end freely in fine networks around the tarsal glands, upon the blood-vessels, and in the epithelium of the conjunctiva. Other fibres terminate in end-bulbs which are especially numerous at the margin of the lid.

Development of the Eye

The eyes begin their development very early in embryonic life. As *optic depressions* they are visible even before the closure of the medullary groove.

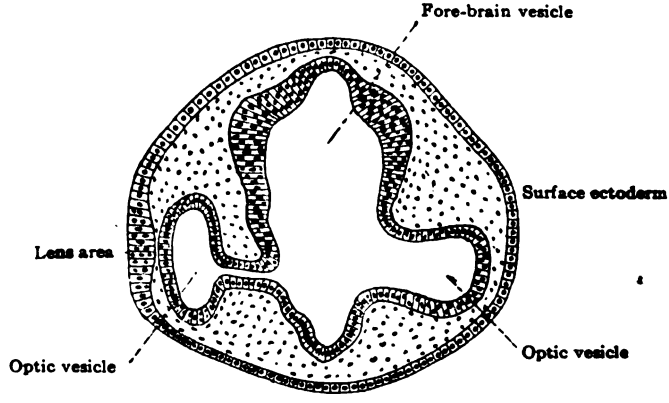

FIG. 408.—Section through head of chick of two days' incubation. (Duval.) The formation of the optic vesicle and stalk appears to be somewhat more advanced on the left than on the right.

As a result of the closure of this groove, the optic depressions are transformed into the *optic vesicles*. The connection between vesicle and brain now becomes narrowed so that the two are connected only by the thin *optic stalk*. The surface of the optic vesicle becomes firmly adherent to the epidermis and as a

result of proliferation of ectodermic cells at this point is pushed inward (invaginated), forming the *optic cup*. The invagination of the optic vesicle extends also to the stalk, the sulcus in the latter being known as the *chorioid*

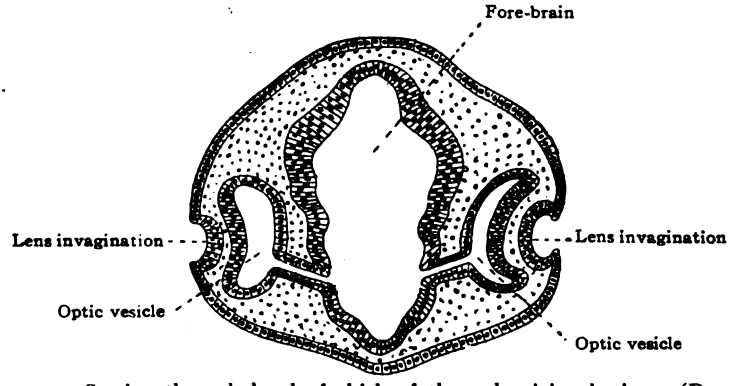

FIG. 409.—Section through head of chick of three days' incubation. (Duval.)

fissure. The latter serves for the introduction of mesenchyme, and the development of the hyaloid retinal artery. Three distinct parts may now be distinguished in the developing eye, which at this stage is known as the *secondary*

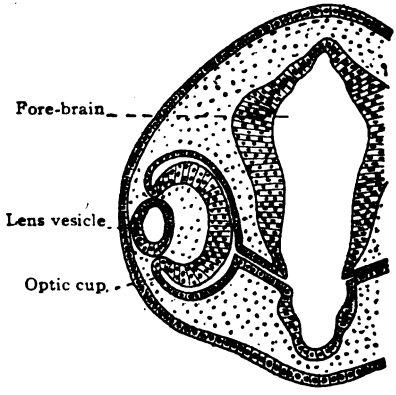

FIG. 41C.—Showing somewhat later stage in development of optic cup and lens than is shown in Fig. 409. (Duval.)

optic vesicle: (*a*) The proliferating epidermis which is to form the lens; (*b*) the more superficial of the invaginated layers which is to become the retina; and (*c*) the surrounding mesodermic tissue from which the outer coats of the eye are to develop.

TECHNIC

(1) For the study of the general structures of the eyeball the eye of some large animal, such as an ox, is most suitable. Fix the eye for about a week in ten-

per-cent. formalin. Then wash in water and bisect the eye in such a manner that the knife passes through the optic-nerve entrance and the centre of the cornea. The half eye should now be placed in a dish of water and the structures shown in Fig. 393 identified with the naked eye or dissecting lens. On removing the vitreous and retina, the pigmented epithelium of the latter usually remains attached to the chorioid from which it may be scraped and examined in water or mounted in glycerin. In removing the lens note the lens capsule and the suspensory ligament. The lens may be picked to pieces with the forceps, and a small piece, after further teasing with needles, examined in water or mounted in glycerin or eosin-glycerin. The retinal surface of the chorioid shows the iridescent membrane of Bruch. By placing a piece of the chorioid, membrane-of-Bruch-side down, over the tip of the finger and gently scraping with a knife in

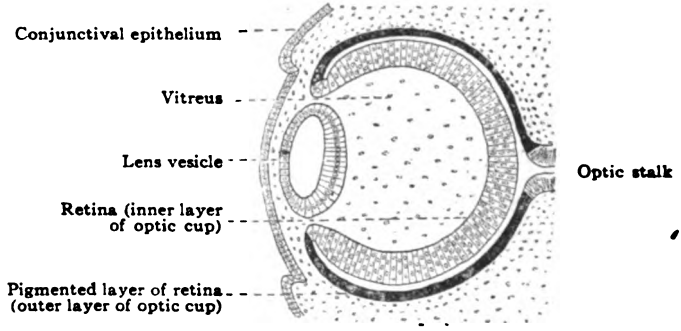

FIG. 411.—Diagram of developing lens and optic cup. (Duval.) The cells of the inner wall of the lens vesicle have begun to elongate to form lens fibres. The epithelium over the lens is the anlage of the corneal epithelium. The mesodermal tissue between the latter and the anterior wall of the lens vesicle is the anlage of the substantia propria corneæ.

the direction of the larger vessels, the latter may be distinctly seen. By now staining the piece lightly with hæmatoxylin and strongly with eosin, clearing in oil or origanum and mounting in balsam, the choriocapillaris and the layer of straight vessels become distinctly visible with the low-power lens. In removing the chorioid note the close attachment of the latter to the sclera, this being due to the intimate association of the fibres of the lamina suprachorioidea and of the lamina fusca. If the brown shreds attached to the inner side of the sclera be examined, the pigmented connective-tissue cells of the sclera can be seen.

(2) For the study of the finer structure of the coats of the eye, a human eye if it is possible to obtain one, if not, an eye from one of the lower animals, should be fixed in formalin-Müller's fluid (technic 6, p. 7) and hardened in alcohol. (A few drops of strong formalin injected by means of a hypodermic needle directly into the vitreous often improves the fixation.) The eye should next be divided into quadrants by first carrying the knife through the middle of the cornea and of the optic-nerve entrance, and then dividing each half into an anterior and a posterior half. Block in celloidin, cut the following sections, and stain with hæmatoxylin-eosin (technic 1, p. 23).

(*a*) Section through the sclero-corneal junction, including the ora serrata.

ciliary body, iris, and lens. Before attempting to cut this section almost all of the lens should be picked out of the block, leaving only a thin anterior and lateral rim attached to the capsule and suspensory ligament. The block should then be so clamped to the microtome that the lens is the last part of the block to be cut. The above precautions are necessary on account of the density of the lens, making it difficult to cut.

(*b*) Section through the postero-lateral portion of the eyeball to show structure of sclera, chorioid, and retina. This section should be as thin as possible and perpendicular to the surface.

(*c*) Section through the entrance of the optic nerve. Hæmatoxylin-picro-acid-fuchsin also makes a good stain for this section. It is instructive in cutting the eye to cut a small segment from the optic nerve and to block it with the optic-nerve entrance material in such a manner that it is cut transversely. In this way both longitudinal and transverse sections of the optic nerve appear in the same section.

(*d*) For the study of the neurone relations of the retina, material must be treated by one of the Golgi methods (page 36).

(4) The connective-tissue cells and cell spaces of the cornea may be demonstrated by means of technics 8 and 9, page 100.

(5) The different parts of the lacrymal apparatus may be studied by fixing material in formalin-Müller's fluid and staining sections in hæmatoxylin-eosin.

(6) The Eyelid. An upper eyelid, human if possible, should be carefully pinned out on cork, skin side down, and fixed in formalin-Müller's fluid. Vertical sections should be stained with hæmatoxylin-eosin or with hæmatoxylin-picro-acid-fuchsin.

The Organ of Hearing

The organ of hearing comprises the external ear, the middle ear, and the internal ear.

The External Ear

The external ear consists of the pinna or auricle, the external auditory canal, and the outer surface of the tympanic membrane.

The *pinna* consists of a framework of elastic cartilage embedded in connective tissue and covered by skin. The latter is thin and contains hairs, sebaceous glands, and sweat glands.

The *external auditory canal* consists of an outer cartilaginous portion and an inner bony portion. Both are lined with skin continuous with that of the surface of the pinna. In the cartilaginous portion of the canal the skin is thick and the papillæ are small. Hair, sebaceous glands, and large coiled glands (*ceruminous glands*) are present. The last named resemble the glands of Mall (page 647) and are probably modified sweat glands. Their cells contain numerous fat droplets and

pigment granules. They have long narrow ducts lined with a two-layered epithelium. In children these ducts open into the hair follicles; in the adult they open on the surface near the hair follicles. The secretion of these glands plus desquamated epithelium constitutes the *ear wax*. In the bony portion of the canal the skin is thin, free from glands and hair, and firmly adherent to the periosteum.

The *tympanic membrane* (ear drum) separates the external ear from the middle ear. It consists of three layers: a middle layer or substantia propria, an outer layer continuous with the skin of the external ear, and an inner layer continuous with the mucous membrane of the middle ear.

The substantia propria consists of closely woven connective-tissue fibres, the outer fibres having a radial direction from the head of the malleus, the inner fibres having a concentric arrangement and being best developed near the periphery.

The outer layer of the tympanic membrane is skin, consisting of epidermis and of a thin non-papillated corium, excepting over the manubrium of the malleus, where the skin is thicker and papillated.

The inner layer is mucous membrane and consists of a stroma of fibro-elastic tissue covered with a single layer of low epithelial cells.

Blood-vessels.—Blood is supplied to the tympanic membrane by two sets of vessels, an external set derived from the vessels of the external auditory meatus and an internal set from the vessels of the middle ear. These give rise to capillary networks in the skin and mucous membrane, respectively, and anastomose by means of perforating branches at the periphery of the membrane. From the capillaries the blood passes into two sets of small veins, one extending around the periphery of the membrane, the other following the handle of the malleus.

Lymphatics.—These follow in general the course of the blood-vessels. They are most numerous in the outer layer.

Nerves.—The larger nerves run in the substantia propria. From these, branches pass to the skin and mucous membrane, beneath the surfaces of which they form plexuses of fine fibres.

The Middle Ear

The middle ear or *tympanum* is a small chamber separated from the external ear by the tympanic membrane and communicating with the pharynx by means of the Eustachian tube. Its walls are formed

by the surrounding bony structures covered by periosteum. It is lined with mucous membrane and contains the ear ossicles and their ligamentous and muscular attachments. The epithelium is mainly of the squamous type except in the region of the orifices of the Eustachian tube when it is creboidal and ciliated. Areas of ciliated cells also occur in other parts of the lympanic mucosa especially its flow. Beneath the epithelium is a thin stroma which may contain a little diffuse lymphoid tissue and blends with the dense, underlying periosteum. Small tubular glands may be present, especially near the opening of the Eustachian tube.

The *fenestra rotunda* is covered by the secondary tympanic membrane. This consists of a central lamina of connective tissue covered on its tympanic side by part of the mucous membrane of that chamber, on the opposite side by a single layer of endothelium.

The *ossicles* are composed of bone tissue arranged in the usual systems of lamellæ. The *stapes* alone contains a marrow cavity. Over their articular surfaces the ossicles are covered by hyaline cartilage.

The Eustachian Tube.—This is a partly bony, partly cartilaginous canal lined with mucous membrane. The epithelium of the latter is of the stratified columnar ciliated variety consisting of two layers of cells. In the bony portion of the tube the stroma is small in amount and intimately connected with the periosteum. In the cartilaginous portion the stroma is thicker and contains, especially near the pharyngeal opening, lymphoid tissue and simple tubular mucous glands.

The Internal Ear

The internal ear consists of a complex series of connected bony walled chambers and passages containing a similar-shaped series of membranous sacs and tubules. These are known, respectively, as the *osseous labyrinth* and the *membranous labyrinth*. Between the two is a lymph space, which contains the so-called *perilymph*, while within the membranous labyrinth is a similar fluid, the *endolymph*.

The bony labyrinth consists of a central chamber, the *vestibule*, from which are given off the three *semicircular canals* and the *cochlea*. The vestibule is separated from the middle ear by a plate of bone in which are two openings, the *fenestra ovalis* and the *fenestra rotunda*. Just after leaving the vestibule each canal presents a dilatation, the *ampulla*. As each canal has a return opening into the vestibule and as the anterior and posterior canals have a common return opening

(the *canalis communis*), there are five openings from the vestibule into the semicircular canals (Fig. 412). The bony labyrinth is lined with periosteum, covered by a single layer of endothelial cells.

The Vestibule and the Semicircular Canals.—In the vestibule the membranous labyrinth is subdivided into two chambers, the *saccule* and the *utricle*, which are connected by the *utriculo-saccular duct*. From the latter is given off the *endolymphatic duct* which communicates, through the aqueduct of the vestibule, with a subdural lymph space, the *endolymphatic sac*. The saccule opens by means of the *ductus reuniens* into the cochlea, while the utricle opens into the ampullæ of the semicircular canals. The saccule and utricle only partly fill the vestibule, the remaining space, crossed by fibrous bands and lined with endothelium, constituting the perilymphatic space.

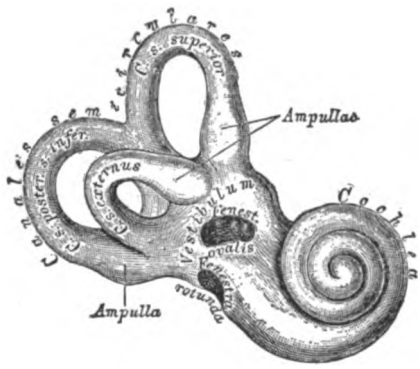

FIG. 412.—The Bony Labyrinth. ×3. (Heitzmann.)

SACCULE AND UTRICLE.—The walls of the saccule and of the utricle consist of fine fibro-elastic tissue supporting a thin basement membrane, upon which rests a single layer of low epithelial cells. In the wall of each chamber is an area of special nerve distribution, the *macula acustica*. Here the epithelium changes to high columnar and consists of two kinds of cells, sustentacular and neuro-epithelial. The *sustentacular cells* are long, irregular, nucleated cylinders, narrow in the middle, widened at each end, the outer end being frequently split and resting upon the basement membrane. The *neuro-epithelial cells* or "hair cells" are short cylinders which extend only about halfway through the epithelium. The basal end of the cell is the larger and contains the oval nucleus. The surface of the cell is provided with a cuticular margin from which project several long hair-like processes, the *auditory hairs*. Small crystals of calcium carbonate are found on the surfaces of the hair cells. These are known as *otoliths* and are embedded in a soft substance, the *otolithic membrane*. The hair cells are the neuro-epithelial end-organs of the vestibular division of the auditory nerve and are, therefore, closely associated with the nerve fibres. The latter on piercing the basement membrane

lose their medullary sheaths and split up into several small branches, which form a horizontal plexus between the basement membrane and the bases of the hair cells. From this plexus are given off fibrils which end freely between the hair cells.

SEMICIRCULAR CANALS.—The walls of the semicircular canals are similar in structure to the walls of the saccule and utricle; they also bear a similar relation to the walls of the bony canal. Along the concavity of each canal the epithelium is somewhat higher, forming the

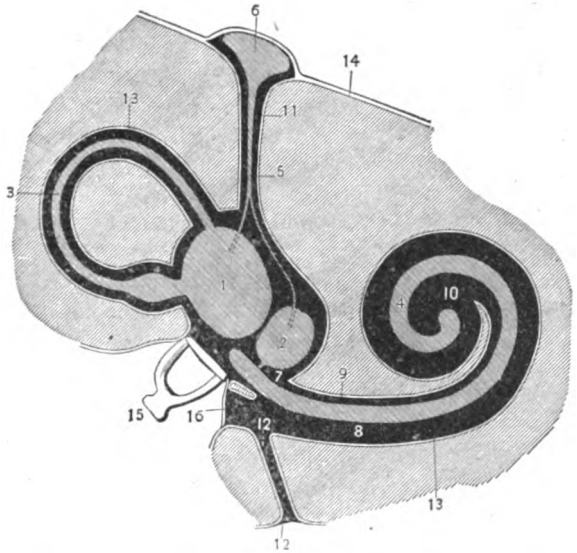

FIG. 413.—Diagram of the Perilymphatic and Endolymphatic Spaces of the Inner Ear. (Testut.) Endolymphatic spaces in gray; perilymphatic spaces in black. 1, Utricle; 2, saccule; 3, semicircular canals; 4, cochlear canal; 5, endolymphatic duct; 6, subdural endolymphatic sac; 7, canalis reuniens; 8, scala tympani; 9, scala vestibuli; 10, their union at the helicotrema; 11, aqueduct of the vestibule; 12, aqueduct of the cochlea; 13, periosteum; 14, dura mater; 15, stapes in fenestra ovalis; 16, fenestra rotunda and secondary tympanic membrane.

raphé. In each ampulla is a *crista acustica*, the structure of which is similar to that of the maculæ of the saccule and utricle. With the adjoining high columnar cells, this forms the so-called *semilunar fold.* As in the case of the maculæ the hair cells have otoliths upon their surfaces, the otolithic membrane here forming a sort of dome over the hair cells known as the *cupula.*

The Cochlea.—The bony cochlea consists of a conical axis, the *modiolus*, around which winds a spiral bony canal. This canal in man makes about two and one-half turns, ending at the rounded tip of the cochlea or *cupola.* Projecting from the modiolus partly across

the bony canal of the cochlea is a plate of bone, the *bony spiral lamina* (Fig. 416, *x*). This follows the spiral turns of the cochlea, ending at the cupola in a hook-shaped process, the *hamulus*. Along the outer

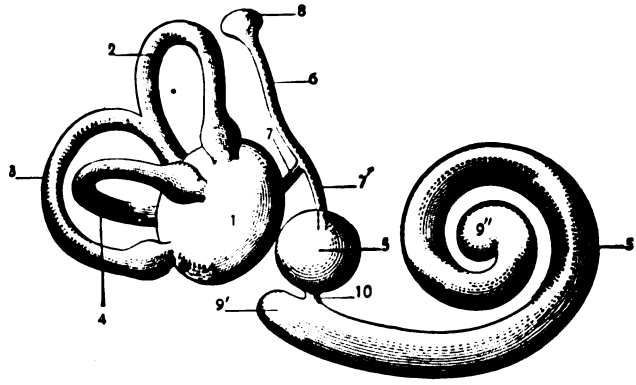

FIG. 414.—Diagram of the Right Membranous Labyrinth. (Testut.) 1, Utricle; 2, superior semicircular canal; 3, posterior semicircular canal; 4, external semicircular canal; 5, saccule; 6, endolymphatic duct; 7 and 7', canals connecting utricle and saccule respectively with the endolymphatic duct; 8, endolymphatic sac; 9, cochlear duct; 9', its vestibular cul-de-sac; 9'', its terminal cul-de-sac; 10, canalis reuniens.

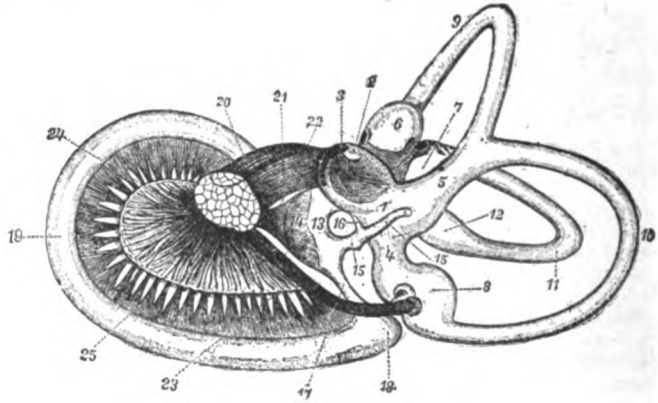

FIG. 415.—The Membranous Labyrinth from the Right Internal Ear of a Human Embryo at the Fifth Month; seen from the Medial Side. (After Retzius, from Barker.) 1–5, Utricle; 2, utricular recess; 3, macula acustica of utricle; 4, posterior sinus; 5, superior sinus; 6, 7, 8, superior, lateral, and posterior ampullæ; 9, 10, 11, superior, posterior, and lateral semicircular canals; 12, widened mouth of lateral semicircular canal opening into the utricle; 13, saccule; 14, macula acustica of the saccule; 15, endolymphatic duct; 16, utriculo-saccular duct; 17, ductus reuniens; 18, vestibular cul-de-sac of cochlear duct; 19, cochlear duct; 20, facial nerve; 21–24, auditory nerve; 21, its vestibular branch; 22, saccular branch; 23, branch to inferior ampulla; 24, cochlear branch; 25, distribution of cochlear branch within the bony spiral lamina.

side of the canal, opposite the bony spiral lamina, is a projection of thickened periosteum, the *spiral ligament* (Fig. 416, *h*). A connective-tissue membrane, the *membranous spiral lamina* (Fig. 416, *s*)

crosses the space intervening between the spiral ligament and the bony spiral lamina, thus completely dividing the bony canal of the cochlea into two parts, an upper, *scala vestibuli* (Fig. 416, *l*) and a lower, *scala tympani* (Fig. 416, *k*). These are perilymphatic spaces, the scala vestibuli communicating with the perilymph space of the vestibule, the scala tympani communicating with the perivascular

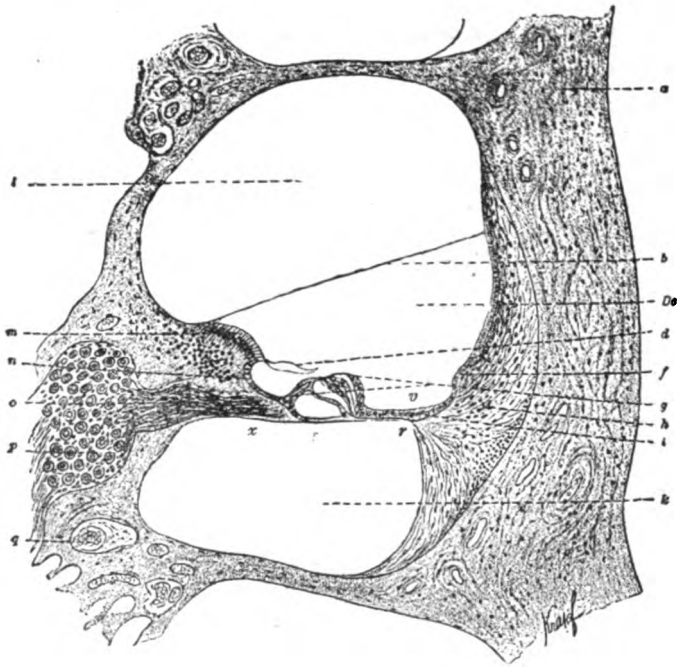

FIG. 416.—Section through a Single Turn of the Cochlea of a Guinea-pig. (Böhm and von Davidoff.) *a*, Bone of cochlea; *l*, scala vestibuli, *Dc*, scala media or cochlear duct; *k*, scala tympani; *b*, membrane of Reissner; *d*, membrana tectoria or membrane of Corti; *f*, spiral prominence; *g*, organ of Corti; *h*. spiral ligament; *i*, basilar membrane (outer portion—zona pectinata—covered by cells of Claudius); *z*, stria vascularis; *v*, external spiral sulcus; *r*, crista basilaris; *s*, membranous spiral lamina; *x*, bony spiral lamina; *m*, spiral limbus; *n*, internal spiral sulcus; *o*, medullated peripheral processes (dendrites) of cells of spiral ganglion passing to the organ of Corti; *p*, spiral ganglion; *q*, blood-vessel.

lymph spaces of the veins of the cochlear duct. The scala vestibuli and the scala tympani communicate with each other in the cupola by means of a minute canal, the *helicotrema*.

THE COCHLEAR DUCT (*Membranous Cochlea or Scala Media*).—This is a narrow, membranous tube lying near the middle of the bony cochlear canal and following its spiral turns from the vestibule, where it is connected with the saccule through the canalis reuniens,

to its blind ending in the cupola. It is triangular in shape on transverse section, thus allowing a division of its walls into upper, outer, and lower (Fig. 416, *Dc*).

The upper or vestibular wall is formed by the thin *membrane of Reissner* (Fig. 416, *b*) which separates the cochlear duct from the scala vestibuli. The membrane consists of a thin central lamina of connective tissue covered on its vestibular side by the vestibular endothelium, on its cochlear side by the epithelium of the cochlea.

The outer wall of the cochlear duct is formed by the spiral ligament, which is a thickening of the periosteum. The outer part of the spiral ligament consists of dense fibrous tissue, its projecting part of more loosely arranged tissue. From it, two folds project slightly into the duct. One, the *crista basilaris* (Fig. 416, *r*), serves for the attachment of the membranous spiral lamina; the other, the *spiral prominence* (Fig. 416, *f*), contains several small veins. Between the two projections is a depression, the *external spiral sulcus* (Fig. 416, *v*). That part of the spiral ligament between the spiral prominence and the attachment of Reissner's membrane is known as the *stria vascularis* (Fig. 416, *z*). It is lined with granular cuboidal epithelial cells, which, owing to the absence of a basement membrane, are not sharply separated from the underlying connective tissue. For this reason the capillaries extend somewhat between the epithelial cells, giving the unusual appearance of a vascular epithelium.

The lower or tympanic wall of the cochlear duct has an extremely complex structure. Its base is formed by the already mentioned bony and membranous division-wall between the scala media and the scala tympani (bony spiral lamina and membranous spiral lamina).

The bony spiral lamina has been described (page 656).

The membranous spiral lamina consists of a substantia propria or basilar membrane, its tympanic covering, and its cochlear covering.

The *basilar membrane* (Fig. 416) is a connective-tissue membrane composed of fine straight fibres which extend from the bony spiral lamina to the spiral ligament. Among the fibres are a few connective-tissue cells. On either side of the fibre layer is a thin, apparently structureless membrane.

The *tympanic covering* of the basilar membrane consists of a thin layer of connective tissue—an extension of the periosteum of the spiral lamina—covered over by a single layer of flat endothelial cells.

The *cochlear covering* of the basilar membrane is epithelial. Owing to the marked difference in the character of the epithelium, the basilar

membrane is divided into an outer portion, the *zona pectinata* (Fig. 416, *i*) and an inner portion, the *zona tecta* (Fig. 416, *s*). The epithelium of the former is of the ordinary columnar type; that of the latter is the highly differentiated neuro-epithelium of Corti's organ.

The Organ of Corti.—The spiral organ or the organ of Corti (Fig. 416, *g*, and Fig. 417) is a neuro-epithelial structure running the entire length of the cochlear canal with the exception of a short distance at either end. It rests upon the membranous portion of the spiral amina, and consists of a complex arrangement of four different kinds

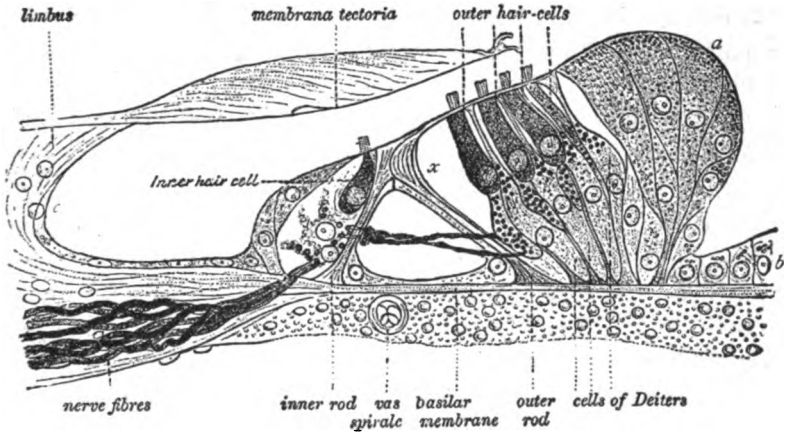

FIG. 417.—Semidiagrammatic Representation of the Organ of Corti and Adjacent Structures (Merkel-Henle.) *a*, Cells of Hensen; *b*, cells of Claudius; *c*, internal spiral sulcus; *x*, Nuel's space. The nerve fibres (dendrites of cells of the spiral ganglion) are seen passing to Corti's organ through openings (foramina nervosa) in the bony spiral lamina. The black dots represent longitudinally-running branches, one bundle lying to the inner side of the inner pillar, a second just to the outer side of the inner pillar within Corti's tunnel, the third beneath the outer hair cells.

of epithelial cells. These are known as: (1) pillar cells, (2) hair cells, (3) Deiter's cells, and (4) Hensen's cells (Fig. 417).

(1) The *pillar cells* are divided into *outer pillar cells* and *inner pillar cells*. They are sustentacular in character. Each cell consists of a broad curved protoplasmic base which contains the nucleus, and of a long-drawn-out shaft or pillar which probably represents a highly specialized cuticular formation. The end of the pillar away from the base is known as the *head*. The head of the outer pillar presents a convexity on its inner side, which fits into a corresponding concavity on the head of the inner pillar, the heads of opposite pillars thus "articulating" with each other. From their articulation the pillars diverge, so that their bases which rest upon the basilar membrane are

widely separated. There are thus formed by the pillars a series of arches known as *Corti's arches*, enclosing a triangular canal, *Corti's tunnel*. This canal is filled with a gelatinous substance and crossed by delicate nerve fibrils. As the outer pillar cells are the larger, they are fewer in number, the estimated number in the human cochlea being forty-five hundred of the outer cells and about six thousand of the inner cells.

(2) The *hair cells* or *auditory cells* lie on either side of the arches of Corti, and are thus divided into inner hair cells and outer hair cells. Both inner and outer hair cells are short, cylindrical elements which do not extend to the basilar membrane. Each cell ends below in a point, while from its free surface are given off a number of fine stiff hairs.

The inner hair cells lie in a single layer against the inner side of the inner pillar cells, one hair cell resting upon about every two pillars.

The outer hair cells lie in three or four layers to the outer side of the outer pillar cells, being separated from one another by sustentacular cells, the cells of Deiter, so that no two hair cells come in contact.

(3) *Deiter's Cells* (Fig. 417).—These like the pillar cells are sustentacular. Their bases rest upon the basilar membrane, where they form a continuous layer. Toward the surface they become separated from one another by the hair cells. The long slender portions of the Deiter's cells, which pass in between the hair cells, are known as *phalangeal processes*. Between the innermost of the outer hair cells and the outer pillar is a space known as *Nuel's space* (Fig. 417, *x*).

(4) *Hensen's Cells* (Fig. 417, *a*).—These are sustentacular cells, which form about eight rows to the outer side of the outermost Deiter's cells. These cells form the outer crest of Corti's organ and consequently have a somewhat radial disposition, their free surfaces being broad, their basal ends narrow. They decrease in height from within outward, and at the end of Corti's organ become continuous with the cells of Claudius (Fig. 417, b), the name given to the cochlear epithelium covering the basal membrane to the outer side of Corti's organ.

The phalangeal processes of the Deiter's cells are cemented together and to the superficial parts of the outer pillars in such a manner as to form a sort of cuticular membrane, the *lamina reticularis*, through which the heads of the outer hair cells project. This mem-

brane also extends out as a cuticula over the cells of Hensen and of Claudius.

The Membrana Tectoria.—This is a peculiar membranous structure attached to a projection of the bony spiral lamina known as the *spiral limbus* (Fig. 417), the concavity beneath its attachment being the *internal spiral sulcus* (Fig. 417, *c*). The membrane is non-nucleated and shows fine radial striations. It bridges over the internal spiral sulcus and ends in a thin margin, which rests upon Corti's organ just at the outer limit of the outer hair cells.

Blood-vessels.—The arteries consist of two small branches of the auditory—one to the bony labyrinth, the other to the membranous labyrinth. The latter divides into two branches—a vestibular and a cochlear. The vestibular artery accompanies the branches of the auditory nerve to the utricle, saccule, and semicircular canals. It supplies these parts, giving rise to a capillary network, which is coarse meshed except in the cristæ and maculæ, where the meshes are fine. The cochlear artery also starts out in company with the auditory nerve, but accompanies it only to the first turn of the cochlea. Here it enters the modiolus where it gives off several much coiled branches, the glomerular arteries of the cochlea. Branches from these pierce the vestibular part of the osseous spiral lamina and supply the various structures of the cochlear duct. The veins accompany the arteries, but reach the axis of the modiolus through foramina in the tympanic part of the bony spiral lamina.

Lymphatics.—The scala media contains endolymph and is in communication with the subdural lymph spaces by means of the endolymphatic duct, the endolymphatic sac, and minute lymph channels connecting the latter with the subdural spaces. The perilymph spaces—scala tympani and scala vestibuli—are connected with the pial lymph spaces by means of the perilymphatic duct. Lymph spaces also surround the vessels and nerves. These empty into the pial lymphatics.

Nerves.—The vestibular branch of the auditory nerve divides into branches which supply the saccule, utricle, and semicircular canals, where they end in the maculæ and cristæ as described on page 581. The ganglion of the vestibular branch is situated in the internal auditory meatus. The cochlear branch of the auditory nerve enters the axis of the modiolus, where it divides into a number of branches which pass up through its central axis. From these,

numerous fibres radiate to the bony spiral laminæ, in the bases of which they enter the spiral ganglia (Fig. 416, *p*).

The cells of the spiral ganglia are peculiar, in that while of the same general type as the spinal ganglion cell they maintain their embryonic bipolar condition (see page 427) throughout life. Their axones follow the already described course through the modiolus and thence through the internal auditory meatus to their terminal nuclei in the medulla (see page 544). Their dendrites become medullated like the dendrites of the spinal ganglion cells and pass outward in bundles in the bony spiral lamina (Fig. 416, *o*, and Fig. 417). From these are given off branches which enter the tympanic portion of the lamina, where they lose their medullary sheaths and pass through the foramina nervosa (minute canals in the tympanic part of the spiral lamina) to their terminations in the organ of Corti. In the latter the fibres run in three bundles parallel to Corti's tunnel. One bundle lies just inside the inner pillar beneath the inner row of hair cells (Fig. 417). A second bundle runs in the tunnel to the outer side of the inner pillar (Fig. 417). The third bundle crosses the tunnel (tunnel-fibres) and turns at right angles to run between the cells of Deiter beneath the outer hair cells (Fig. 417). From all of these bundles of fibres are given off delicate terminals which end on the hair cells. (For details of acoustic tract see pp. 505, 510, and 544.)

Development of the Ear

The essential auditory part of the organ of hearing, the membranous labyrinth, is of ectodermic origin. This first appears as a thickening followed by an invagination of the surface ectoderm in the region of the posterior cerebral vesicle. This is known as the *auditory pit*. By closure of the lips of this pit and growth of the surrounding mesodermic tissue is formed the *otic vesicle* or *otocyst*, which is completely separated from the surface ectoderm. Diverticula soon appear passing off from the otic vesicle. These are three in number and correspond respectively to the future endolymphatic duct, the cochlear duct and the membranous semicircular canals. Within the saccule, utricle, and ampullæ special differentiations of the lining epithelium give rise to the maculæ and cristæ acusticæ. Of the cochlear duct the upper and lateral walls become thinned to form Reissner's membrane and the epithelium of the outer wall, while the lower wall becomes the basilar membrane, its epithelium undergoing an elaborate specialization to form the organ Corti.

Of the cochlea, only the membranous cochlear duct develops from the otic vesicle; the scala vestibuli, scala tympani, and bony cochlea developing from the surrounding mesoderm. The mesodermic connective tissue at first com-

pletely fills in the space between the cochlear duct and the bony canal. Absorption of this tissue takes place, resulting in formation of the scala tympani and scala vestibuli.

During the differentiation of the above parts a constriction appears in the body of the primitive otic vesicle. This results in the incomplete septum which divides the utricle from the saccule.

The middle ear is formed from the upper segment of the pharyngeal groove, the lower segment giving rise to the Eustachian tube.

The external ear is developed from the ectoderm of the first branchial cleft and adjacent branchial arches. The tympanic membrane is formed from the mesoderm of the first branchial arch, its outer covering being of ectodermic, its inner of entodermic origin.

TECHNIC

(1) For the study of the general structure of the pinna and walls of the external auditory meatus, material may be fixed in formalin-Müller's fluid (technic 6, p. 7) and sections stained with hæmatoxylin-eosin (technic 1, p. 23). In sections of the wall of the cartilaginous meatus the ceruminous glands may be studied, material from children and from new-born infants furnishing the best demonstrations of these glands.

(2) For the study of the inner ear the guinea-pig is most satisfactory on account of the ease with which the parts may be removed. Remove the cochlea of a guinea-pig with as much as possible of the vestibule and semicircular canals and fix in Flemming's fluid (technic 8, p. 8). A small opening should be made in the first turn of the cochlea in order to allow the fixative to enter the canal. After forty-eight hours the cochlea is removed from the fixative and hardened in graded alcohols (page 9). The bone is next decalcified, either by one of the methods mentioned on page 10 or in saturated alcoholic solution of picric acid. If one of the aqueous decalcifying fluids is used, care must be taken to carry the material through graded alcohols. Embed in celloidin or paraffin, cut sections through the long axis of the modiolus, through the utricle and saccule, and through the semicircular canals. Stain with hæmatoxylin-eosin and mount in balsam.

(3) The neurone relations of the cristæ, maculæ, and cochlear duct can be demonstrated only by means of the Golgi method. The ear of a new-born mouse or guinea-pig furnishes good material. The cochlea together with some of the base of the skull should be removed and treated by the Golgi rapid method (page 36). Sections should be thick and must of course be cut through undecalcified bone. Good results are difficult to obtain.

The Organ of Smell

The olfactory organ consists of the olfactory portion of the nasal mucosa. In this connection it is, however, convenient to describe briefly the *olfactory bulb* and the *olfactory tract.*

The Olfactory Mucosa.—This has been described (page 305). The

peculiar olfactory cells there described are not neuro-epithelium but are analogs of the spinal ganglion cell, being the only example in man of the peripherally placed ganglion cell found in certain lower animals. Each cell sends to the surface a short dendrite which ends in several short, stiff, hair-like processes. From its opposite end each cell gives off a longer centrally directed process (axone), which as a fibre of one of the olfactory nerves passes through the cribriform plate of the ethmoid (Fig. 418, *ethm*) to its terminal nucleus in the olfactory bulb (Fig. 418).

The Olfactory Bulb.—This is a somewhat rudimentary structure analogous to the much more prominent olfactory brain lobe of some

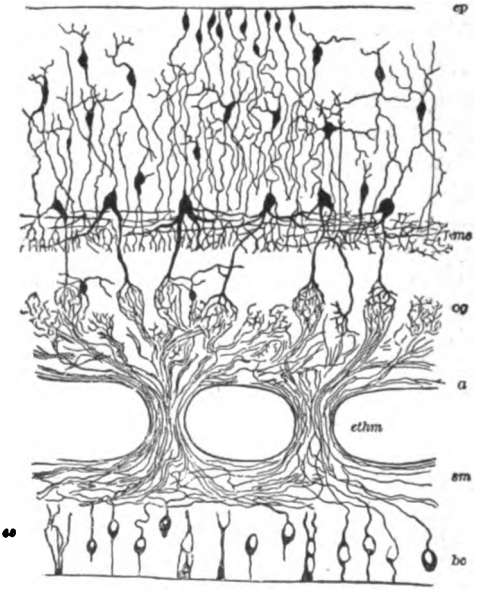

FIG. 418.—Diagram of Structure of Olfactory Mucosa and Olfactory Bulb. (Ramón y Cajal.) *bc*, Bipolar cells of olfactory mucosa; *sm*, submucosa; *ethm*, cribriform plate of ethmoid; *a*, layer of olfactory fibres; *og*, olfactory glomeruli; *me*, mitral cells; *ep*, epithelium of olfactory ventricle.

of the lower animals. It consists of both gray matter and white matter arranged in six fairly distinct layers. These from below upward are as follows: (*a*) The layer of olfactory fibres; (*b*) the layer of glomeruli; (*c*) the molecular layer; (*d*) the layer of mitral cells; (*e*) the granule layer; (*f*) the layer of longitudinal fibre bundles. Through the centre of the last-named layer runs a band of neuroglia which represents the obliterated lumen of the embryonal lobe. The relations of these layers to the olfactory neurone system are as follows:

The layer of olfactory fibres (Fig. 418, *a*) consists of a dense plexiform arrangement of the axones of the above-described olfactory cells. From this layer the axones pass into the layer of olfactory glomeruli where their terminal ramifications mingle with the dendritic terminals of cells lying in the more dorsal layers, to form distinctly outlined spheroidal or oval nerve fibre nests, the *olfactory glomeruli* (Fig. 418, *og*). The latter mark the ending of neurone system No. I. of the olfactory conduction path. (For olfactory tract see pp. 505, 510.)

The molecular layer contains both small nerve cells and large nerve cells. These send their dendrites into the olfactory glomeruli. The smaller cells belong to Golgi Type II. (see page 135) and appear to be association neurones between adjacent glomeruli. The axones of the larger cells, the so-called brush cells, become fibres of the *olfactory tract.*

Of the mitral cells (Fig. 418, *me*), the main dendrites end in the olfactory glomeruli, while their axones, like those of the brush cells, become fibres of the *olfactory tract.*

In addition to the fibres which pass through it (axones of mitral and of brush cells), the granular layer contains numerous nerve cells. Many of these are small and apparently have no axones (amacrine cells). Their longer dendrites pass toward the periphery, their shorter dendrites toward the olfactory tract. Larger multipolar cells, whose axones end in the molecular layer, also occur in the granular layer.

The layer of longitudinal fibre bundles consists mainly of the centrally directed axones of the mitral and brush cells. These fibres run in distinct bundles separated by neuroglia. Leaving the bulb they form the olfactory tract by means of which they pass to their cerebral terminations.

The brush cells and mitral cells with their processes thus constitute neurone system No. II. of the olfactory conduction path.

TECHNIC

(1) Carefully remove the olfactory portion of the nasal mucosa (if human material is not available, material from a rabbit is quite satisfactory). This may be recognized by its distinctly brown color. Fix in Flemming's fluid (technic 8, p. 8), or in Zenker's (technic 10, p. 8). Stain thin vertical sections with hæmatoxylin-eosin (technic 1, p. 23) and mount in balsam.

(2) For the study of the nerve relations of the olfactory cells material should be treated by the rapid Golgi method (page 36).

The Organ of Taste

The organ of taste consists of the so-called taste buds of the lingual mucosa. These have been mentioned in connection with the papillæ of the tongue (page 231) and under sensory end-organs (p. 444).

The taste buds are found in the side walls of the circumvallate papillæ (page 231), of some few of the fungiform papillæ, in the mucosa of the posterior surface of the epiglottis, and especially in folds (foliate papillæ) which occur along the postero-lateral margin of the tongue.

The taste bud (Fig. 419) is an ovoid epithelial structure embedded in the epithelium and connected with the surface by means of a minute canal, the gustatory canal (Fig. 419, *a*), the outer and inner ends of which are known, respectively, as the outer and inner taste pores.

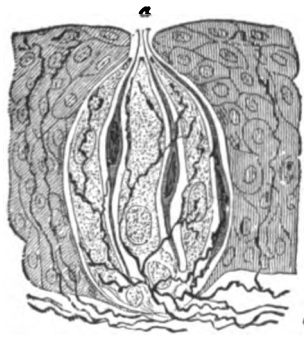

FIG. 419.—Taste-bud from Side Wall of Circumvallate Papilla. (Merkel-Henle.) *a*, Taste-pore; *b*, nerve fibres, some of which enter the taste-bud—intrageminal fibres; while others end freely in the surrounding epithelium—intergeminal fibres.

Each taste bud consists of two kinds of cells, neuro-epithelial cells or gustatory cells and sustentacular cells (Fig. 419). The gustatory cells are long, delicate, spindle-shaped cells which occupy the centre of the taste bud, each ending externally in a cilium-like process, which usually projects through the inner pore. The inner end of the cell tapers down to a fine process, which may be single or branched. The sustentacular cells are long, slender cells which form a shell several cells thick around the gustatory cells. Sensory terminals of the glosso-pharyngeal nerves (Fig. 419, *b*) end within the taste buds in a network of varicose fibres—*intrageminal fibres*. Other sensory terminals of the same nerve end freely in the epithelium between the taste buds. These are finer and smoother than the intrageminal fibres and are known as *intergeminal fibres* (Fig. 419).

TECHNIC

(1) The general structure of the taste buds is shown in the sections of tongue (technic, p. 232).

(2) For the study of the nerve terminals the method of Golgi should be used (page 36).

General References for Further Study

Kölliker: Handbuch der Gewebelehre des Menschen.
McMurrich: The Development of the Human Body.
Ramón y Cajal: La rétine des vertébrés. La Cellule, ix., 1893.
Schwalbe: Lehrbuch der Anatomie der Sinnesorgane, 1887.

INDEX

Abducens (nerve VI), 506, 509, 516, 522, 559, 561;
see also *Nerves, cranial*
Absorption, 277
of fat, 279
Accessorius (nerve XI), 513, 527
Accessory, chromosomes, 56, 350*b*
nasal sinuses, 305
olivary nucleus, 523, 533, 541
Achromatic element of intranuclear network, 49, 132
spindle, 54*b*
Acid aniline dyes, 23
cells, 254, 415
Acidophile, cells, 415
granules, 110, 265
leuco cytes, 110
Acini, 222
Acoustic group of segmental neurones, 505
tubercle, 544
Acromegaly, 415*b*
Acrosome, 350
Acusticus (nerve VIII), 544; see *Nerves, cranial*
Adelomorphous cells, 254
Adenoids, 184
Adipose tissue, 92
Adrenal gland, 418
blood-vessels of, 420
chromaffin granules of, 418, 420
development of, 421
lipoid granules of, 418
nerves of, 420
phæochrome granules, 418
phæchromoblasts, 421
secretion of, 420
spongioblasts, 419
sympathoblasts, 421
Adrenalin, 420
Adventitia of arteries, 160
of lymph vessels, 169
of veins, 162
Afferent cerebellar neurones, 511, 541, 548, 558, 561, 566, 575, 579
Afferent, central continuations of, 522
paths, 504, 506, 507
pallial, 488, 507, 520
physiology of, 507
peripheral nerves, 423, 435
neurones and receptors, 427, 428, 437, 498, 499, 504
segmental neurones, 504
roots, their terminal nuclei and secondary tracts, 522, 527, 531, 538, 546, 557, 561, 562, 575, 579, 583, 592, 594, 603, 609
suprasegmental neurones, 429, 507, 511, 520
suprasegmental paths, 507
afferent cerebellar, 511
mesencephalic, 511
pallial, 507
olivo-cerebellar, 512
physiology of, 507
special proprioceptive, 512
vestibular, 512
Agminated follicles, 265*b*
Air cells, 316
passages, 316
sacs, 316
vesicles, 316
Ala cinerea, 523, 531, 533
Alcohol, as a fixative, 6
dilute, as a fixative, 7
for hardening, 13
Ranvier's, 4
absolute, as a fixative, 6
Alcohol-ether celloidin, 14
Alimentary canal, primitive, 302
tract, 224
development of, 302
endgut, 268
foregut, 248
headgut, 225
midgut, 260
Altmann's granule theory of protoplasmic structure, 45
Alum-carmine, 22, 25
for staining in bulk, 24

Alveolar ducts, 316
glands, 219, 222
passages, 317
sacs, 316
Alveoli, of glands, 222
of lung, 318
Amacrine cells, 637, 665
Amitosis, 54a
Amœboid movement, 53, 111
technic for, 64
Amphiaster, 54*b*
Amphicytes, 438
Amphipyrenin, 49
Ampulla, 653
Amygdaliform nucleus, 601
Anabolism, 51
Anaphase, 56
Aniline dyes, acid, 23
basic, 22
Anistropic line, 119
substance, 119
Annular terminations, 447
Annuli fibrosi, 166
Ansa lenticularis, 601, 609
Anterior corpus quadrigeminum, 581, 585
cerebral commissure, 601, 605, 609
horns, 464, 472, 475, 479
root or motor cells of, 470
perforated space, 538, 542
pyramids, 493, 523, 532, 542
white commissure, 542
Anus, 272
Aorta, 160
Apathy, concerning cilia, 79
Apical body, 350
foramina, 233
Aponeuroses, 95
Apparato reticulare, 47
Apparatus of Golgi-Rezzonics, 140*c*
Appendix epididymidis, 348
testis, 348
vermiformis, 270
Aqueductus Sylvii, 425, 575
Arachnoid membrane, 434
Arbor vitæ, 513
Arborescent terminations, 447
Arborizations, terminal, 136, 447
Arc cerebellar, 499
cerebral, 501
pallial, 501
spinal reflex, 498
three-neurone, 499
Arc, two-neurone reflex, 498
Archipallium, 601
Archoplasm, 51
Arciform nucleus, 540
Arcuate fasciculus, 608, 609
fibres, 532, 541
external, 532, 540, 548
internal, 532, 540, 557, 585
Area, acustica, 523, 533
tegmenti, 595
Areolar (loose) connective tissue, 91
Arrector pili muscle, 397
Arteriæ arciformes, 332
rectæ, 334
Arteries, 157
adventitia of, 160
anterior spinal, 477
aorta and other large, 160
arcuate, 332
arteriole, 158
bronchial, 319, 321
central, 188
ciliary, 644
coats of, 157
coronary, 166
development of, 167
greater arterial circle of iris, 645
hepatic, 294
interlobar, 332
interlobular, 332
intima of, 158
large, like the aorta, 160
lesser arterial cricle of the iris, 645
lymph channels of, 163
media of, 159
medium-sized, 158
nerves of, 163
posterior spinal, 477
precapillary, 158
pulmonary, 319
pulp, 188
rectæ, 334
renal, 324, 331
sheathed, 188
small, 157
splenic, 187
structural peculiarities of some, 161
sulco-commissural, 477
technic of, 164
vasa vasorum, 163
Arteriole, 158
Articular cartilages, 209

Articulations, 209; see *Joints*
diarthrosis, 210
synarthrosis, 209
synchondrosis, 209
syndesmosis, 209
technic of, 211
Arytenoid cartilages, 307
Ascending degeneration, 479
fibre tracts of spinal cord, 485
direct cerebellar, 490
Gowers', 492
long arms of dorsal root fibres, 485
posterior columns, 485
funiculi, 485
Ascending fibre, spino-tectal, 488, 489, 494, 497, 579
-thalamic, 488, 540, 561, 566, 577, 587, 595
tract of Flechsig, 490, 511, 515
tracts forming parts of afferent paths, 483
to cerebellum, 490
tractus spino-cerebellaris dorsalis 469
ventralis, 490
uncrossed cerebellar, 490
Asters, 58
Astral rays, 54*b*
Atresia of follicle, 369
Atrophy method of determining fibre tracts of the cord, 622
Attraction sphere, 51, 54*b*
Auditory canal, 651
cells, 650
hairs, 654
nerve, 505, 522, 544
cochlear branch of, 505, 542
vestibular branch of, 540, 544, 594
path, 503, 544
pit, 589
Auerbach, end buttons of, 569
end foot of, 39
plexus of, 262, 268, 276, 452
Auricle, 165, 573
muscle of, 165
Auriculo-ventricular ring, 165
Autogenetic theory of neurones, 146
Autonomic nervous system, 424, 448
Axis cylinder, 130, 138; see also *Axone*
Axolemma, 139
and neurilemma, relation of, 140
Axonal degeneration, 146, 479
method of determining fibre tracts by means of, 479
Axone, the, 130, 135, 426
Bethe's views of, 141
Cajal's views of, 141
collaterals of, 136
degenerative changes in, 142
development of, 426
fibres of Remak, 138
medullary sheath of, 137
medullated, 138
naked axone, 136
neurolemma, 136
non-medullated, 136
sheath of Schwann, 136
terminal arborizations of, 136
Axone-hill, 135
Axone-reflex, 453

Baillarger, line of, 615
Balsam, Canada, for mounting, 26
Barker, concerning the neurone, 131, 134
Bartholin, duct of, 283
glands of, 69, 382
Basal filament, 218
granule, 79
Basement membrane, 223
Basic aniline dyes, 22
Basis pedunculi, 581
Basket cells, 227, 516
Basophile granules, 110
leucocytes, 110
Bellini, duct of, 327, 330
Benda's method of staining mitochondria, 32
Bensley and Theobara, concerning secretion, 277
Bergman, nerve fibres of, 574
Berkley, concerning pituitary body, 414
Bertini, columns of, 326
Betz, cells of, 612
Bielschowsky's nerve stain, 40
Bielschowsky's stain, Maresh's modification of, for connective tissue, 31
Bikfalir concerning development of lungs, 322
Bile duct, 295
Bioblasts, 45
Bipolar nerve cells, 131, 434
Bladder, urinary, 336
Blastoderm, 63, 69

Blastomeres, 62
Blocking, 15
Blood, 107
  corpuscles, 107, 113
  crenation of red cells, 108
  development of, 113
  diapedesis, 111
  dust, 112
  erythrocytes of, 107
  granules, elementary, 113
  granules of Ehrlich, 111
  hæmatin, 108
  hæmatokonia, 112
  hæmoglobin of, 108
  hæmolysis, 108
  Jenner's stain for, 32
  leucocytes of, 109
  macrocytes, 107
  microcytes, 107
  phagocytosis, 111
  plasma of, 107
  platelets, 112, 114
  reaction of, 107
  red cells of, 107
    crenation of, 108
    technic for, 63
  smears, technic of, 32, 114
  specific gravity of, 107
  stroma of, 108
  technic of, 114
  thrombocytes, 112
  vascular unit, 320
  white cells of, 109
Blood-islands, 113, 167
Blood-sinuses of hæmolymph nodes, 177
Blood-smear, 6, 32, 114
Blood-vascular unit, 320
Blood-vessel system, 155
  arteries, 157
  bronchial, 319
  capillaries, 155
  development of, 167
  heart, 165
  lymph channels of, 163
  nerves of, 163
  pulmonary, 319
  technic of, 164, 167
  vasa vasorum, 163
  veins, 162
Blood-vessels, 155
  lymph channels of, 163
  nerves of, 163
Blood-vessels, technic of, 164
Body cavities, 169
  pericardial, 169
  peritoneal, 169
  pleural, 169
  serous membranes of, 169
Bone, breakers, 204
  cells, 105, 195, 205, 238
  cementum, 238
  decalcification of, 9, 105
  development of, 202
  formers, 204
  tissue, 104
    calcination of, 105
    cells of, 105
    corpuscles of, 105
    decalcification of, 9, 105, 202
    intercellular substance of, 105
    lacunæ and canaliculi of, 105, 204
    lamellæ of, 105
    technic of, 106, 202
Bone-marrow, 197
  blood-vessels of, 201
  cells of, 197
  development of, 206, 208
  endosteum, 197, 201
  erythroblasts of, 198
  fat cells of, 199
  gelatinous, 201
  giant cells, 198
  leucocytes, 197
  marrow cells, 197
    spaces, 197, 206
  mast cells of, 199
  megakaryocytes, 198
  myelocytes of, 197
  myeloplaxes of, 198
  non-nucleated red blood cells of, 107, 197
  normoblasts, 198
  nucleated red blood cells of, 198
  osteoclasts, 198
  plasma cells of, 199
  polykaryocytes of, 198
  primary marrow spaces, 206
  red, 199
  technic of, 202
  yellow, 201
Bones, 193
  blood-vessels of, 201
  canaliculi of, 196, 202
  cancellous or spongy, 193, 204

Bones, cells of, 195
origin of, 204
circumferential lamellæ of, 195
development of, 202
intracartilaginous, 205
intramembranous, 203
subperichondrial development of, 207
subperiosteal, 207
growth of, 208
hard or compact, 193
Haversian canals of, 194
lamellæ, 195
spaces, 207
systems, 196
Howship's lacunæ, 204
intermediate lamellæ, 196
interstitial lamellæ, 196
lacunæ, 195, 202, 204
lymphatics of, 202
marrow, 197
red, 199
yellow, 201
nerves of, 202
nutrient canal, 201
foramen, 201
vessels, 201
osteoblasts, 203
osteoclasts, 204
osteogenetic layer, 196
tissue, 203
perforating fibres, 197
perichondrium, 205
pericranium, 204
periosteal buds, 205
periosteum of, 196, 204
Sharpey's fibres, 197
spongy, 194, 207
technic of, 202, 208
developing bone, 208
Volkmann's canals, 196, 201, 202
Bony cochlea, 655
spiral lamina, 656
Borax-carmine, alcoholic solution, 24
Born's theory of corpus luteum, 368
Bowman, capsule of, 326, 328
glands of, 306
membrane of, 623
sarcous elements of, 120
Brachia conjunctiva, 559, 567, 577, 579
Brachium of posterior corpus quadrigeminum, 577
pontis, 558
Brain, the, 503
cerebral cortex of, 609
contrasted with spinal cord, 503
corpus striatum, 601
development of, 424
effectors, 503
endbrain (*telencephalon*), 425, 600
corpus striatum, 601
pallium, 519, 605
rhinencephalon, 601
forebrain (*prosencephalon*), 425, 586
diencephalon (*thalamencephalon*), 425, 586
epithalamus, 586
hypothalamus, 586
thalamus, 425, 586, 594, 597
general consideration of paths of, 517
general histology of, 522
structure of, 503
hemispheres of, 425, 519
higher coördinating apparatus of, 503
hindbrain (*rhombencephalon*), 425, 522
cerebellum, 519, 523, 559, 566
isthmus, 574
medulla oblongata (bulb), 523
nerves of, 524
pons, 425, 525
tegmentum, 552
interbrain, 586
membranes of, 432
arachnoid, 434
blood-vessels of, 434
cerebral dura, 432
dura mater, 432
pia mater, 433
cerebralis, 434
Pacchionian bodies of, 434
relation of optic nerve to, 639
technic of, 434
midbrain (*mesencephalon*), 425, 577
aqueductus Sylvii, 577
basis pedunculi, 577
corpora quadrigemina, 519, 577, 579, 581, 585
iter, 575, 577, 582
pes pedunculi, 577, 579, 584
posterior commissure, 580, 594
substantia nigra, 577
superior colliculus, 581, 583, 585, 594
tegmentum, 552

Brain, pallium, 425, 519, 605
physiology of suprasegmental paths, 507
receptors, 503
relation of, to optic nerve, 594
sand, 415*d*
segmental brain and nerves, 429, 504
afferent peripheral neurones, 504
efferent peripheral neurones, 506
posterior or medial longitudinal fasciculus, 495
semicircular canals, 503
striated voluntary muscle of, 503
suprasegmental structures, 429, 504, 519
afferent and efferent, general consideration of, 517
technic of, 526, 549, 623
ventricles, 425
vesicles, 425
Branca, concerning the centrosome, 59
Bridges, intercellular, 70, 72, 76
Bronchi, 310
alveolar, 315
blood-vessels of, 319
cartilages of, 312
cells of, 310
development of, 322
lobular, 315
lymphatics, 321
nerves of, 321
primary, 310
respiratory epithelium, 317
structure of walls of, 310
technic of, 323
terminal, 316
Bruch, membrane of, 630
Brunner's glands, 258, 267, 278
Brush cells, 665
Bulb, 523; see *Medulla*
Bulbo-urethral gland, 355
Bulbus oculi, 627; see *Eyeball*
Bulk stains, 24
Bundle of Löwenthal, 495
of Vicq d'Azyr, 511
Burdach, column of, 479, 487, 523, 527, 531
nucleus of, 487, 523, 527, 531
Bursæ, 213
Busch-Marchi staining method, 36
Bütschli's theory of protoplasm structure, 45
Cachexia strumipriva, 409
Cœlom, 169
Cajal, cells of, 612
concerning the neurone, 135, 139, 141
interstitial nucleus of, 494, 529, 532, 541, 548, 558
methods for staining neurofibrils in nerve cells, 38
plexiform layer of, 612
Cajeput oil for clearing sections, 26
Calcarine area, 611
Calcification, 85
center, 203, 205
zone, 207
Calcination, 105
Calyces of kidney-pelvis, 335
Canada balsam, 26
Canal, gastro-intestinal, 250
gustatory, 666
Haversian, 194, 202
lacrymal, 646
of Cloquet, 644
of Petit, 644
of Schlemm, 633
portal, 295
Volkmann's, 196, 202
Canaliculi of bone, 105, 196, 202
of connective tissue, 87
of Golgi, 140b
Canalis communis, 654
Canalized fibrin, 379
Cancellous bone, 193, 204
Capillaries, blood, 155
chyle, 265, 275
development of, 167
lymph, 169, 275
relation of, to liver cells, 300
technic of, 164
Capillary endothelium, 155
network, 156
Capsule of Bowman, 326, 328
cells, 437
externa, 605
extrema, 605
of ganglion cells, 437
of Glisson, 293
of Tenon, 645
Carbol-xylol for clearing specimens, 26
Carboxyhæmoglobin, 111
Cardiac glands, 257
Carmine, alum, 22, 25
borax, 25

Carmine, gelatin, 11
neutral, 23
picro-, 24
Carotid gland, 416
Cartilage, 101, 202
arytenoid, 307
articular, 210
cells, 102
chondrogenetic layer, 102
chondrin, 101
classification of, 101
cricoid, 307
development of, 104
elastic, 103, 307
embryonal, 102
epiphyseal, 208
fibrous, 103, 209
hyaline, 101, 205, 307
intercellular matrix of, 103
intermediate, 208
laryngeal, 307
of developing bone, 202
perichondrium of, 102, 103
Santorini's, 307
technic of, 104
thyreoid, 307
tracheal, 308
of Wrisburg's, 307
Cartilages, articular, 209
costal, 209
laryngeal, 307
interarticular, 210
skeletal, 209
tracheal, 308
Caryochromes, 4, 13, 570
Caudate nucleus, 594, 597, 601, 602, 605, 609
Cavernous sinuses, 356
Cavity of embryonic vesicle, 62
Cedarwood oil as solvent, 16
Cell, the, 43
amitosis, 54
amphipyremin, 48
body of, 44, 130
centrosome of, 44, 50
ciliary movement of, 54*a*
crusta of, 47
cuticula of, 48
cytoplasm of, 44, 46
cytoreticulum of, 46
deutoplasm granules of, 46
division, direct, 54*a*
Cell, division, indirect, 54*b*
dynamic centre of, 58
endoplasm of, 46
exoplasm of, 46
function of, 52
hyaloplasm of, 44
intranuclear network of, 49
irritability of, 53
karyoplasm of, 46, 50
linin of, 49
lutein, 364*a*
membrane of, 47b
metabolism of, 51
metaplasm granules of, 46
microsomes, 44
mitochondria, 47
mitosis, 54*b*
motion of, 53
nuclear membrane of, 49
nuclein of, 49
nucleolus of, 50
nucleoreticulum, 49
nucleus, 48
origin of word, 47b
paraplasm granules of, 46
pellicula, 48
plastids, 46
plastin, 44
primitive, 54*a*
protoplasm of, 44
Altmann's granule theory of, 45
Bütschli's foam ore mulsion theory of, 45
Flemming's filar theory of, 45
Frommann's reticular theory of, 45
protoplasmic movement of, 54
reproduction of, 54*a*
spongioplasm of, 44
technic for study of, 63
trophospongium, 47
typical, 44
diagram of, 43
structure of, 43
vital properties of, 51, 58, 218
Cell-islands of Langerhans, 290
function of, Opie's theory of, 291
origin of, 291
structure of, 291
technic of, 292
Cell-patches, 290
space (lacuna), 105
Celloidin, alcohol-ether, 14

Celloidin, clove-oil, 15
embedding, 14
sections, 17
clearing of, 26
mounting of, 26
Cells, acid, 250, 254, 277
acidophiles, 415*a*
active, 217
adelomorphous, 254
air, 316
amacrine, 637, 665
amœboid, 148
auditory, 660
basal, 306
basket, 22,, 516
basophiles, 415*a*
blood, 107
bone, 105, 195, 204, 238
brush, 665
capsule, 427
cartilage, 101, 205
cementoblasts, 240
central, 254
centro-acini, of Langerhans, 289
centro-tubular, 289
chief, 250, 254, 278, 411, 413
chromaffin, 265, 416
chromophobes, 414
ciliated, 79, 311
clasmatocytes, 87, 89
clasmocytes, 89
clear, 411
colloid, 409, 411
columnar, 75, 261
compound tactile, 444
connective-tissue, 87, 264
crescents of Gianuzzi, 227
cuboidal, 75
daughter, 58
decidual, 376*a*
Deiter's, 660
delomorphous, 254
demilunes of Heidenhain, 227
empty, 217
endothelial, 155
eosinophile, 110, 178
ependymal, 148, 426, 467
epithelial, 73
erythroblasts, 198
erythrocytes, 107
extrinsic, 458
fat, 92, 178, 199
Cells, fibroblasts, 85, 99
fixed connective tissue, 87, 240
fœtal, 318, 322
fusiform, 233
ganglia, 424, 432, 449, 437, 458
giant, 198
gland, 217
glandular (spermatogenic), 341
goblet, 78, 82, 217, 262, 277, 307
Golgi Type I., 134, 136
Type II., 135, 136, 572, 612
granule, 570
gustatory, 666
hair, 654, 660
hecatomeric, 461
Hensen's, 660
heteromeric, 460
inter-neuroglia, 415*d*
interstitial of seminiferous tubule, 344
intrinsic of cord, 458
inverted pyramidal, 612
Kupffer's, 299
Langerhans', 289
leucocytes, 109, 110, 197
Leydig's, 514
liver, 297
loaded, 217
lutein, 365
lymphoid, 171, 187, 225, 265, 307
lymphocytes, 175
macrocytes, 107
marrow, 197
mast, 87, 178, 199
megakaryocyte, 198
megalocyte, 188
microcyte, 107
migratory leucocytes, 264
mitral, 665
mononuclear, 188
mossy, 147
mucous, 217, 226, 262, 277, 310
multinuclear, 178, 188
muscle, 115, 121, 373
myelocytes, 197
myeloplaxes, 198
myoblasts, 126
nerve, 130; for classification see *Nerve cells*
neurolemma, 148, 427, 468
neuroblasts, 130, 146, 424
neuro-epithelial, 80
neuroglia, 147, 415*d*, 426

Cells, normoblasts, 198
nucleated red blood, 113, 198
odontoblasts, 233, 246
of Claudius, 660
of oral glands, 227
olfactory, 306
osteoblasts, 203, 240
osteoclasts, 198, 204, 240
ovum, 54a, 360, 361
oxyntic, 254
oxyphile, 411
Paneth's, 265, 278
parenchyma, 415*d*
parietal, 254
peptic, 254, 277
phæochromoblasts, 418, 421
phagocytes, 53, 111, 179
pigmented, 46, 75, 80, 135, 390, 394, 560
pillar, 641
plasma, 87, 89, 199
polykaryocytes, 198
prickle, 389, 393
primitive ova, 360, 384
Purkinje, 568
pyramidal, 609, 612
red blood, 107, 188
replacing, 75, 257, 264
reserve, 409
respiratory, 318
resting, 217, 409
satellite, 433
secreting, 218, 264, 289, 409
serous, 226
Sertoli's, 341, 384
sex, 384
signet-ring, 92
simple tactile, 443
single primitive, 53
smooth muscle, 115, 264
spermatids, 343, 350
spermatoblasts, 351
spermatocytes, 343, 350
spermatogenic, 342
spermatogonia, 342, 350, 384
spider, 147
spinal ganglion, 437, 439, 458
spleen, 188
spongioblasts, 419, 426
squamous, 76
stellate, 233, 611
supporting, 341
Cells, sustentacular, 290, 306, 341
sympathoblasts, 421
tactile, 443
tautomeric, 460
tendon, 96
thrombocytes, 112
wandering, 53, 87, 90, 111, 264
white blood, 109, 188
Cementing glycerin mounts, 25
Cementoblasts, 240
Cementum, 238
development of, 247
Centers of calcification, 203
Central canal, 423, 523
cells, 254
chromatolysis, 146
gelatinous substance, 533
gray, 527, 533, 575, 585
nervous system, 422, 457
neurones, 426
spindle, 54*b*
tegmental tract, 541, 557, 558, 566, 575, 579, 594
Central continuations of afferent neurones, 522
Central vein, 294
Centriole, 50, 54*b*
Centro-acinar cells of Langerhans, 289
Centrogenetic theory, 146
Centrosome, 44, 50, 54, 60
achromatic spindle, 54*b*
archoplasm, 51
attraction sphere, 51, 54*b*
centriole, 50, 54*b*
centrosphere, 54*b*
daughter, 54*a*
of fertilization, 63
Centro-tubular cells of Langerhans, 289
Cerebellar arc, 499
connections, 499, 511, 516, 517
cortex, 559
peduncles, 558, see *Peduncle, cerebellar*
Cerebello-olivary fibres, 541
Cerebello-pallial path, 511
reticular, 517
rubro-spinal, 516
vestibulo-ocular, 517
vestibulo-spinal, 517
Cerebellum, 425, 519, 523, 559, 566
arbor vitæ, 567
ascending paths to the, 511

Cerebellum, association cells of, 574
basket cells of, 570
brachium-conjunctivorum, 559
climbing fibres of, 573
corpus dentatum, 559
cortex of, 520, 559, 568
dentate nucleus of, 559
descending tracts from, 516
development of, 520
fastigio-bulbar tract of, 559
fibres of, 567
climbing, 573
mossy, 573
of Bergmann, 574
parallel, 572
general histology, 568
glomeruli of (islands), 570
Golgi cells, 572
granular layer, 568
granule cells, 570
gray matter of, 567
hemispheres of, 566
internal nuclei of, 559, 567
laminæ, 567
molecular layer, 568
neuroglia of, 147, 522, 574
nuclear layer, 568
nuclei of, 559, 567
nucleus dentatus, 559
emboliformis, 559
globosus, 559
tecti or fastigii, 513, 559
paths connecting with mid-brain roof, pallium and body, 507
peduncles of, 559, 567, 577
Purkinje cells of, 568
short axone cells, 572
stellate cells, 570
technic of, 623
van Gehuchten cells, 573
vermis, 567.
white matter of, 567
Cerebral arc, 500
areas, 615
cortex, 605, 609, see also *Cortex cerebri*
dura, 432
hemispheres, 425, 519, 609
development of, 425
localization, 620
membranes, 432
peduncles, 581
Cerebral vesicle, 425
Cerebro-spinal ganglia; 130, 427, 437, see *Spinal ganglia*
nervous system, 422, 424; see also *Nervous system*
neurones, efferent peripheral, 456
Ceruminous glands, 651
Cervical enlargement of cord, 457, 479
segments of cord, 458
Cervix, 372
epithelium of, 374
external os, 374
glands of, 374
ovula Nabothi, 374
plicæ palmatæ, 374
technic of, 385
Chain ganglia, 451
Cheeks, mucous membrane of, 225
Chemotaxis, 53
Chiasma, optic, 594, 640
Chief cells, 250, 254, 278
Chloride of gold for staining connective-tissue cells, 28
Chloroform as solvent, 16
Choledochus ductus, 303
Chondogenetic layer, 102
Chondrin, 101
Chondriosomes, 135
Choriocapillaris, 630
Chorioid, the, 629
Bruch, membrane of, 630
choriocapillaris of, 630
ciliary body, 631
process, 631
fissure, 649
Haller's layer of, 630
lamina citrea, 630
suprachorioidea, 630
perichoriodal lymph spaces of, 630
plexus, 425, 523, 533
tapetum cellulosum of, 630
fibrosum of, 630
venæ vorticosæ, 630
vessels, straight of, 630
vitreous membrane of, 631
Chorion, 377
Chorionic villi, 377
Chromaffin cells, 265, 416
granules, 418
organs, 416
Rose, concerning chromaffin cells, 416

Chromatic element of intranuclear network, 49, 132
Chromatin, 49, 132
Chromatolysis, 146
Chrome-silver method of Golgi, 29
Chromophile cells, 414
Chromophilic bodies, 133
  significance of, 142
  Nissl technic for, 39, 133, 149
Chromophobes, 414
Chromosomes, 56
  accessory, 56
  daughter, 56
  diploid (or somatic) number, 350*a*
  haploid number, 350*a*
  probable number for species, 56
Chyle, 175
  vessels, 265, 275
Cilia, 54*a*, 73, 78
Ciliary artery, 644
  body, 631
    blood-vessels of, 644
    canal of Schlemm, 633
    ligamentum pectinatum, 633
    muscles of, 632
    pars ciliaris retinæ, 632
    processes of, 631
    spaces of Fontana, 633
    vitreous membrane of, 632
  ganglion, 451
  movement, 54*a*
    technic for, 64
  muscle, 632
  plexus, 645
  processes, 631
Cingulum, 607
Circulatory system, 155
  blood-vessel system, 155
  development of, 167
  lymph-vessel system, 169
Circumferential lamellæ, 196
Circumvallate papillæ, 230
Cirl, concerning fibres of internal capsule, 594
Clarke's columns, 479, 499
Clasmatocytes, 87, 89
Clasmocytes, 89
Claude, concerning development of pancreas, 303
Claudius, cells of, 660
Claustrum, 605
Clava, the, 523
Clearing specimens before mounting, 26
Clefts of Schmidt-Lantermann, 139
Climbing fibres, 573
Clitoris, 382
Cloquet's canal, 644
Closed skein (spireme), 55
Clove-oil celloidin, 15
Coagulum sheath, 141
Coccygeal glands, 417
  segments of spinal cord, 458
Cochlea, 655
  bony spiral lamina of, 656
  cupola of, 655
  cupula of, 655
  hamulus of, 656
  helicotrema, 657
  membranous spiral ligament of, 656
  modiolus of, 655
  scala tympani, 657
    vestibuli, 657
  spiral ligament of, 656
Cochlear duct, 657
    basilar membrane of, 658
    crista basilaris, 658
    external spiral sulcus, 658
    membrane of Reissner, 658
    nuclei, 497
    organ of Corti, 659
    spiral prominence of, 658
    stria vascularis, 658
    zona pectinata, 659
      tecta, 659
  nerve, 542, 544
  tracts see *tract, cochlear*
Cœlom, 169
Cohnheim's field, 120, 123*b*
Collageu, 90
Collagenous fibres, 85, 90
Collaterals, 136, 463
Colliculi, 425, 506, 519
  inferior, 577, 579, 580
  superior, 581, 583, 585, 594
Colliculo-bulbar path, 516
Colliculo-medial longitudinal fasciculus, 516
Colliculo-spinal tract, 494, 529, 531, 532, 559, 562
Colloid, 408, 411, 415*a*
Colostrum corpuscles, 405
Column cells, 460, 472
    hecateromeric, 461
    heteromeric (heterolateral), 460

Column cells, tautomeric (ipsilateral or homolateral), 460
technic of, 461
of Burdach, 479, 487, 523, 527
of Goll, 479, 487, 523, 527
Columnæ rectales, 272
Columns of Bertini, 326
of Sertoli, 341, 384
Comma tract of Schultze, 496
Commercial formalin, 5
Commissura habenularis, 597
Commissuralis, nucleus, 532, 539
Commissure, dorsal gray, 466, 585, 594
dorsal white, 466
ventral gray, 466
ventral white, 466
Common dental germ, 243
senses, 507
Compact bone, 193
Compound tactile cells, 444
Conduction path, 429, 483
afferent and efferent, 483
afferent-cerebellar: see *Tracts*
mesencephalic, 511
pallial, 507
auditory, 544, 594
connecting body pallium, mid-brain roof and cerebellum, 507
efferent cerebellar; see *Tracts*
mesencephalic, 516
pallial, 512
for general body sensibilities, 507
special senses, 507
motor, 483
pallio-bulbo-spino-sympathetic, 497
pallio-cerebellar, 492, 514
pallio-spinal efferent, 592
relays in, 483
to cerebellum, 492, 507
sensory, 483
significance of relays in, 483
trigeminal afferent pallial, 564
Cone association neurones, 640
bipolar, 636
fibres, 636
neurones, 639
-visual cell, 636
Cones, layer of rods and, 635
Conjunctiva, 647
end bulbs of, 445, 575
Connective tissue, 84, 86
adipose or fat, 92
Connective tissue, aponeurotic, 95
areolar, 91
bone, 104
cartilage, 101
cells of, 87, 264
cellular, 91
characteristics of, 84
chlorid-of-gold method for demonstrating cells of, 28
clasmatocytes, 89
classification of, 86
dense fibrous, 91, 94
development of, 85
elastic, 95
elastin of, 91, 98
embryonal, 85, 86, 202, 208
fat, 92
fibres of, 85, 90
collagenous, 85
elastic, 90
fibrillated, 90
reticular, 91, 97
white, 90
yellow, 85, 90
fibrillar, 86
fibroblasts, 85
fixed cells of, 87
formed, 94
gelatin of, 90
histogenesis of, 84
intrafascicular, 436
intralobular, 94, 220
interalveolar, 319
intercellular substance of, 87, 90
interlobar, 220
interlobular, 93, 220
intrafascicular, 213, 431
ligaments, 94
loose, 91
Mallory's stains for, 29, 30
mast cells of, 89
mucous, 86
nerve endings in, 447
neuroglia, 146, 424, 459, 520
pigmented cells of, 89
plasma cells of, 89
reticular, 97
retinaculæ cutis, 388
staining of, 28
technic for, 98, 104, 106
tendons, 94
theories of development of fibres of, 85

Connective tissue, wandering cells of, 90
white fibrous, 86
Constrictions of Ranvier, 139
Contact theory of neurones, 141
Continuity theory of neurones, 142
Contour lines of Owen, 237
Convoluted tubules of kidney, 326, 328, 329
of testis, 340
Cord, spinal, 457; see *Spinal Cord*
Corium, 386
Cornea, the, 627
anterior elastic membrane of, 628
epithelium of, 628
corpuscles of, 629
endothelium of Descemet of, 629
membrane of Bowman of, 628
of Descemet of, 629
posterior elastic membrane of, 629
substantia propria of, 629
Corneal corpuscles, 629
Cornu ammonis, 601
Cornua of cord (posterior horns), 464
Corona radiata of ovum, 362
of pallium, 595, 609
Coronary arteries, 166
Corpora amylacea, 354
cavernosa, 355
lutea of pregnancy, 366
spuria, 366
vera, 366
mammillaria, 597
quadrigemina, 425, 519, 577, 579
anterior, 577, 581, 585
development of, 425
posterior, 577, 579, 580
striata, 425
Corpus albicans, 366
callosum, 607, 609
dentatum, 559
hæmorrhagicum, 364*a*
Highmori, or mediastinum testis, 339
luteum, 364*a*
theory of, 368
quadrigeminum, anterior, 577, 581, 585
posterior, 577, 579, 580
restiforme, 523, 540, 541
spongiosum, 355
striatum, 601, 605, 609
connections of, 602
Corpus striatum, caudate nucleus, 602
globus pallidus, 601
lenticular nucleus, 600, 602
physiology of, 602
putamen, 601, 605
subthalamicum, 586
trapezoideum, 561
Corpuscles, blood, 107
bone, 105
colostrum, 405
corneal, 629
crescentic, of prostate, 354
genital, 356
Golgi-Mazzoni, 400, 448
Grandry's, 443
Hassall's, 181
Meissner's, 357, 400, 444
Merkel's, 443
Pacinian, 202, 356, 400, 445, 453
renal, 326
Ruffini's, 400, 448
salivary, 184
splenic, 186
tactile, 400, 444
Vater-Pacinian, 356, 400
Wagner, 400
Cortex cerebelli, 568; see also *Cerebellum*
cerebri or pallium, 605, 609
afferent connections, 605
areas of, 616
methods of determining, 617, 621
association fibres of, 605, 607
cells of, 609, 617
of Betz, 612
of Cajal, 612
of Golgi, Type II, 135, 136, 572, 612
horizontal, 612
inverted pyramidal, 612
of Martinotti, 612, 614
polymorphus, 612
pyramidal, 609
stellate, 611
commissural fibres, 605
corona radiata of, 539, 542, 595 605, 609
corpus callosum, 605, 607
efferent connections, 605
external granular layer, 612
fibre layers of, 615
dysfibrous, 615
infrastriate, 615

Cortex cerebri, fibre layers of Baillarger, 615
suprastriate, 615
tangential, 615
Vogt's classification, 615
formix commissure, 605
ganglionic layer, 612
horizontal cells of Cajal, 612
internal capsule, 606
internal granular layer, 612
inverted pyramidal cells of Martinotti, 612
layer of polymorphous cells, 612
of pyramidal cells of, 612
line of Baillarger, 615
of Gennari, 549
molecular layer, 612
multiform layer, 612
peduncular fibres, 605
plexiform layer of Cajal, 612
polymorphous cells of, 612
projection fibres, 605, 617
radiations of Meynert, 603
stellate cells of, 611
supraradiary plexus of, 615
Cortical labyrinths, 326
pyramids, 326
Corti's arches, 660
organ, 505; see also *Organ of Corti*
tunnel, 659, 662
Costal cartilages, 209
Cotyledons, 377
Cowdrey, concerning mitochondria, 47
Cowper's glands, 69, 335
technic of, 355
Cox-Golgi method of staining nerve tissue, 37
Cranial nerves; see *Nerves, cranial*
Crenation of red blood cells, 108
Crescentic corpuscles, of prostate, 354
Crescents of Gianuzzi, 227, 283, 308
Cretinism, 409
Cricoid cartilage, 307
Crista acustica, 655
basilaris, 658
Cross-fibre-nets, 121
Crossed pyramidal tracts, 490, 492, 531
Crura cerebri, 581
Crusta (exoplasm), 47
Crypt of Lieberkühn, 265
of tonsils, 183
Crystalloids, 341
Cumulus ovigerus, 362
Cuneus, 523
Cupola, 655
Cupula, 655
Cutaneous sensation, 488, 489, 507
Cuticle, 388
Cuticula, 48 73
dentis, 238
Cuticular membrane, 73, 245, 262
Cutis plate, 127
Cystic duct, 300, 303
Cytoarchitecture, 615, 616
Cytoplasm, 46, 47b
of nerve cells, 132
Cytoreticulum, 46
Cytosomes, 218

DARKSCHEWITSCH, nucleus of, 494
Daughter cells, 58
centrioles, 54b
centrosomes, 54*a*
chromosomes, 56
nuclei, 60
stars, 57
Davidoff, concerning cells of stomach 264
Decalcification, 3, 9, 105
Decalcifying, fluids, 10
Decidua basalis, 376*a*
capsularis, 376*a*
graviditatis, 376*a*
menstrualis, 376
reflexa, 376*a*
serotina, 376*a*
subchorionic-placental, 380
vera, 376*a*
Decidual cells, 376*a*
Decolorizing fluid for Weigert's hæmatoxylin, 34
Decussatio brachii conjunctiva, 577, 579
Decussation of fillet, 531
motor, 527, 531
of Forel, 585
of Meynert, 585
of pyramids, 492, 493, 527, 531
of superior peduncle, 577, 579
optic, 640
sensory, 531
Deep sensation, 448
Degenerating nerves, Marchi's method for staining, 35, 143

Degeneration of neurones, 142
Wallerian law of, 143
Dehiscent glands, 223
Deiter's cells, 587
nucleus, 495, 505, 525, 544, 557, 558, 501
descending tract from, 495, 541, 544
Deitero-spinal tract, 495, 541
Delafield's hæmatoxylin, 21
Delomorphous cells, 254
Demilunes of Heidenhain, 227
Dendrites, the, 135, 418
Dense fibrous connective tissue, 95
Dental germ, 243
groove, 243
papilla, 243
periosteum, 239
pulp, 233
layer of Weil of, 233
odontoblasts, 233, 246
ridge, 243
sac, 244
sheath, Neumann's, 237
shelf, 243
Dentate nucleus, 559
Dentinal canals, 235
contour lines of Owen, 237
development of, 246
fibres, 233, 235
interglobular spaces of, 237
lines of Schreger, 237
nerves of, 241
Neumann's dental sheath, 237
Tomes' granular layer, 237
Dentine, 233
chemical composition of, 235
secondary, 237
Derma, or *corium*, 386
corpuscles of Meissner, 356, 400, 438
muscle cells of, 387
papillæ, compound, 387
nerve, 387
simple, 387
vascular, 387
pars papillaris, 387
reticularis, 386
pigmentation of, 390
subcutaneous tissue of, 387
Descemet, endothelium of, 628
membrane of, 628
Descending degeneration, 142, 479
fibre tracts of the spinal cord, 479; see *Fibre tracts of spinal cord (descending)*
suprasegmental paths, 531
Deutoplasm, 46, 363
Diapedesis, 111
Diaphysis of bone, 208
Diarthrosis, 210
articular cartilages, 210
glenoid ligaments, 210
interarticular cartilages, 210
joint capsule, 210
Diaster, 57, 60
Diencephalon, 425, 528
Digestive system, 224
absorption, 277, 279
alimentary tract of, 224
development of, 243, 302
endgut, 268
foregut, 248
gall-bladder, 301
gastro-intestinal canal, 250
headgut, 225
large intestine, 268
larger glands of, 281
liver, 292
mesentery, 272
midgut, 260
mouth, 225
muscular tissue of, 224
œsophagus, 248
omentum, 272
pancreas, 286
peritoneum, 272
pharynx, 247
rectum, 271
salivary glands, 281
secretion, 277
small intestine, 260
stomach, 252
teeth, 232
tongue, 228
vermiform appendix, 270
Diplosome, 54*b*
Direct cerebellar tract, 490
pyramidal tract, 492, 519
Discriminative associations, 518
Discus proligerus, 362
Dissociation of tissue elements, 4
Disynaptic arc, 499
Dogiel's end plates, 646

Dogiel's theory of structure of spinal ganglion, 440
Dorsal accessory olivary nucleus; see *Accessory olivary nucleus*
decussation of Meynert, 579, 585
gray commissure, 466, 585, 594
horns (posterior or cornu dorsalis) nuclei of, 470, 472
root fibres, 466
spino-cerebellar tract; see *Tract*.
white commissure, 466
Duct glands, 221, 282
systems of glands, 219, 222
Ductless glands, 222
Ducts, aberrans Halleri, 348
alveolar, 316
Bartholini's, 283
Bellini's, 330
bile, 295
choledochus, 303
cochlear, 657
common, 300
cystic, 300, 303
ejaculatory, 348
endolymphatic, 654
excretory, 219, 282, 287, 294
Fallopian tube, 370
Gärtner's, 369
hepatic, 294, 300
kidney-pelvis and ureter, 335
mesonephric, 383
Müllerian, 348, 354
nasal, 646
of Müller (embryonal), 348, 354
of sweat glands, 390
oviduct, 370
pancreatic, 287
papillary, 383
pronephric, 383
reuniens, 654
Santorini's, 287
secondary pancreatic, 287
seminal, 345
Stenoni's, 282
thoracic, 169
thyreo-glossal, 409
utriculo-saccular, 654
vas deferens, 346
vas efferentia, 346
vas epididymis, 346
Wharton's, 284
Wirsung's, 287, 301
Ducts, Wolffian, 383
Ductus aberrans Halleri, 348
reuniens, 654
Dura mater, 432
blood-vessels of, 434
cerebral, 432
epidural space, 432
spinal, 432
subdural space, 433
technic of, 434
Dyad, 350*b*
Dyes, acid aniline, 23
basic aniline, 22
nuclear, 20
plasma, 22
Dynamic centre of cell, 58

EAR, 651; see also *Organ of hearing*
blood-vessels of, 661
development of, 662
drum, 652
external, 651
auditory canal, 651
auricle, 651
blood-vessels of, 652
ceruminous glands of, 651
ear drum, 652
lymphatics of, 652
nerves of, 652
pinna, 651
tympanic membrane, 652
internal, 653
ampulla, 653
blood-vessels of, 661
canalis communis, 654
cochlea, 655
ducts of, 657
ductus reuniens, 654
endolymph of, 653
endolymphatic duct, 661
sac, 661
fenestra ovalis, 653
rotunda, 653
lymphatics of, 661
membrana tectoria, 661
membranous labyrinth, 653
nerves of, 661
organ of Corti, 659
osseous labyrinth of, 653
perilymph of, 661
saccule, 654
scala media, 657

Ear, internal, semicircular canals, 654
utricle, 654
utriculo-saccular duct, 654
vestibule, 653
middle, or tympanum, 652
fenestra rotunda of, 653
ossicles of, 653
stapes, 653
wax, 652
Ebner's glands, 231
hydrochloric salt solution, 10
Ectoderm, 63
derivations from, 69, 130, 146, 243, 401
Ectoplasm, 85
Edinger-Westphal nucleus, 581, 583
Effectors, 423, 426, 456
Efferent-cerebellar paths, 496, 516
Efferent midbrain paths, 496
pallial paths, 483, 496, 497, 513, 514, 515, 518, 526, 599, 601, 603
peripheral somatic cerebro-spinal neurones, 423, 426, 456, 498, 527, 531, 533, 538, 542, 546, 552, 559, 562, 575, 578, 581, 592
root fibres, 426
suprasegmental neurones, 429, 506, 532, 542
paths, 512
efferent cerebellar, 516
mesencephalic, 516
pallial, 512
physiology of, 507
Egg cords, Pflüger's, 360, 384
technic of, 372
nests, 360
Ehrlich, granules of, 111
Eighth VIII (auditory) nerve, 505, 542, 544
Ejaculatory ducts, 348
Elastic cartilage, 103*a*
fibres, 85, 95
tissue, 95
Verhœff's differential stain for, 28
Weigert's stain for, 28
Elastin, 85, 91, 98
Eleidin, 389
Ellipsoid of Krause, 636
Elzholz, bodies of, 140b
Embedding, 14
celloidin, 14
paraffin, 16
Emboliform nucleus, 550
Embryonal tissue, 86
fat tissue, 92
Eminentia abducentis, 523
hypoglossi, 523
medialis, 523
Emulsion theory of protoplasmic structure, 45
Enamel, 238
cells, 242, 244
chemical composition of, 238
cuticula dentis of, 238
membrane of, 245
development of, 243
fibres, 238
organ, 244
prisms, 238, 245
lines of Retzius of, 238
pulp, 245
Tomes' process, 245
Encephalon (brain), 422, 503
Endbrain (*telencephalon*), 425, 600
corpus striatum, 600, 601
olfactory pallium, 601
pallium, 605
neopallium, 601
rhinopallium (archipallium), 601
rhinencephalon, 601
anterior perforated space, 601
olfactory bulb, 601
nerve, 601
pyriform lobe, 601
trigonum olfactorium, 601
tuberculum olfactorium, 601
End-buttons, 569
-bulbs, 445
of Krause, 232, 357, 400, 646
Endgut, 268
large intestine, 268
mesentery, 275
omentum, 273
peritoneum, 272
rectum, 271
vermiform appendix, 270
Endocardium, 165
primitive, 168
Endochondral ossification, 203, 205
Endolymph, 653
Endolymphatic duct, 654
sac, 654
Endomysium, 213
Endoneurium, 138, 436

Endoplasm, 46, 85
Endosteum, 197, 201
Endothelial tube, 168
Endothelium, 72, 80
  of Descemet, 556
  technic for, 83
Engelmann, showing ciliated epithelial cell, 79
Enterokinase, 278
Entoderm, 63
  tissue derivations from, 69, 302, 321
Eosin, 22
  -glycerin, 25
  -hæmatoxylin stain, 23
Eosinophile granules, 110, 178
Ependymal cells, 426
Epiblast, 63
Epicardium, 165
Epicranium, 204
Epidermis (or cuticle), 388
  eleidin, 389
  keratin, 389
  keratohyaline granules, 389
  mitosis of cells of, 389
  pareleidin, 390
  pigmentation of, 390
  prickle cells of, 389
  stratum corneum of, 389
    cylindricum of, 388
    germinativum of, 388
    granulosum of, 389
    lucidum of, 389
    Malpighii of, 388
    mucosum of, 388
    spinosum of, 389
Epididymis, 339, 346
  body of, 340
  cells of, 346
  globus major, 340
  minor, 340
  vas deferens, 340, 346
  vas epididymis of, 340, 346
  vas efferentia of, 346
Epidural space, 432
Epiglottis, 307
Epimysium, 213
Epineurium, 436
Epiphyseal cartilage, 208
Epiphysis cerebri (pineal body), 415c
  brain sand, 415d
  Tilney, concerning the, 415d
Epiphyses of bone, 208
Epithalamus, 425, 586, 597
  habenulæ, 586, 597
  pineal body, 415c; see *Epiphysis cerebri*
  striæ thalami, 586, 597
Epithelium, 72
  basal membrane of, 73
  cells of, 73
    secretory activities of, 217, 277
  ciliated, 78
  classification of, 73
  cuticular membrane of, 73
  derivation of, 69
  endothelium, 80
  follicular, 361
  general characteristics of, 72
  germinal, 360, 384
  glandular, 80, 217
  histogenesis of, 69
  intercellular bridges of, 72
  lens, 643
  membrana propria of, 73
  mesenchymal, 210
  mesothelium, 80
  neuro, 80
  pigmented, 80
  pseudo-stratified, 75
  replacing cells of, 75
  respiratory, 317
  simple, 74
    columnar, 75
    pseudo-stratified, 75
      squamous, 74
  stratified, 75
    columnar, 77
    squamous, 75, 183
    transitional, 77
  surface, of mucous membranes, 223
  syncytium, 379
  tactile cells of, 437
  technic of, 82
  transitional, 77
Eponychium, 393
Epoöphoron, 369
Erectile tissue, 355, 382
Ergastoplasm, 118, 218, 277
Erythroblasts, 198
Erythrocytes, 107
Erythrosin, 23
Eustachian tube, 653
Excretion, 218, 248
Excretory ducts, 219, 282
  substances in cells, 46, 218

Exoplasm, 46, 76, 85
External arcuate fibres, 532, 540, 548
ear, 651; see *Ear, external*
geniculate bodies, 587, 594
os, 374
spiral sulcus, 658
Extero-ceptors, 448
Extracellular network, 142
Eye, the, 627; see *Organ of Vision*
blood-vessels of, 644
development of, 648
eyeball or bulbous oculi, 627
eyelid, 646
lacrymal apparatus, 646
lens, 643
lymphatics, 645
nerves of, 645
neurone systems of, 639
optic nerve, 638
technic of, 649
vitreous body of, 644
Eyeball (or bulbus oculi), 627
blood-vessels of, 644
chorioid of, 629
ciliary body of, 631
cornea of, 627
development of, 648
iris of, 633
lens, 653
lymphatics of, 645
nerves of, 634, 638, 644
retina of, 634
sclera of, 627
technic of, 647
Eyelashes, 647
Eyelid, the, 646
blood-vessels of, 648
conjunctiva of, 647
epidermis of, 646
glands of, 649
of Mall, 647
lymphatics of, 648
Meibomian glands of, 647
muscles of, 647
nerves of, 445, 575
tarsus of, 647
technic of, 648

FACIALIS (nerve VII), 506, 522, 552, 559, 566
Fallopian tube (*oviduct*), 370
development of, 382
Fallopian tube, technic of, 372
False arteriæ rectæ, 334
corpora lutea, 366
Fascicles of muscles, 212
of nerves, 436
Fasciculus, a, 429
arcuatus, 608, 609
cuneatus, 479, 487
gracilis, 479, 487
of Thomas, 496
inferior longitudinal, 609
medial longitudinal, 495, 516, 529, 532, 541, 548, 549, 558, 561, 566, 575, 577, 579, 584, 594
perpendicular of Wernicke, 607
predorsal, 562, 577, 579, 584
retroflexus of Meynert, 579, 597
solitarius, 538, 558
superior longitudinal, 607
uncinate, 607, 609
Fastigio-bulbar tract, 557, 561
Fat, absorption of, 279
technic of, 280
blood supply of, 95
development of, 92, 94
technic of, 101
osmic-acid stain for, 31
subcutaneous, 388
Sudan III and Scharlack R stain for, 31
tissue, 92
histogenesis of, 92*a*
technic of, 100
Fat-droplets in cells, 46, 94, 261
Fat-lobules, 92a
Fauces, mucous membrane of, 225
Female genital organs, 358
pronucleus, 60
Fenestra ovalis, 653
rotunda, 653
Fenestrated membrane, 97
Ferrein, pyramids of, 326
Fertilization of the ovum, 59, 350*b*, 364
theory of, 63
Fibræ propriæ of Meynert, 607
Fibre baskets, 638
systems, 429
tracts of cord, 479
ascending, 485
Burdach's, see *Burdach*
diagram of, 486
direct cerebellar, 490

Fibre systems, tractsof cord, ascending, dorsal white columns, 485; see *Goll and Burdach*
dorsal-spino-cerebellar, 490
Flechsig's, 490
fundamental columns, 461
Goll's, 487; see *Goll*
Gower's, 492
ground bundles, 461
lateral spino-thalamic, 488
long ascending arms of dorsal root fibres, 461, 485
posterior columns, see *Goll and Burdach*
short, 461, 497
spino-collicular, 489
spino-spinal tracts, 461
spino-tectal, 489
uncrossed cerebellar, 490
ventral-spino-cerebellar, 489, 491
spino-thalamic, 489
descending, 479
antero-lateral, 495
cerebro-spinalis, 492
colliculo-spinal, 494
comma tract of Schultze, 496
cortico-spinalis, 492
crossed pyramidal, 490
Deitero-spinal. 495, 541, 544
direct pyramidal 492, 519
fasciculus of Thomas, 496
from interstitial nucleus, 494
from nucleus of posterior longitudinal fasciculus, 494, 495
fundamental, 461, 497
Helweg's, 496
marginal bundles of Löwenthal, 495
origin of tracts, 458
oval bundle of Flechsig, 496
pallio-spinalis, 492
pyramidal, 492, 494
rubro-spinal, 494
septo-marginal, 496
short, 461, 497
tecto-spinal tract, 494
tractus cortico-spinalis, 492
vestibulo-spinal, 495
Von Monakow's tract, 494
methods of determining, 142, 479, 621, see *Methods*
Fibres, afferent nerve, 435; see also *Nerve fibres*
arcuate, 532, 541
association of pallium, 605, 607
calcified, 203
cartilage, 103
collagenous, 85
commissural of cerebral cortex, 605, 607
cone, 636
connective-tissue, 90
development of, 85
cortical of hair, 394
of cerebellum, see *Cerebellar cortex*
of cerebrum, see *Cerebral cortex*
dentinal, 233, 235
efferent root, 426
elastic, 85, 96
enamel, 238
external arcuate, 532, 540, 548
genioglossal, 229
heart muscle, 123
hyoglossal, 229
intergeminal, 666
internal arcuate, 532, 540, 557, 585
interzonal, 57
intrageminal, 666
involuntary striated (heart) muscle, 123
lens, 643
Mallory's method of staining connective-tissue, 30
mantle, 54*a*
Müller's, 637
nerve, 136; see also *Nerve fibres*
medullated, 137
non-medullated, 136
neuroglia, 147
of areolar tissue, 91
of bone, 105
of developing muscle, 128
of formed connective tissue, 95
of Remak, 137
of Sharpey, 197, 238
olfactory, layer of, 653
perforating or arcuate, of cornea, 629
projection, 605, 617
radiate of liver, 298
reticular, 91, 99
reticulo-spinal, 496
rod, 633
styloglossal, 229

Fibres, superficial arcuate, 532, 540
tendon, 95, 213
tunnel of Corti's organ, 662
voluntary muscle, 118, 121
Weigert's method for staining elastic, 28
method for staining nerve, 33
white or fibrillated, 85, 90, 213
yellow or elastic, 85, 90, 213
Fibrillar connective tissue, 86
theory of protoplasmic structure, 44
Fibrinogen, 112
Fibroblasts, 85, 99
Fibrous cartilage, 103*a*, 312
Field of Forel, 536
Fifth, V (trigeminus) nerve, 505, 562; see *Nerves, cranial*
Fila olfactoria, 505
Filar mass, 45
Filiform papillæ, 230
Fillet (or medial lemniscus), see *Lemniscus medial*
lateral; see *Lemniscus, lateral*
Filum terminale, 457
Fissure, anterior median, 523
chorioid, 649
Fixation, 5
by injection, 6
in toto, 6
Fixatives, 6, 7, 8, 9
Fixed connective tissue cells, 87
Flechsig, oval bundle of, 496
myelogenetic method of, 547, 616
tract of, 490; see *Tract, dorsal spino-cerebellar*
Flemming concerning cell-division, 54*a*
Flemming's fluid, 8
filar theory of protoplasm, 45
Foam theory of protoplasm structure, 45
Fœtal cells, 318, 322
structures, appendix epididymidis, 348
of genital system, 348, 369
testis, 348
ductus, aberrans Halleri, 348
organ of Giraldes, 348
paradidymis, 348, 383
Foliate papillæ, 660
Follicle, Graafian, 360; see also *Graafian follicle*
hair, 394
Follicles, agminated, 265*b*
Follicles, solitary, 259
Follicular cavity or antrum, 361
Folliculi linguales, 184; see *Tonsils*
Fontana, spaces of, 633
Foramen cæcum linguæ, 184
Foramina papillaria, 327
Forebrain (*prosencephalon*), 425, 586
diencephalon (*thalamencephalon*), 425, 586
epithalamus, 586
hypothalamus, 586
thalamus, 425, 586, 594, 597
interbrain, 586
section through junction of midbrain and thalamus, 592
Foregut, the, 248
general structure of walls of the gastro-intestinal canal, 250
œsophagus, 248
stomach, 252
Forel, decussation of, 585
field of, 586, 595
Formaldehyde, for macerating, 5
Formalin, commercial, 5
-bichromate method, 37
Formalin-alcohol (Schaffer), 7
Formalin-Müller's fluid (Orth's), 7
Formed connective tissue, 94
Fornix, 597
anterior pillars of, 609
commissure, 601, 605
Fossa navicularis, 358
Fountain-like decussation of Meynert, 585
Fourth ventricle, 533, 542, 552, 559
Fovea centralis, 638
Fraenkel's theory of corpus luteum, 368
Free endings of sympathetic nerves, 455
Fromann's reticular theory of protoplasm, 45
Frozen sections, 18
Fuchsin, 22
Function of cells, 50, 52
Fundamental columns of spinal cord, 461, 497
Fundus glands, 254
Fungiform papillæ, 230
Funiculus cuneatus, 479, 487, 523, 527
gracilis, 479, 487, 523, 527
posterior, 478

GAGE, showing muscle fibres, 123
Gage's hæmatoxylin, 20

Galea capitis, 349
Gall-bladder, 301
Galvanotaxis, 52
Ganglia, 427
amphicytes, 438
cerebro-spinal, 437
chain, 451
ciliary, 451
Gasserian, 562
geniculate, 505, 552
habenulæ, 597
of Scarpa of VIII, 505
otic (IX), 451
pelvic, 451
peripheral, 454
prevertebral, 451
satellite cells, 433
sphenopalatine, 451
spinal, 437, 439
spiral, 505
spirale of VIII., 505
structure of, 437
sublingual (VII), 451
submaxillary, 451
sympathetic, 454
technic for, 455
terminal, 451
vertebral, 451
Ganglion cells, 437, 458
capsule of, 437
cardiac, 167
development of, 427
of Wrisberg, 167
Gärtner's canal, 383
duct, 369
Gasserian ganglion, 562
Gastric crypts, 253
glands, 253, 254
pits, 253
Gastro-hepatic omentum, 273
Gastro-intestinal canal, general structure of the walls of, 250
Gelatin, 90, 99
carmine for injecting, 11
Prussian blue, for injecting, 11
Gelatinous marrow, 201
substance of Rolando, 466
Gemmules, 134, 569
General considerations concerning afferent and efferent paths, 517
General methods for investigation of architecture of nervous system, 621
Geniculate body, 544, 587, 594
ganglion of, VII., 451, 505, 552
Genio-glossal fibres, 229
Genital gland, 384
organs, female, 358
male, 339
ridge, 384
system, 339; see also *Reproductive system*
development of, 382
rudimentary structures connected with development of, 348, 369
Genito-urinary system; see *Urinary system*, 324 and *Reproductive system*, 339
Gennari, line of, 611
Gentian violet, 22
Genu-facialis, 556
Germ hill, 362
layers, 63
tissues derived from, 69
primary, 63, 69
Germinal epithelium, 360, 384
Germinal spot, 363
vesicle, 59, 363
Giant cells, 198
of Betz, 539, 542
Gianuzzi, crescents of, 227, 283, 308
Giraldés, organ of, 348
Gland cells, 217
Glands, 217
accessory thyreoid, 409
acini of, 222
adrenal, 418
alveolar, saccular, 219, 222
compound, 222
simple, 222
alveoli of, 222
Bartholin's, 382
basement membrane of, 219
basal filaments of, 218
Bowman's, 306
Brunner's, 258, 267, 278
bulbo-urethral, 355
cardiac, 257
carotid, 416
cells of, 217
ceruminous, 651
classification of, 217, 220
coccygeal, 417
compound, 219
corpus luteum, 365

Glands, Cowper's, 355
dehiscent, 223
development of, 220
duct, 219
alveolar, 222
racemose, 222
saccular, 222
tubular, 221
ductless, 219, 222
Ebner's, 231
epithelium of, 217
ergastoplasm, 218
excretory ducts of, 219
fundus, 254
gall-bladder, 301
gastric, 254
general structure of, 217
genital, 384
hæmolymph, 177
internal secreting, 219, 222, 223
interstitial tissue of, 220
intraepithelial, 346
kidney, 324
lacrymal, 646
large, of digestive system, 281
Lieberkühn's, 258, 265
lingual, 227
Littré's, 357, 358
liver, 223, 292
lobes of, 220
lobules, 220
lymph, 176
Mall's, 647
mammary, 402
Meibomian, 222, 574
mixed, 226
mucous, 217, 226, 249, 287
membranes of, 223
of internal secretion, 223
of the oral mucosa, 225
ovary, 358
pancreas, 286
paraganglia, 415*a*
paranucleus of, 218
parathyreoids, 410
parenchyma of, 220, 282
parotid, 282
peptic, 254
pineal, 415*c*
prehyoid, 409
prostate, 353
pyloric, 254, 257
Glands, racemose, 220
reticular, 222
saccular, 219
salivary, 281
sebaceous, 357, 390, 397, 574, 576
secreting portions of, 219
serous, 226
simple, 219
spleen, 185
sublingual, 283
submaxillary, 284
sudoriferous, 390
suprahyoid, 409
sweat, 390
tarsal, 647
thymus, 179
thyreoid, 408
accessory, 409
tonsils, 182
tubular, 219, 221
compound, 222, 324
simple, 221
branched, 249
tubulo-alveolar, 219, 287
tympanic, 415*d*
Tyson's, 357
uterine, 373
Glandulæ sudoriparæ, 390
vestibulares majores, 382
minores, 382
Glandular epithelium, 80, 217
Glans penis, 357
Glenoid, ligaments, 210
Glia, 148; see *Neuroglia*
marginal, 467
Gliosis, 148
Glisson, capsule of, 293
Globus major, 340
minor, 340
pallidus, 601, 602, 609
Glomerulus of kidney, 327
blood-vessels of, 331
Bowman's capsule of, 326, 328
olfactory, 664
Glosso-pharyngeal (IX nerve) 480, 497
Glycerin for mounting specimens, 25
jelly, 26
Glycogen granules, 103, 295
Goblet cells, 78, 82, 217, 261, 277, 307
Goetsch, concerning mitochondria, 47*a*
Gold chlorid for staining connective-tissue cells, 28

Gold-size for glycerin mounts, 26
Golgi cell, Type I., 134, 136
cell, Type II., 135, 136, 461, 572, 612
methods of staining bichlorid, 37
chrome silver, 29
Cox modification, 37
formalin bichromate, 37
mixed, 36
rapid, 36
silver, for nerve tissue, 36
slow, for nerve tissue, 36
muscle-tendon organs of, 447
net, 142
organs of, 447
Golgi-Mazzoni corpuscles, 400, 448
Golgi-Rezzoines, apparatus of, 140*c*
Goll, column of, 479, 487
nucleus of, 487, 522, 527, 589
Gowers' tract, 492
Graafian follicles, 360
antrum of, 361
corona radiata, 362
cumulus ovigerus, 362
development of, 360, 382
discus proligerus, 362
egg nest, 360
epithelium of, 360
follicular cavity of, 361
germ hill of, 362
liquor folliculi, 361
nerves of, 369
ovum of, 362
Pflüger's egg cords, 360
primitive, 361
ova, 360
rupture of, 364*a*
stratum granulosum, 361
technic of, 371
theca folliculi, 362
tunica fibrosa, 362
vasculosa, 362
Graded alcohols, 7
Grandry, corpuscles of, 443
Granule cells of cerebellum, 570
theory of protoplasmic structure, 45
Granules, of Reich, 140*b*
chromaffin, 418
phæochrome, 418
pigment, 46, 135
Gray matter of spinal cord, 428, 466
general structure of, 466
mesodermal elements of, 469
Gray matter, nervous elements of, 466
neuroglia of, 466
rami communicantes, 451
reticular formation, 482, 491
Greater omentum, 273
Ground bundles of spinal cord, 461, 497
Grübler's methylene blue, 32, 39
Grübler's water-soluble eosin, 32
Gudden, commissure of, 595
Gums, mucous membrane of, 225
Gustatory canal, 566
Gyrus ambiens, 601
dentatus, 601
of Heschl, 617
semilunaris, 601
subcallosus, 601

HABENULÆ, 597
Hæmalum, Mayer's, 21
Hæmatein, 20, 108
Hæmatoidin, crystals of, 366
Hæmatokonia, 112
Hæmatoxylin, 20
and eosin, for staining double, 23
and picro-acid fuchsin, 24
Delafield's, 21
Gage's, 20
Heidenhain's, 21
Mallory's stain, 29, 30
Weigert's, 22, 33
Hæmoglobin, 108
Hæmolymph nodes, 177
blood sinuses of, 177
blood-vessels of, 179
cells of, 178
eosinophiles, 178
mast cells, 178
phagocytes, 179
development of, 179
function of, 179
hilum of, 178
marrow-lymph, 178
relation of, to lymphatic system, 179
spleno-lymph, 178
technic of, 179
Hæmolysis, 108
Hair, 393
arrector pili muscle of the, 397
blood-vessels of, 399
bulb, 393
cells of the, 394

Hair, connective-tissue follicle of, 395
cortex of, 394
cortical fibres of, 394
cuticle of, 394
development of the, 402
eyelashes, 647
follicle, 394
germ, 398, 402
growth of the, 398
hyaline membrane, 395
inner root sheath, 394
cuticle of, 395
Henle's layer of, 395
Huxley's layer of, 395
lanugo, the, 394
lymphatics, 400
medulla of, 393
nerves of, 400, 436, 437, 446
outer root sheath, 395
papilla of, 393
pigment of, 394
prickle cells, 395
root of the, 393
root sheath, 394
sebaceous glands of the, 397
sebum of the, 398
shaft of, 393
shedding of the, 398
stratum cylindricum, 395
technic of the, 399
vitreous membrane, 395
Hair cells, 654
Halleri, ductus aberrans, 348
Haller's layer, 630
Hamulus, 656
Hardening, 13
Hassall's corpuscles, 181
Haversian canals, 194
development of, 207
fringes, 210
lamellæ, 195
spaces, 207
systems of lamellæ, 196, 208
Hayem's fluid, 64
Headgut, 225
mouth, 225
pharynx, 247
teeth, 232
tongue, 228
Hearing, organ of, 651; see *Ear*
Heart, 165
annuli fibrosi, 166
Heart, auricular muscle, 165
auriculo-ventricular ring, 165
blood-vessels of, 166
coronary arteries of, 166
development of, 167
endocardium of, 165
epicardium of, 165
lymphatics of, 166
-muscle, 123, 165; see also *Involuntary striated muscle*
muscles of, 165
myocardium of, 165
nerves of, 167, 446
technic of, 167
valves of, 166
Hecateromeres, 461
Heidenhain, concerning voluntary striated muscle, 121
concerning heart muscle, 126
demilunes of, 227
Heidenhain's hæmatoxylin, 21
Heisterian valve, 301
Helicotrema, 657
Heller's plexus, 274
Helweg, tract of, 496, 512
Hemispheres of cerebellum, 566
of cerebrum, 425
Hendrickson, concerning coats of liver ducts, 301
Henle, concerning ovum, 369
Henle's layer of hair follicle, 395
loop of uriniferous tubule, 326, 328, 329
sheath of nerve fibre, 140, 436
Hensen's cells, 660
line, 119
Hepatic artery, 294
cells, 298
cords, 297
cylinders, 303
duct, 294, 300
Heredity, 350*d*
Heschl, transverse temporal gyri of, 617
Heteromeres, 460
Hilum of liver, 293
of kidney, 324
Hindbrain (*rhombencephalon*), 425, 522
bulb, 523
cerebellum, 425, 526, 566
medulla oblongata, 425, 523
peripheral nerves of, 522
pons, 525

Hindbrain, section of, through, at level of junction of pons and cerebellum, and entrance VIII, vestibular, 552
through roots of VI, abducens and VII facial nerves, 559
through roots of V, trigeminus nerve, 562
tegmentum, 526
Hippocampus, 506
His, marginal veil of, 426
myelospongium of, 425
spongioblasts of, 426
Histogenesis, 69
Holmgren, showing trophospongium, 47
Homeotypic mitosis, 350*a*
Horizontal cells, 612
Howship's lacunæ, 204
Huxley's layer, 395
Hyaline cartilage, 101, 205
Hyaloid canal, 644
membrane, 644
Hyaloplasm, 44, 127
Hydatid of Morgagni, 348
stalked, 348
Hydrochloric acid for decalcifying, 10
Hyoglossal fibres, 229
Hyperthyreoidism, relation to mitochondria, 47*b*
Hypoblast, 63
Hypoglossal (XII nerve), 533 see also *Nerves, cranial*
Hyponychium, 393
Hypophysis cerebri (Pituitary body), 413
acidophiles, 415
basophiles, 415
Berkley, concerning, 414
blood supply of, 415*c*
chromophiles, 414
chromophobes, 414
colloid in, 415*a*
development of, 413
eminentia saccularis, 414
infundibulum, 413
interglandular cleft, 413
intermediate portion, 413
pars buccalis, 414
distalis, 415
glandularis, 414
intermedia, 413
juxta neuralis, 415*a*
neuralis, 414
Hypophysis, pars buccalis, tuberalis, 415*a*
processus infundibuli, 413
relation of, to pregnancy, 415*b*
residual lumen of, 413
secretion of, 415*a*
stainability of cells, basis of classification, 415
Tilney, concerning, 413
tuber cinereum, 413
ventricle of, 413
Hypothalamus, 425, 586, 597
corpora mammillaria, 586, 597
infundibulum, 586, 597
hypophysis, 415, 586
tuber cinereum, 586, 597

INCISURES of Schmidt-Lantermann, 139
Incremental lines of Schreger, 237
Indirect cell division, 54*b*; see *Mitosis*
Induseum, 601
Inferior brachium quadrigeminum, 526
cerebellar peduncle, see *Restiform body*
colliculi, 519
olivary nucleus, 533, 537, 541
Infundibulum, 413, 414
Injection, 10
apparatus, 11
double, 12
separate organs, 12
whole animals, 12
Innervation of muscles, 446, 455
Inokomma, 121
Instinct reactions, 431
Interalveolar connective tissue, 319
Interarticular cartilages, 210
Interbrain, 425, 586
epithalamus, 597
hypothalamus, 597
thalamus, 586
Intercalated discs, 123*b*
tubules, 282
Intercellular bridges of epithelium, 72, 76
of muscle tissue, 116
substance, 70
silver-nitrate method of staining, 28
Interfilar mass, 45
Intermediate cartilage, 208
lamellæ, 196
Intermediate neurones, 426

Internal arcuate fibres, 532, 540, 557, 585
capsule, 595, 605
ear, 653, see also *Ear, internal*
nuclei of cerebellum, 559
Internode, 139
Intero-ceptors, 448
Intersegmental neurones; see *Neurones, intersegmental*
tracts, 451, 474
Interstitial lamellæ, 196
cells of seminiferous tubule, 344
nucleus of Cajal, 494
tissue, 153, 220
Interzonal fibres or central spindle, 57
Intestines, development of, 303
Intestine; see *Small intestine*, 260; *Large intestine*, 268
Intima, 158
of arteries, 158
of lymph vessels, 169
of veins, 162
Intracartilaginous ossification, 205
Intracellular canals, 47
Intrafascicular connective tissue, 213, 436
Intramembranous ossification, 203
Intranuclear network of typical cell, 49
Inverse ferment, 278
Invertin, 278
Involuntary striated muscle (heart), 123
Cohnheim's field, 120, 123*b*
development of, 127
intercalated discs of, 123*b*, 124
McCallum's views, 123*b*
membrane of Krause, 123*b*
muscle columns of Kölliker, 120, 123*b*
nerves of, 455
sarcoplasm of, 124
technic of, 129
smooth muscle, 115
cells, 115, 264, 309
intercellular bridges of, 116
nerves of, 455
Iodine, to remove mercury, 13
Iron-alum solution, hæmatoxylin solution, 21
Iris, the, 633
greater arterial circle, 635
layers of the, 633
lesser arterial circle, 645
muscles of the, 634
pigmentation of, 633
Irritability of cells, 53
Islands, blood, 113, 167
of Langerhans, 290
Isolated smooth muscle cells, 115, 264
technic of, 129
Isotropic line, 119
substance, 119
Isthmus, 425, 574
section through, at exit of IV, trochlearis, nerve, 574
Iter, 425, 575

JENNER'S blood stain, 32
Joint capsule, 210
stratum fibrosum, 210
synoviale, 210
synovial membrane, 210
Joints, 209; see *Articulations*
Jordan, concerning anisotropic bands, 126
Jugular ganglion of X, 505, 552
Juxta-restiform body, 558, 567
inferior peduncular path, 517

KAHLBAUM'S solution of sulphalizarinate, 32*a*
Karyolysis, 389
Karyoplasm, 46, 50
Karyosomes, or false nucleoli, 49
Katabolism, 51
Keratin, 76, 389
Keratohyaline granules, 389, 393
Kidney, the, 324
arteriæ arciformes, 332
rectæ, 334
blood-vessels of, 331
capillaries of, 334
columns of Bertini, 326
convoluted tubules of, 326, 328, 329
cortex of, 324
cortical pyramids of, 326
development of, 382
hilum of, 324
labyrinths of, 326
lobulated, 324
lymphatics of, 334
main excretory duct of, 335
Malpighian pyramid, 326
medulla of, 324
medullary (or Malpighian) pyramid, 326
rays, 326
mesonephroi, 382

Kidney, metanephroi, 382
nerves of, 334
papillæ of, 325
pelvis of, 325
pronephroi, 382
pyramids of Ferrein, 326
renal artery, 324, 331
corpuscle, 327
vein, 324
renculi or lobes of, 324
septa renis, 326
stellate veins of Verheyn, 334
technic of, 338
ureter, 324, 335
uriniferous tubule, 326; see also *Uriniferous tubule*
Kidney-pelvis, 335
calyces of, 335
development of, 382
technic of, 338
Kinetic neural reaction, 430
Kinoplasm, 218
Kölliker, muscle columns of, 120, 123*b*
concerning bronchi, 310
showing Golgi cell type II, 135
spleen cells, 188
Krause, ellipsoid, 626
end-bulbs, 232, 357, 400, 444, 646
line of, 119
membrane of, 121, 123*b*
Kupffer, cells of, 299

Labia minora, sebaceous glands of, 390
Labyrinth, membranous, 653
osseous, 653
Lacrymal apparatus, 646
canal, 646
gland, 646
blood-vessels of, 646
lymphatics of, 646
nasal duct of, 646
nerves of, 646
sac, 646
technic for, 649
Lacteals, 280
Lacunæ, 105, 238
Howship's, 204
origin of, 204
Laguesse, concerning development of pancreas, 303
concerning lung lobules, 316
Lamellæ, circumferential, 196
Lamell, gæround, 196
Haversian, 195
intermediate, 196
interstitial, 196
of bone tissue, 105
Lamina, bony spiral, 656
citrea, 630
Lamina, cribrosa, 567, 627
fusca, 627
medullaris medialis, 586
membranous spiral, 656
reticularis, 660
suprachorioidea, 630
Laminæ of cerebellum, 567
Langerhans, cell islands of, 290
centro-acinar cells of, 289
centro-tubular cells of, 289
Langley and Sewell concerning secretion, 277
Lanugo hairs, 394
Large intestine, 268
Auerbach's plexus, 270, 276
blood-vessels, 273
coats of, 268
development of, 303
gland tubules, 268
Heller's plexus of, 274
lineæ coli, 269
lymphatics, 275
nerves, 276
plexus of Meissner, 269, 276
myentericus, 276
technic of, 280
Larynx, the, 307
blood-vessels of, 309
cartilages of, 307
arytenoid, 307
cricoid, 307
epiglottis, 307
Santorini's, 307
thyreoid, 307
Wrisburg's, 307
development of, 321
epithelium of, 307
lymphatics, 310
nerves, 310
perichondrium, 307
technic, 310
vocal cords, 307
Lateral fillet, 505
horn, 465
lemniscus, see *Lemniscus*

Lateral ventricles, 423
Law of Wallerian degeneration, 144
Layer of Weil, 233
Lecithin, 419
Lemniscus, bulbo-thalamic, 530
lateral, 510, 544, 547, 557, 561, 566, 575, 579
medial, 510, 513, 531, 532, 544, 547, 548, 558, 561, 566, 575, 579, 583, 594
pes-lemniscus bundles, 513
Lenhossék, concerning ciliated epithelium, 79
Lens, 643
capsule, 644
epithelium, 644
fibres, 644
hyaloid membrane, 644
invagination, 649
suspensory ligament, 644
vesicle, 650
zonula ciliaris, 644
zonule, of Zinn, 644
Lenticular nucleus; see *Nucleus lenticularis*
Leopold, concerning pregnant uterus, 376
Leucocytes, 109, 178
acidophile, 110
basophile, 110
granular, 110
lymphocytes, 109
migratory, 264
mononuclear, 109
neutrophile, 110
of milk, 406
polymorphonuclear, 109, 175
polynuclear, 109, 178
transitional, 109
Lieberkühn, crypts of, 265
glands of, 258
Ligament, glenoid, 210
spiral, 656
structure of, 94
suspensory, 644
Ligamentum denticulatum, 464
nuchæ, 97
pectinatum, 633
Lineæ coli, 269
Line of Baillarger, 615
of Gennari, 549
Lines of Retzius, 238
of Schreger, 237
Lingual glands, 227
tonsils, 184, 231
Lingualis, genio-glossus fibres of, 229
hyoglossus fibres of, 229
longitudinal fibres of, 229
styloglossus fibres of, 229
transverse fibres of, 229
Linin, 49, 132
Lipochrome, 135
Lipoid granules, 418
Liquor folliculi, 361
Lissauer, zone of, 458, 487
Littré, glands of, 357, 358
Liver, the, 292
bile duct of, 295
blood supply of, 294
capillary network, 294
capsule of Glisson, 293
cells of, 295
of Kupffer, 299
central vein of, 294
compared with other compound tubular glands, 299
connective tissue, 293, 298
cords of liver cells, 297
development of, 303
ducts, 295
common, 300
cystic, 300
hepatic, 294, 300
glycogen granules, 295
Heisterian valve, 301
hepatic artery, 294
cords, 297
duct, 294
hilum, 293
intralobular secreting tubules, 295
lobes of, 293
lobules, 293
lymphatics, 300
main ducts, 294
nerves, 300
Oppel's method of staining intralobular connective tissue of liver, 302
portal canal, 295
vein, 294
radiate fibres, 298
reticulum, 298
septa, 293
sinusoidal circulation of, 304
sublobular vein, 294

Liver, technic of, 301
tubules of, 297
Lobulated kidney, 324
Locus cæruleus, 575, 579
Long ascending arms of dorsal root fibres, 466
Longitudinal cleavage, 56
fasciculus; see *Fasciculus, medial longitudinal*
Loop of Henle, 326, 329
Loose (areolar) connective tissue, 91
Löwenthal, anterior marginal bundle of, 495
Lugol's solution, 28
Lumbar enlargement of spinal cord, 457
segments of cord, 458
Lungs, the, 314
air cells, 316
sacs, 316
vesicles, 316
alveolar bronchi, 315
ducts, 316
passage, 317
sacs, 316
alveoli of, 317
blood-vessels of, 319
bronchial artery, 319
system, 319
capsule of, 314
cells of, 318
development of, 321
elastic tissue of, 317
epithelium of, 317
fœtal cells of, 318
infundibulum of, 316
interalveolar connective tissue of, 319
Lageusse's schematic division of, 316
lobes of, 314
lobules of, 314
lymphatics of, 321
nerves of, 321
parietal pleura, 314
pulmonary artery, 319
lobule, 314
pleura of, 314
respiratory bronchi, 316
cells, 318
epithelium, 317
septa of, 314
technic of, 323
terminal bronchi of, 316
Lunula, 393
Lutein, 364*a*
cells, 364*a*
Luteum, corpus, 364*a*
Luys, nucleus of, 586, 587
Lymph, 72, 175
capillaries, 169, 270
follicles, 231
nodes, 171
blood-vessels of, 174
capsule of, 171
chains of, 171
connective tissue, 171
cords of, 173
cortex of, 173
development of, 176
germinal centre of, 173
hilum of, 172
lymphatics of, 175
lymphoid tissue proper, 174
medulla of, 173
nerves of, 175
nodules of, 173
reticular connective tissue of, 174
sinuses of, 173
technic of, 101, 176
nodule 99, 173
germinal centre of, 173
paths of the eye, 645
spaces, 169
pericellular, 169
perivascular, 163
vessel system, 169
capillaries of, 169
development of, 170
lymph spaces, 169
relation of, to hæmolymph node, 179
stomata of, 170
technic of, 170
vessels, coats of, 169
structure of, 169
Lymphatic organs, 171
development of, 176, 179, 181, 184, 190
hæmolymph nodes, 177
lymph nodes, 171
spleen, 185
technic of, 176, 179, 182, 185, 191
thymus, 179
tonsils, 182
tissue, 171
Lymphocytes, 109

Lymphoid cells, 174, 264
tissue, 174

MACERATING fluids, 4
Maceration, 4
Macrocytes, 107
Macro-nucleus, 58
Macula acustica, 654
lutea, 636
fovea centralis, 638
Male genital organs, 339
pronucleus, 60
Mall, concerning development of fibrillar connective tissue, 85
glands of, 647
Mallory's aniline blue stain for connective tissue, 30
Mallory's phosphomolybdic acid hæmatoxylin stain for connective tissue, 29
phosphotungstic acid hæmatoxylin stain for connective tissue, 30
Malpighian bodies, 186
body of kidney, 327
Bowman's capsule, 326, 328
development of, 383
glomerulus, 326, 327
pyramid, 326
Mamillo-thalamic tract, 587, 597
Mammary gland, 402
active, 404
alveoli of active, 404
of inactive, 403
ampulla of, 403
blood-vessels of, 405
colostrum corpuscles, 405
development of, 407
ducts of, 402
of nipple, 403
fatty secretions in, 31
inactive, 403
interlobar septa of, 403
interlobular septa of, 403
lobular ducts of, 403
lymphatics of, 406
milk, 405
nerves of, 406, 446
secretion of, 404
structure of, 402
technic of, 407
Mantle fibres, 54*a*
Marceau, concerning heart muscle, 126
Marchi's method for staining degenerating nerves, 35, 143
Busch's modification of, 36
Maresh's modification of Bielschowsky's stain for connective tissue, 31
Marginal bundle of Löwenthal, 495
veil of His, 426
Marrow, 197; see *Bone marrow*
lymph nodes, 178
Martinotti, cells of, 612, 614
Mast cells, 89, 178, 199
Matrix of nail, 391
Maturation, 59
of ovum, 59, 363
of spermatozoon, 59, 350*a*
Mayer's hæmalum, 21
McCallum, concerning heart muscle, 123*b*
Media of arteries, 159
of lymph vessels, 169
of veins, 162
Medial eminence, 523
accessory olives, 541
fillet, 532, 544, 547, 548
longitudinal fasciculus, see *Fasciculus medial longitudinal*
Median center of Luys, 587, 597
lemniscus, 531, 532
raphé, 534, 540, 563, 566
septum, dorsal, 463
Mediastinum testis, 339
Medulla oblongata, 425, 523
accessory olivary nucleus, 541
olives, 541
afferent cerebellar neurones, 541, 548
(afferent) peripheral roots, 527, 531, 538, 546
secondary tracts of, 527, 531, 538, 540, 546
terminal nuclei of, 527, 531, 538, 542, 546
ala cinerea, 523, 531, 533
anterior fissure, 523
pyramid, 493, 523
arciform (arcuate) nucleus, 540
arcuate fibres, 532, 540, 548
area acustica, 523, 533
auditory (acusticus) nerve, 544
central canal, 523
gelatinous substance, 533
gray matter, 527, 533
tegmental tract, 541

Medulla, cerebellar peduncles, 552, 558, 567, 594
cerebello-olivary fibres, 541
cerebellum, 523
chorioid plexus, 523, 533
clava, 523
cochlear nerve, 542, 544
nuclei, 544
colliculo-spinal tract, 529, 531, 532
column of Burdach, 523, 527, 589
of Goll, 523, 527, 589
compared with spinal cord, 523
corpus restiforme, 523, 540, 541
cranial nerves of, 523
crossed pyramidal tract, 531
cuneus, 523
decussation of fillet, 531
Deiter's nucleus, 495, 505
tract, 495, 541
descending root of fifth nerve, 527
or spinal root of vestibular portion of eighth nerve, 540, 547
suprasegmental paths, 527, 529
tract from Deiter's nucleus, 541, 544
from the vestibular nuclei, 495, 496, 532, 541
development of, 425
direct cerebellar tract, 490
pyramidal tract, 493
dorsal horns, 527
nucleus of ninth cranial nerve, 513, 537
of tenth nerve, 531
spino-cerebellar tract, 490; see *Tracts*
dorsal horns of, 527
efferent peripheral neurones, 527, 531, 533, 546
suprasegmental neurones, 505, 531, 532, 552
eminentia abducentis, 523
hypoglossi, 542
external arcuate fibres, 532, 540, 548
fasciculus cuneatus, 523, 527
gracilis, 523, 527
solitarius, 532, 538, 540, 546
fillet or medial lemniscus, 532, 544, 547, 548
formatio reticularis, 532, 541, 548
fourth ventricle, 523, 533
Medulla, funiculus cuneatus, 478, 487
gracilis, 478, 487
ganglion of Scarpa, 544
gelatinous substance of Rolando, 527
general structure of, 523
genu facialis, 523
Gowers' tract, 492
gray reticular formation, 531
inferior medullary velum, 523
internal arcuate fibres of, 532, 538, 540, 557, 585
intersegmental neurones, 529, 532, 541, 548
lateral fillet, 510, 544, 547
lemniscus, 497, 499, 510, 544, 547, 548
longitudinal fasciculus, 548
median lemniscus, 531, 532
longitudinal fasciculus, 541, 548, 549
tract from, 529
raphé, 540
motor decussation, 527
nuclei arcuati, 540
laterales, 540
of posterior columns, 487
of the floor of the ventricle, 523
nucleus, abducentis, 523
alæ cinereæ, 523, 531
ambiguus, 537, 546
arcuatus, 540
commissuralis, 532, 539
cuneatus, 523, 531, 540
dorsal sensory, 539
gracilis, 523, 531
hypoglossi, 523, 531
magnocellularis funiculi dorsalis, 532
medialis vestibularis, 533
of acoustic nerve, 544
of the column of Burdach, 523, 531
of the column of Goll, 523, 531
of the fifth spinal nerve, 523
of origin of eleventh cranial (*spinal-accessory*) nerve, 513, 527
of origin of twelfth cranial (*hypoglossal*) nerve, 523, 527, 533
of vagus nerve, 513, 523, 531
raphés, 540
reticularis, 540
rotundus, 539
ventralis fasciculi solitarii, 538

Medulla, olivary nuclei, 523, 533, 541, 542
olives, 523, 533, 548
olivo-cerebellar fibres, 538, 541, 548
pallio-ponto-cerebellar path, 526
pallio-spinal tract, 531
peduncles of, 541
peripheral neurones of, 531
plexus chorioideus, 523
pons Varolii, 525
posterior columns of, 523
septum, 523
predorsal tract, 541
pyramidal decussation, 523, 531
tracts, 527, 531
raphé, 540
restiform body, 523, 540, 541, 548
reticulo-spinal fibres of, 495
root fibres of spinal V., 523
and nucleus of origin of sixth (*abducens*) cranial nerve, 523, 548
of seventh (*facial*) cranial nerve, 523
and nuclei of eighth (*auditory*) cranial nerve, 523, 542, 544
of eleventh (*spinal-accessory*) cranial nerve, 523
of ninth nerve (*glosso-pharyngeal*), 523
of tenth nerve (*vagus*), 533, 535, 537
of twelfth (*hypoglossal*) cranial nerve, 523, 533
rubro-spinal tract, 529, 532, 548
secondary cochlear tract, 547, 557, 561, 566, 583
sensory tract of fifth nerve, 562
vestibular tract, 544
section through decussation of fillet, 531
entrance of cochlear root of eighth, 542
lower part of inferior olivary nucleus, 533
middle of olivary nucleus, 542
pyramidal decussation, 527
sensory decussation, 531
solitary fasciculus, 528, 532, 540
spinal (descending) root of fifth cranial nerve, 523
spinal V, 509, 522, 523, 541
spino-cerebellar tract, 529, 532, 540
-thalamic tract, 529, 532, 540
Medulla, striæ medullares, 546, 597
sulcus limitans, 523
superior medullary velum, 523
technic of, 526
tecto-spinal tract, 489, 494, 497, 585
tegmentum (see *Tegmentum*), 526
terminal nucleus of the descending (sensory) root fibres of the fifth nerve, 527
tract of Gowers, 492
from interstitial nucleus of Cajal, 494, 529, 532, 541, 548, 558
of Helweg, 496, 512, 514
of Löwenthal, 495
tractus reunions of Fuse, 540
tractus spinalis trigemini, 527
trapezius, 547
trigonum hypoglossi, 523, 533
vagi, 533
tuberculum cinereum, 523 (tuberculum Rolandoi or trigemini)
vestibular nerve, 544; see *Auditory nerve*
vestibulo-spinal tract, 495, 496, 529, 532, 548
Medulla spinalis, 422
Medullary cords, 181
lamina, 597
pyramid (Malpighian), 326
rays, 326
sheath, 136, 138
velum, 523, 574
Medullated (myelinated) nerve fibres, 138, 435
number of in man, 437, 457
Weigerts' stain for, 33
Megalocytes, 188
Megakaryocytes, 198
Meibomian glands, 222, 647
Meissner, corpuscles of, 357, 400, 444
Meissner, plexus of, 259, 268, 269, 276. 442
Melanin, 135
Membrana chorii, 377
elastica externa, 160
interna, 158
limitans olfactoria, 306
preformativa, 246
propria, 73, 223
tectoria, 661
Membrane, basal, 73
cuticular, 73, 245
glial, 148

Membrane, mucous, 223
of Bowman, 627, 628
of Descemet, 629
of Krause, 121, 1230
of Reissner, 658
peridental, 239
serous, 169
Schneiderian, 305
synovial, 210
Membranes of brain and cord, 432
arachnoid, 434
dura mater, 432
pia mater, 433
Membranous cochlea, 657
labyrinth, 653
spiral lamina, 656
ligament, 656
Meninges, 432
Meniscus, tactile, 443
Menstrualis, decidua, 376
Menstruating uterus, 376
Menstruation, 375
Mercuric chlorid as a fixative, 8
Merkel's corpuscles, 443
Mesencephalic root of fifth, V (*trigeminus*) cranial nerve, 505; see *Nerves, cranial*
Mesencephalon, 425, 577
Mesenchymal epithelium, 210
Mesenchyme, 85
Mesentery, 273
Mesoappendix, 270
Mesoblast, 63
Mesoderm, 63
tissue derivations from, 70, 126, 243, 302, 321
Mesonephric or Wolffian duct, 383
visceral layer of, 302
Mesonephros, 383
derivations from, 348, 369
Mesophragma, 121
Mesothelium, 72, 80
technic for, 82
Metabolism of cells, 51, 218
Metanephroi, 382
Metaphase, 56
Metaplasm, 46
Metathalamus, 587
Methods for studying fibre tracts of the cord, 479, 621
atrophy, 622
axonal degeneration, 622
Methods, comparative anatomy, 622
embryological physiological, 622
experimental physiological, 622
myelogenetic, 622
pathological physiological, 622
secondary degeneration, 622
von Guddens, 622
Methyl blue, 22
green, 22
violet, 22
Methylene blue for staining nerve cells, 39
Meynert, commissure of, 595
decussation of, 579, 585
fasciculus retroflexus of, 597
fibræ propriæ of, 607
radiations of, 615
Microcytes, 107
Micron (micromillimeter), 18
Micro-nucleus, 58
Microsomes, 44
Microtome, 17
Midbrain, mesencephalon, 425, 577
aqueductus Sylvii, 577
basis pedunculi, 577
brachia conjunctiva, 577
cerebral peduncles, 581
colliculi, 577, 581, 583, 585
corpora quadrigemina, 577, 581
cranial nerves III and IV, 577; also see *Nerves, cranial*
crura cerebri, 581
decussation of Forel, 583
of Meynert, 579, 585
Edinger-Westphal nucleus, 581, 583
geniculate bodies of, 583, 594
inferior brachium quadrigeminum, 526
colliculi, 577, 579, 580, 583
internal arcuate fibres, 585
iter, 577
lemniscus, 583
mesencephalic root of fifth nerve, 579, 583
optic nerve, 583
pes pedunculi, 577, 584
Midbrain, posterior commissure, 585
longitudinal fasciculus, see *Fasciculus*
red nucleus of, 567, 577, 583, 594, 595
reticular formation, 583

Midbrain, root fibres and nucleus of origin of third (*oculomotor*) cranial nerve, 581
section through exit of third (oculomotor) cranial nerve, 581
spino-tectal tract, 585
substantia nigra, 577, 584
superior cerebellar peduncles of, 584
colliculi, 584, 585
tegmentum, 577
Middle ear, 652; see *Ear, middle*
Midgut, 260
small intestine, 260
Migratory leucocytes, 264
Milk, 405
cells of, 405
colostrum corpuscles of, 405
teeth, 240, 244, 245, 246
Minot, concerning endothelium and mesothelium, 80
concerning the pregnant uterus, 376
Mitochondria, 47, 135, 218
Benda's method of staining, 32
Cowdry, concerning, 47*b*
Goetsch, concerning, 47*b*
Miton, 45
Mitosis, 54*b*
anaphase, 56
homeotypic, 350*a*
metaphase, 56
method of demonstrating by Flemming's fluid, 64
of gastric glands, 256
prophase, 54*b*
technic for, 64
telophase, 57
Mitotic figure, 56
Mitral cells, 663
Mixed glands, 226
spinal nerve, 430
Modiolus, 655
Mollier, concerning splenic pulp, 189
Monaster, 56
Mononuclear cells, 188
leucocytes, 109
Monophyletic theory of blood cells, 113
Monosynaptic arc, 498
Mordanting, 33
Morgagni, hydatid of, 348
Mossy cells, 147
fibres, 519
Motion of cells, 53
Motor cells of anterior horns, 459
decussation, 489
end plate, 457
nuclei, 456
peripheral nerves, 456
precentral area, 549
Mounting, 25
celloidin specimens, 26
in balsam, 26
in glycerin, 25
paraffin sections, 26
Mouth, the, 225
blood-vessel of, 227
end bulbs in mucous membrane, 445
glands of, 225
lymphatics of, 227
mucous membrane of, 225
nerves of, 227, 232, 445
technic of, 228
Mucin, 86, 226
Mucous glands, 226
membranes, 223
end bulbs in, 439
general structure of, 223
muscularis mucosæ, 223
of alimentary tract, 224
submucosa, 223
tactile cells of, 437
corpuscles of, 438
tissue, 86
tubules, 227
Mucus, 217, 226, 253, 262, 277
Müller, cells of, 637
circular muscle of, 632
fibres of, 637
Müller's fluid, 7
Müllerian ducts, 348, 354
Multinuclear cells, 188
Multipolar nerve cells, 131, 434, 450
Muscle, arrector pili, 397
auricular, 165
cells, 115
ciliary, 632
circular, of Müller, 632
columns of Kölliker, 120, 123*b*
discs, 119
fibrillæ, 118
nuclei, 116, 123
of sweat glands, 402
spindles, or neuro-muscular bundles, 446

Muscle, tendon junction, 214
organs of Golgi in, 447
peripheral nerve terminations in, 448
plate, 127
tissue, 115
classification of, 115
development of, 125
histogenesis, 126
intercalated discs of, 125
heart, 123
involuntary smooth, 115
intercellular bridges of, 116
involuntary striated (heart muscle), 123
intercalated discs of, 125
of alimentary tract, 224
technic of, 129
voluntary striated, 118
anisotropic substance, 119
Cohnheim's fields, 120, 123*b*
cross fibre nets of, 121
end bulbs of, 445
ergastoplasm, 118
Heidenheim's scheme of structure of, 121
Hensen's line, 119
inokomma, 121
isotropic substance, 119
Krause's line, 119
membrane, 121, 123*b*
mesophragma, 121
muscle columns of Kölliker, 120, 123*b*
discs, 119
spindles, 440
myofibrils, 121
nerves, terminations in, 446, 451, 455
nuclei, 118
of head and brain, 503
Pacinian corpuscles of, 445
Ruffini's theory of nerve terminations in, 448
sarcolemma, 118
sarcoplasm, 119
sarcous element of Bowman, 120
technic of, 129
telophragma, 121
ultimate fibrillæ, 119
white and red fibres, 121
Muscles, voluntary, 212
capsule of, 212
Muscles, endomysium, 213
epimysium, 212
fascicles of, 212
growth of, 214
intrafascicular connective tissue of, 213
perifascicular sheath, 213
perimysium, 213
sarco styles of, 214
Muscular system, 212
blood-vessels of, 215
bursæ, 213
lymphatics of, 215
nerves of, 215
technic of, 215
tendons of, 95, 213
voluntary muscle, 212
Muscularis mucosæ of mucous membranes, 223
Musculature of intestine, 117, 267, 271
Myelin, 139
sheath, 136
Myelinated nerve fibres, 138
Myelon, 422
Myeloarchitecture, 615
Myelocytes, 197
Myelogenetic method for determining fibre tracts, 616
Myelon, 442
Myeloplaxes, 198
Myelospongium of His, 425
Myentericus, plexus, 276
Myoblast, 126, 215
Myocardium, 165
primitive, 168
Myofibril, 121
Myotome, 127
Myxœdema, 409

Nabothi, ovula, 374
Nail-bed, 391
root, 391
groove, 391
wall, 391
Nails, the, 391
development of, 407
eponychium of, 393
hyponychium, 393
keratohyalin of, 393
lunula of, 393
matrix of, 391
prickle cells of, 393

Nails, technic of, 393
Nares, 305
accessory nasal sinuses, 305
cells of, 306
basal, 306
olfactory, 306
sustentacular, 306
development of, 321
glands of Bowman, 306
membrana limitans olfactoria, 306
Schneiderian membrane, 305
structure of, 305
olfactory region, 305
respiratory region, 305
vestibular region, 305
technic of, 310
zone of oval nuclei, 306
of round nuclei, 306
Nasal duct, 646
Neëncephalon, 521
Nemiloft, showing amitosis, 54
scheme of medullated nerve fibre, 141
Neo-cerebellum, 568
Neopallium, 521, 607
association fibres of, 607
fibræ of Meynert, 607
Nerve cells, 130; see also *Neurone*
amacrine, 637, 665
amphicytes, 438
anterior (ventral) horn, 470
association, 574, 617
basket, 517, 570
Bentz', 612
bipolar, 131, 434
brush, 665
Cajal's, 612
capsule, 438
caryochromes, 134, 570
cerebro-spinal ganglia, 130, 427, 437
chromophilic bodies, 132
column, 458, 460, 472
cone-bipolar, 636
cone-visual, 636
efferent projection, 617
ependymal, 148, 426, 467
extrinsic, 458
diffuse, 474
ganglion, 437, 458
giant, of Betz, 589, 612
glia, 148
Nerve cells, Golgi, Type I, 134, 136
Type II, 135, 136, 458, 461, 472, 612
granule cells of cerebellum, 570
hecateromeric, 461
heterolateral, 460
heteromeric, 460
homolateral, 461
horizontal, 612
in gray matter of cord, 458
intrinsic, 458
inverted pyramidal, 612
ipsilateral, 460
Martinotti's, 612, 614
mitral, 663
mossy, 147
motor, of the anterior horn, 131, 459
Müller's, 637
multipolar, 131, 434, 450
neurolemma, 148, 427, 468
neuroblasts, 130, 147, 426
neuroglia, 147, 426, 612
nucleus of, 131
of Gierke, 470
of motor area of cerebral cortex, 612
of van Gehuchten, 573
outside the spinal cord, 458
peripheral motor, 470
sensory, 437
pigment in, 135
polymorphous, 612
preganglionic sympathetic, 459
pre-motor, 522
projection, 617
Purkinje, 568
pyramidal, 609
inverted, 612
rod-bipolar, 636
rod-visual, 636
root, 458, 470
somatochromes, 134
spider, 147
spinal ganglion, 437, 438, 439
spongioblasts, 147, 426
stellate of cerebellum, 570
of cerebral cortex, 611
of colliculi, 585
sympathetic ganglion, 448, 454
tautomeric, 490
typical sympathetic, 454

Nerve cells, unipolar, 131, 439
endings, 441; see *Peripheral nerve terminations*
fibres, 130, 137
afferent peripheral, 423, 427
root, 427
arcuate, 532, 541
association, 429, 605, 607, 617
axone, 136
cerebro-pontile, 558
climbing, 573
cone, 636
deep tangential, 615
dorsal root, 423, 427
efferent peripheral, 423
efferent root, 423, 426
fastigio-bulbar, 557, 561
glial, 148
layer of, of retina, 637
lens, 643
mammillo-tegmental, 597
mammillo-thalamic, 597
medullary (myelin) sheath, 136
medullated (myelinated), 138, 140c
mossy, 573
motor end plates of, 456
myelinated, 138
nerve, 136
neuroglia, 147
non-medullated, 137
non-myelinated, 137
of Bergmann, 574
of Remak, 137
origin of, of white matter of cord, 458
pallial, 605
pallio-collicular, 514
pallio-nigral, 515
pallio-pontile, 566, 577
pallio-rubro spinal, 514
pallio-striate, 515
pallio-subthalamic, 515
pallio-tectal, 514
pallio-thalamic, 515, 605
parallel, of the cerebellum, 572
perpendicular pontile, 558, 561
pes-lemniscus, 575
postganglionic, 448, 451
preganglionic, 448, 451, 506
projection, 605
reticulo-spinal, 496
rod and cone, 636
Nerve fibres, spino-spinal, 496
superficial tangential, 615
roots, afferent fibres, 437
dorsal, 435, 459
sensory, 423
terminations, 441
motor, 456
sensory, 441
tissue, 130
Golgi methods of staining, 36
neuroglia, 147
neurone, 130
axone, 135
cell body, 130
dendrites, 135
protoplasmic processes, 135
technic for, 33, 149
Nerves, cranial, table of, 624, 625
I (olfactorius), 505, 601
II (opticus), 505, 535, 594, 640
optic decussation of, 595
chiasma, 595, 641
tract, 505, 592, 594, 595, 609
motor and sensory nuclei of, 640
III (oculomotor), 505, 506, 509, 516, 517, 581
oculomotor nucleus, 517, 581
root fibres and nucleus of origin of third, 513, 548
ganglia of, 451
IV (trochlearis), 505, 506, 509, 517, 548, 574
root fibres and nucleus of origin of fourth, 513, 548, 574
V (trigeminus), 509, 522, 523, 548, 558, 562
Gasserian ganglion, 562
mesencephalic root of fifth, 505, 523, 564, 574, 579
motor nucleus of fifth, 513, 527, 562
"principal sensory" nucleus, 564
secondary tracts from, 562
semilunar ganglion of fifth, 504
sensory nucleus of fifth, 507, 562
and motot root fibres of fifth, 527, 562, 566
spinal root of fifth, 504, 523, 566
terminal nucleus of, 523, 527, 538, 565, 562
tractus spinalis trigemini, 527, 562
VI (abducens), 506, 509, 516, 517, 522, 552, 559

Nerves, cranial, nucleus of origin of sixth, 513, 552, 558, 561
abducentis, 506, 509, 516, 522, 552
root fibres of sixth, 552, 558, 559, 561
VII (facial), 506, 522, 552, 559, 566
ganglion geniculate, 451, 505, 552
glosso-palatine, 552
nerve of Wrisberg, 552
nucleus facialis, 513, 548, 556
motorius, 516, 523
salivarius, 537
of origin of seventh, 513
root fibres of seventh, 546, 552, 559
VIII (auditory), 522, 544
cochlear branch of eighth, 505, 542, 544
ganglion of Scarpa, 505, 512, 544
spirale, 505, 544
nuclei of eighth, 544
Deiter's, 544
von Bechterew's, 544
root fibres of eighth, 544
vestibular branch of eighth, 505 540, 544, 547
IX (glosso-pharyngeal), 506, 515, 522, 523, 533, 566
descending or sensory root fibres of the ninth, 533
dorsal nucleus of ninth, 534
ganglia (superior and petrosal) of, 451, 505, 552
motor nucleus of ninth, 513, 537
nucleus ambiguous, 537
nucleus salivarius inferior, 537
root fibres of ninth, 546
X (vagus), 515, 516, 522, 523, 533
descending or sensory root fibres of tenth, 535
dorsal nucleus of tenth, 523, 535
ganglion jugular, 505, 552
nodose, 451, 505
motor nucleus of tenth, 513, 523, 535
nucleus alæ cinereæ, 523, 531
nucleus ambiguus, 537, 566
root fibres of tenth, 533
XI (spinal accessory), 527
nucleus of origin of eleventh, 513, 527
root fibres of eleventh, 527
Nerves, cranial, XII (hypoglossal), 506 515, 422, 533
motor nucleus of twelfth, 513, 523
nucleus of origin of twelfth, 523, 531, 533, 566
nucleus tactile-lingual reflex, 527
root fibres of twelfth, 523, 531
mixed spinal, 435
olfactory, 505, 601
peripheral, 428, 435
spinal, anterior, motor or efferent portions of, 456
sensory, or afferent portions, 437
Nervous system, the, 422; for complete analysis see *Table Contents* p. vii
autonomic, 424, 448
central, see *Central nervous system*, 422, 457
brain, 503
spinal cord, 457
cerebro spinal peripheral, 424
connective tissue of, 146
development of, 69, 424
general structure of, 422
general methods of investigation of architecture of, 621
membranes of brain and cord, 432
peripheral, 422, 435
afferent peripheral neurones and receptors, 437
efferent peripheral cerebro-spinal somatic neurones, 456
sympathetic system, 448
physiology of suprasegmental paths, 507
segmental, 429
somatic, 423
special technic, 33, 623
splanchnic, 423
suprasegmental, 429
sympathetic, 424, 448
visceral, 423
technic, 461, 501, 526, 623
table of cranial and spinal nerves 624, 625
Net-knots, 49
Neumann's dental sheath, 237
Neural arc, 430, 498
cerebellar, 499
cerebral, 501
disynaptic, 499

Neural arc, monosynaptic, 498
pallial, 501
three-neurone spinal reflex, 499
two-neurone spinal reflex, 498
canal, 130
fold, 424
groove, 424
plate, 424
reactions, 422
conscious, 430
habit, 430, 431
instinct, 430, 431
kinetic, 430
reflex, 430, 431
skilled, 430, 431
somatic, 424, 430
splanchnic, 424, 430
static (tonic), 43c, 431
tube, 424
Neuraxone, 130
Neurite, 130
Neuroblasts, 130, 147, 426
Neuro-epithelium, 80
cone bipolar cells, 636
visual cells, 636
rod bipolar cells, 636
visual cells, 636
Neurofibrils, 133
Cajal's method of staining, 38
importance of, in neurone, 141
Neuroglia, 147
cells, 147, 426, 459
fibres, 147, 459
ependyma of, 467
gliosis, 148
marginal glia, 467
membrana limitans gliæ, 467
mossy cells of, 147
Müller's cells of, 637
neuroblasts, 130, 147, 426
of brain, 522
of cerebellum, 522
of spinal cord, 467
spider cells, 147
spongioblasts of, 147, 426
technic for, 149
Weigert's stain for, 40
Neurokeratin network, 140*b*
Neurolemma, 136, 137, 139
and axolemma, relation of, 140
"band" fibres, 149
-cells, 145, 427, 468
Neurological staining methods, 33
Neuromuscular bundles, 446
Neurone, the, 130
achromatic nucleoplasm, 132
arc, 475
three-neurone, spinal, 499
two-neurone, spinal, 498
axone of, 136
Barker's classification, 134
canaliculi, 135
caryochromes, 133
cell body, 130
chondriosomes, 135
chromophilic bodies, 135, 141
clefts or incisures of Schmidt-Lantermann, 139
contact theory of, 141
continuity theory of, 142
cytoplasm of, 132
chromophilic bodies, 133
neurofibrils, 133
peri fibrillar substance, 133
degenerative changes in, 142
dendrites of, 135
development of, 130
extracellular network of, 142
functional centre of, 140*d*
genetic centre of, 140*d*
Golgi net, 142
intranuclear network, 132
long axone neurone, 136
mitochondria, 135
neurilemma, 137
neurofibrils of, 133, 142
Nissl, special method of technic for, 39
nucleolus, 132
nucleus, 131
nutritive centre of, 140*d*
pericellular network of, 141
perifibrillar substance, 133
physiological significance of, 140*d*
pigment in, 135
protoplasmic processes, 136
retraction, hypothesis of, 141
Schmidt-Lantermann segments, 139
sheath of Schwann, 139
short axone neurone, 136
somatochromes, 134
substantia nigra, 135
synapsis of, 141
technic for, 33, 149

Neurone, trophic centre of, 140*d*
Neurone-theories, 141
Neurones, afferent peripheral, 423, 427, 428, 437
cerebellar, 541, 548, 558, 561, 566, 575, 579
segmental, 429, 504; see also *Segmental brain*
suprasegmental, 429, 506
associative, 429, 504
central, 423, 426, 428
cone association, 640
connector (Gaskell), 423
cortical precentral, 477
efferent peripheral, 423, 426, 428, 456, 527, 531, 538, 542, 546, 552, 559, 562, 575, 578, 581, 592
peripheral segmental, 506
suprasegmental, 429, 506, 532, 542, 552, 559, 566, 575, 583, 594, 595, 609
intermediate, 423, 426, 428
intersegmental, 429, 506, 522, 529, 532, 541, 548, 558, 561, 566, 575, 579, 583, 594, 595
intrasegmental, 429, 506, 522
olivo-cerebellar, 512
pallio-cerebellar, 512
pallio-pontile, 513
peripheral, 423, 428, 437
afferent, 427, 428, 437
efferent, 423, 426, 456
ponto-cerebellar, 513, 561
preganglionic, 448, 471
rod-association, 640
sensory, 423
somatic (peripheral), 428, 456
spino-cerebellar, 492
splanchnic (peripheral), 428, 505
suprasegmental associative, 429
thalamo-bulbar, 497
thalamo-cortical, 505
upper motor, 492
visceral (peripheral), 428
Neuroplasm, 138
Neutral carmine, 23
Neutrophile granules, 110
leucocytes, 110
Nipple, 403
Nissl method for staining nerve cells, 39
concerning chromophilic bodies, 134
pathological value of, 134
Nitric acid for decalcifying, 11
for dissociating muscle tissue, 5
Nodes, hæmolymph, 177
lymph, 171
marrow lymph, 178
splenolymph, 178
of Ranvier, 139
Nodose ganglion of X nerve, 505
Non-medullated (non-myelinated) nerve fibres, 137
Normoblasts, 198
Notochord, anlage of, 63, 209
Noyes concerning nerves of teeth, 241
Nuclear dyes, 20
alum carmine, 22
basic anilin, 22
carmine, 20
combination of Gage's and Mayer's formulas, 21
Delafield's hæmatoxylin, 21
Gage's hæmatoxylin, 20
hæmatoxylin, 20
Heidenhain's hæmatoxylin, 21
Mayer's hæmalum, 21
Weigert's hæmatoxylin, 22
eccentricity in nerve cell, 146, 446
fluid, 50
groups of placenta, 379
membrane, 49
sap, 50
structures, method of demonstrating by Flemming's fluid, 8
Nuclei of brain and cord, abducens, 552, 561, 566
accessory olivary, 541
acoustic tubercle, 544
alæ cinereæ, 523, 531, 533
ambiens, 546
ambiguus, 537, 546
amygdaliformis, 601, 609
arciform, 540
arcuate, 540
caudate, 594, 597, 601, 602, 605, 609
centralis superior, 575
commissuralis, 532, 539
cochlear, 544, 546, 561
colliculi inferioris, 579
cuneatus, 478, 487, 489, 522, 527, 531, 540, 589
Darkschewitsch, 494
Deiter's, 544, 557, 558, 561
dentate, 559

Nuclei of brain and cord, diffuse, 474
dorsal sensory, 539
Edinger-Westphal, 581, 583
emboliformis, 559
eminentia medialis, 542
external geniculate, 594
facial, 552, 556, 559, 566
fastigii, 559
funiculi teretis, 542
ganglia habenulæ, 597
globose, 559
glosso-pharyngeal, 556
gracilis, 479, 487, 523, 531, 540, 579
hypoglossal, 566
inferior olivary, 533, 537, 541
intercalatus of Stoderini, 542
internal of cerebellum, 559
intersegmental, 522
interstitial of Cajal, 494, 520, 532, 541, 548, 558
intrasegmental, 522
lateralis, 542
lenticularis, 595, 597, 601, 602, 605, 609
locus cæruleus, 575, 579
magroo cellularis cornua dorsalis, 532, 541
medial accessory olivary, 541
oculomotor, 549, 581, 583
of column of Burdach, see *Burdach*
of column of Goll, see *Goll*
of cranial nerves, see *Nerves, cranial*
olivary, 523, 533, 541, 544, 557, 566
pontile, 558, 577
preolivary, 557
prepositus, 542
raphes, 541
red (ruber), 567, 577, 581, 583, 594, 595
reticularis, 541
reticularis tegmenti, 561
retrofacial, 556
rotundus, 539
salivarius, 537, 557
Schwalbe's, 544
semilunaris, 557
sensibilis propritus, 474
sensory of V, 564
solitary fasciculus, 538, 540
spinal accessory, 513, 527
superior olivary, 541, 548, 557
Nuclei of brain and cord, tecti, 559
terminal, 522
thalamic, 586, 587, 597, 603, 604
trapezoid, 544, 547, 557, 566
triangular, 544
trigeminus, 562, 564, 566
trochlearis, 578
vagus, 546
vestibular, 533, 544
von Bechterew's, 544
Nuclei terminal, 522
the, 48, 131, 429
Nuclein, 48
Nucleolus or plasmosome of typical cell, 50
false, 49
Nucleoplasm, 50
Nucleoreticulum, 49
Nucleus, the, 48
achromatic element of, 49, 132
amphipyrenin, 49
chromatin of, 49, 132
function of, 48
intranuclear network of, 49
karyoplasm of, 50
karyosomes, 49
linin, 48
membrane of, 49
net-knots, 49
network of, 49
nuclein of, 49
nucleolus of, 49
nucleoreticulum of, 49
of a typical cell, 47*b*
paranuclein, 50
pulposus, 209
resting, 57
Nuel's space, 660
Nutrient canal, 201
foramen, 201
vessels, of bone, 201
Nutritive center of neurone, 141

Oculomotor III nerve, 581
nucleus, 549, 581
Odontoblasts, 233, 246
Œsophagus, the, 248
ampulla of, 249
glands of, 248, 249
technic of, 250
Oil of origanum Cretici for clearing specimens, 26

Olfactorius (I nerve), 505, 601
Olfactory area, 601
bulb, 601, 664
cells, 306
granule layer, 665
of longitudinal fibre bundles, 665
of mitral cells, 665
of olfactory fibres, 665
molecular layer, 665
olfactory glomeruli of, 665
path, 506
glomeruli, 665
group of segmental neurones, 505
nerve, 435, 505, 665
organ, 653
pallium, 601
region of the nares, 305
tract, 505, 506, 666
Olivary nucleus, 523, 544, 548, 557, 566
Olives, 523, 541, 548
accessory olivary nucleus, 523, 533, 541
dorsal accessory, 541
medial accessory, 541
superior, 541, 548, 557
Olivo-cerebellar fibres, 512, 541, 548, 558, 567
neurones, 512
Omentum, 273
gastro-hepatic, 273
greater, 273
Oögenesis, 363
Oogonia, 364
Opie, concerning the cell-islands of Langerhans, 291
concerning the pancreas, 291
Oppel's method of staining intralobular connective tissue of liver, 302
Optic chiasma, 594
cup, 649
decussation, 640
depressions, 648
nerve, 435
arachnoid of, 639
dural sheath of, 638
pial sheath, 638
relation to retina and brain, 639
subarachnoid space, 639
subdural space, 639
tract of, 505
technic of, 649
stalk, 648
Optic tract, 505, 592, 594, 595, 609
vesicle, 648, 649
Opticus (II nerve), 505, 535
Ora serrata, 631, 634
Oral glands, cells of, 226
crescents of Gianuzzi, 227
demilunes of Heidenhain, 227
mixed glands, 226
mucous glands, 226
serous glands, 226
technic of, 228
Orange G, 23
Organ an, 70, 153
of Corti, 659
acoustic neurones to, 505
cells of Claudius of, 660
Corti's arches, 660
tunnel, 660
Deiter's cells, 660
hair or auditory cells, 660
Hensen's cells, 660
lamina reticularis of, 660
Nuel's space of, 660
phalangeal processes, 660
pillar cells, 659
of Giraldès (paradidymis), 348
of hearing, 651; see also *Ear*
blood-vessels of, 661
cochlear nerve, 544
development of, 662
ear, external, 651
internal, 653
middle, 652
lymphatics, 661
nerves, 661
technic of, 663
of smell, 663
olfactory bulb, 664
mucosa, 663
tract, 665
technic of, 665
of taste, 666
cells of, 666
foliate papillæ, 666
gustatory canal, 666
intergeminal fibres of, 666
intrageminal fibres of, 666
taste buds, 231, 232, 444, 445, 667
technic of, 666
of vision, 627
blood-vessels of, 644
development of, 648

Organ of eyeball or bubus oculi, 627
eyelid, 646
lacrymal apparatus, 646
lens, 643
lymphatics of, 645
nerves of, 645
neurone systems of, 639
optic nerve, 515, 516, 522, 523, 533
technic of, 649
of Zuckerkandl, 418
Organs, the, 153
of Golgi, peripheral nerve terminations in, 447
Orth's fluid (formalin-Müller's), 7
Osmic acid as a fixative, 8
action on fat, 8
on myelin, 8
stain for fat, 31
Osseous labyrinth, 653
Ossicles of middle ear, 653
Ossification, 85, 205
centres, 203, 206
endochondral, 203, 205
intracartilaginous, 205
intramembranous, 203
subperichondrial, 207
subperiosteal, 207
Osteoblasts, 203, 240
Osteoclasts, 198, 204, 240
Osteogenetic tissue, 203
Otic ganglion, 451
vesicle, 662
Otocyst, 662
Otolithic membrane, 654
Otoliths, 654
Oval bundle of Flechsig, 496
Ovary, the, 358
blood-vessels of, 369
corpora lutea, of pregnancy, 366
spuria, 366
vera, 366
corpus albicans, 366
hæmorrhagicum, 364*a*
luteum, 364*a*
cortex of, 359
development of, 382
egg nest, 360
epoöphoron, 369
Fallopian tube, 359, 370
follicular cavity, 361
germinal epithelium of, 360
Ovary, Graafian follicles, 360
hæmatoidin crystals, 366
hilum of, 359
liquor folliculi, 361
lutein cells, 364*a*
lymphatics of, 369
medulla of, 359
nerves of, 369
oögenesis, 363
ovarian stroma, 359
oviduct, 359, 370
ovum, 358, 362
paroöphoron, 369
Pflüger's egg tubes or cords, 360
primitive Graafian follicle, 361
ova, 360, 384
rudimentary structures connected with, 369
secretion of, 358
structure of, 359
technic of, 371
tunica albuginea, 359
zona vasculosa, 359
Oviduct, the, 370; see *Fallopian tubes*
Ovula Nabothi, 374
Ovum, the, 54*a*, 59, 362
atresia of follicle, 369
deutoplasm granules, 363
development of, 362
fertilization of, 59, 350, 364
germinal spot, 363
maturation of, 59, 363, 364
oögenesis, 363
oögonia, 364
perivitelline space, 363
primitive, 360, 384
segmentation of, 61
yolk granules of, 363
zona pellucida of, 363
Owen, contour lines of, 237
Oxyhæmoglobin, 111
Oxyntic cells, 254
Oxyphile cells, 411

Pacchionian bodies, 434
Pacinian bodies, 202, 445, 453
corpuscles, 211, 356, 445
Palæo-cerebellum, 568
Palæëncephalon, 521
Palæothalamus, 586
Palate, mucous membrane of, 225
Palatine tonsils, 182; see *Tonsils*

Pallial arc, connections, 501, 559, 566, 568, 577, 579, 584, 591, 592, 595, 597, 602, 603, 605, 607, 609
Pallio-pontile fibres, 513, 577
Pallio-ponto-cerebellar path, 513
Pallio-rubro-spinal, 514
Pallio-thalamic fibres, 602, 605
Pallio-tectal fibres, 514
Pallium, 425, 519, 605, 609
  afferent connections of, 605
  association fibres of, 605
  corona radiata, 605
  corpus callosum, 605, 606
  development of, 520
  efferent connections of, 605
  fornix commissure, 605
  internal capsule, 606
  pallio-thalamic fibres, 605
  paths connecting with cerebellum and midbrain, 507
  peduncular fibres of, 605
  projection fibres of, 605
  retrolenticular portion of, 606
  sublenticular portion of, 606
Pancreas, the, 286
  blood-vessels of, 291
  cell-islands of Langerhans, 290
  centro-acinar cells of Langerhans, 289
  development of, 303
  duct of Santorini, 287
    of Wirsung, 287
  ductus choledochus, 303
  excretory ducts, 287
  intracellular secretory tubules of, 290
  lobules of, 286
  lymphatics of, 291
  nerves of, 291
  Opie, concerning cell-islands, 291
  secondary excretory duct of, 287
  secretion of, 288
  sustentacular cells of, 290
  technic of, 292
  terminal tubules of, 287
  zymogen granules of, 287
Paneth, cells of, 265, 278
Panniculus adiposus, 388
Papillæ, circumvallate, 230, 593
  compound, 387
  dental, 243
  filiform, 230
  foliate, 666
Papillæ, fungiform, 230, 593
  nerve, 387
  of hair, 396
  of mouth, 225
  of skin, 387
  pharynx, 247
  simple, 387
  vascular, 387
Paradidymis, or organ of Giraldès, 348, 383
Paraffin embedding, 16
  apparatus for, 17
  oven, 16
  section-cutting, 18
  sections, staining and mounting of, 26
  "ribbons" of, 18
Paraganglia, 415*d*
  carotid gland, 416
  chromaffin cells and organs, 416
  coccygeal gland, 417
  organ of Zuckerkandl, 418
  tympanic gland, 418
Paralinin, 49
Paramiton, 45
Paranuclein, 50
Paranucleus, 218
Paraplasm, 46
Parathyreoids, 410
  chief or clear cells of, 411
  development of, 412
  function of, 412
  oxyphile cells, 411
  Poolls theory of, 412
  technic of, 412
Pareleidin, 390
Parenchyma, 153
  of glands, 220, 282
Parietal cells, 254, 255
  peritoneum, 272, 440
  pleura, 314
Paroöphoron, 369
Parotid gland, 282
  development of, 303
  nerves of, 285
  Stenoni's duct of, 282
  technic of, 286
  tubules of, 282
Pars, buccalis, 414
  ciliaris retinæ, 565, 634, 638
  distalis, 415
  glandularis, 414
  intermedia, 413

Pars, iridica retinæ, 634, 638
juxta neuralis, 415*a*
neuralis, 414
optica retinæ, 534
papillaris, 387
reticularis, 386
tuberalis, 415*a*
Pavlow, concerning secretion, 278
Peduncle, cerebellar, inferior, 552, 558, 562, 567, 594
middle, 552, 558, 567
superior, 552, 559, 562, 566, 575, 577, 579, 581, 584
cerebral, 581
Pellicula, 48
Penicillus, 188
Penis, 355
arteries of, 356
cavernous sinuses, 356
corpora cavernosa of, 355
corpus spongiosum of, 355
erectile tissue, 355
glans, 357
glands of Tyson of, 357
lymphatics, 356
nerve endings of, 356, 446
prepuce of, 357
sebaceous glands of, 357
technic of, 358
tunica albuginea of, 355
Pepsinogen granules, 277
Peptic cells, 254, 272
glands, 254
Perforated space, anterior, 609
Perforating fibres, 197
of cornea, 556
of Sharpey, 197
Perforatorium, 350
Periaxial sheath, 138
Pericardial cavity, 169
Pericellular network, 142
Perichondrial ossification, 203
Perichondrium of bone, 205
of cartilage, 103
Perichorioidal lymph spaces, 630
Pericranium, 204
Peridental membrane, 239
Perifascicular sheath, 213, 436
Perifibrillar substance, 133
Perilymph, 653
Perimysium, 213
Perineurium, 436
Periosteal buds, 205
Periosteum, 196, 204, 205
Peripheral neurones, 428
afferent, 428, 437
efferent, 423, 426, 428, 456, 527
segmental, 521
Peripheral neurones, 428
afferent neurones, 427, 428, 437, 498
cerebro-spinal ganglia, 437
sympathetic ganglia, 448
efferent neurones, 423, 426, 428, 456, 527
motor neurone system, 456
nerve terminations, 441
annular, 447
diffuse, 442
end-bulbs, 445
free endings, 455
in penis, 356, 447
Golgi Mazzoni corpuscles, 448
Grandry, corpuscles, 443
in mucous membrane of mouth and conjunctiva, 445
in muscle-tendon junctions, 447
in skin, 400, 443
in smooth muscle, 442
in voluntary muscle, 446
Krause's end-bulbs in penis, 356
Meissner's corpuscles in papillæ of penis, 356, 444
muscle spindles, 446
muscle-tendon organs of Golgi, 447
nerve terminations, Ruffini's theory of, 446
neuromuscular bundles, 446
Pacinian bodies, 202, 211, 356, 445, 446, 453
corpuscles of penis, 356
peritrichial, 442
spiral terminations, 447
tactile cells, 444
corpuscles, 444
meniscus, 443
taste buds, 232, 444, 667
nerves, 427, 435
afferent part of, 435
cranial, 435
efferent part of, 435
endoneurium of, 436
epineurium of, 436
fascicles of, 436

Peripheral nerves, intrafas ciculareonnective tissue of, 436
medullated fibres of, 138, 436
motor or efferent, 435
motor nerve terminations, 455
non-medullated fibres of, 137
perifascicular sheath of, 436
perineurium of, 436
sensory or afferent, 435
sensory nerve terminations, 441
sheath of Henle, 436
spinal, 435
structure of, 435
technic of, 437
nervous system, 435
spinal nerves, 435
Peritoneal cavity, 169
Peritoneum, 272, 301
parietal, 272
subserous tissue of, 273
visceral, 272
Peritrichial nerve endings, 442
Perivitelline space, 363
Perpendicular fasciculus of Wernicke, 607
Pes lemniscus bundle, 579
Pes pedunculi, 425, 559, 567, 577, 579, 594, 595
Petit, canal of, 644
Petrosal ganglion of IX, 451, 505
Peyer's patches, 174, 265*b*
Pflüger's egg tubes or cords, 360
Phæochrome granules, 418
Phæochromoblasts, 421
Phagocytes, 53, 179
Phagocytosis, 53, 111, 112
Phalangeal processes, 660
Pharyngeal tonsils, 184; see *Tonsils*
Pharynx, the, 247
blood-vessels of, 248
lymph nodules, 184, 247
lymphatics of, 248
nerves of, 248
structure of, 247
technic of, 248
Phloroglucin, 10
Pia mater, 433
arachnoid, 434
blood-vessels of, 430
cerebralis, 428
cerebrospinal fluid, 434
Pacchionian bodies, 434
spinalis, 463
Pia mater, technic of, 434
Picric acid as a fixative, 9
as plasma dye, 23
Picro-acid-fuchsin, 24
Picro-carmine, 24
Pigment granules in cells, 46, 390
in connective tissue, 89
in epithelium, 73, 80
of hair, 394
in iris, 633
in nerve cells, 135
Pillar cells, 660
Pineal body (epiphysis cerebri), 415*c*
brain sand of, 415*c*
Pinna, 651
Pituitary body, 413; see *Hypophysis cerebri*
Placenta, 377
blood-vessels of, 381
canalized fibrin, 379
cell patches, 379
chorion frondosum, 377
chorionic villi, 377
cotyledons, 377
fastening villi, 377
fœtalis, 377
free or floating villi of, 377
lymphatics of, 381
membrana chorii of, 377
nerves of, 381
nuclear groups, 379
septa of, 380
subchorionic placental decidua, 380
syncytium of, 379
technic of, 385
uterina, 380
villi of, 380
Plasma cells, 89, 199
dyes, 22
acid aniline, 23
eosin, 22
neutral carmine, 23
picric acid, 23
Plasmosome, 50
Plastids, 46
Plastin, 44
Platelets, blood, 112
Pleura, parietal, 314
pulmonary, 314
Pleural cavity, 169
Pleuroperitoneal cleft, 169
Plexiform layer of Cajal, 612

Plexus annularis, 646
Auerbach's, 268, 276, 442
ciliary, 645
chorioideus, 523, 533, 542, 552, 559
Heller's, 274
Meissner's, 259, 268, 269, 276, 442
myentericus, 276
prevertebral, 451
Plicæ palmatæ, 374
Pneumogastricus (vagus nerve), 515, 516, 522, 523, 533, 535
Polar bodies, 60, 364*a*
globules, 62
rays, 55
Polykaryocytes, 198
Polymorphonuclear leucocytes, 109
Polynuclear leucocytes, 109
Polyphyletic theory of blood-cells, 113
Pons Varolii, 425, 522, 525, 552, 559, 574, 577
longitudinal fibres of, 558
perpendicular fibres, 558
pontile nuclei of, 558, 561
tegmentum, 526
pyramid of, 558
transverse fibres of, 558
Pool, E. H., concerning parathyreoïd gland, 412
Poroöphoron, 369
Portal canal, 295
vein, 294
Posterior column of Burdach, 458, 464, 479, 487
of Goll, 458, 464, 479, 487
columns of spinal cord, 458, 464, 479, 487
origin of fibres of, 458
commissure, 466, 594
corpus quadrigeminum, 579
funiculus, 458, 464, 479, 487
horns, 464
longitudinal fasciculus; see *Longitudinal fasciculus, medial*
median septum, 463
nerve root, 466
root fibres, 466
nucleus funiculi cuneati, 479, 487, 523, 531, 540
funiculi gracilis, 479, 487, 523, 531, 540
origin of 449
Posterior tract, or terminal zone of Lissauer, 458, 487
zone of Lissauer, 487
Potassium hydrate, as a macerating fluid, 5
Precapillary artery, 158
Predorsal fasciculus, 541, 562, 577, 579, 584
Preganglionic sympathetic cells, 459
Pregnant uterus, 376*a*
Preolivary nucleus, 557
Preparation of sections, 5
Prepuce, 357
Preserving, 14
Prevertebral plexuses, 451
Prickle cells, 389, 393
Principal sensory nucleus of nerve V, 564
Processus reticularis, 465
Projection fibres, 605, 617
Pronephric, duct, 383
Pronephroi, 382
Pronucleus, female, 60
male, 60
Prophase, 54*b*
Proprio-ceptors, 448, 509
Proprio-spinal tract of cord, 461, 497
Prosencephalon, 425, 586
Prostate gland, 353
blood-vessels of, 354
corpora amylacea of, 354
crescentic corpuscles of, 354
lymphatics of, 354
Müllerian duct, 354
nerves of, 354
senile, 354
technic of, 355
uterus masculinus, 354
utriculus prostaticus, 354
vesicula prostatica, 354
Protoneurones, 483
Protargol, for staining intercellular substance, 28
Prothrombin, 112
Protoplasm, 44, 46
streaming of, 54
theories of structure of, 45
Protoplasma superieur, 218
Protoplasmic movement, 54
Proprioceptive paths, 509
Protoplasmic processes, 130, 135
Proximal convoluted tubule, 326
Prussian blue gelatin as an injecting fluid, 11

Pseudo-chromosomes, 218
Pseudopodia, amœboid movement of, 53
Pseudo-reflex of Langley, 453
Pseudo-stratified epithelium, 75
Pulvinar radiations, 588
  thalami, 587, 594
Pulmonary artery, 319
  lobule, 314, 320
  pleura, 314
  system, 319
Pulp cavity, 232
  cord, 188
  splenic, 188
Purkinje cells, 568
Putamen, 601, 605, 609
Pyloric glands, 254, 257
Pylorus, 257
Pyramid, cortical, 326
  of Ferrein, 326
  Malpighian, 326
Pyramidal cells, 609
  decussation, 492, 523, 533
  tracts, 492, 493, 519, 527, 531, 532
Pyramids, 425, 523, 531, 542, 552, 559, 561, 575, 579
Pyrenin, 50
Pyriform lobe, 601
Pyrogallol for neurofibrils, 38

Racemose glands, 220
Radiations of Meynert, 615
Radix spinalis, V, 505
Rami communicantes, gray, 452
  white, 451
Ranvier's alcohol as a macerating fluid, 4
  nodes or constrictions of, 139, 140*c*
  showing muscle fibres, 119
Raphé, of semicircular canals, 655
  median, 534, 540, 563, 566
Receptors, 423, 427, 437, 441, 442, 479, 507
  diffuse endings, 442
  encapsulated, 442
  end-bulbs, 443
  extero-ceptors, 448
  intero-ceptors, 448
  non-encapsulated, 442
  of special senses, 509
  of voluntary muscle, 446
  Pacinian bodies, 445
  peritrichial endings, 442
  proprio-ceptors, 448
Receptors, Sherrington's classification of, 448
  somatic, 507
  tactile cells, 443
    corpuscles, 443
  visceral, 509
Rectum, 271
  anus, 272
  columnæ rectales, 272
  technic of, 280
Red blood cells, 107; see also *Blood*
    nucleated, 114, 188
    technic for study of, 63
  bone marrow, 199
  nucleus, see *Nucleus ruber*
Reduction of chromosomes, 59, 351, 364
Reflex arc, disynaptic, 499
  monosynaptic, 498
  three-neurone spinal, 499
  two-neurone spinal, 498
Reflexes, 431
Reich, granules of, 140*b*
Reissner, membrane of, 658
Remak, fibres of, 137
Renal artery, 324, 331
  corpuscle, 326
    development of, 383
  vein, 324
Renculus, 324
Replacing cells, 75, 257
Reproduction of cells, 54*a*
  direct, amitosis, 54*a*
  indirect, mitosis, 54*b*
Reproductive system, 339
  development of, 382
    rudimentary structures connected with the, 348, 369
  female organs, 358
    clitoris, 382
    Fallopian tube, 359, 370
    oögenesis, 363
    ovary, 358
    oviduct, 359, 370
    placenta, 377
    uterus, 372
    vagina, 381
    vestibule, 382
  male organs, 339
    Cowper's glands, 355
    ejaculatory ducts, 348
    epididymis, 336
    penis, 355

Reproductive male organs, prostate gland, 353
seminal ducts, 345
vesicle, 348
seminiferous tubule, 340
spermatogenesis, 350
spermatozoa, 343, 349
testis, 339
urethra, 357
vas deferens, 346
Respiratory cells, 318
epithelium, 317
system, 305
bronchi, 310
development of, 321
larynx, 307
lungs, 314
nares, 305
technic of, 310, 323
trachea, 307
Restiform body, 523, 540, 541, 458, 552
Rete testis, tubules of, 340, 345
vasa efferentia of, 345
Reticular fibres, 91, 99
formation, 506, 532, 541, 548, 558, 561, 567, 575
glands, 222
process, 454, 461
tissue, 97, 174, 178
Reticulin, 98
Retina, 634
blood-vessels of, 644
ellipsoid of Krause, 636
fibre-basket of, 638
fovea centralis, 636
ganglion in, 505
ganglionic layer of, 634
horizontal cells of, 637
inner limiting membrane of, 637
layer of nerve cells, 637
of nerve fibres, 637
of neuro-epithelium, 634, 635
of pigmented epithelium, 634
of rods and cones, 635
macula lutea, 638
molecular layer, 564, 636, 637
Müller's cells and fibres, 637
nuclear layer, 636
ora serrata, 634
outer limiting membrane, 637
molecular layer, 637
nuclear layer, 635
Retina, pars ciliaris retinæ, 634, 638
iridica retinæ, 634, 638
optica retinæ, 634
relation to optic nerve, 639
rod and cone cells of, 636
visual purple of, 636
Retinaculæ cutis, 388
Retraction hypothesis, 141
Retrolenticular portion of internal capsule (Cirl), 594
Retzius, lines of, 238
Rezzoines, apparatus of Golgi, 140c
Rhinencephalon, 425, 601
Rhinopallium, 601
Rhombencephalon, 425, 522
Ribboning paraffin sections, 18
Rod association neurones, 640
fibres, 636
neurones, 639
Rod-visual cells, 636
Rods, layer of rods and cones, 636
Rolando, gelatinous substance of, 466
Root canal, 232
cells, 447, 450, 457
Roots, afferent, 437
Rose concerning chromaffin cells, 416
Rubro-spinal tract, 494, 532, 541, 548, 561, 567, 575, 579
Ruffini, corpuscles of, 400, 440
theory of nerve terminations, 440
Rugæ, 251, 253, 382
Rühle, concerning the uriniferous tubule, 331

Saccular glands, 219
Saccule, and utricle, 654
auditory hairs of, 654
macula acustica, 654
neuro-epithelial cells of, 654
otolithic membrane of, 654
otoliths of, 654
sustentacular cells of, 654
Sachs, E., concerning thalamus, 588
Sacral segments of spinal cord, 458
Safranin, 22
Salivary corpuscles, 184
glands, 281
blood-vessels of, 285
development of, 303
general structure, 282
interstitial tissue, 282
lymphatics of, 285

Salivary glands, minute structure of, 226
nerves of, 285
parenchyma of, 282
parotid, the, 282
sublingual, the, 283
submaxillary, the, 284
technic of, 286
tubules, 282
Santorini, cartilage of, 307
duct of, 287
Sarcolemma, 118
Sarcoplasm, 119
Sarcostyles, 214
Sarcous elements of Bowman, 120
Satellite cells, 433
Scala media, 657
tympani, 657
vestibuli, 657
Scarpa's ganglion, 505, 512, 544
Schaffer's formalin-alcohol for fixation, 7
Schaper, concerning placenta, 377
Scharlack R method for staining fat, 31
Schlemm, canal of, 630
Schmidt-Lantermann, clefts of, 139
incisures of, 139.
segments of, 139
Schneiderian membrane, 305
Schreger, incremental lines of, 237
Schultze, comma tract of, 496
Schwalbe, lymph paths of, 645
Schwann, sheath of, 136, 139
Schweitzer, concerning lymph-vessels of teeth, 241
Sclera, the, 627
Scleratome, 127
Sebaceous glands, 357, 390, 397
development of, 402
of glans penis, 357, 390
of hair, 397
of labia minora, 390
of margin of lips, 390
of prepuce, 390
Sebum, 398
Secondary cochlear tract, 547, 557, 561, 566
dentine, 237
trigeminal tract, 527, 562, 587
vestibular tract, 553, 555, 557
Secretion, 46, 218, 262, 277
cells of, 217, 226, 277
Langley and Sewell concerning, 277
Theohara and Bensley concerning, 277
Secretory tubules, 219, 282
Golgi method of demonstrating, 29
of parietal cells of stomach, 256
growing points of, 256
Section cutting, 17
celloidin specimens, 17
frozen sections, 18
paraffin specimens, 18
preparation of, 5, 17
staining, 20, 23
Segmental brain, 429, 504
nerves, 429, 504
afferent peripheral (segmental) neurones, 504
acoustic group, 505
olfactory group, 505
somatic group, 504
splanchnic group, 505
vestibulo-semicircular canal group, 505
visual group, 505
afferent and efferent suprasegmental paths, 506, 507, 522
efferent peripheral (segmental) neurones, 506
somatic group, 506
splanchnic, 506
intrasegmental and intersegmental neurones, 506
Segmentation cavity, 62
of ovum, 61
Segments of Schmidt-Lantermann, 139
of spinal cord, 449, 461
Semen, 349
Semicircular canals, 481, 655
crista acustica of, 655
cupula of, 655
raphé of, 655
semilunar, fold of, 655
Semilunar fold, 655
ganglion of V, 480
nucleus, 557
Seminal ducts, 345
vas epididymis, 346
vas deferens, 346
vasa efferentia, 346
vesicles, 348
Seminiferous tubule, 340
cells of, 341
columns of Sertoli, 341
convoluted tubule of, 340
development of, 350

Seminiferous tubule, glandular cells of, 341
interstitial cells, 344
non-active, 344
rete testis, 340, 345
spermatids, 343
spermatocytes, 343
spermatogenic cells, 342
spermatogonia, 342
spermatozoa, 340, 343
straight tubule, 345
supporting cells of, 341
sustentacular cells of, 341
Sensation, cutaneous, 488, 489, 507
Senses, common, 507
general, 507
special, 509
Sensory decussation, 531
nerve endings, 441
nerve fibres, 423, 435
path, general, 504, 506, 507
peripheral nerves, 435
Septa renis, 326
Septo-marginal tract, 496
Septum linguæ, 229
Serial sections, 18
Serous cells, 226
glands, 226
membranes, 169, 252, 259, 268, 270, 271, 272, 301
tubules, 226
Sertoli, cells of, 341, 384
columns of, 341
Sewell and Langley concerning secretion, 277
Sex cells, 384
chromosomes, 350*b*
Sharpey, showing bone lamellæ, 196
Sharpey's fibres, 197, 238
Sheath of Henle, 140, 436
medullary, 137, 138
myelin, 137
Neumann's dental sheath, 237
of Schwann, 136, 139
perifascicular, 213, 436
Short fibre tracts, 461, 497
Signet-ring cell, 92
Silver nitrate method, Golgi, 36
of staining intercellular substance, 28
Sinusoidal circulation of liver, 304
Skein, closed, 55
Skeletal system, 193
articulations, 209
Skeletal bone-marrow, 197
bones, 193
cartilages, 209
Skilled reactions, 431
Skin (*cutis*) and its appendages, 386
blood-vessels of, 405
color of, 390
corium, 386
corpuscles of Grandry, 443
of Meissner, 400, 444
of Merkel, 443
of Ruffini, 400, 448
of Wagner, 400
cuticle, 388
derma, 386
development of, 401
eleidin of, 389
end-bulbs in, 443
epidermis of, 388
glands of, 390
glandulæ sudoriparæ, 390
Golgi-Mazzoni corpuscles of, 400, 448
hair follicles of, 393
junction of, with mucous membrane of mouth, 225, 390
keratohyalin granules, 389, 393
Krause's end-bulbs, 400
lymphatics of, 400
mammary gland, 402
mitosis of cells of, 389
nails, 391
nerves of, 400, 436
of nipple, 387
of scrotum, 387
Pacinian bodies of, 202, 445, 453
panniculus adiposus of, 388
papillæ of, 387
pareleidin, 390
pars papillaris, 387
pars reticularis, 386
peripheral nerve terminations in, 400 430
prickle cells of, 389, 393
retinaculæ cutis, 388
sebaceous glands of, 390, 397
smooth muscle of, 387
subcutaneous tissue of, 387
sweat glands (glandulæ suboriparæ), 390
pores of, 390
tactile cells of, 443
corpuscles, 444

Skin, technic of, 390, 393, 399
for blood-vessels of, 401
Vater-Pacinian corpuscles of, 400
Small intestines, 260
absorption of fat, 279
agminated follicles, 265
Auerbach's plexus, 268
blood-vessels of, 273
Brunner's glands of, 267, 278
cells of, 261
acidophile, 265
chromaffin, 265
columnar, 261
connective tissue, 264
fat in, 31
goblet, 262
lymphoid, 265
mucous, 262
of Paneth, 265, 278
replacing, 264
secreting, 262, 264, 278
smooth muscle, 264
wandering, 264
chyle capillaries of, 275
coats of, 261, 267, 268
crypts of Lieberkühn, 265
Davidoff, concerning cells of stomach, 264
development of, 303
epithelium of, 261
lacteals of, 280
lymphatics, 275
Meissner's plexus, 268
migratory leucocytes, 264
muscle of, 267
nerves of, 276
Paneth's cells, 265, 278
Peyer's patches of, 174, 265*b*
plexus myentericus, 276
secretion, 278
solitary follicles, 265
technic of, 82, 280
valvulæ conniventes of, 251, 260
villi of, 260, 261
Smell, organ of, 657
Smooth muscle, 115; see *Involuntary muscle*
Sodium hydrate as a macerating fluid, 5
Solitary fasciculus, 538, 558
follicles, 259, 265
Somatic nervous system, 423
neural reaction, 424, 430
Somatic nervous system, 423
receptors, 503, 507, 508
(peripheral) neurones, 429, 504
Somatico-splanchnic reactions, 424
Somatochromes, 133
Spaces of Fontana, 633
Special dental germs, 243
senses, 442
Spermatids, 343
Spermatoblast, 351
Spermatocytes, 343, 350
Spermatogenesis, 350
technic of, 352
Spermatogonia, 342
Spermatozoa, 60, 340, 343, 349
acrosome, 350
anterior end-knob, 350
apical body, 350
axial thread, 350
development of, 59, 350
growth, 350*a*
maturation, 350*a*
proliferation, 350*a*
transformation, 351
diagram of, 349
end ring or end disc, 350
galea capitis, 350
maturation of, 59
motility of, 350
perforatorium, 350
posterior end-knob, 350
structure of, 59, 349
technic of, 352
Sphenopalatine ganglion, 451
Sphincter pylori, 259
of liver, 301
Spider cells, 147
Spinal acessory nerve, see *Nerves, cranial*
Spinal cord, 425, 457
anterior columns of, 465
funiculus, 465
horns of, 464
marginal bundle of Löwenthal, 495
median fissure, 463
pyramids, 493
white commissure of, 466
antero-lateral columns of, 464
funiculus, 464
white column, 464
arachnoid membrane of, 434
arrangement of fibres of, 474
arteries of, 477

Spinal cord, ascending tracts of, 485
axonal method of determining fibres tracts, 479
blood-vessels of, 477
caput, 466
cell column, 470
cell-groupings of, 470
cells of dorsal horn, 470
of Golgi, Type II., 461, 472
of the intermediate gray matter, 458
of ventral horn, 470
outside cord, with axones to white matter of cord, 458, 459
central canal of, 424, 465
gelatinous substance, 466
cervical enlargement of, 457, 479
segments of, 458
cervix, 466
Clarke's column of, 479, 491, 492
coccygeal segments of, 458
collaterals of, 463
column of Burdach, 479, 487, 523, 527
of Goll, 479, 487, 523, 527
cells, 460
hecateromeric, 461
heteromeric (heterolateral), 460
tautomeric (ipsilateral or homolateral), 460
conduction paths of, 429, 483
cornua of, 464
descending paths from higher centres, 492
diagram showing tracts of, 486
direct ascending paths to higher centres, 485
cerebellar tracts, 490
pyramidal tract, 492, 483
dorsal funiculus, 464
gray columns, 464
commissure, 466, 585, 594
median septum, 463
nerve roots, 466
spino-cerebellar tract, 490
white columns, 464
commissure, 466
dorso-lateral grooves, 463
dural mater of, 432
efferent peripheral neurones, 470
ependyma of, 467
Spinal cord, fasciculus cuneatus, 479
gracilis, 479, 487
medial longitudinal, 495; see *Fasciculus medial longitudinal*
of Thomas, 496
fibre tracts of, 479
methods of determining, 142, 479, 628
filum terminale of, 457
Flechsig's tract, 490
fundamental columns of, 461, 497
ganglion cells of, 458
gelatinous substance of Rolando, 466
general topography of, 463
Gowers' tract, 492
gray matter of, 428, 458, 463, 465
ground bundles of, 461, 497
Helweg's tract, 496
intermediate gray matter, 466
lateral funiculus (white column), 465
lateral horn of, 465
lateral spino-thalamic tract, 488
ligamentum denticulatum, 464
long ascending arms of dorsal root fibres, 485
long ascending fibre tracts, 461
longitudinal section of six days' chick embryo, 463
lumbar enlargement of, 457
segments of, 458
main motor fibre systems of, 492
marginal bundle of Löwenthal, 495
medial fillet (lemniscus); see *Lemniscus medial*
membranes of, 432
arachnoid, 432
blood-vessels of, 434
dura mater, 432
pia mater, 433
spinal dura, 432
technic of, 434
mixed spinal nerve, 435
motor cells of anterior horn, 459
multipolar ganglion cells of, 131, 454, 458
myelogenetic method of determining fibres, 622
neural arcs involving the, 498
neuroglia cells, 467
fibres, 467
neurone systems of, 429
nuclei sympathici, 471

Spinal cord, nucleus, Darkschewitsch's, 494
origin of fibres of white matter, 458
of posterior columns of, 458
oval bundle of Flechsig, 496
peripheral motor or efferent neurone system, 426, 456
sensory or afferent neurone system, 427, 437
pia mater, spinalis, 433, 463
posterior columns, 458, 464
white, 464
funiculus, 458, 464
horns, 464
median septum, 463
nerve roots, 466
root fibres, 466
postero-lateral grooves, 463
sulci, 463
preganglionic sympathetic cells, 459
preganglionic sympathetic neurones, 471
processus reticularis, 465
pyramidal decussation, 492
tracts, 492, 493
reflex arcs, 498
relation to spinal ganglion, 458
reticular process, 465, 479
root cells, 458, 470
rubro-spinal tract, 494
sacral segments of, 458
schematic section, 464
scheme of neurone relations of, 486
section through cervical enlargement of, 479
through lumbar enlargement, 463
through mid thoracic region, 479
through six-day chick embryo, 462
through twelfth thoracic segment, 479
segments of, 458
septo-marginal tract, 496
shape of, 457
short fibre systems of, 461, 497
shorter intersegmental tracts, 497
size of, 457
spino-cerebellar tract, 489, 490
spino-olivary fibres, 496
spino tectal tract, 489, 497
thalamic tract, 489, 490
sulci, 463
technic of, 461
Spinal cord, thoracic segments of, 458
tract from interstitial nucleus of Cajal, 494
from Dieter's nucleus, 495
tracts of, 479; see *Tracts*
variations in structure at different levels, 478
veins of, 477
ventral gray columns, 464
commissure, 466
white, 466
funiculus (anterior white column), 465
median fissure, 463
nerve roots, 466
root cells, 459
white columns, 459, 465
white commissure, 466
matter, 428, 457, 464
mesodermal elements of, 469
nervous elements of, 466
neuroglia of, 467
zona spongiosa, 466
terminalis, 466
zone of Lissauer, 458, 464
Spinal ganglia, 130, 427, 437
amphicytes, 438
development of, 427
technic of, 455, 461
ganglion cells, 437, 458
capsules of, 437
classification of, 438, 439
collaterals from, 440
development of, 427
Dogiel's classification, 440
ectodermic origin, 422
modes of termination of peripheral processes of, 441
peripheral processes of, 439
Ruffini's classification of terminations in muscle spindles, 447
structure of, 437
technic of, 455, 461
types of cells, 438, 439
nerves, 435
reflex arcs, 498, 499
Spindle, achromatic, 54*b*
Spino-cerebellar tract, dorsal, 490, 511, 529
ventral, 490, 511, 529
Spino-collicular tract, 489, 511
Spino-spinal tract, 497

Spino-tectal tract, 489, 494, 497, 511
Spino-thalamic tract, 489, 540, 561, 566, 577, 587, 595
Spiral filament, 352
ganglion, 505, 544
lamina, 657
ligament, 657
limbus, 588
organ, 659
prominence, 659
sulcus, external, 622, 659
terminations, 447
Spireme, closed, 55
open, 55
Spireme-thread, 56
Splanchnic effectors, 503
nervous system, 423
neutral reaction, 424
(peripheral) neurones, 428, 505
Splanchno-somatic reaction, 424
Spleen, 185
ampullæ, 188
arteries of, 188
blood-vessels, 187
cavernous veins, 188
cells of, 188
central arteries of, 188
connective-tissue framework, 186
cords of, 188
corpuscles of, 186
development of, 189, 190
function of, 190
germinal centres of, 187
lymphatics of, 191
Malpighian bodies, 186
Mollier, concerning splenic pulp, 189
nerves of, 191
penicillus, 188
pulp of, 186, 188
cords of, 188
spindles of, 187
technic of, 191
Spleen-sinus, 188
Splenic corpuscles, 186
pulp, 188
Spleno-lymph nodes, 178
Spongioblasts, 147, 426
of His, 426
Spongioplasm, 44
Spongy bone (cancellous), 193
development of, 202
Staining, 20
differential, 4
double with hæmatoxylin-eosin, 23
in bulk, 24
methods, special, 28
Benda's method for mitochondria 32
chlorid of gold, 28
Golgi's chrome silver for secretory tubules, 29
Jenner's, for blood, 32
Mallory's aniline blue for connective tissue, 30
phosphomolybdic acid hæmatoxylin stain for connective tissue, 29
phosphotungstic acid hæmatoxylin stain for connective tissue, 30
Maresh's modification of Bielschowsky's stain for fine connective-tissue fibrils, 31
Meve's method for mitochondria, 32
osmic acid, for fat, 31
silver nitrate, for intercellular substance, 28
Scharlack R, for fat, 31
Sudan III, for fat, 31
Verhoeff's differential stain for elastic tissue, 28
Weigert's elastic-tissue stain, 28
nuclear dyes for, 20
paraffin sections, 26
plasma dyes for, 22
Regaud's method for mitochondria, 32
sections, 23
double with hæmatoxylin-eosin, 23
triple with hæmatoxylin-picro-acid-fuchsin, 24
with picro-acid-fuchsin, 24
with picro-carmine, 24
selective, 4
special neurological methods, 33
Cajal's methods for neurofibrils in nerve cells, 38
Cox-golgi method, 37
Golgi bichlorid method, 37
Golgi silver methods, 36
Marchi's, for degenerating nerves, 35

Staining, Nissl's method, 39
Weigert's, for medullated nerve fibres, 33
Weigert-Pal method, 34
Stains, nuclear dyes, 20
plasma dyes, 23
Stalked hydatid, 348
Stapes, 653
Stellate cells, 233, 570, 611
veins of Verheyn, 334
Stenoni, duct of, 282
Stöhr, concerning muscle fibres, 123, 214
concerning thymus, 182
concerning arteries of mucosa of stomach, 274
Stomach, 252
absorption of, 277
acid cells of, 255, 277
adelomorphous cells of, 254
Auerbach's plexus, 276
blood-vessels of, 273
cardiac glands of, 257
chief cells of, 254, 277
delomorphous cells of, 254
development of, 302
epithelium of, 253
fundus glands of, 254
gastric glands of, 253, 254
pits of, 253
Heller's plexus, 274
lymphatics of, 275
Meissner's plexus, 276
mucous membrane of, 253
muscular coat of, 259
nerves of, 276
oxyntic cells, 254
parietal cells of, 255
peptic cells of, 254, 277
glands of, 254
plexus myentericus, 276
pyloric glands of, 257
replacing cells, 257
rugæ of, 251, 253
secretion of, 277
secretory tubules, 256
solitary follicles of, 259
stroma of, 258
submucosa, 259
technic of, 259
tubules of, 256
tunica propria of, 258
Stomata, 170
Straight tubules of testis, 245
Stratum cinereum, 585
corneum, 223, 389
cylindricum, 388
fibrosum, 210
germinativum, 388
granulosum, 223, 361, 389
griseum superficiale, 585
lemnisci, 585
lucidum, 389
Malpighii, 388
mucosum, 388
opticum, 585
spinosum, 389
submucosum, 372
supravasculare, 372
synoviale, 210
vasculare, 372
zonale, 585
Streaming of protoplasm, 4
Stria cornea, 597
medullaris, 597
of Baillarger, 547
semicircularis, 597
terminalis, 597
vascularis, 658
Striæ thalami, 603
Striated voluntary muscle, 125
Stroma, 223
Styloglossal fibres, 229
Subarachnoid space, 434
Subchorionic placental decidua, 380
Subcutaneous tissue, 387
Subdural space, 433
Sublingual gland, 283
crescents of Gianuzzi of, 283
development of, 303
duct of Bartholin of, 283
ganglion, 451
nerves of, 285
technic of, 286
Sublingualis minor, 284
Submaxillary ganglion, 451
gland, 284
development of, 303
duct of Wharton of, 284
nerves of, 285
technic of, 286
Submucosa, 223
Subperichondrial ossification, 207
Subperiosteal ossification, 207
Subserous tissue, 273

Substantia alba, see *White matter*, 428, 466
grisea, see *Gray matter*, 428, 466
nigra, 135, 581, 584, 594
propria corneæ, 629
Subthalamus, 586
corpus subthalamicum of Luys, 586
Sudan III and Scharlack R method for staining fat, 31
Sudoriferous glands, 390
Sulcus, external spiral, 658
Sulcus limitans, 523
Superficial sensation, 488, 489, 507
Superior cerebellar peduncles, see *Peduncles, superior cerebellar*
colliculus, 425, 506, 519
ganglion of IX, 552
longitudinal fasciculus, 607
olive, 551, 557, 561, 607
Suprachorioidea, 630
Supraradiary plexus, 615
Suprasegmental arc, 430
brain, 504
cerebral hemispheres, 519
connections (afferent and efferent), 506
development of, 520
corpora quadrigemina, 428, 519
intersegmental nuclei and tracts of segmental brain, 522
intrasegmental nuclei and tracts of segmental brain, 522
nuclei and tracts forming suprasegmental paths, 507, 522
pallium, 429, 519
paths, 506, 507, 512
afferent, 507
efferent, 512
general considerations concerning, 517
of medulla, 527, 529
peripheral (segmental) neurones, 506
physiology of, 507
structures, 519, 522
cerebellum, 519
corpora quadrigemina, 519
pallium, 519
terminal nuclei, 522
neurones, 429
afferent, 429
associative, 429, 504
efferent, 429
Suspensory ligament, 644
Sustentacular cells, 290, 306, 341
Sweat glands, 390
development of, 402
ducts of, 390
muscle tissue of, 402
pore, 390
Sympathetic ganglia, 427, 448
afferent fibres, 453
cells of, 454
chain ganglia, 451
development of, 427
free endings of, 455
in Auerbach's plexus, 452
in Meissner's plexus, 452
pigmentation of cells of, 454
preganglionic cells, 459
prevertebral plexuses, 451
structure of, 454
technic of, 455
termination of nerves, 451, 455
typical sympathetic nerve cell, 454
vertebral ganglia, 451
nervous system, 422, 424, 448
diagram of, 450
nuclei sympathici, 471
preganglionic neurones, 448, 471
sympathetic ganglia, 448
organ of Zuckerkandl, 415*d*
Sympathoblasts, 421
Synapsis of neurones, 141
of chromosomes, 350*a*
Synarthrosis, 209
Synchondrosis, 209
Syncytial cells, 425
Syncytium, 70, 140
of placental villi, 379
Syndesmosis, 209
Synovial membrane, 210
villi, 210
System, a, 70
Szymonowizc, showing intercellular bridges, 77
showing medullated nerve fibre, 140

TACTILE cells, 443
compound, 444
simple, 443
corpuscles, 228, 444
of Meissner, 400, 444
of Wagner, 400
meniscus, 443

Tænia thalami, 597, 599, 600
Tapetum cellulosum, 630
fibrosum, 630
Tarsal glands, 647
Tarus, 647
Taste buds, 231, 232, 307, 310, 444, 509, 666
organ of, 666; see *Organ of Taste*
receptors, 509
Tautomeres, 490
Teasing, 4
Technic, general, 3
Tecto-spinal Tract, see *Tract, tectospinal*
Teeth, 232
apical foramina, 233
blood-vessels of, 240
cementum of, 232, 238
contour lines of Owen, 237
crown of, 232
cuticula dentis, 238
dental germ, 243
groove, 243
papilla, 242, 243
periosteum, 239
pulp, 233
dental sac, 244
shelf, 243
dentinal canals, 235, 246
fibres, 233, 235, 246
dentine of, 232, 233
development of, 243
common dental germ, 243
cuticular membrane, 245
dental papilla, 243
dental shelf, 243
enamel organ, 244
prisms, 245
membrana preformativa, 246
special dental germ, 243
technic of, 247
Tomes' process, 245
enamel of, 232, 238
cells, 242
cuticuladentis, 238
fibres, 238
organ, 244
prisms, 238, 245
fang of, 232
incremental lines of Schreger, 237
interglobular spaces, 237, 246
layer of Weil, 233
lines of Retzius, 238
Teeth, lines of Schreger, 237
lymphatics of, 241
milk, 240, 244, 245, 246
neck of, 232
nerves of, 241, 436
Neumann's dental sheath, 237
odontoblasts of, 233, 246
peridental membrane, 239
permanent, 244, 247
pulp cavity, 232, 246
root of, 232
root-canal of, 232
special dental germs, 243
technic of, 247
Tomes' granular layer, 237
process, 245
true molars, 247
wisdom, 247
Tegmental tract, central, see *Tract, central tegmental*
Tegmentum, 425, 523, 552, 574, 581
Tela chorioidea, 425, 523
Telencephalon, 425, 600
Telophragma, 121
Telophase, 57
Tendon, structure of, 94, 213
sheaths, 213
Tendon-muscle junction, 214
organs of Golgi in, 448
peripheral-nerve terminations in, 447
Tenon, capsule of, 645
Tensor chorioideæ, 633
Terminal arborizations, 136, 442, 447
bronchus, 316
ganglia, 451
nuclei, and secondary tracts, 522
nucleus, 429, 522
Terminations, nerve, 441
annular, 447
arborescent, 447
peritrichial, 442
Ruffini's theory of, 446
spiral, 447
Testis, 339
blood-vessels of, 348
convoluted tubules of, 340
corpus Highmori, 339
development of, 382
ducts of, 340, 345, 348
ejaculatory, 347
epididymis of, 346
lymphatics of, 348

Testis, mediastinum, 339
nerves, 349
rete, 345
secretion of, 349
semen, 349
seminal ducts of, 345
vesicles, 348
seminiferous tubules of, 340
spermatozoa, 343, 349
technic of, 352
tubules of non-active, 344
tunica albuginea of, 339
vaginalis, 339
vasculosa, 339
vas deferens, 346
Tetrad, 350*b*
Thalamencephalon, 586
Thalamic radiations, 587, 597
Thalamo-cortical neurones, 587
Thalamus, 425, 586, 594, 597
anterior corona radiata, 587
arcuate nucleus, 587
bundle of Vicq d'Azyr, 597
corpus subthalamicum of Luys, 586
cortical connections, 587
epithalamic structures, 597
external segment of, 587
geniculate bodies, 587, 594
internal, segment of, 586
Luys, median center of, 587, 597
mamillo-thalamic tract, 586
medial, 586
metathalamus, 587
neothalamus, 586
nuclei of, 587
classification of, 588
palæothalamus, 586
physiology of, 589
pulvinar, 587, 594
subthalamus, 586, 597
tænia, 597, 599, 600
thalamic paths, 581, 597
radiations, 587, 594, 597, 609
Theca folliculi, 362
Theoharra and Bensley concerning secretion, 277
Thermostat, 16
Thermotaxis, 52
Thionin, 22
Third ventricle, 425
Thomas, fasciculus of, 496
Thoracic duct, 169
Three-neurone afferent suprasegmental conduction path, 430
spinal reflex arc, 499
Thrombin, 112
Thrombocytes, 112
Thurlow, concerning mitochondria, 47*a*
Thymus, 179
blood-vessels of, 181
development of, 181
Hassall's corpuscles, 181
lymphatics of, 181
medullary cords, 181
nerves of, 181
technic, 182
Thyreoid, 408
absence of, 409
blood-vessels of, 409
cartilage, 307
cells of, 409
colloid of, 408
development of, 409
isthmus of, 408
lymphatics of, 409
nerves of, 409
Tilney, concerning epiphysis cerebri, 415*d*
concerning hypophesis cerebri, 413
Timofeew, concerning nerve fibres in prostate gland, 354
Tissue, 70
-elements, dissocation of, 4
Tissues, 71
adipose, 92
aponeurotic, 96
areolar, 91
blood, 71, 107
bone, 104
cartilage, 102
classification of, 71
connective, 84, 86
derivatives from ectoderm, entoderm, mesoderm, 69, 70
dissociation of, 4
elastic, 96
embryonal connective, 86, 202
endothelium, 80
endomysium, 213
epithelial, 71, 72
erectile, 355, 382
examination of fresh, 4
fibro-elastic, 317
glandular, 220
histogenesis of, 69

Tissues, interstitial, 153, 220
intrafascicular connective, 215
lymphatic, 171
lymphoid, 174
meosthelium, 80
muscle, 71, 115, 213
nerve, 71, 130
osteogenetic, 203
reticular, 98, 174
subcutaneous, 388
subserous, 273
Toluidin blue, 22
Toluol, as solvent, 16
Tomes' granular layer, 237
process, 245
Tongue, 228
blood-vessels of, 231
circumvallate papillæ, 230
connective tissue of, 229
Ebner's glands, 231
end-bulbs of Krause, 232, 445
fibres of, 229
filiform papillæ, 230
fungiform papillæ, 230
glands of, 227, 231
longitudinal fibres of, 229
lymph follicles of, 184, 231
spaces of, 232
mucous membrane of, 229
muscles of, 228
nerves of, 232
papillæ of, 229
septum linguæ, 229
taste buds, 231, 232, 444, 509, 666
technic of, 232
transverse fibres of, 229
vertical fibres of, 229
Tonsils, 182
blood-vessels of, 184
crypts of, 183
development of, 184
germ centre of, 183
lingual; folliculæ linguales, 184
foramen cæcum linguæ of, 184
lymphatics of, 184
lymphoid infiltration of epithelium, 183, 311
nerves of, 184
nodule of, 183
palatine or true, 182
pharyngeal, 184
adenoids of, 184
Tonsils, salivary corpuscles of, 184
technic of, 185
Tonus, 430
Trachea, 307
blood-vessels of, 309
cartilages of, 308
crescents of Gianuzzi, 308
glands of, 308
lymphatics of, 310
nerves of, 310
technic of, 310
Tract, a, 429
afferent cerebellar, 511
mesencephalic, 511
pallial, 507; see *Afferent pallial paths*
suprasegmental, 507
antero-lateral ascending-ventral spino-cerebellar, 491
antero-lateral descending, 495
auditory, 544, 594
Burdach's, 479, 487
central tegmental, 541, 557, 558, 566, 575, 579, 594
cerebro-spinalis, 492
cochlear, 544, 551, 557
colliculo-spinal, 494, 511, 531, 532, 541, 552, 559, 566, 577, 579
comma, of Schultze, 496
cornu-commissural, 497
cortico-spinalis, 492
crossed or lateral, pyramidal, 490, 492, 531
Deitero-spinal tract, 495, 541, 544
descending from pallium to motor nuclei, 497
direct cerebellar, 490
pyramidal, 492, 519
dorsal spino-cerebellar, 479, 490, 493, 511, 529, 540, 558
white columns, 485
efferent cerebellar, 516
mesencephalic, 516
pallial, 512; see *efferent pallial paths*
suprasegmental, 512
fasciculus of Thomas, 496
fastigio-bulbar, 557, 561
Flechsig's, 490; see *Dorsal-spino-cerebellar*
from interstitial nucleus of Cajal, 494, 529, 541, 548, 558,

Tract, from nucleus of posterior longitudinal fasciculus, 494, 495
from vestibular nuclei, 495
fundamental or ground bundles, 461, 497
general sensory, 594
Goll's, 479, 487
Gower's, 492
Helweg's, 496, 512, 514
internuncial, 497
intersegmental (shorter), 496, 497
lateral spino-thalamic, 488
Lissauer's, 458, 464
long ascending arms of dorsal root fibres, 485
mamillo-thalamic, 587, 597
marginal bundle of Löwenthal, 495
medial lemniscus, 510, 513, 531, 532, 544, 547, 548, 558, 561, 566, 575, 579, 583, 594
longitudinal fasciculus, 494, 495, 516, 529, 532, 541, 548, 549, 558, 561, 566, 575, 577, 579, 584, 594
olfactory, 506
olivo-cerebellar, 512
optic, 592, 594, 595, 699
oval bundle of Flechsig, 496
pallio-spinalis, 492
posterior columns, 487
funiculi, 479
posterior longitudinal fasciculus, 494
predorsal, 541, 585
fasciculus, 562
proprioceptive, general body, 512
special, 512
proprio-spinal, 497
pyramidal, 492, 519, 531, 532, 542, 552, 559, 562, 566, 575, 579
anterior, 493
reunions of Fuse, 540
rubro-spinal, 494, 541, 548, 561, 567, 575, 579
secondary cochlear, 547, 557, 561, 556, 566, 583
trigeminal, 527, 562, 587
vago-glossopharyngeal and trigeminal, 533, 566, 575
vestibular, 557
septo-marginal, 496
short fibre, 461, 497, 529
spinalis trigemini, 527
Tract, spino-cerebellar, ventral, 491, 511, 529, 532, 540, 561, 566, 575
-colliculo, 489, 511
-spinal, 497
-tectal, 489, 494, 497, 579
-thalamic, 488, 489, 540, 561, 566, 577, 587, 595
tecto-spinal, 489, 494, 497, 585
uncrossed cerebellar, 490
ventral spino-cerebellar, 491, 561, 566, 575
-spino-thalamic, 489
vestibulo-spinal, 495, 496, 532, 541
voluntary motor, 512
Von Monakow's, 494
Transitional leucocytes, 109
Transverse temporal gyri of Heschl, 617
Trapezius, 547
Trapezoid nucleus, 544, 547, 557, 566
Triangle of Philippe and Gombault, 496
Trigeminus (V nerve), 562; see *Nerves cranial*
Trigonum hypoglossi, 523
olfactorium, 601
vagi, 523
Triple staining, 24
Trochlearis (IV nerve), see *Nerves, cranial*
Trophic centre of neurone, 141
influence of neurone on muscle, 457
Trophospongium, 47
True corpora lutea, 366
molars, 247
tonsils, 182
vocal cords, 301
Tuber cinereum, 413, 597
Tuberculum cinereum, 523, 601
olfactorium, 601
Rolandoi, 523
trigemini, 523
Tubular glands, 219, 221, 324
Tubules, arched, 329
collecting, 330
convoluted, 328, 340
distal, 329
first or proximal, 328
intercalated, 282
intercellular secretory, 256
intermediate, 282, 284
intracellular secretory, 256
junctional, 377
mucous, 227
non-active, 344

Tubules, salivary, 282
second or distal, 329
secreting, 282
seminiferous, 340
serous, 226
straight, 330, 340
terminal, 283
uriniferous, 326
Tubulo-alveolar gland, 219, 287
Tunica albuginea, of ovary, 359
of penis, 355
of testis, 339
dartos, 387
fibrosa, 362
propria, 223
vaginalis, 339
vasculosa, 339, 348, 362
Two-neurone spinal reflex arc, 498
Tympanic gland, 418
membrane, 652
Tympanum, 652; see also *Ear, middle*
Tyson, glands of, 630

Ultimate fibrillæ, 119
Uncinate fasciculus, 607
Unipolar nerve cells, 131, 141, 433
Ureter, 335
development of, 382
technic of, 338
Urethra, female, 357
glands of Littré of, 358
male, 357
fossa navicularis, 358
glands of Littré of, 358
technic of, 358
Urinary bladder, 336
development of, 382
system, 324
development of, 382
kidney, 324
-pelvis, 335
technic of, 338
ureter, 335
urinary bladder, 336
Urine, 331
Uriniferous tubules, 326
arched tubule of, 327
ascending arm of Henle's loop, 320, 329
blood-vessels of, 331
Bowman's capsule, 326, 328
cortical labyrinth, 330
Uriniferous tubules, descending arm of Henle's loop, 326, 328
development of, 383
duct of Bellini, 327, 330
epithelium of, 331
first or proximal convoluted, 326, 328
foramina papillaria, 327
glomerulus, 326
Henle's loop, 326, 329
Malpighian body, 326, 327
membrana propria of, 327
neck of, 328
nerves of, 334
renal corpuscle, 326
Rühle, concerning epithelium of, 331
second or distal convoluted, 326, 329
straight or collecting, 327, 330
Utericulo-saccular duct, 654
Uterus, 372
blood-vessels of, 381
cervix, 372
decidua basalis, 376*a*
capsularis, 376*a*
graviditatus, 376*a*
menstrualis, 376
reflexa, 376*a*
serotina, 376*a*
Uterus, decidua subchorionic placental, 380
vera, 376*a*
decidual cells of, 376*a*
lymphatics of, 381
mucosa of menstruating, 375
of pregnant, 376*a*
of resting, 373
nerves of, 381
placenta, 377
plicæ palmatæ, 374
pregnant, 376*a*
stage of menstruation proper, 376
of preparation, 376
of reparation, 376*a*
stratum submucosum, 372
supravasculare, 372
vasculare, 372
technic of, 385
with placenta *in situ*, technic of, 385
Uterus-masculinus, 354
Utricle, 654; see *Saccule and utricle*
Utriculus prostaticus, 354
Uvula, mucous membrane of, 225

VAGINA, 381
blood-vessels of, 382
clitoris, 382
glands of Bartholin, 382
nerves of, 382
rugæ of, 382
technic of, 382
Vagus (X) nerve, 167
Valve, Heisterian, 301
Valves of heart, 166
of veins, 162
Valvulæ conniventes, 251, 260
Van Gehuchten's fluid, 9
Van Gieson's picric-acid-fuchsin stain, 24
Vas deferens, 346
technic of, 352
epididymis, 346
Vasa efferentia, 346
vasorum, 163
Vascular papillæ, 387
system, 155; see also *Circulatory system*
Vater-Pacinian corpuscles, 400
Veins, 162
adventitia of, 162
anterior median, 460
arcuate, 334
cavernous, 188, 358
central, 294
coats of, 162
development of, 167
intima of, 162
lymph channels of, 163
media of, 162
musculature of, 163
nerves of, 163
perivascular lymph spaces of, 163
portal, 295
posterior median, 460
renal, 324
splenic, 187
stellate, of Verheyn, 334
sublobular, 294
technic of, 164
valves of, 162
vasa vasorum, 163
venæ vorticosæ, 630
Velum, medullary, 523, 574
Vena cava, 302
Venæ vorticosæ, 630
Ventral horns, 464, 470
Ventricles of brain, 425, 533, 542, 552, 559
of heart, 165
Verheyn, stellate veins of, 334
Verhoeff's differential elastic-tissue stain, 28
Velum, superior medullary, 523, 574
Vermiform appendix, 270
lymph nodules of, 271
mesoappendix, 270
technic of, 280
Vermis of cerebellum, 567, 568
Vertebral ganglia, 451
Vesicle, air, 316
brain, 425
germinal, 59
optic, 648
otic, 666
seminal, 348
Vesicula prostatica, 354
Vestibular ganglion, 505, 512, 544
nerve, 505, 544
nuclei, 544
descending tract from, 495, 544, 547
region of the nares, 305
Vestibule, 654
ductus reuniens of, 654
endolymphatic duct, 654
sac, 654
saccule of, 654
utricle of, 654
utriculo-saccular duct of, 654
Vestibulo-semicircular canal group of segmental neurones, 505
spinal tract, 495
Vicq d'Azyr bundle of, 511, 597
Villi, 261
chorionic, 377
fastening, 377
floating, 377
free, 377
of small intestine, 262, 264
synovial, 210
terminal, 377
Virchow-Robin or adventitial lymph spaces, 434
Visceral nervous system, 423
neurones, 428
peritoneum, 224, 272
Vision, organ of, 627; see *Organ of Vision*
Visual area, 619
group of segmental neurones, 505

Visual path, 594
purple, 636
Vital properties of cells, 50, 218
function, 52
irritability, 52
metabolism, 51, 218
motion, 52
reproduction, 53
Vitreous body of the eye, 644
Cloquet's canal, 644
hyaloid canal of, 644
membrane of chorioid, 632
of iris, 632
Vocal cords, 307
Volkmann's canal, 196, 202
Voluntary motor path, 512
striated muscle, 118, 503; see *Muscle, striated, voluntary*
Von Bechterew's nucleus, 544, 557, 566
Von Bibra, concerning chemical composition of dentine, 233
of enamel, 238
Von Gudden, concerning method of determining fibre tracts of cord, 622
Von Monakow's bundle, 494

WAGNER, corpuscles of, 400
Wallerian degeneration, law of, 144
Wandering cells, 53, 87, 90, 111, 264
Washing after fixation, 13
Wax, ear, 652
Weigert's elastic-tissue stain, 28
hæmatoxylin, 22
method of staining medullated nerve fibres, 33
neuroglia stain, 40
Weigert-Pal method, 34
Weil, layer of, 233
Wernicke, perpendicular fasciculus of, 607
Wharton's duct, 284
jelly, 86
White blood cells (leucocytes), 109, 188
fibrous tissue, 86
matter of brain and cord, 428, 466
or fibrillated fibres, 90
rami communicantes, 451
Wilson, E. B., diagrams showing mitosis, 55, 57
Wirsung, duct of, 287
Wolffian body, 345, 383
Wrisburg, cartilage of, 307
ganglion of, 167
nerve of, 552

XYLOL and cajeput oil for clearing, 26
-balsam, 26
damar, 30
Xylol-paraffin for embedding, 16

YELLOW or elastic fibres, 85, 97, 307
Yellow bone marrow, 201
Yolk granules, 363

ZENKER'S fluid for decalcifying, 10
for fixation, 8
Zinn, zonule of, 644
Zona incerta, 595
pectinata, 659
pellucida, 62, 363
spongiosa, 466
tecta, 659
terminalis, 466
Zone of Lissauer, 458, 464, 466
of oval nuclei, 306
of round nuclei, 306
Zonula ciliaris, 644
Zonule of Zinn, 644
Zuckerkandl, organ of, 418
Zymogen granules, 287
technic of, 292